

World Journal of *Clinical Cases*

World J Clin Cases 2019 November 26; 7(22): 3683-3914



**REVIEW**

- 3683** Colorectal cancer: The epigenetic role of microbiome
Sabit H, Cevik E, Tombuloglu H

ORIGINAL ARTICLE**Case Control Study**

- 3698** Human podocyte injury in the early course of hypertensive renal injury
Sun D, Wang JJ, Wang W, Wang J, Wang LN, Yao L, Sun YH, Li ZL

Retrospective Cohort Study

- 3711** Relationship between acute hypercarbia and hyperkalaemia during surgery
Weinberg L, Russell A, Mackley L, Dunnachie C, Meyerov J, Tan C, Li M, Hu R, Karalapillai D

Retrospective Study

- 3718** Surgical treatment of patients with severe non-flail chest rib fractures
Zhang JP, Sun L, Li WQ, Wang YY, Li XZ, Liu Y
- 3728** Super-selective arterial embolization in the control of acute lower gastrointestinal hemorrhage
Ly LS, Gu JT
- 3734** End-stage liver disease score and future liver remnant volume predict post-hepatectomy liver failure in hepatocellular carcinoma
Kong FH, Miao XY, Zou H, Xiong L, Wen Y, Chen B, Liu X, Zhou JJ

Observational Study

- 3742** Treatment of hemorrhoids: A survey of surgical practice in Australia and New Zealand
Fowler GE, Siddiqui J, Zahid A, Young CJ
- 3751** Relationship between homocysteine level and prognosis of elderly patients with acute ischemic stroke treated by thrombolysis with recombinant tissue plasminogen activator
Li J, Zhou F, Wu FX

CASE REPORT

- 3757** Cystic fibrosis transmembrane conductance regulator functional evaluations in a G542X+/- IVS8Tn:T7/9 patient with acute recurrent pancreatitis
Caldrer S, Bergamini G, Sandri A, Vercellone S, Rodella L, Cerofolini A, Tomba F, Catalano F, Frulloni L, Buffelli M, Tridello G, de Jonge H, Assael BM, Sorio C, Melotti P

- 3765** Ulcerated intussuscepted jejunal lipoma-uncommon cause of obscure gastrointestinal bleeding: A case report
Cuciureanu T, Huiban L, Chiriac S, Singeap AM, Danciu M, Mihai F, Stanciu C, Trifan A, Vlad N
- 3772** Ultrasonographic evaluation of the effect of extracorporeal shock wave therapy on calcific tendinopathy of the rectus femoris tendon: A case report
Lee CH, Oh MK, Yoo JI
- 3778** Contrast-enhanced computed tomography findings of a huge perianal epidermoid cyst: A case report
Sun PM, Yang HM, Zhao Y, Yang JW, Yan HF, Liu JX, Sun HW, Cui Y
- 3784** Iatrogenic crystalline lens injury during intravitreal injection of triamcinolone acetonide: A report of two cases
Su J, Zheng LJ, Liu XQ
- 3792** Sagliker syndrome: A case report of a rare manifestation of uncontrolled secondary hyperparathyroidism in chronic renal failure
Yu Y, Zhu CF, Fu X, Xu H
- 3800** Pre-eclampsia with new-onset systemic lupus erythematosus during pregnancy: A case report
Huang PZ, Du PY, Han C, Xia J, Wang C, Li J, Xue FX
- 3807** Unilateral congenital scrotal agenesis with ipsilateral cryptorchidism: A case report
Fang Y, Lin J, Wang WW, Qiu J, Xie Y, Sang LP, Mo JC, Luo JH, Wei JH
- 3812** Metastatic infection caused by hypervirulent *Klebsiella pneumonia* and co-infection with *Cryptococcus meningitis*: A case report
Shi YF, Wang YK, Wang YH, Liu H, Shi XH, Li XJ, Wu BQ
- 3821** Allergic fungal rhinosinusitis accompanied by allergic bronchopulmonary aspergillosis: A case report and literature review
Cheng KJ, Zhou ML, Liu YC, Zhou SH
- 3832** Invasive aspergillosis presenting as hilar masses with stenosis of bronchus: A case report
Su SS, Zhou Y, Xu HY, Zhou LP, Chen CS, Li YP
- 3838** Retropharyngeal abscess presenting as acute airway obstruction in a 66-year-old woman: A case report
Lin J, Wu XM, Feng JX, Chen MF
- 3844** Thoracoscopic segmentectomy assisted by three-dimensional computed tomography bronchography and angiography for lung cancer in a patient living with situs inversus totalis: A case report
Wu YJ, Bao Y, Wang YL
- 3851** Single-lung transplantation for pulmonary alveolar microlithiasis: A case report
Ren XY, Fang XM, Chen JY, Ding H, Wang Y, Lu Q, Ming JL, Zhou LJ, Chen HW

- 3859** Respiratory failure and macrophage activation syndrome as an onset of systemic lupus erythematosus: A case report
Sun J, Wang JW, Wang R, Zhang H, Sun J
- 3866** Diagnosis of gastric duplication cyst by positron emission tomography/computed tomography: A case report
Hu YB, Gui HW
- 3872** Peritoneal cancer after bilateral mastectomy, hysterectomy, and bilateral salpingo-oophorectomy with a poor prognosis: A case report and review of the literature
Ma YN, Bu HL, Jin CJ, Wang X, Zhang YZ, Zhang H
- 3881** Apatinib for treatment of a pseudomyxoma peritonei patient after surgical treatment and hyperthermic intraperitoneal chemotherapy: A case report
Huang R, Shi XL, Wang YF, Yang F, Wang TT, Peng CX
- 3887** Novel frameshift mutation causes early termination of the thyroxine-binding globulin protein and complete thyroxine-binding globulin deficiency in a Chinese family: A case report
Dang PP, Xiao WW, Shan ZY, Xi Y, Wang RR, Yu XH, Teng WP, Teng XC
- 3895** Diffuse large B-cell lymphoma arising from follicular lymphoma with warthin's tumor of the parotid gland - immunophenotypic and genetic features: A case report
Wang CS, Chu X, Yang D, Ren L, Meng NL, Lv XX, Yun T, Cao YS
- 3904** Exogenous endophthalmitis caused by *Enterococcus casseliflavus*: A case report
Bao QD, Liu TX, Xie M, Tian X

LETTER TO THE EDITOR

- 3912** Microbial transglutaminase should be considered as an environmental inducer of celiac disease
Lerner A, Matthias T

ABOUT COVER

Editorial Board Member of *World Journal of Clinical Cases*, Ridvan Hamid Alimehmeti, MD, PhD, Associate Professor, Lecturer, Surgeon, Department of Neuroscience, University of Medicine, Tirana 1000, Albania

AIMS AND SCOPE

The primary aim of *World Journal of Clinical Cases* (WJCC, *World J Clin Cases*) is to provide scholars and readers from various fields of clinical medicine with a platform to publish high-quality clinical research articles and communicate their research findings online.

WJCC mainly publishes articles reporting research results and findings obtained in the field of clinical medicine and covering a wide range of topics, including case control studies, retrospective cohort studies, retrospective studies, clinical trials studies, observational studies, prospective studies, randomized controlled trials, randomized clinical trials, systematic reviews, meta-analysis, and case reports.

INDEXING/ABSTRACTING

The WJCC is now indexed in PubMed, PubMed Central, Science Citation Index Expanded (also known as SciSearch®), and Journal Citation Reports/Science Edition. The 2019 Edition of Journal Citation Reports cites the 2018 impact factor for WJCC as 1.153 (5-year impact factor: N/A), ranking WJCC as 99 among 160 journals in Medicine, General and Internal (quartile in category Q3).

RESPONSIBLE EDITORS FOR THIS ISSUE

Responsible Electronic Editor: Ji-Hong Liu

Proofing Production Department Director: Yun-Xiaojuan Wu

NAME OF JOURNAL

World Journal of Clinical Cases

ISSN

ISSN 2307-8960 (online)

LAUNCH DATE

April 16, 2013

FREQUENCY

Semimonthly

EDITORS-IN-CHIEF

Dennis A Bloomfield, Bao-Gan Peng, Sandro Vento

EDITORIAL BOARD MEMBERS

<https://www.wjnet.com/2307-8960/editorialboard.htm>

EDITORIAL OFFICE

Jin-Lei Wang, Director

PUBLICATION DATE

November 26, 2019

COPYRIGHT

© 2019 Baishideng Publishing Group Inc

INSTRUCTIONS TO AUTHORS

<https://www.wjnet.com/bpg/gerinfo/204>

GUIDELINES FOR ETHICS DOCUMENTS

<https://www.wjnet.com/bpg/GerInfo/287>

GUIDELINES FOR NON-NATIVE SPEAKERS OF ENGLISH

<https://www.wjnet.com/bpg/gerinfo/240>

PUBLICATION MISCONDUCT

<https://www.wjnet.com/bpg/gerinfo/208>

ARTICLE PROCESSING CHARGE

<https://www.wjnet.com/bpg/gerinfo/242>

STEPS FOR SUBMITTING MANUSCRIPTS

<https://www.wjnet.com/bpg/GerInfo/239>

ONLINE SUBMISSION

<https://www.f6publishing.com>

Apatinib for treatment of a pseudomyxoma peritonei patient after surgical treatment and hyperthermic intraperitoneal chemotherapy: A case report

Rong Huang, Xiu-Ling Shi, Yun-Fei Wang, Fei Yang, Ting-Tao Wang, Cun-Xu Peng

ORCID number: Rong Huang (0000-0003-4444-0385); Xiu-Ling Shi (0000-0002-8014-886X); Yun-Fei Wang (0000-0003-0958-9811); Fei Yang (0000-0002-6665-6358); Ting-Tao Wang (0000-0001-8915-4417); Cun-Xu Peng (0000-0002-0721-4859).

Author contributions: Huang R drafted, reviewed, and revised the manuscript; Peng CX and Wang TT were the primary physicians during the patient's inpatient stay; Shi XL provided the images; Wang YF and Yang F were involved in the editing and overseeing of the text; all authors have read and approved the final manuscript.

Informed consent statement: Informed consent as documented by signature was obtained from the patient.

Conflict-of-interest statement: The authors declare that they have no conflict of interest.

CARE Checklist (2016) statement: The authors have read the CARE Checklist (2016), and the manuscript was prepared and revised according to the CARE Checklist (2016).

Open-Access: This article is an open-access article which was selected by an in-house editor and fully peer-reviewed by external reviewers. It is distributed in accordance with the Creative Commons Attribution Non Commercial (CC BY-NC 4.0) license, which permits others to distribute, remix, adapt, build upon this work non-commercially,

Rong Huang, Fei Yang, Department of Clinical Medicine, Jining Medical University, Jining 272000, Shandong Province, China

Xiu-Ling Shi, Yun-Fei Wang, Ting-Tao Wang, Cun-Xu Peng, Department of Gynecology, The Affiliated Hospital of Jining Medical University, Jining Medical University, Jining 272000, Shandong Province, China

Corresponding author: Cun-Xu Peng, Doctor, Professor, Surgeon, Department of Gynecology, The Affiliated Hospital of Jining Medical University, Jining Medical University, 89 Guhuai Road, Jining 272000, Shandong Province, China. pengcunxu@aliyun.com
Telephone: +86-17562232048

Abstract

BACKGROUND

Pseudomyxoma peritonei (PMP) is a rare benign, but progressive, disease according to myxoma histopathology. Surgical resection is the preferred and most effective treatment, but the outcomes are often unsatisfactory.

CASE SUMMARY

A 63-year-old Chinese woman with PMP received apatinib at a daily dose of 0.5 mg for 15 d per cycle and at a daily dose of 0.4 mg to date for recurrent abdominal distension after surgical treatment and hyperthermic intraperitoneal chemotherapy. During the follow-up period, apatinib was the maintenance treatment with a progression-free period of 10 mo and the toxicity of apatinib was controllable and tolerable. Unfortunately, recurrence occurred 10 mo after administration. After two operations, the patient gave up treatment at the 18th mo and eventually died of intestinal obstruction and multiple organ failure.

CONCLUSION

Apatinib may be an option for recurrent PMP after surgical treatment, but this conclusion remains to be confirmed.

Key words: Pseudomyxoma peritonei; Abdominal distention; Anti-angiogenic agent; Apatinib; Case report

©The Author(s) 2019. Published by Baishideng Publishing Group Inc. All rights reserved.

Core tip: The preferred treatment for pseudomyxoma peritonei (PMP) is surgery, but it is

and license their derivative works on different terms, provided the original work is properly cited and the use is non-commercial. See: <http://creativecommons.org/licenses/by-nc/4.0/>

Manuscript source: Unsolicited manuscript

Received: July 20, 2019

Peer-review started: July 23, 2019

First decision: September 9, 2019

Revised: September 17, 2019

Accepted: October 5, 2019

Article in press: October 5, 2019

Published online: November 26, 2019

P-Reviewer: Morris DL, Nag DS

S-Editor: Dou Y

L-Editor: Wang TQ

E-Editor: Wu YXJ



easy to relapse after surgery. There is currently no good treatment for patients with postoperative recurrence. In this work, a PMP patient received apatinib for recurrent abdominal distension after surgical treatment and hyperthermic intraperitoneal chemotherapy. After treatment with apatinib, the recurrence time was significantly prolonged. Apatinib, a small-molecule oral inhibitor with anti-angiogenic function, may be an option for recurrent PMP after surgical treatment.

Citation: Huang R, Shi XL, Wang YF, Yang F, Wang TT, Peng CX. Apatinib for treatment of a pseudomyxoma peritonei patient after surgical treatment and hyperthermic intraperitoneal chemotherapy: A case report. *World J Clin Cases* 2019; 7(22): 3881-3886

URL: <https://www.wjgnet.com/2307-8960/full/v7/i22/3881.htm>

DOI: <https://dx.doi.org/10.12998/wjcc.v7.i22.3881>

INTRODUCTION

Pseudomyxoma peritonei (PMP) is a rare disease with an estimated incidence of 1 per million per year, and the appendix and ovaries are reported as the primary sites^[1]. Surgical resection is the preferred and most effective treatment. However, according to Sugarbaker^[2], the recurrence rate after tumor reduction can be as high as 100%. After aggressive cytoreductive surgery (CRS) and hyperthermic intraperitoneal chemotherapy (HIPEC), patient outcomes remain unsatisfactory due to recurrent abdominal distension. Thus, the development of effective novel agents, especially targeted therapy, is required to improve patient outcome.

Tumor angiogenesis has been found to be essential for tumor cell proliferation^[3]. Vascular endothelial growth receptor-2 (VEGFR-2) is an important factor involved in tumor angiogenesis.

Apatinib, a small-molecule inhibitor with anti-angiogenic function, acts mainly by the highly selective inhibition of vascular endothelial growth factor receptor-2 and is used in clinical practice for metastatic breast cancer, esophageal cancer, non-small-cell lung cancer, and hepatocellular carcinoma^[4,5]. This new oral drug can efficiently suppress tumor angiogenesis.

Here, we report on a patient with PMP who was treated with apatinib after CRS and HIPEC. This patient did not exhibit symptoms of abdominal distension during the 6 mo of follow-up, which demonstrated the potential of apatinib in the treatment of PMP.

CASE RRESETATION

Chief complaints

In November 2015, a 63-year-old woman arrived at our hospital with a 2-mo history of persistent abdominal distention along with an increased abdominal girth.

History of present illness

The patient's symptoms started two month ago with recurrent abdominal distention along with an increased abdominal girth.

History of past illness

The patient had a free previous medical history.

Physical examination upon admission

The patient's abdomen was bulging, but no obvious hard mass could be touched.

Laboratory examinations

The results of hematological examinations were: White blood cell count, $7.44 \times 10^9/L$; C-reactive protein, 44.00 mg/L; hemoglobin, 87 g/L; platelets, $254 \times 10^9/L$; no abnormalities in liver and kidney function tests. The tumor markers were not elevated (CEA, 138 ng/mL; CA19-9, 99.67 U/mL; CA125, 133.1 U/mL).

Imaging examinations

Computed tomography (CT) shows a large amount of fluid, and the lesion has affected the liver surface (Figure 1A).

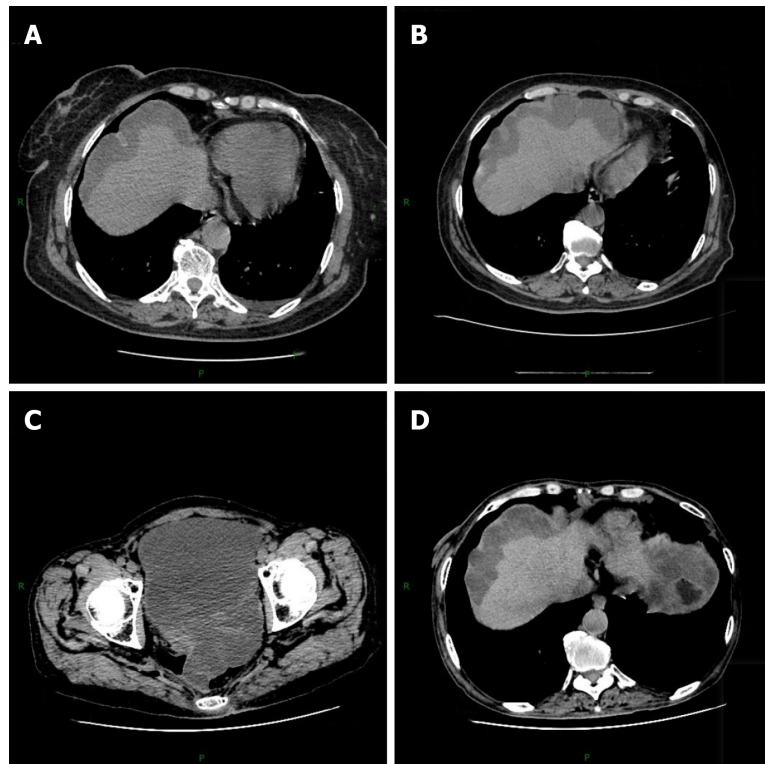


Figure 1 Chest and abdomen computed tomography. A: Before the operative treatment (November 24, 2015); B: After the operative treatment (January 1, 2016); C, D: After the apatinib treatment (December 18, 2017).

FINAL DIAGNOSIS

Ovarian cancer.

TREATMENT

The patient underwent intraperitoneal laparoscopic exploration on November 26, 2015. Intraperitoneal laparoscopic exploration revealed dense light-red ascitic fluid in the abdominopelvic cavity. The peritoneum, intestinal tube, liver, and diaphragm surfaces displayed disseminated gelatinous tumor implants, approximately 1 millimeter to 1 centimeter. The surface of the right ovary and fallopian tubes contained dense gelatinous nodules. Subsequently, some lesions, including those in the right ovary, peritoneum, and omentum, were excised for biopsy. Biopsy of the lesions showed low-grade mucinous neoplasm in the right ovary and pseudomyxoma in the peritoneum and omentum. The patient underwent debulking surgery on December 10, 2015, including total hysterectomy, left adnexectomy, greater omental resection, and appendectomy. Pathology confirmed low-grade mucinous neoplasm in the right ovary with metastatic implants in the peritoneum, intestinal tube, liver, and diaphragm (Figure 2).

Postoperative review CT showed that the patient's condition was temporarily improved (Figure 1B). However, on April 26, 2016, the patient presented at the Aero Space Center Hospital with a 1-mo history of recurrent abdominal distension. The patient underwent myxoma reduction surgery. Exploratory laparotomy revealed approximately 6000 mL of dense yellow ascites, peritoneal thickening, and gelatinous masses on the surface of the descending colon, sigmoid colon, mesentery, and pelvic peritoneal space. Then, the patient underwent enterolysis, peritoneal tumor resection, and small omental resection of the stomach. Meanwhile, the patient underwent HIPEC with 5-FU (1000 mg) and mitomycin (10 mg). After that, the patient received four cycles of HIPEC.

On June 18, 2017, the patient arrived at Yuncheng God Faith Hospital with the same complaint, recurrent abdominal distension. At this time, the patient had a poor appetite. The patient underwent two rounds of laparoscopic ascites removal by pumping. On June 20, 2017, the first laparoscopic ascites removal from the patient's abdominal cavity produced approximately 7000 mL of light yellow viscous gelatinous substance. After 20 d, the patient developed abdominal distension, which gradually

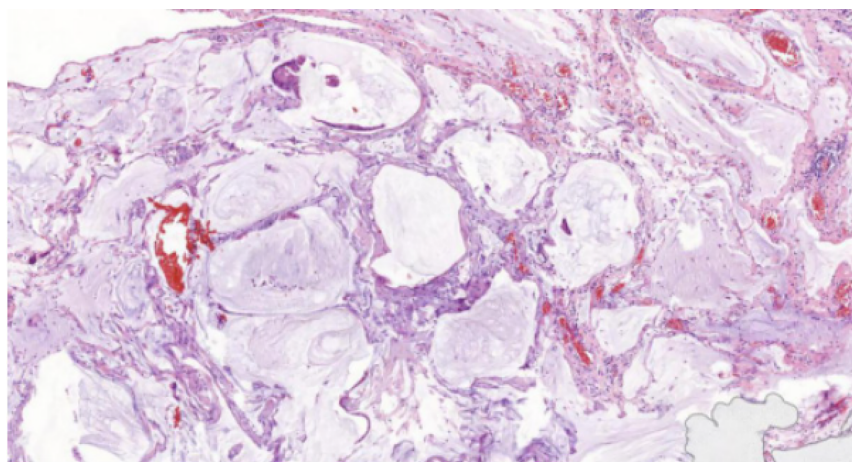


Figure 2 Hematoxylin and eosin staining of appendix lesions (×200).

increased. On August 22, 2017, the second laparoscopic ascites removal from the patient's abdominal cavity produced approximately 5000 mL of dark red gelatinous substance (Figure 3). By this time, the patient had become agitated about the multiple operative treatments. Therefore, we recommended her to receive apatinib as anti-angiogenesis therapy. After we explained the function and possible risks of apatinib, the patient signed an informed consent form for the administration of apatinib, which was approved by the Medical Ethics Committee of Yuncheng God Faith Hospital. Meanwhile, the patient provided her written informed consent for the accompanying images of the examination result to be published with this case study. On August 31, 2017, the ninth day after surgery, the patient received apatinib (0.25 mg bid) as the main treatment. After 15 d, the patient had high blood pressure of 160/100 mmHg. Since then, the patient has received valsartan and apatinib (0.45 mg qd).

OUTCOME AND FOLLOW-UP

Postoperative pathology showed low-grade mucinous neoplasm in the right ovary and pseudomyxoma in the peritoneum and omentum. The patient received apatinib at a daily dose of 0.5 mg for 15 d per cycle and at a daily dose of 0.4 mg to date for recurrent abdominal distension after surgical treatment and HIPEC. During apatinib treatment, the primary side effect developed by the patient was hypertension. This side effect was well controlled with drug treatment with valsartan.

On December 18, 2017, the patient visited our hospital for review. An abdominal CT scan revealed no obvious mucinous lesion. The patient's abdominal distention did not reappear. CT review results showed no progression (Figure 1C and D).

At the follow-up visit, the patient adhered to the above medication until the 10th mo after the medication, and the patient relapsed and was treated again with abdominal distension. In the 18th mo after the administration, the patient developed abdominal distension again with intestinal obstruction and multiple organ failure. After 15 d of maintenance treatment in an external hospital, he abandoned the treatment. After leaving the hospital for 20 d, he died at home.

DISCUSSION

To the best of our knowledge, this is the first case report of apatinib treatment for PMP. PMP is a rare benign, but progressive, condition associated with myxoma histopathology. The typical clinical manifestation is an enlarged tumor encroaching into the organs of the abdominal cavity, resulting in abdominal distension and an increase in abdominal circumference^[6]. The current best treatment for PMP is CRS combined with HIPEC^[7]. The literature reports that CRS combined with HIPEC can achieve a 5-year survival rate of 62.5% to 100.0% for low-grade malignancy and a 5-year survival rate of 0.0% to 65.0% for high-grade malignancy^[8,9]. Despite combination therapy, some patients will experience repeated relapse. For example, for this patient, although pathology indicated a low-grade disease, repeated recurrence was observed. Thus, new treatments are urgently needed, and new drugs and targeted therapy might be good options.

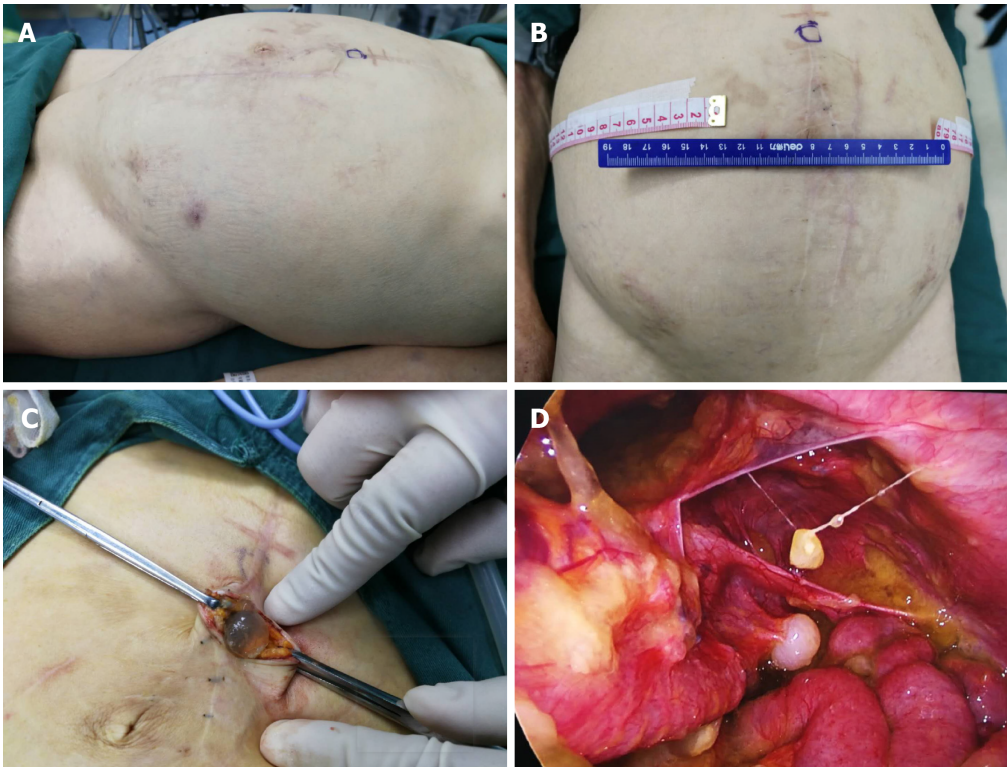


Figure 3 Preoperative and intraoperative photos of the patient. A: Preoperative side; B: Preoperative front; C: Cutting skin; D: Entering the abdominal cavity.

Angiogenesis is an important process for tumor growth and metastasis^[10]. VEGF plays an important role in angiogenesis and displays broad vascular functions by binding and activating VEGFR, a key regulator of the tyrosine kinase signaling pathway, especially VEGFR-2, which is mainly expressed in vascular endothelial cells^[11]. Therefore, VEGFR may be a target of anticancer therapy.

Apatinib, a small-molecule oral inhibitor with anti-angiogenic function, mainly targets VEGFR-2 through an intracellular ATP-binding site and inhibits all VEGF-stimulated endothelial cell migration and proliferation, decreases tumor microvascular density, and promotes apoptosis^[12]. In a phase II randomized clinical trial, a total of 144 patients with advanced metastatic gastric cancer who had failed two or more lines of chemotherapy were randomly assigned to a placebo (PL) group or two groups with different doses of apatinib^[13]. The results showed that the median overall survival of the three groups was 2.50 mo, 4.83 mo, and 4.27 mo, and the median progression-free survival of the three groups was 1.40 mo, 3.67 mo, and 3.20 mo, respectively, demonstrating a significant difference between the apatinib and PL groups, but no significant difference between the two apatinib groups. On October 17, 2014, apatinib was recommended for the treatment of advanced gastric adenocarcinoma of the gastroesophageal junction by the Food and Drug Administration of the People's Republic of China. Moreover, other clinical trials indicated that apatinib can be effective without severe additional toxicity in patients with hepatocellular carcinoma, ovarian cancer, and advanced non-squamous and non-small-cell lung cancer^[14,15].

In this case, the patient who had failed CRS and HIPEC received apatinib treatment. During treatment with apatinib, the patient did not experience severe side effects except hypertension, which was well controlled by drugs. Although the patient eventually relapsed, the time to relapse was extended from the original 2 mo to 10 mo, which significantly improved the quality of life of the patient. Although this is a single case, apatinib did have an effect on PMP.

Here, we report the first case of PMP treated with apatinib, which demonstrated improvement in the patient's condition. Apatinib may be an additional treatment option for PMP. Nevertheless, there are many questions: (1) Does apatinib affect all PMP types? (2) How to overcome rapid drug resistance if apatinib is effective? and (3) When is the best time to use apatinib for PMP patients? Thus, future clinical trials are still required.

CONCLUSION

Apatinib may be an option for recurrent PMP after surgical treatment, but this conclusion remains to be confirmed.

REFERENCES

- 1 **Ghosh RK**, Somasundaram M, Ravakhah K, Hassan C. Pseudomyxoma peritonei with intrathoracic extension: a rare disease with rarer presentation from low-grade mucinous adenocarcinoma of the appendix. *BMJ Case Rep* 2016; 2016 [PMID: 26729823 DOI: 10.1136/bcr-2015-211076]
- 2 **Sugarbaker PH**. Cytoreductive surgery and peri-operative intraperitoneal chemotherapy as a curative approach to pseudomyxoma peritonei syndrome. *Eur J Surg Oncol* 2001; 27: 239-243 [PMID: 11373099 DOI: 10.1053/ejso.2000.1038]
- 3 **Carmeliet P**, Jain RK. Angiogenesis in cancer and other diseases. *Nature* 2000; 407: 249-257 [PMID: 11001068 DOI: 10.1038/35025220]
- 4 **Hu X**, Zhang J, Xu B, Jiang Z, Ragaz J, Tong Z, Zhang Q, Wang X, Feng J, Pang D, Fan M, Li J, Wang B, Wang Z, Zhang Q, Sun S, Liao C. Multicenter phase II study of apatinib, a novel VEGFR inhibitor in heavily pretreated patients with metastatic triple-negative breast cancer. *Int J Cancer* 2014; 135: 1961-1969 [PMID: 24604288 DOI: 10.1002/ijc.28829]
- 5 **Zhang H**. Apatinib for molecular targeted therapy in tumor. *Drug Des Devel Ther* 2015; 9: 6075-6081 [PMID: 26622168 DOI: 10.2147/DDDT.S97235]
- 6 **Jacquemin G**, Laloux P. Pseudomyxoma peritonei: review on a cluster of peritoneal mucinous diseases. *Acta Chir Belg* 2005; 105: 127-133 [PMID: 15906901]
- 7 **Moran B**, Baratti D, Yan TD, Kusamura S, Deraco M. Consensus statement on the loco-regional treatment of appendiceal mucinous neoplasms with peritoneal dissemination (pseudomyxoma peritonei). *J Surg Oncol* 2008; 98: 277-282 [PMID: 18726894 DOI: 10.1002/jso.21054]
- 8 **Misdraji J**. Mucinous epithelial neoplasms of the appendix and pseudomyxoma peritonei. *Mod Pathol* 2015; 28 Suppl 1: S67-S79 [PMID: 25560600 DOI: 10.1038/modpathol.2014.129]
- 9 **Ramaswamy V**. Pathology of Mucinous Appendiceal Tumors and Pseudomyxoma Peritonei. *Indian J Surg Oncol* 2016; 7: 258-267 [PMID: 27065718 DOI: 10.1007/s13193-016-0516-2]
- 10 **Cowey CL**. Profile of tivozanib and its potential for the treatment of advanced renal cell carcinoma. *Drug Des Devel Ther* 2013; 7: 519-527 [PMID: 23818763 DOI: 10.2147/DDDT.S31442]
- 11 **Kieran MW**, Kalluri R, Cho YJ. The VEGF pathway in cancer and disease: responses, resistance, and the path forward. *Cold Spring Harb Perspect Med* 2012; 2: a006593 [PMID: 23209176 DOI: 10.1101/cshperspect.a006593]
- 12 **Li F**, Liao Z, Zhao J, Zhao G, Li X, Du X, Yang Y, Yang J. Efficacy and safety of Apatinib in stage IV sarcomas: experience of a major sarcoma center in China. *Oncotarget* 2017; 8: 64471-64480 [PMID: 28969086 DOI: 10.18632/oncotarget.16293]
- 13 **Li J**, Qin S, Xu J, Guo W, Xiong J, Bai Y, Sun G, Yang Y, Wang L, Xu N, Cheng Y, Wang Z, Zheng L, Tao M, Zhu X, Ji D, Liu X, Yu H. Apatinib for chemotherapy-refractory advanced metastatic gastric cancer: results from a randomized, placebo-controlled, parallel-arm, phase II trial. *J Clin Oncol* 2013; 31: 3219-3225 [PMID: 23918952 DOI: 10.1200/JCO.2013.48.8585]
- 14 **Li J**, Qin S, Xu J, Xiong J, Wu C, Bai Y, Liu W, Tong J, Liu Y, Xu R, Wang Z, Wang Q, Ouyang X, Yang Y, Ba Y, Liang J, Lin X, Luo D, Zheng R, Wang X, Sun G, Wang L, Zheng L, Guo H, Wu J, Xu N, Yang J, Zhang H, Cheng Y, Wang N, Chen L, Fan Z, Sun P, Yu H. Randomized, Double-Blind, Placebo-Controlled Phase III Trial of Apatinib in Patients With Chemotherapy-Refractory Advanced or Metastatic Adenocarcinoma of the Stomach or Gastroesophageal Junction. *J Clin Oncol* 2016; 34: 1448-1454 [PMID: 26884585 DOI: 10.1200/JCO.2015.63.5995]
- 15 **Ledermann JA**, Embleton AC, Raja F, Perren TJ, Jayson GC, Rustin GJS, Kaye SB, Hirte H, Eisenhauer E, Vaughan M, Friedlander M, González-Martín A, Stark D, Clark E, Farrelly L, Swart AM, Cook A, Kaplan RS, Parmar MKB; ICON6 collaborators. Cediranib in patients with relapsed platinum-sensitive ovarian cancer (ICON6): a randomised, double-blind, placebo-controlled phase 3 trial. *Lancet* 2016; 387: 1066-1074 [PMID: 27025186 DOI: 10.1016/S0140-6736(15)01167-8]



Published By Baishideng Publishing Group Inc
7041 Koll Center Parkway, Suite 160, Pleasanton, CA 94566, USA
Telephone: +1-925-2238242
E-mail: bpgoffice@wjgnet.com
Help Desk: <https://www.f6publishing.com/helpdesk>
<https://www.wjgnet.com>

