

World Journal of *Clinical Cases*

World J Clin Cases 2020 January 6; 8(1): 1-244





REVIEW

- 1 Role of oxysterol-binding protein-related proteins in malignant human tumours
Liu H, Huang S

ORIGINAL ARTICLE

Case Control Study

- 11 Oncogenic role of Tc17 cells in cervical cancer development
Zhang ZS, Gu Y, Liu BG, Tang H, Hua Y, Wang J

Retrospective Study

- 20 Acute distal common bile duct angle is risk factor for post-endoscopic retrograde cholangiopancreatography pancreatitis in beginner endoscopist
Han SY, Kim DU, Lee MW, Park YJ, Baek DH, Kim GH, Song GA
- 29 Three-dimensional computed tomography mapping of posterior malleolar fractures
Su QH, Liu J, Zhang Y, Tan J, Yan MJ, Zhu K, Zhang J, Li C
- 38 Application of a modified surgical position in anterior approach for total cervical artificial disc replacement
Hou WX, Zhang HX, Wang X, Yang HL, Luan XR
- 46 Potential role of the compound Eucommia bone tonic granules in patients with osteoarthritis and osteonecrosis: A retrospective study
Hu CX, Hu KY, Wang JF
- 54 Prognostic factors for overall survival in prostate cancer patients with different site-specific visceral metastases: A study of 1358 patients
Cui PF, Cong XF, Gao F, Yin JX, Niu ZR, Zhao SC, Liu ZL
- 68 Application of multiple Roux-en-Y hepaticojejunostomy reconstruction by formation of bile hilar duct lake in the operation of hilar cholangiocarcinoma
Yang XJ, Dong XH, Chen SY, Wu B, He Y, Dong BL, Ma BQ, Gao P

Observational Study

- 76 Relationship between β -amyloid protein 1-42, thyroid hormone levels and the risk of cognitive impairment after ischemic stroke
Mao L, Chen XH, Zhuang JH, Li P, Xu YX, Zhao YC, Ma YJ, He B, Yin Y

Prospective Study

- 88 Can the wet suction technique change the efficacy of endoscopic ultrasound-guided fine-needle aspiration for diagnosing autoimmune pancreatitis type 1? A prospective single-arm study
Sugimoto M, Takagi T, Suzuki R, Konno N, Asama H, Sato Y, Irie H, Watanabe K, Nakamura J, Kikuchi H, Takasumi M, Hashimoto M, Kato T, Hikichi T, Notohara K, Ohira H

CASE REPORT

- 97 Pembrolizumab - emerging treatment of pulmonary sarcomatoid carcinoma: A case report
Cimpeanu E, Ahmed J, Zafar W, DeMarinis A, Bardarov SS, Salman S, Bloomfield D
- 103 Sclerosing angiomatoid nodular transformation of the spleen, a rare cause for splenectomy: Two case reports
Chikhladze S, Lederer AK, Fichtner-Feigl S, Wittel UA, Werner M, Aumann K
- 110 Postpartum pubic symphysis diastasis-conservative and surgical treatment methods, incidence of complications: Two case reports and a review of the literature
Norvilaite K, Kezeviciute M, Ramasauskaite D, Arlauskienė A, Bartkeviciene D, Uvarovas V
- 120 Use of omental patch and endoscopic closure technique as an alternative to surgery after endoscopic full thickness resection of gastric intestinal stromal tumors: A series of cases
Sachdev AH, Iqbal S, Ribeiro IB, de Moura DTH
- 126 Primary maxillary chondrosarcoma: A case report
Cuevas-González JC, Reyes-Escalera JO, González JL, Sánchez-Romero C, Espinosa-Cristóbal LF, Reyes-López SY, Tovar Carrillo KL, Donohue Cornejo A
- 133 Hyalinizing clear cell carcinoma-a rare entity in the oral cavity: A case report
Donohue-Cornejo A, Paes de Almeida O, Sánchez-Romero C, Espinosa-Cristóbal LF, Reyes-López SY, Cuevas-González JC
- 140 Jejunal cavernous lymphangioma manifested as gastrointestinal bleeding with hypogammaglobulinemia in adult: A case report and literature review
Tan B, Zhang SY, Wang YN, Li Y, Shi XH, Qian JM
- 149 Large pelvic mass arising from the cervical stump: A case report
Zhang K, Jiang JH, Hu JL, Liu YL, Zhang XH, Wang YM, Xue FX
- 157 Mechanical intestinal obstruction due to isolated diffuse venous malformations in the gastrointestinal tract: A case report and review of literature
Li HB, Lv JF, Lu N, Lv ZS
- 168 Two-level percutaneous endoscopic lumbar discectomy for highly migrated upper lumbar disc herniation: A case report
Wu XB, Li ZH, Yang YF, Gu X

- 175 Successful treatment of congenital palate perforation: A case report
Zhang JF, Zhang WB
- 179 Calcitonin-negative neuroendocrine tumor of the thyroid with metastasis to liver-rare presentation of an unusual tumor: A case report and review of literature
Cai HJ, Wang H, Cao N, Huang B, Kong FL, Lu LR, Huang YY, Wang W
- 188 Giant exophytic cystic adenomyosis with a levonorgestrel containing intrauterine device out of the uterine cavity after uterine myomectomy: A case report
Zhou Y, Chen ZY, Zhang XM
- 194 Unusual presentation of bladder neuroblastoma in a child: A case report
Cai JB, Wang JH, He M, Wang FL, Xiong JN, Mao JQ, Li MJ, Zhu K, Liang JW
- 200 Value of dynamic plasma cell-free DNA monitoring in septic shock syndrome: A case report
Liu JP, Zhang SC, Pan SY
- 208 Sarcomatoid intrahepatic cholangiocarcinoma mimicking liver abscess: A case report
Wang Y, Ming JL, Ren XY, Qiu L, Zhou LJ, Yang SD, Fang XM
- 217 Clinical characteristics on manifestation and gene mutation of a transient neonatal cyanosis: A case report
Yuan J, Zhu XP
- 222 Six families with balanced chromosome translocation associated with reproductive risks in Hainan Province: Case reports and review of the literature
Chen YC, Huang XN, Kong CY, Hu JD
- 234 Primary intestinal extranodal natural killer/T-cell lymphoma, nasal type: A case report
Dong BL, Dong XH, Zhao HQ, Gao P, Yang XJ

LETTER TO THE EDITOR

- 242 Cluster headache as a manifestation of a stroke-like episode in a carrier of the MT-ND3 variant m.10158T>C
Finsterer J

ABOUT COVER

Editorial Board Member of *World Journal of Clinical Cases*, Maddalena Zippi, MD, PhD, Doctor, Unit of Gastroenterology and Digestive Endoscopy, Sandro Pertini Hospital, Rome 00157, Italy

AIMS AND SCOPE

The primary aim of *World Journal of Clinical Cases* (WJCC, *World J Clin Cases*) is to provide scholars and readers from various fields of clinical medicine with a platform to publish high-quality clinical research articles and communicate their research findings online.

WJCC mainly publishes articles reporting research results and findings obtained in the field of clinical medicine and covering a wide range of topics, including case control studies, retrospective cohort studies, retrospective studies, clinical trials studies, observational studies, prospective studies, randomized controlled trials, randomized clinical trials, systematic reviews, meta-analysis, and case reports.

INDEXING/ABSTRACTING

The WJCC is now indexed in PubMed, PubMed Central, Science Citation Index Expanded (also known as SciSearch®), and Journal Citation Reports/Science Edition. The 2019 Edition of Journal Citation Reports cites the 2018 impact factor for WJCC as 1.153 (5-year impact factor: N/A), ranking WJCC as 99 among 160 journals in Medicine, General and Internal (quartile in category Q3).

RESPONSIBLE EDITORS FOR THIS ISSUE

Responsible Electronic Editor: *Yan-Xia Xing*

Proofing Production Department Director: *Yun-Xiaojuan Wu*

NAME OF JOURNAL

World Journal of Clinical Cases

ISSN

ISSN 2307-8960 (online)

LAUNCH DATE

April 16, 2013

FREQUENCY

Semimonthly

EDITORS-IN-CHIEF

Dennis A Bloomfield, Bao-Gan Peng, Sandro Vento

EDITORIAL BOARD MEMBERS

<https://www.wjnet.com/2307-8960/editorialboard.htm>

EDITORIAL OFFICE

Jin-Lei Wang, Director

PUBLICATION DATE

January 6, 2020

COPYRIGHT

© 2020 Baishideng Publishing Group Inc

INSTRUCTIONS TO AUTHORS

<https://www.wjnet.com/bpg/gerinfo/204>

GUIDELINES FOR ETHICS DOCUMENTS

<https://www.wjnet.com/bpg/GerInfo/287>

GUIDELINES FOR NON-NATIVE SPEAKERS OF ENGLISH

<https://www.wjnet.com/bpg/gerinfo/240>

PUBLICATION MISCONDUCT

<https://www.wjnet.com/bpg/gerinfo/208>

ARTICLE PROCESSING CHARGE

<https://www.wjnet.com/bpg/gerinfo/242>

STEPS FOR SUBMITTING MANUSCRIPTS

<https://www.wjnet.com/bpg/GerInfo/239>

ONLINE SUBMISSION

<https://www.f6publishing.com>

Six families with balanced chromosome translocation associated with reproductive risks in Hainan Province: Case reports and review of the literature

Yun-Chun Chen, Xu-Ning Huang, Chang-Ying Kong, Jian-Dong Hu

ORCID number: Yun-Chun Chen (0000-0002-6554-3204); Xu-Ning Huang (0000-0001-8335-9454); Chang-Ying Kong (0000-0002-9449-9150); Jian-Dong Hu (0000-0003-2021-8886).

Author contributions: Chen YC and Hu JD designed and performed the study; Huang XN and Kong CY participated in acquisition, analysis, or interpretation of the data; Chen YC and Hu JD wrote the paper; all authors read and approved the final manuscript.

Supported by Natural Science Foundation of Hainan Province, NO. 819MS148.

Informed consent statement: Written informed consent was obtained from the patient for publication of this report and any accompanying images.

Conflict-of-interest statement: The authors declare that they have no conflict of interest.

CARE Checklist (2016) statement: The authors have read the CARE Checklist (2016), and the manuscript was prepared and revised according to the CARE Checklist (2016).

Open-Access: This article is an open-access article which was selected by an in-house editor and fully peer-reviewed by external reviewers. It is distributed in accordance with the Creative Commons Attribution Non Commercial (CC BY-NC 4.0) license, which permits others to

Yun-Chun Chen, Department of Laboratory Medicine, Haikou Branch of Yueyang Hospital of Integrated Traditional Chinese and Western Medicine, Shanghai University of Traditional Chinese Medicine (Haikou Hospital of Traditional Chinese Medicine), Haikou 570300, Hainan Province, China

Xu-Ning Huang, Department of Ultrasound Medicine, Second Affiliated Hospital of Hainan Medical University, Haikou 570300, Hainan Province, China

Chang-Ying Kong, Department of Gynecology, Second Affiliated Hospital of Hainan Medical University, Haikou 570300, Hainan Province, China

Jian-Dong Hu, Department of Internal Medicine, Haikou Branch of Yueyang Hospital of Integrated Traditional Chinese and Western Medicine, Shanghai University of Traditional Chinese Medicine (Haikou Hospital of Traditional Chinese Medicine), Haikou 570300, Hainan Province, China

Corresponding author: Jian-Dong Hu, MD, Doctor, Department of Internal Medicine, Haikou Branch of Yueyang Hospital of Integrated Traditional Chinese and Western Medicine, Shanghai University of Traditional Chinese Medicine (Haikou Hospital of Traditional Chinese Medicine), No. 45, Jinpan Road, Haikou 570216, Hainan Province, China.
hamlethu@163.com

Abstract

BACKGROUND

Balanced translocation refers to the process where breakage and reconnection of chromosomes occur at abnormal positions. As the genetic substance with balanced translocation in individuals does not change, which is usually characterized by normal phenotype and intelligence, the individuals seek medical service after many miscarriages, resulting in considerable mental and physical burdens of the family members. In the current era with rapid advances in detection technology, cytogenetic examination, as a definitive approach, still plays an essential role.

CASE SUMMARY

We report six cases with balanced chromosome translocation: Case 1: 46,XY,t(3;12)(q27;q24.1), infertility after 3 years of marriage; Case 2: 46,XX,t(4;16)(q31;q12), small uterus and irregular menstruation; Case 3: 46,XY,t(4;5)(q33;q13), 9qh+, not pregnant after arrested fetal development; Case 4: 46,XX,t(11;17)(q13;p11.2), not pregnant after two times of spontaneous abortion;

distribute, remix, adapt, build upon this work non-commercially, and license their derivative works on different terms, provided the original work is properly cited and the use is non-commercial. See: <http://creativecommons.org/licenses/by-nc/4.0/>

Manuscript source: Unsolicited manuscript

Received: July 28, 2019

Peer-review started: July 28, 2019

First decision: November 12, 2019

Revised: November 28, 2019

Accepted: December 13, 2019

Article in press: December 13, 2019

Published online: January 6, 2020

P-Reviewer: Gheita T, Huang AHC

S-Editor: Zhang L

L-Editor: Wang TQ

E-Editor: Liu MY



Case 5: 46,XX,t(10;13)(q24;q21.2), not pregnant after arrested fetal development for once; Case 6: 46,XX,t(1;4)(p36.1;q31.1), not pregnant after arrested fetal development for two times. The first four cases had chromosomal aberration karyotypes.

CONCLUSION

These results suggested that balanced chromosomal translocation carriers are associated with reproductive risks and a very high probability of abnormal pregnancy. The discovery of the first four reported chromosomal aberration karyotypes provides an important basis for studying the occurrence of genetic diseases.

Key words: Reproductive risk; Balanced translocation; Abnormal pregnancy; Genetic counseling; Case report

©The Author(s) 2020. Published by Baishideng Publishing Group Inc. All rights reserved.

Core tip: The genetic substance with balanced translocation in individuals does not change, which is usually characterized by normal phenotype. Here, we report six cases with balanced chromosome translocation: Case 1: 46,XY,t(3;12)(q27;q24.1), infertility for 3 years; Case 2: 46,XX,t(4;16)(q31;q12), small uterus and irregular menstruation; Case 3: 46,XY,t(4;5)(q33;q13), 9qh+, infertility; Case 4: 46,XX,t(11;17)(q13;p11.2), two times of spontaneous abortion; Case 5: 46,XX,t(10;13)(q24;q21.2), arrested fetal development for one time; Case 6: 46,XX,t(1;4)(p36.1;q31.1), arrested fetal development for two times. This study suggested that balanced chromosomal translocation carriers are associated with reproductive risks. The first four reported chromosomal aberration karyotypes provide an important basis for studying the occurrence of genetic diseases.

Citation: Chen YC, Huang XN, Kong CY, Hu JD. Six families with balanced chromosome translocation associated with reproductive risks in Hainan Province: Case reports and review of the literature. *World J Clin Cases* 2020; 8(1): 222-233

URL: <https://www.wjnet.com/2307-8960/full/v8/i1/222.htm>

DOI: <https://dx.doi.org/10.12998/wjcc.v8.i1.222>

INTRODUCTION

Chromosomal disorder is defined as a genetic disease caused by abnormalities in number, morphology, or structure of chromosomes, often resulting in miscarriage, congenital mental retardation, mental retardation, and multiple malformations clinically. This seriously threatens the health of humans. Chromosomal abnormalities cannot be treated in the current medical field, as they are irreversible. Balanced translocation is referred to as the situation where both breakage and reconnection of chromosomes occur at abnormal positions. Currently, the specific mechanisms underlying balanced translocation remain unclear. Translocation might be a completely harmless process or may cause serious health problems based on specific scenarios. In the first scenario, as the amount of individual chromosomal substance with balanced translocation does not change, which is usually characterized by normal phenotype and intelligence, the individuals look for medical services after undergoing many miscarriages. Chromosomes with balanced translocation can be inherited from parents or caused by the occurrence of new mutations^[1]. Hence, in the present study, six families with balanced chromosome translocation are described, where four individuals had chromosomal aberration karyotypes, and so further observation and analyses were performed. Further verification of these detection results of abnormal karyotypes has significance in guiding patients with clinical indications, such as spontaneous abortion, infertility, mental retardation, and fetal ultrasound abnormalities^[2].

CASE PRESENTATION

Chief complaints

(1) Case 1: Infertility after 3 years of marriage; (2) Case 2: Irregular menstruation; (3) Case 3: Not pregnant after arrested fetal development; (4) Case 4: Not pregnant after two times of spontaneous abortion; (5) Case 5: Not pregnant after arrested fetal development for one time; and (6) Case 6: Not pregnant after arrested fetal development for two times.

History of present illness

Five patients (Cases 1, 3, 4, 5, and 6) had infertility, and Case 2 had small uterus and irregular menstruation.

History of past illness

(1) Case 1: No significant past medical history; (2) Case 2: She received long-term traditional Chinese medicine for menstrual induction. The specific drugs and time were unknown. The uterus was small in size, and menstruation showed brown secretions; (3) Case 3: The medical abortion was reported during the first gestation, and arrested fetal development was reported after 60 d of pregnancy during the second gestation; (4) Case 4: Spontaneous abortion was reported after 50 d of pregnancy for two gestations; (5) Case 5: After 3 years of marriage, she underwent miscarriage after 1 mo of pregnancy due to no fetal heart. During her second pregnancy, blood was seen after 3 mo, and developmental arrest was noted. When engaged in physical work, she reported physical weakness, and advanced menstruation occurred often; and (6) Case 6: Arrested fetal development was observed after 60 d of pregnancy during the two gestations.

Personal and family history

Five patients (Cases 1, 3, 4, 5, and 6) had no significant personal or family history, and Case 2 had small uterus and irregular menstruation, but had no significant personal or family history.

Physical examination upon admission

(1) Case 1: The proband was a 30-year-old man who was 170 cm in height, and his phenotypic features and intelligence appeared normal; (2) Case 2: The proband was a 22-year-old unmarried woman who was 158 cm in height, and her phenotype and intelligence were normal; (3) Case 3: The proband was a 28-year-old man who was 172 cm in height, and his phenotype and intelligence were normal; (4) Case 4: The proband was a 32-year-old woman with a height of 153 cm, and her phenotype and intelligence were normal; (5) Case 5: The proband was a 24-year-old woman with a height of 158 cm, and her phenotype and intelligence were normal; and (6) Case 6: The proband was a 32-year-old woman with a height of 160 cm, and her phenotype and intelligence were normal.

Laboratory examinations

(1) Case 1: The results of semen examination based on three items (UU-DNA, CT-DNA, and NG-DNA) were normal, and showed anti-sperm antibody (-); (2) Case 2: Five items for sex hormones were unremarkable [luteinizing hormone (LH), follicle stimulating hormone (FSH), estradiol (E2), progesterone (PRG), and prolactin (PRL)], and the total testosterone (TES) level was normal; (3) Case 3: The results of routine semen tests were unremarkable; (4) Case 4: Five items of sex hormones (LH, FSH, E2, PRG, and PRL) were unremarkable. TES and insulin levels were normal. She had anti-sperm antibody (-); (5) Case 5: The five sex hormones (such as LH, FSH, E2, PRG, and PRL) were unremarkable. Her TES level was normal; and (6) Case 6: The five items of sex hormones (LH, FSH, E2, PRG, and PRL) were unremarkable. The TES was normal. Anti-sperm antibody was negative, and $-\alpha$ 4.2 thalassemia gene deletion type (heterozygous) was observed.

Imaging examinations

Five patients (Cases 1, 3, 4, 5, and 6) had normal imaging examinations, and Scanning under bladder filling in Case 2 showed that the uterus was small in size (3.9 mm \times 2.5 mm \times 3.1 mm).

FINAL DIAGNOSIS

Four chromosomal aberration karyotypes were identified by the expert group of Chinese Database of Human Abnormal Chromosome Karyotypes. No relevant report

was found in the “Chinese Human Chromosome Abnormality Karyotype Database”, “Cytogenetics Database”. Therefore, the karyotypes were included in the “Chinese Human Chromosome Abnormal Nuclei Database” (Database Numbers: 4222, 4059, 4238, and 4223). The genetic pedigree diagrams were drawn using Microsoft PowerPoint (Figures 1-6). The comparison of family history is shown in Table 1.

Case 1

G-banding chromosome analysis of peripheral blood (Database Number: 4222) showed 46,XY,t(3;12)(q27;q24.1) (Figure 1A). The genetic pedigree diagram is shown in Figure 1B.

Case 2

G-banding chromosome analysis of peripheral blood showed 46,XX,t(4;16)(q31;q12) (Figure 2A). The genetic pedigree diagram is shown in Figure 2B.

Case 3

G-banding chromosome analysis of peripheral blood showed 46,XY,t(4;5)(q33;q13),9qh+ (Figure 3A). The genetic pedigree diagram is shown in Figure 3B.

Case 4

G-banding chromosome analysis of peripheral blood (Database Number: 4059) showed 46,XX,t(11;17)(q13;p11.2) (Figure 4A). The genetic pedigree diagram was shown in Figure 4B.

Case 5

G-banding chromosome analysis of peripheral blood (Database Number: 4238) showed 46,XX,t(10;13)(q24;q21.2) (Figure 5A). The genetic pedigree diagram was shown in Figure 5B.

Case 6

G-banding chromosome analysis of peripheral blood (Database Number: 4223) showed 46,XX,t(1;4)(p36.1;q31.1) (Figure 6A). The genetic pedigree diagram was shown in Figure 6B.

TREATMENT

Case 1

In 2016, he underwent *in vitro* fertilization-embryo transfer (IVF-ET).

Case 2

The patient took drugs such as estrogen and progesterone to adjust the menstrual cycle.

Cases 3 and 4

In 2014, they underwent IVF-ET.

Cases 5 and 6

In 2016, they underwent IVF-ET.

OUTCOME AND FOLLOW-UP

(1) Case 1: No successful pregnancy; (2) Case 2: Menstruation was basically normal; (3) Case 3: No successful pregnancy; (4) Case 4: No successful pregnancy; (5) Case 5: No successful pregnancy; and (6) Case 6: Had first successful gestation for 5 mo in January 2019.

DISCUSSION

The six probands in the present study had a history of abnormal pregnancy or irregular menstruation. Cytogenetic karyotype analysis showed autosomal balanced translocation, and four of them were identified to have the world's first reported chromosomal aberration karyotypes. Despite the rapid development of molecular technology, cytogenetic analysis remains an indispensable tool^[3,4].

Chromosome breakage and recombination occur during spermatogenesis or

Table 1 History comparison table of the six families

Items	Family 1	Family 2	Family 3	Family 4	Family 5	Family 6
Area	Haikou, Hainan Province	Danzhou, Hainan Province	Wenchang, Hainan Province	Dongfang, Hainan Province	Haikou, Hainan Province	Qionghai, Hainan Province
Age (yr)	30	22	28	32	24	32
Sex	M	F	M	F	F	F
Ethnicity	Han	Han	Han	Han	Han	Han
Occupation	Office worker	Office worker	Civil servant	Office worker	Civil servant	Civil servant
Height (cm)	170	158	172	153	158	160
Visiting time	2016	2015	2014	2014	2016	2016
Reasons for medical visit	Infertility after 3 yr of marriage	Small uterus, irregular menstruation	Not pregnant after arrested fetal development	Not pregnant after two times of spontaneous abortion	Not pregnant after arrested fetal development for one time	Not pregnant after arrested fetal development for two times
Pregnancy history of self or spouse	G0P0	Unmarried	G2P0	G2P0	G1P0	G3P0
Proband karyotype	46,XY,t(3;12)(q27;q24.1)(Database number: 4222)	46,XX,t(4;16)(q31;q12)	46,XY,t(4;5)(q33;q13),9qh+	46,XX,t(11;17)(q13;p11.2)(Database number: 4059)	46,XX,t(10;13)(q24;q21.2)(Database number: 4238)	46,XX,t(1;4)(p36.1;q31.1)(Database number: 4223)
Spouse karyotype	46,XX	0	46,XX	46,XY	46,XY	46,XY
Spouse's age	30	0	25	38	28	35

oogenesis, or during fertilization process. The problem caused by these changes has a small probability, and moreover, these changes are unknown. The case reports by Sha *et al*^[5] and Mas *et al*^[6] showed that complex balanced translocation may be an important cause of oligospermia, suggesting that chromosomes with balanced translocation impedes the meiosis of germ cells, and leads to the damage of spermatogenesis. The reciprocal translocation of chromosomes occurs in the process of meiosis during gametogenesis. When the chromosomes are homologously paired, a quadriradial chromosome is formed. By alternate, adjacent, and 3:1 separations, 18 gametes are formed, in which there is a normal one and a balanced one, and the remaining 16 gametes are unbalanced. From references^[7-9], we know that the development of zygotes formed by these unbalanced gametes through fertilization forms a monosome or partial monosome, trisome, or partial trisome, leading to adverse outcomes of spontaneous abortion, stillbirth, fetal malformations, or neonatal death. Therefore, the likelihood of abnormal pregnancy for carriers is quite high, and this also explains the reasons for the six families with a history of abnormal pregnancy or irregular menstruation.

The chromosomal abnormality rate in the general population in China is 0.5%-1.0%, and the rate of chromosomal abnormalities in patients with a history of adverse pregnancy is 2%-10%^[10,11]. We retrospectively analyzed 36 articles from a population with a poor maternal history (Table 2): Among them, the detection rate of chromosomal abnormalities in 20 provinces and cities in China was 5.86% (2703/46133), the incidence of autosomal equilibrium translocation was 1.74% (804/46133), the detection rate of chromosomal abnormalities in 16 countries was 5.15% (1139/22134), and the incidence of autosomal equilibrium translocation was 2.35% (521/22134). The total detection rate of chromosomal abnormalities in patients with a poor maternal history in 20 provinces and cities in China and 16 countries was 5.62% (3842/68267), basically consistent with the aforementioned literature. The total incidence of autosomal balanced translocation was 1.97% (1325/68267). This analysis demonstrates that chromosomal abnormalities may be one of the important causes of a poor maternal history and it is necessary to carry out cytogenetic examination.

The study conducted by Clementini *et al*^[12] reported that each couple should undergo karyotyping in the infertility centers in Europe before receiving assisted reproductive therapy, with an aim to reduce the incidence of miscarriage or congenital anomalies. Studies have concluded that all women who require assisted reproductive therapy should undergo cytogenetic screening.

Recurrent miscarriage (RM) is defined as two or more consecutive spontaneous abortions, which accounted for 1% to 3% in couples^[13,14]. Zhu *et al*^[15] studied 42 balanced translocation carriers with a total of 90 pregnancies, in which spontaneous abortion occurred for 75 times during the early pregnancy, reaching an incidence of up to 83.4%. From the pedigree chart of Case 5 in this study, the mother of the proband was also accompanied by four adverse pregnancies. Although chromosomal

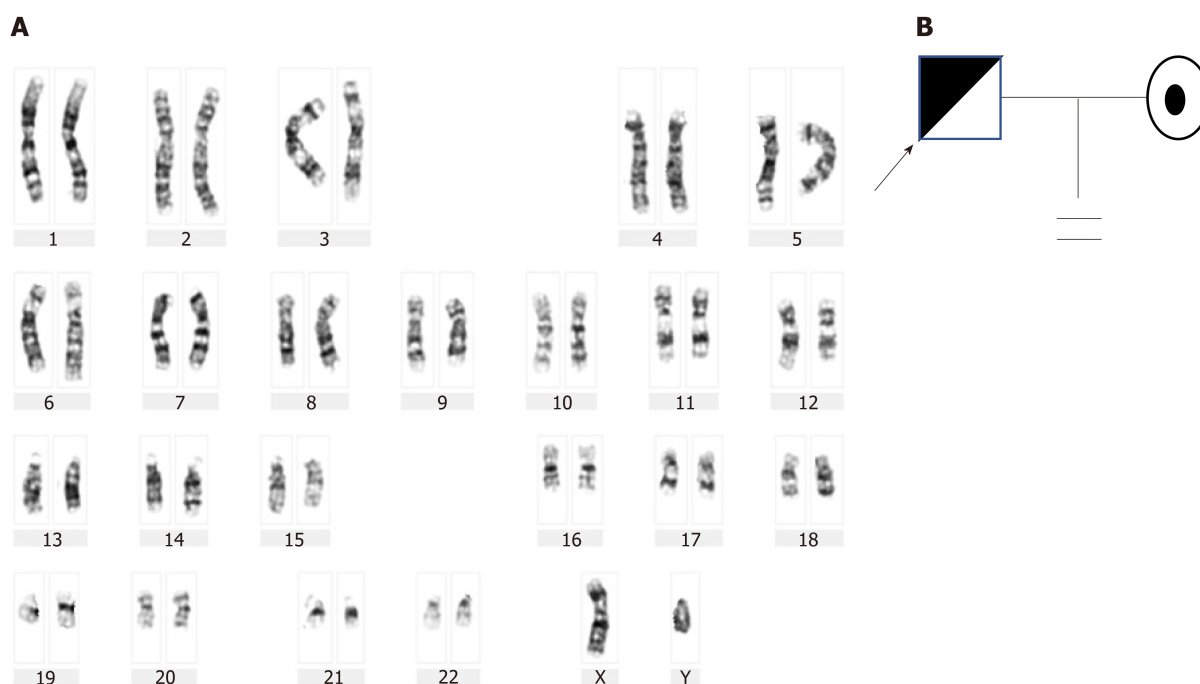


Figure 1 G-banding chromosome analysis and genetic pedigree diagram of Case 1. A: Karyogram (Database Number: 4222): 46,XY,t(3;12)(q27;q24.1); B: Genetic pedigree diagram.

detection was not performed, it was speculated to be inherited from the mother. The probands in the five families showed a history of adverse pregnancies. Multiple miscarriages can lead to emotional and physical trauma. To avoid the birth of infants with chromosomal abnormalities, intrauterine diagnosis is recommended for balanced chromosome translocation carriers at 16 to 20 wk of pregnancy. For couples with balanced translocations, the probability of birth of normal offspring is very small, and so assisted reproductive technology is recommended and preimplantation genetic diagnosis should be performed. Moreover, transplantation of normal embryos can significantly reduce the reproductive risk and pain of balanced translocation carriers, thus achieving the purpose of good childbearing and sound child-bearing^[16], for example, Case 6 reported successful conception after about 3 years.

Chromosomal examinations should be performed on those with a history of abnormal pregnancy, and if possible, the chromosomes of family members should be examined. A computerized database generated from the literature on cytogenetic studies in couples experiencing repeated pregnancy losses has been put in place at the University of Quebec at Chicoutimi. It contains data on 22199 couples (44398 individuals). It also appears that only translations are linked to a higher risk of pregnancy wastage^[17]. Bernardi *et al*^[18] suggested chromosome testing of the second miscarriage, to determine whether a recurrent pregnancy loss (RPL) evaluation is required. Selective RPL evaluation, which is based upon chromosome testing of the subsequent miscarriage, is a cost-saving strategy for couples with RPL when compared with universal RPL evaluation.

Kaneko *et al*^[19] believed that although the detection causes a variety of complex psychological problems for the probands, they believed that it was important to be aware as to which parent to inherit from. For example, studies by Bache *et al*^[20] resulted in changes in genetic counseling practice in Denmark. When balanced chromosome translocation carriers aged over 18 years underwent examinations during prenatal period or childhood, parents will receive a letter to remind the family regarding the importance of potential reproductive risks involved and recommend participation in genetic counseling. This helps us to identify the risks faced by future generations, and is extremely necessary for individuals to undergo targeted examinations as well as provide guidance for good childbearing and sound child-bearing.

The detection of new karyotypes of human chromosomes provides abundant data of medical genetics for genetic counseling and prenatal diagnosis. Our four cases had first reported chromosomal aberration karyotypes in this study, which can help us to better understand the balanced autosomal translocation involved in infertility. Also, the discovery and declaration of abnormal karyotypes provide an important basis for

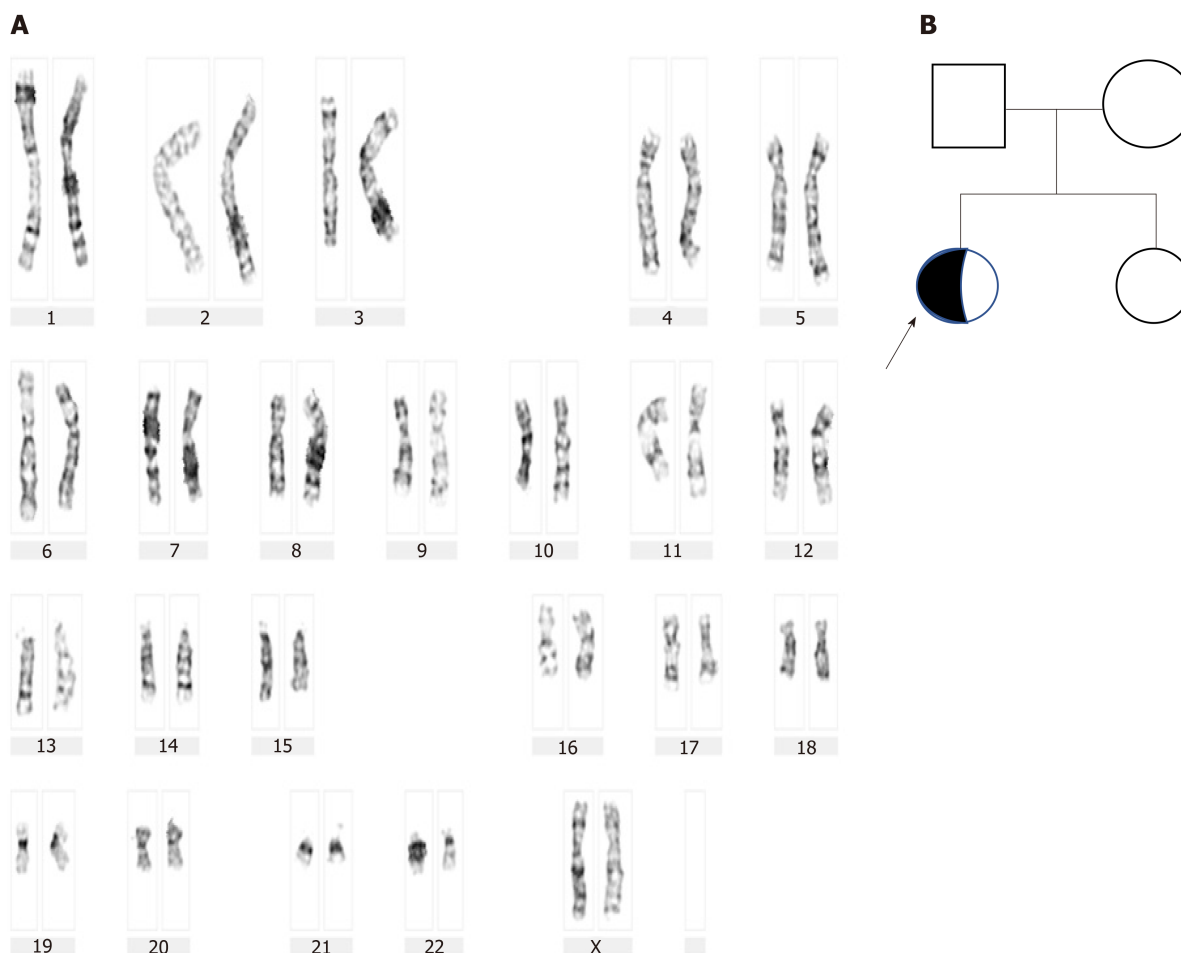


Figure 2 G-banding chromosome analysis and genetic pedigree diagram of Case 2. A: Karyogram: 46,XX,t(4;16)(q31;q12); B: Genetic pedigree diagram.

studying the occurrence, development, prevention, clinical diagnosis, and treatment of genetic diseases. Furthermore, pre-pregnancy and prenatal diagnosis is also important for good childbearing and sound child-bearing, decreasing the birth of infants with malformations and hypophrenia.

However, our study had a few limitations, such as inclusion of small sample size and unavailability of cytogenetic analysis of miscarriage materials, history of the diagnosis, and previous history of treatment. In future, a study with large sample size should be conducted to provide more useful insight for clinical diagnosis.

CONCLUSION

This study suggested that balanced chromosomal translocation carriers are associated with reproductive risks. The first four reported chromosomal aberration karyotypes provide an important basis for studying the occurrence of genetic diseases. This analysis demonstrates that chromosomal abnormalities may be one of the important causes of a poor maternal history and it is necessary to carry out cytogenetic examination.

Table 2 Chromosome detection rates in China's 20 provinces and cities and 16 countries

No	Region	Anomaly chromosome detection rate	Incidence of autosomal balanced translocation	Medical history
1	Hainan Province, China ^[21]	10.5% (353/3353)	0.44% (15/3353)	Genetic counselors
2	Gansu Province, China ^[22]	3.91% (51/1304)	1% (13/1304)	Genetic counselors
3	Ningxia Hui Autonomous Region, China ^[23]	3.52% (36/1024)	2.5% (26/1024)	Recurrent spontaneous abortion
4	Shanxi Province, China ^[24]	23.76% (307/1292)	14% (185/1292)	Abnormal child-bearing history
5	Shandong Province, China ^[25]	4.73% (309/6534)	0.39% (26/6534)	Abnormal child-bearing history
6	Hebei Province, China ^[26]	2.09% (70/3348)	1.1% (36/3348)	Infertility
7	Zhejiang Province, China ^[27]	6.6% (106/1601)	0.5% (8/1601)	Infertility
8	Shanghai, China ^[28]	3.96% (111/2798)	1.24% (37/2798)	Natural abortion
9	Fujian Province, China ^[29]	4.32% (87/2110)	1.18% (25/2110)	Abnormal child-bearing history
10	Beijing, China ^[30]	7% (28/400)	2.5% (10/400)	Abnormal child-bearing history
11	Anhui Province, China ^[31]	5.35% (353/6600)	2.98% (197/6600)	Infertility
12	Hubei Province, China ^[32]	20.2% (315/1559)	3.72% (58/1559)	Recurrent abortion
13	Guizhou Province, China ^[33]	5.12% (32/625)	4.16% (26/625)	Abnormal child-bearing history
14	Yunnan Province, China ^[34]	1.5% (3/200)	1% (2/200)	Abnormal child-bearing history
15	Guangdong Province, China ^[35]	10.37% (132/1273)	1.1% (14/1273)	Abnormal child-bearing history
16	Jiangsu Province, China ^[36]	1.7% (90/5292)	0.6% (32/5292)	Infertility
17	Hunan Province, China ^[37]	3.14% (111/3540)	1.67% (59/3540)	Natural abortion
18	Heilongjiang Province, China ^[38]	4.51% (82/455)	3.3% (15/455)	Genetic counselors
19	Henan Province, China ^[39]	11.5% (21/182)	4.4% (8/182)	Natural abortion
20	Sichuan Province, China ^[40]	4% (106/2643)	0.45% (12/2643)	Genetic counselors
21	Republic of Macedonia ^[41]	0.47% (16/3800)	0.21% (8/3800)	Natural abortion
22	United Kingdom of Great Britain and Northern Ireland ^[42]	3.52% (56/1590)	2.26% (36/1590)	Recurrent abortion
23	Turkey ^[43]	4.1% (124/3020)	0.99% (30/3020)	Natural abortion
24	Republic of India ^[44]	6.8% (54/788)	5.9% (47/788)	Recurrent abortion
25	Japan ^[45]	4.3% (55/1278)	1.5% (19/1278)	Recurrent abortion
26	Morocco ^[46]	11% (137/1254)	2.71% (34/1254)	Recurrent abortion
27	Islamic Republic of Iran ^[47]	11.7% (170/1456)	7.35% (107/1456)	Recurrent abortion
28	the United Mexican States ^[48]	7.6% (24/316)	1.27% (4/316)	Recurrent abortion
29	Sultanate of Oman ^[49]	3.42% (26/760)	2.8% (21/760)	Recurrent abortion
30	Kingdom of Saudi Arabia ^[50]	7.2% (154/2148)	3.35% (72/2148)	Recurrent abortion
31	Magyarország ^[51]	3.39% (8/236)	0.85% (2/236)	Recurrent abortion
32	Islamic Republic of Pakistan ^[52]	5.3% (32/600)	2.3% (14/600)	Recurrent abortion
33	The Republic Of Poland ^[53]	6.2% (16/258)	4.65% (12/258)	Recurrent abortion
34	Russia ^[54]	2.37% (81/3414)	1.9% (65/3414)	Infertility
35	Tunis ^[55]	8.5% (28/326)	3.68% (12/326)	Recurrent abortion
36	Spain ^[56]	17.7% (158/890)	4.27% (38/890)	Recurrent abortion
Total (1-20)		5.86% (2703/46133)	1.74% (804/46133)	
Total (21-36)		5.15% (1139/22134)	2.35% (521/22134)	
Total (1-36)		5.62% (3842/68267)	1.97% (1325/68267)	

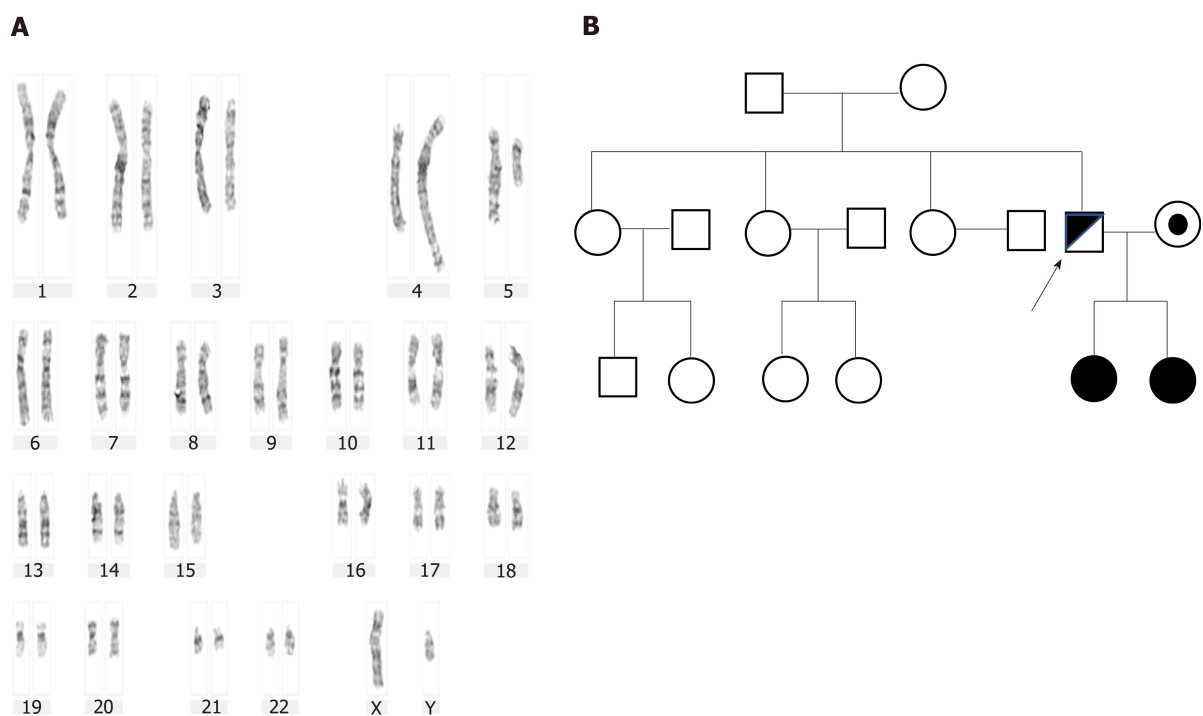


Figure 3 G-banding chromosome analysis and genetic pedigree diagram of Case 3. A: Karyogram: 46,XY,t(4;5)(q33;q13),9qh+; B: Genetic pedigree diagram.

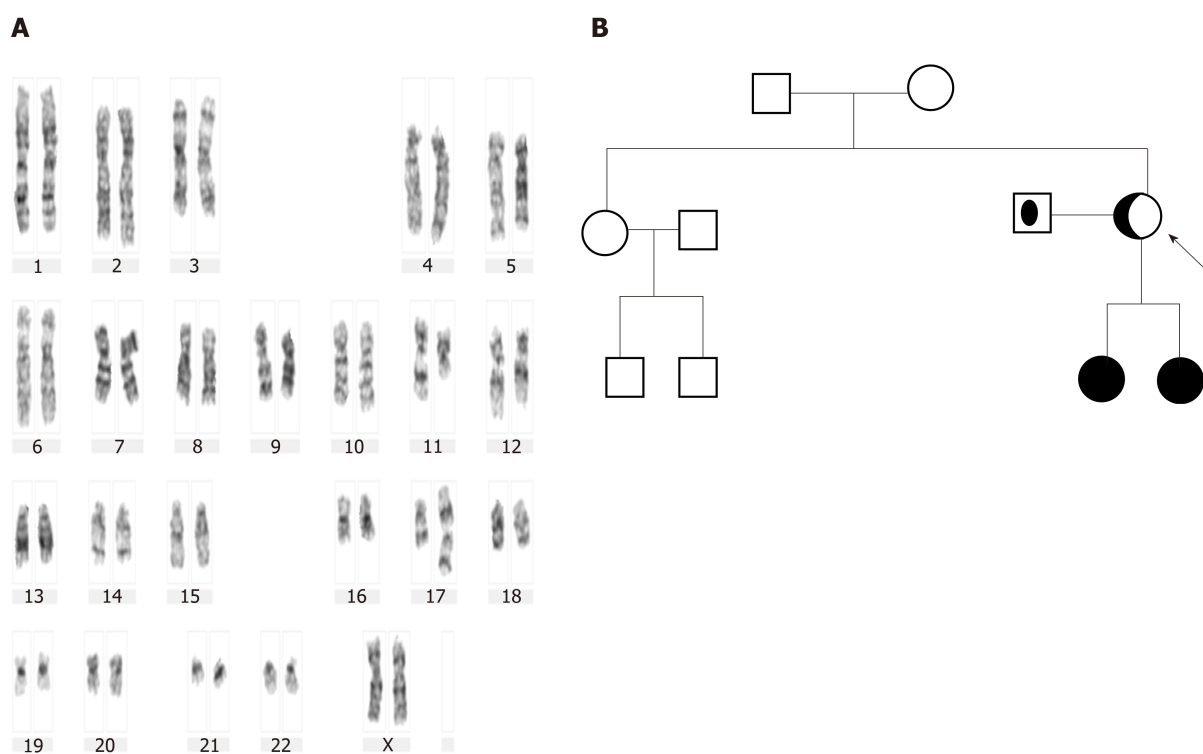


Figure 4 G-banding chromosome analysis and genetic pedigree diagram of Case 4. A: Karyogram (Database Number: 4059): 46,XX,t(11;17)(q13;p11.2); B: Genetic pedigree diagram.

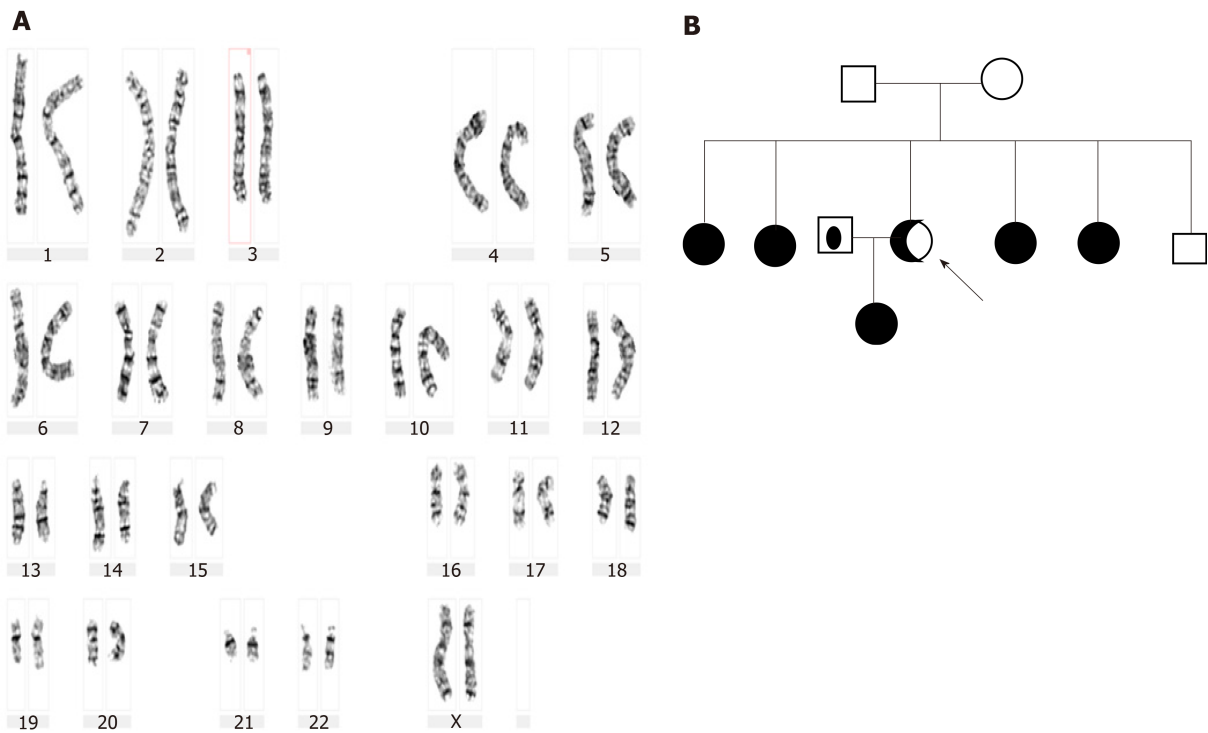


Figure 5 G-banding chromosome analysis and genetic pedigree diagram of Case 5. A: Karyogram (Database Number: 4238): 46,XX,t(10;13)(q24;q21.2); B: Genetic pedigree diagram.

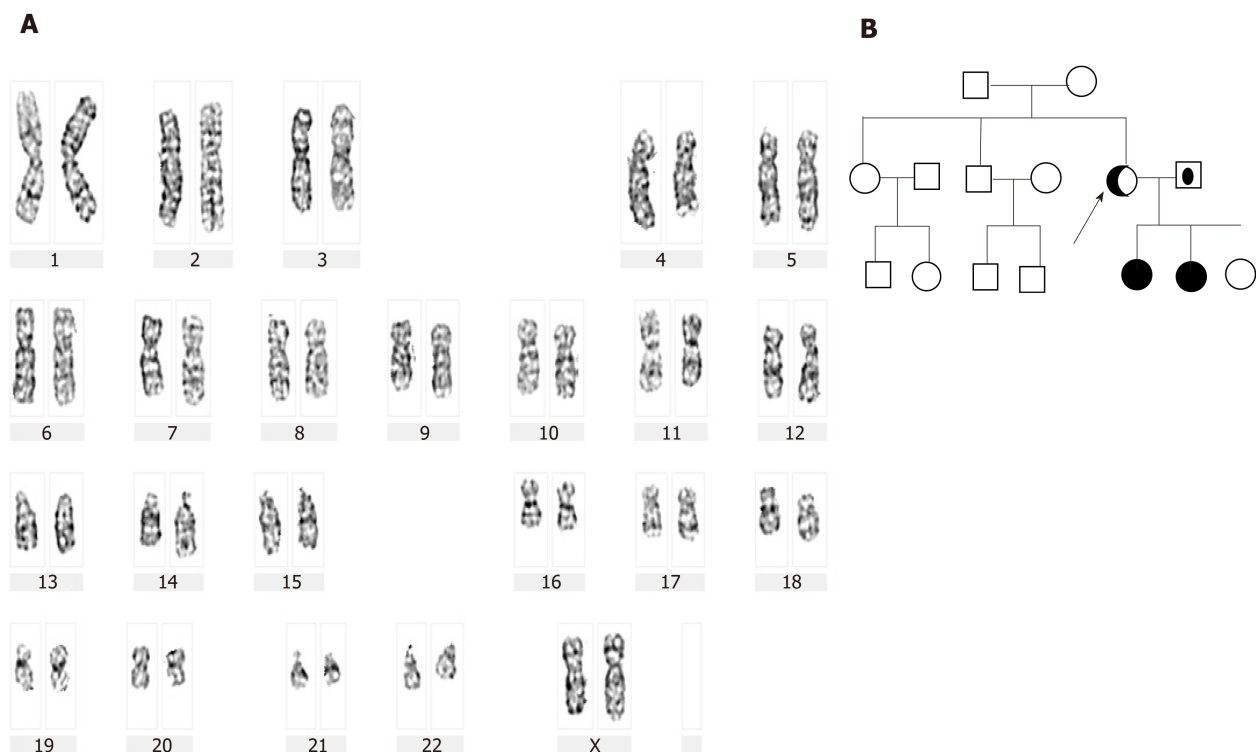


Figure 6 G-banding chromosome analysis and genetic pedigree diagram of Case 6. A: Karyogram (Database Number: 4223): 46,XX,t(1;4)(p36.1;q31.1); B: Genetic pedigree diagram.

REFERENCES

- 1 Wilch ES, Morton CC. Historical and Clinical Perspectives on Chromosomal Translocations. *Adv Exp Med Biol* 2018; **1044**: 1-14 [PMID: 29956287 DOI: 10.1007/978-981-13-0593-1_1]

- 2 **Ou S**, Du J, Chen SK, Zheng CG, Meng DH, Zhang HY, Qiu QM, Liu TS, Tang B. [Cytogenetic analysis of 105 new human abnormal karyotypes]. *Yi Chuan* 2013; **35**: 885-889 [PMID: [23853359](#) DOI: [10.3724/SP.J.1005.2013.00885](#)]
- 3 **Yokoyama E**, Del Castillo V, Sánchez S, Ramos S, Molina B, Torres L, Navarro MJ, Avila S, Castrillo JL, Garcia-De Teresa B, Asch B, Frias S. Derivative chromosomes involving 5p large rearranged segments went unnoticed with the use of conventional cytogenetics. *Mol Cytogenet* 2018; **11**: 30 [PMID: [29760780](#) DOI: [10.1186/s13039-018-0374-4](#)]
- 4 **Verma S**, Shah R, Bhat A, Bhat GR, Dada R, Kumar R. A Familial Case Report of a 13;22 Chromosomal Translocation with Recurrent Intracytoplasmic Sperm Injection Failure. *Balkan J Med Genet* 2018; **21**: 73-77 [PMID: [30984530](#) DOI: [10.2478/bjmg-2018-0017](#)]
- 5 **Sha YW**, Mei LB, Ji ZY, Ding L, Ge Y, Wu Q, Kong H, Su ZY, Li P. Two cases of complex balanced autosomal translocations associated with severe oligozoospermia. *Gene* 2018; **663**: 126-130 [PMID: [29684482](#) DOI: [10.1016/j.gene.2018.04.052](#)]
- 6 **Mas J**, Sabouni R, Bocca S. A novel male 2;4;14 complex chromosomal translocation with normal semen parameters but 100% embryonic aneuploidy. *J Assist Reprod Genet* 2018; **35**: 907-912 [PMID: [29380280](#) DOI: [10.1007/s10815-018-1126-4](#)]
- 7 **Zhang K**, Huang Y, Dong R, Yang Y, Wang Y, Zhang H, Zhang Y, Gai Z, Liu Y. Familial intellectual disability as a result of a derivative chromosome 22 originating from a balanced translocation (3;22) in a four generation family. *Mol Cytogenet* 2018; **11**: 18 [PMID: [29467824](#) DOI: [10.1186/s13039-017-0349-x](#)]
- 8 **De Krom G**, Arens YH, Coonen E, Van Ravenswaaij-Arts CM, Meijer-Hoogeveen M, Evers JL, Van Golde RJ, De Die-Smulders CE. Recurrent miscarriage in translocation carriers: no differences in clinical characteristics between couples who accept and couples who decline PGD. *Hum Reprod* 2015; **30**: 484-489 [PMID: [25432924](#) DOI: [10.1093/humrep/deu314](#)]
- 9 **Crippa M**, Giangiobbe S, Villa R, Bestetti I, De Filippis T, Fatti L, Taurino J, Larizza L, Persani L, Bellini F, Finelli P, Bonati MT. A balanced reciprocal translocation t (10;15) (q22.3; q26.1) interrupting ACAN gene in a family with proportionate short stature. *J Endocrinol Invest* 2018; **41**: 929-936 [PMID: [29302920](#) DOI: [10.1007/s40618-017-0819-3](#)]
- 10 **Codina-Pascual M**, Navarro J, Oliver-Bonet M, Kraus J, Speicher MR, Arango O, Egozcue J, Benet J. Behaviour of human heterochromatic regions during the synapsis of homologous chromosomes. *Hum Reprod* 2006; **21**: 1490-1497 [PMID: [16484310](#) DOI: [10.1093/humrep/del028](#)]
- 11 **Liu Y**, Kong XD, Wu QH, Li G, Song L, Sun YP. Karyotype analysis in large-sample infertile couples living in Central China: a study of 14965 couples. *J Assist Reprod Genet* 2013; **30**: 547-553 [PMID: [23474860](#) DOI: [10.1007/s10815-013-9964-6](#)]
- 12 **Clementini E**, Palka C, Iezzi I, Stuppia L, Guanciali-Franchi P, Tiboni GM. Prevalence of chromosomal abnormalities in 2078 infertile couples referred for assisted reproductive techniques. *Hum Reprod* 2005; **20**: 437-442 [PMID: [15567875](#) DOI: [10.1093/humrep/deh626](#)]
- 13 **Rull K**, Nagirnaja L, Laan M. Genetics of recurrent miscarriage: challenges, current knowledge, future directions. *Front Genet* 2012; **3**: 34 [PMID: [22457663](#) DOI: [10.3389/fgene.2012.00034](#)]
- 14 **McCarthy FP**, Moss-Morris R, Khashan AS, North RA, Baker PN, Dekker G, Poston L, McCowan L, Walker JJ, Kenny LC, O'Donoghue K. Previous pregnancy loss has an adverse impact on distress and behaviour in subsequent pregnancy. *BJOG* 2015; **122**: 1757-1764 [PMID: [25565431](#) DOI: [10.1111/1471-0528.13233](#)]
- 15 **Zhu YY**, Dai MJ, Tao ZH, Zhu SY. The effect of balanced translocation of chromosome on pregnancy outcome. *Zhongguo Fuyou Baojian Zazhi* 2008; **23**: 204-206 [DOI: [10.3969/j.issn.1001-4411.2008.02.032](#)]
- 16 **Hao XS**, Ma HQ, Yang LM, Liu XL, Guo ZJ, Zhu JZ. An analysis of 2 patients with chromosome karyotype being balanced translocation. *Zhongguo Yousheng Yu Yichuan Zazhi* 2018; **11**: 57
- 17 **De Braekeleer M**, Dao TN. Cytogenetic studies in couples experiencing repeated pregnancy losses. *Hum Reprod* 1990; **5**: 519-528 [PMID: [2203803](#) DOI: [10.1093/oxfordjournals.humrep.a137135](#)]
- 18 **Bernardi LA**, Plunkett BA, Stephenson MD. Is chromosome testing of the second miscarriage cost saving? A decision analysis of selective versus universal recurrent pregnancy loss evaluation. *Fertil Steril* 2012; **98**: 156-161 [PMID: [22516510](#) DOI: [10.1016/j.fertnstert.2012.03.038](#)]
- 19 **Kaneko M**, Ohashi H, Takamura T, Kawame H. Psychosocial Responses to being Identified as a Balanced Chromosomal Translocation Carrier: a Qualitative Investigation of Parents in Japan. *J Genet Couns* 2015; **24**: 922-930 [PMID: [25787091](#) DOI: [10.1007/s10897-015-9828-6](#)]
- 20 **Bache I**, Brondum-Nielsen K, Tommerup N. Genetic counseling in adult carriers of a balanced chromosomal rearrangement ascertained in childhood: experiences from a nationwide reexamination of translocation carriers. *Genet Med* 2007; **9**: 185-187 [PMID: [17413423](#) DOI: [10.1097/GIM.0b013e3180314671](#)]
- 21 **Chen YC**, Wang XF, Xu YN, Cao XQ, Zheng CJ, Lin LY, Hu JD. Cytogenetic analysis of 3353 genetic counselors in Hainan area. *Zhongguo Yousheng Yu Yichuan Zazhi* 2019; **7**: 827-829
- 22 **Hao SJ**, Yan YS. Genetic examination and clinical analysis of chromosomal abnormalities in Lanzhou area. *Zhongguo Yousheng Yu Yichuan Zazhi* 2007; **15**: 31 [DOI: [10.3969/j.issn.1006-9534.2007.07.019](#)]
- 23 **Zhan FS**, Wan Y, Ma YJ, Sui RZ, Wang GP, Huo ZH. Karyotype analysis of peripheral blood of 512 couples with recurrent spontaneous abortion in Ningxia region. *Shandong Yiyao Zazhi* 2019; **59**: 52-54 [DOI: [10.3969/j.issn.1002-266X.2019.29.015](#)]
- 24 **Yang WX**, Qin L, Gao RH, Wang DT, Chen BL, Zhang JF. Relationship between adverse pregnancy history and chromosomal abnormalities. *Zhongguo Yousheng Yu Yichuan Zazhi* 2019; **27**: 1070-1071 [DOI: [10.13404/j.cnki.cjbh.2019.09.017](#)]
- 25 **Zhang J**, Ma YR, Guo KJ, Liu YY, Guo LL, Zheng SY, Han X, Guo QQ. Clinical study on prevention of birth defects in prenatal diagnosis by pedigree analysis of chromosomal karyotype abnormalities. *Zhongguo Fuyou Baojian Zazhi* 2019; **34**: 4258-4262
- 26 **Liu XG**, Liu XY, Chen F, Wang W, Zhang JS. Cytogenetic analysis of 3348 infertile patients. *Zhongguo Yousheng Yu Yichuan Zazhi* 2019; **27**: 299-300
- 27 **Chen YF**, Zou B, Wang ZY. Cytogenetic analysis of 3335 patients with genetic counseling in Ningbo area. *Zhongguo Yousheng Yu Yichuan Zazhi* 2013; **21**: 33
- 28 **Yu J**, Gong B, Hou YP, Hu HY, Zhang L. Clinical analysis of balanced translocation and inversion of chromosomes in couples with spontaneous abortion. *Zhongguo Yousheng Yu Yichuan Zazhi* 2016; **44**: 58-60
- 29 **Xiao YS**, Kong H, Zeng H, Wu HN, Shen YY, Wu Q, Ge YS, Zhou YL. Cytogenetic analysis of 1055 couples with adverse pregnancy history. *Xiandai Yixue Zazhi* 2014; **42**: 1433-1435 [DOI: [10.3969/j.issn.1001-4411.2014.02.032](#)]

- 10.3969/j.issn.1671-7562.2014.12.014]
- 30 **Yang X**, Zhu LN, Ma N, Wang CZ. Cytogenetic analysis of 200 couples with adverse pregnancy history. *Zhongguo Fuyou Baojian Zazhi* 2012; **27**: 4957-4960
 - 31 **Tang J**, Zhang ZG. Cytogenetic analysis of 6600 patients with infertility. *Anhui Yixue Zazhi* 2019; **40**: 406-409 [DOI: 10.3969/j.issn.1000-0399.2019.04.014]
 - 32 **Chen QQ**, Ren W, Xiong GP. Major chromosomal abnormalities and chromosome polymorphism in 1559 couples with recurrent miscarriages. *Zhongguo Fuyou Jianshang Yanjiu Zazhi* 2018; **29**: 126-129 [DOI: 10.3969/j.issn.1673-5293.2018.10.030]
 - 33 **Li GP**, Wang B. Cytogenetic analysis of 625 couples with adverse pregnancy history in Guiyang. *Zhongguo Yousheng Yu Yichuan Zazhi* 2013; **21**: 59-60
 - 34 **Qian Y**, Xiao X, Zhang L, Guo Z, Lu L. Cytogenetic analysis of 100 couples with abnormal pregnancy history. *Kunming Yixueyuan Xueban* 2010; **31**: 127,139 [DOI: 10.3969/j.issn.1003-4706.2010.02.036]
 - 35 **Dong GF**, Kang JL. Genetic analysis of 1273 cases with adverse pregnancy history in Guangzhou. *Zhongguo Yousheng Yu Yichuan Zazhi* 2018; **26**: 60-61
 - 36 **Zhang SH**, Xu YX, Fu D, Ju Y. Cytogenetic study of 5292 patients with adverse pregnancy history in Yangzhou area. *Zhongguo Yousheng Yu Yichuan Zazhi* 2017; **25**: 54-56
 - 37 **Hu L**, Li HX, Peng Y, Long ZG, Wen J, Wu LC. Retrospective analysis of cytogenetics in 1770 couples with spontaneous abortion. *Guoji shengzhi jianshang zazhi* 2014; **3**: 168-171
 - 38 **Zhao XG**, Song QC, Liu MX, Gao J. Cytogenetics of 455 genetic counselors in Daqing area. *Zhongguo Yousheng Yu Yichuan Zazhi* 2009; **17**: 42, 57
 - 39 **Zhang Z**, Ma YX, Zhao YS, Wu JL, Zhao H. Cytogenetics of 182 couples with history of spontaneous abortion. *Zhongguo Yousheng Yu Yichuan Zazhi* 2011; **06**: 45-46 [DOI: 10.3969/j.issn.1006-9534.2002.05.033]
 - 40 **Hu WJ**, Liu YP. Genetic analysis of 2643 exceptional perihemocytes. *Huaxi Yixue Zazhi* 2008; **5**: 1064-1065
 - 41 **Vasilevska M**, Ivanovska E, Kubelka Sabit K, Sukarova-Angelovska E, Dimeska G. The incidence and type of chromosomal translocations from prenatal diagnosis of 3800 patients in the republic of macedonia. *Balkan J Med Genet* 2013; **16**: 23-28 [PMID: 24778559 DOI: 10.2478/bjmg-2013-0027]
 - 42 **Flynn H**, Yan J, Saravelos SH, Li TC. Comparison of reproductive outcome, including the pattern of loss, between couples with chromosomal abnormalities and those with unexplained repeated miscarriages. *J Obstet Gynaecol Res* 2014; **40**: 109-116 [PMID: 24033546 DOI: 10.1111/jog.12133]
 - 43 **Tunç E**, Tanrıverdi N, Demirhan O, Süleymanova D, Çetinel N. Chromosomal analyses of 1510 couples who have experienced recurrent spontaneous abortions. *Reprod Biomed Online* 2016; **32**: 414-419 [PMID: 26874988 DOI: 10.1016/j.rbmo.2016.01.006]
 - 44 **Kochhar PK**, Ghosh P. Reproductive outcome of couples with recurrent miscarriage and balanced chromosomal abnormalities. *J Obstet Gynaecol Res* 2013; **39**: 113-120 [PMID: 22672580 DOI: 10.1111/j.1447-0756.2012.01905.x]
 - 45 **Makino T**, Tabuchi T, Nakada K, Iwasaki K, Tamura S, Iizuka R. Chromosomal analysis in Japanese couples with repeated spontaneous abortions. *Int J Fertil* 1990; **35**: 266-270 [PMID: 1980661]
 - 46 **Elkarhat Z**, Kindil Z, Zarouf L, Razoki L, Aboulfaraj J, Elbakay C, Nasserredine S, Nasser B, Barakat A, Rouba H. Chromosomal abnormalities in couples with recurrent spontaneous miscarriage: a 21-year retrospective study, a report of a novel insertion, and a literature review. *J Assist Reprod Genet* 2019; **36**: 499-507 [PMID: 30470960 DOI: 10.1007/s10815-018-1373-4]
 - 47 **Ghazaey S**, Keify F, Mirzaei F, Maleki M, Tootian S, Ahadian M, Abbaszadegan MR. Chromosomal analysis of couples with repeated spontaneous abortions in northeastern iran. *Int J Fertil Steril* 2015; **9**: 47-54 [DOI: 10.22074/ijfs.2015.4208]
 - 48 **De la Fuente-Cortés BE**, Cerda-Flores RM, Dávila-Rodríguez MI, García-Vielma C, De la Rosa Alvarado RM, Cortés-Gutiérrez EI. Chromosomal abnormalities and polymorphic variants in couples with repeated miscarriage in Mexico. *Reprod Biomed Online* 2009; **18**: 543-548 [DOI: 10.1016/S1472-6483(10)60132-0]
 - 49 **Goud TM**, Mohammed Al Harassi S, Khalfan Al Salmani K, Mohammed Al Busaidy S, Rajab A. Cytogenetic studies in couples with recurrent miscarriage in the Sultanate of Oman. *Reprod Biomed Online* 2009; **18**: 424-429 [DOI: 10.1016/S1472-6483(10)60104-6]
 - 50 **Awartani KA**, Al Shabibi MS. Description of cytogenetic abnormalities and the pregnancy outcomes of couples with recurrent pregnancy loss in a tertiary-care center in Saudi Arabia. *Saudi Med J* 2018; **39**: 239-242 [PMID: 29543300 DOI: 10.15537/smj.2018.3.21592]
 - 51 **Tóth A**, Gaál M, Böszö P, László J. Chromosome abnormalities in 118 couples with recurrent spontaneous abortions. *Gynecol Obstet Invest* 1984; **18**: 72-77 [PMID: 6479698 DOI: 10.1159/000299052]
 - 52 **Azim M**, Khan AH, Khilji ZL, Pal JA, Khurshid M. Chromosomal abnormalities as a cause of recurrent abortions: a hospital experience. *J Pak Med Assoc* 2003; **53**: 117
 - 53 **Sasiadek M**, Haus O, Lukasik-Majchrowska M, Slezak R, Paprocka-Borowicz M, Busza H, Plewa R, Bullo A, Jagielski J. [Cytogenetic analysis in couples with spontaneous abortions]. *Ginekolog Pol* 1997; **68**: 248-252 [PMID: 9480240 DOI: 10.4103/0256-4947.75785]
 - 54 **Pylyp LY**, Spinenko LO, Verhoglyad NV, Kashevarova OO, Zukin VD. Chromosomal abnormalities in patients with infertility. *Tsitologiya* 2015; **49**: 173-177 [DOI: 10.3103/S009545271503010X]
 - 55 **Ayed W**, Messaoudi I, Belghith Z, Hammami W, Chemkhi I, Abidli N, Guermani H, Obay R, Amouri A. Chromosomal abnormalities in 163 Tunisian couples with recurrent miscarriages. *Pan Afr Med J* 2017; **28**: 99 [PMID: 29255569 DOI: 10.11604/pamj.2017.28.99.11879]
 - 56 **Fortuny A**, Carrio A, Soler A, Cararach J, Fuster J, Salami C. Detection of balanced chromosome rearrangements in 445 couples with repeated abortion and cytogenetic prenatal testing in carriers. *Fertility and Sterility* 1988; **49**: 774-779 [DOI: 10.1016/S0015-0282(16)59882-3]



Published By Baishideng Publishing Group Inc
7041 Koll Center Parkway, Suite 160, Pleasanton, CA 94566, USA
Telephone: +1-925-2238242
E-mail: bpgoffice@wjgnet.com
Help Desk: <https://www.f6publishing.com/helpdesk>
<https://www.wjgnet.com>

