

World Journal of *Clinical Cases*

World J Clin Cases 2019 November 26; 7(22): 3683-3914





REVIEW

- 3683** Colorectal cancer: The epigenetic role of microbiome
Sabit H, Cevik E, Tombuloglu H

ORIGINAL ARTICLE

Case Control Study

- 3698** Human podocyte injury in the early course of hypertensive renal injury
Sun D, Wang JJ, Wang W, Wang J, Wang LN, Yao L, Sun YH, Li ZL

Retrospective Cohort Study

- 3711** Relationship between acute hypercarbia and hyperkalaemia during surgery
Weinberg L, Russell A, Mackley L, Dunnachie C, Meyerov J, Tan C, Li M, Hu R, Karalapillai D

Retrospective Study

- 3718** Surgical treatment of patients with severe non-flail chest rib fractures
Zhang JP, Sun L, Li WQ, Wang YY, Li XZ, Liu Y
- 3728** Super-selective arterial embolization in the control of acute lower gastrointestinal hemorrhage
Ly LS, Gu JT
- 3734** End-stage liver disease score and future liver remnant volume predict post-hepatectomy liver failure in hepatocellular carcinoma
Kong FH, Miao XY, Zou H, Xiong L, Wen Y, Chen B, Liu X, Zhou JJ

Observational Study

- 3742** Treatment of hemorrhoids: A survey of surgical practice in Australia and New Zealand
Fowler GE, Siddiqui J, Zahid A, Young CJ
- 3751** Relationship between homocysteine level and prognosis of elderly patients with acute ischemic stroke treated by thrombolysis with recombinant tissue plasminogen activator
Li J, Zhou F, Wu FX

CASE REPORT

- 3757** Cystic fibrosis transmembrane conductance regulator functional evaluations in a G542X+/- IVS8Tn:T7/9 patient with acute recurrent pancreatitis
Caldrer S, Bergamini G, Sandri A, Vercellone S, Rodella L, Cerofolini A, Tomba F, Catalano F, Frulloni L, Buffelli M, Tridello G, de Jonge H, Assael BM, Sorio C, Melotti P

- 3765** Ulcerated intussuscepted jejunal lipoma-uncommon cause of obscure gastrointestinal bleeding: A case report
Cuciureanu T, Huiban L, Chiriac S, Singeap AM, Danciu M, Mihai F, Stanciu C, Trifan A, Vlad N
- 3772** Ultrasonographic evaluation of the effect of extracorporeal shock wave therapy on calcific tendinopathy of the rectus femoris tendon: A case report
Lee CH, Oh MK, Yoo JI
- 3778** Contrast-enhanced computed tomography findings of a huge perianal epidermoid cyst: A case report
Sun PM, Yang HM, Zhao Y, Yang JW, Yan HF, Liu JX, Sun HW, Cui Y
- 3784** Iatrogenic crystalline lens injury during intravitreal injection of triamcinolone acetonide: A report of two cases
Su J, Zheng LJ, Liu XQ
- 3792** Sagliker syndrome: A case report of a rare manifestation of uncontrolled secondary hyperparathyroidism in chronic renal failure
Yu Y, Zhu CF, Fu X, Xu H
- 3800** Pre-eclampsia with new-onset systemic lupus erythematosus during pregnancy: A case report
Huang PZ, Du PY, Han C, Xia J, Wang C, Li J, Xue FX
- 3807** Unilateral congenital scrotal agenesis with ipsilateral cryptorchidism: A case report
Fang Y, Lin J, Wang WW, Qiu J, Xie Y, Sang LP, Mo JC, Luo JH, Wei JH
- 3812** Metastatic infection caused by hypervirulent *Klebsiella pneumonia* and co-infection with *Cryptococcus meningitis*: A case report
Shi YF, Wang YK, Wang YH, Liu H, Shi XH, Li XJ, Wu BQ
- 3821** Allergic fungal rhinosinusitis accompanied by allergic bronchopulmonary aspergillosis: A case report and literature review
Cheng KJ, Zhou ML, Liu YC, Zhou SH
- 3832** Invasive aspergillosis presenting as hilar masses with stenosis of bronchus: A case report
Su SS, Zhou Y, Xu HY, Zhou LP, Chen CS, Li YP
- 3838** Retropharyngeal abscess presenting as acute airway obstruction in a 66-year-old woman: A case report
Lin J, Wu XM, Feng JX, Chen MF
- 3844** Thoracoscopic segmentectomy assisted by three-dimensional computed tomography bronchography and angiography for lung cancer in a patient living with situs inversus totalis: A case report
Wu YJ, Bao Y, Wang YL
- 3851** Single-lung transplantation for pulmonary alveolar microlithiasis: A case report
Ren XY, Fang XM, Chen JY, Ding H, Wang Y, Lu Q, Ming JL, Zhou LJ, Chen HW

- 3859** Respiratory failure and macrophage activation syndrome as an onset of systemic lupus erythematosus: A case report
Sun J, Wang JW, Wang R, Zhang H, Sun J
- 3866** Diagnosis of gastric duplication cyst by positron emission tomography/computed tomography: A case report
Hu YB, Gui HW
- 3872** Peritoneal cancer after bilateral mastectomy, hysterectomy, and bilateral salpingo-oophorectomy with a poor prognosis: A case report and review of the literature
Ma YN, Bu HL, Jin CJ, Wang X, Zhang YZ, Zhang H
- 3881** Apatinib for treatment of a pseudomyxoma peritonei patient after surgical treatment and hyperthermic intraperitoneal chemotherapy: A case report
Huang R, Shi XL, Wang YF, Yang F, Wang TT, Peng CX
- 3887** Novel frameshift mutation causes early termination of the thyroxine-binding globulin protein and complete thyroxine-binding globulin deficiency in a Chinese family: A case report
Dang PP, Xiao WW, Shan ZY, Xi Y, Wang RR, Yu XH, Teng WP, Teng XC
- 3895** Diffuse large B-cell lymphoma arising from follicular lymphoma with warthin's tumor of the parotid gland - immunophenotypic and genetic features: A case report
Wang CS, Chu X, Yang D, Ren L, Meng NL, Lv XX, Yun T, Cao YS
- 3904** Exogenous endophthalmitis caused by *Enterococcus casseliflavus*: A case report
Bao QD, Liu TX, Xie M, Tian X

LETTER TO THE EDITOR

- 3912** Microbial transglutaminase should be considered as an environmental inducer of celiac disease
Lerner A, Matthias T

ABOUT COVER

Editorial Board Member of *World Journal of Clinical Cases*, Ridvan Hamid Alimehmeti, MD, PhD, Associate Professor, Lecturer, Surgeon, Department of Neuroscience, University of Medicine, Tirana 1000, Albania

AIMS AND SCOPE

The primary aim of *World Journal of Clinical Cases* (WJCC, *World J Clin Cases*) is to provide scholars and readers from various fields of clinical medicine with a platform to publish high-quality clinical research articles and communicate their research findings online.

WJCC mainly publishes articles reporting research results and findings obtained in the field of clinical medicine and covering a wide range of topics, including case control studies, retrospective cohort studies, retrospective studies, clinical trials studies, observational studies, prospective studies, randomized controlled trials, randomized clinical trials, systematic reviews, meta-analysis, and case reports.

INDEXING/ABSTRACTING

The WJCC is now indexed in PubMed, PubMed Central, Science Citation Index Expanded (also known as SciSearch®), and Journal Citation Reports/Science Edition. The 2019 Edition of Journal Citation Reports cites the 2018 impact factor for WJCC as 1.153 (5-year impact factor: N/A), ranking WJCC as 99 among 160 journals in Medicine, General and Internal (quartile in category Q3).

RESPONSIBLE EDITORS FOR THIS ISSUE

Responsible Electronic Editor: Ji-Hong Liu

Proofing Production Department Director: Yun-Xiaojuan Wu

NAME OF JOURNAL

World Journal of Clinical Cases

ISSN

ISSN 2307-8960 (online)

LAUNCH DATE

April 16, 2013

FREQUENCY

Semimonthly

EDITORS-IN-CHIEF

Dennis A Bloomfield, Bao-Gan Peng, Sandro Vento

EDITORIAL BOARD MEMBERS

<https://www.wjnet.com/2307-8960/editorialboard.htm>

EDITORIAL OFFICE

Jin-Lei Wang, Director

PUBLICATION DATE

November 26, 2019

COPYRIGHT

© 2019 Baishideng Publishing Group Inc

INSTRUCTIONS TO AUTHORS

<https://www.wjnet.com/bpg/gerinfo/204>

GUIDELINES FOR ETHICS DOCUMENTS

<https://www.wjnet.com/bpg/GerInfo/287>

GUIDELINES FOR NON-NATIVE SPEAKERS OF ENGLISH

<https://www.wjnet.com/bpg/gerinfo/240>

PUBLICATION MISCONDUCT

<https://www.wjnet.com/bpg/gerinfo/208>

ARTICLE PROCESSING CHARGE

<https://www.wjnet.com/bpg/gerinfo/242>

STEPS FOR SUBMITTING MANUSCRIPTS

<https://www.wjnet.com/bpg/GerInfo/239>

ONLINE SUBMISSION

<https://www.f6publishing.com>

Ultrasonographic evaluation of the effect of extracorporeal shock wave therapy on calcific tendinopathy of the rectus femoris tendon: A case report

Chang Han Lee, Min-Kyun Oh, Jun-Il Yoo

ORCID number: Chang Han Lee (0000-0001-8351-5226); Min-Kyun Oh (0000-0003-0258-6298); Jun-Il Yoo (0000-0002-3575-4123).

Author contributions: Lee CH and Yoo JI contributed equally to this work; Lee CH and Yoo JI designed research, performed research, contributed new reagents/analytic tools, analyzed data and wrote the paper; Oh MK revised the paper.

Informed consent statement:

Consent was obtained from patients for publication of this report.

Conflict-of-interest statement: All authors declare that there are no conflicts of interest involved.

CARE Checklist (2016) statement:

The authors have read the CARE Checklist (2016), and the manuscript was prepared and revised according to the CARE Checklist (2016).

Open-Access: This article is an open-access article which was selected by an in-house editor and fully peer-reviewed by external reviewers. It is distributed in accordance with the Creative Commons Attribution Non Commercial (CC BY-NC 4.0) license, which permits others to distribute, remix, adapt, build upon this work non-commercially, and license their derivative works on different terms, provided the original work is properly cited and the use is non-commercial. See: <http://creativecommons.org/licenses/by-nc/4.0/>

Chang Han Lee, Min-Kyun Oh, Department of Rehabilitation Medicine, Gyeongsang National University School of Medicine and Gyeongsang National University Hospital, Jinju 52727, South Korea

Jun-Il Yoo, Department of Orthopaedic Surgery, School of Medicine, Gyeongsang National University, 90 Chilamdong, Gyeongsangnam-do, Jinju 52727, South Korea

Corresponding author: Jun-Il Yoo, MD, Assistant Professor, Department of Orthopaedic Surgery, Gyeongsang National University Hospital, 90 Chilamdong, Gyeongsangnam-do, Jinju 52727, South Korea. furim@daum.net

Telephone: +82-55-7508688

Fax: +82-55-7540477

Abstract

BACKGROUND

Calcific tendinopathy denotes calcific deposits in a specific tendon. It is also known as calcifying tendinitis, calcifying periarticularitis, or periarticular apatite deposition disease. Recently, extracorporeal shock wave therapy (ESWT) has been reported to be effective in relieving and treating pain in calcific tendinopathy.

CASE SUMMARY

A 36-year-old female patient suffered from left hip joint pain for six months. The pain was increased during abduction of the hip, waking, and jumping. B-mode ultrasonography was performed by a physiatrist with an L12-5 linear transducer. A single session of ESWT was given in the marking area under ultrasound guidance at 4 Hz, 2500 shots with intensity of stimulation using energy of 0.1 mJ/mm². The hip pain of the patient slowly decreased within 4 wk after starting the ESWT. After six weeks of ESWT, her hip pain was completely resolved. However, the size of calcification showed almost no reduction in simple radiography at the final follow-up.

CONCLUSION

Ultrasonography is a very good modality not only for diagnosing calcified tendinitis by classical appearance, but also for evaluating the effect of ESWT during the follow-up period.

Key words: Rectus femoris; Calcific tendinopathy; Extracorporeal shock wave therapy;

Manuscript source: Unsolicited manuscript

Received: August 11, 2019

Peer-review started: August 11, 2019

First decision: September 9, 2019

Revised: September 19, 2019

Accepted: October 15, 2019

Article in press: October 15, 2019

Published online: November 26, 2019

P-Reviewer: Bazeed MF, Gao BL, Valek V

S-Editor: Dou Y

L-Editor: A

E-Editor: Liu MY



Ultrasonography; Hip; Joint; Case report

©The Author(s) 2019. Published by Baishideng Publishing Group Inc. All rights reserved.

Core tip: As a feature of ultrasonography, high resolution shows the presence of deposits and defines their locations in the tendon, plus their size and texture. This technique enables staging of the deposits by correlation of shadow cones. In the resting phase, the deposits appear hyperechoic and arc shaped, whereas they appear non-arc shaped (fragmented/punctate and cystic) in the resolving phase. These appearances can also be correlated with the symptomatic and asymptomatic phases of the disease.

Citation: Lee CH, Oh MK, Yoo JI. Ultrasonographic evaluation of the effect of extracorporeal shock wave therapy on calcific tendinopathy of the rectus femoris tendon: A case report.

World J Clin Cases 2019; 7(22): 3772-3777

URL: <https://www.wjnet.com/2307-8960/full/v7/i22/3772.htm>

DOI: <https://dx.doi.org/10.12998/wjcc.v7.i22.3772>

INTRODUCTION

Calcific tendinopathy denotes calcific deposits in a specific tendon. It is also known as calcifying tendinitis, calcifying periarticularitis, or periarticular apatite deposition disease^[1,2]. Causes of calcific tendinopathy have not been clearly clarified yet. According to previous studies, repeated use of attachment site and focal ischemia, cartilage degeneration, and calcium deposition at the tendon attachment site are main causes of calcific tendinopathy. In addition, severe acute or chronic pain frequently occurs due to degradation of calcium deposits. To treat calcific tendinopathy, various methods have been used, including administration of nonsteroidal antiinflammatory drugs (NSAID) to the calcified lesion, needle aspiration, and extracorporeal shock wave therapy (ESWT). However, surgical treatment is rarely necessary.

Recently, ESWT has been reported to be effective in relieving and treating pain in calcific tendinopathy^[3]. Investigating treatment effects is usually based on clinical measurement and typical findings of plain radiography, locating calcific depositions in the tendon or bursa^[4]. However, plain radiography can lead to mistakes without additional check-up with other diagnostic tools such as computed tomography (CT) or magnetic resonance image (MRI). Recently, a few studies have used ultrasonography to determine the effect of treatment on calcific tendinopathy^[5,6]. However, there are only two reports of ESWT for treating calcified tendinopathy around hip joint compared to that for treating calcified tendinopathy of rotator cuff or Achilles tendon^[1,2].

To the best of our knowledge, no case report has described the usefulness of ultrasonography in the treatment of calcific tendinopathy around rectus femoris tendon using ESWT. Herein, we report a case of calcific tendinopathy of rectus femoris successfully treated with ESWT. Our case shows the importance of using ultrasonography to determine the effect of treatment when simple radiography does not reveal difference of calcific deposit over the rectus femoris tendon.

CASE PRESENTATION

Chief complaints

A 36-year-old female patient suffered from left hip joint pain for six months. The pain was increased during abduction of the hip, waking, and jumping.

History of present illness

Initially, the pain was treated with acetaminophen, with some success. Symptoms subsided the following day but recurred quite severely on the third day, requiring admission to a community hospital for treatment. The pain was non-radiating and was exacerbated with any movement of the left hip. There was no fever, chills, preceding systemic illness, or infection.

Since then, there was no pain improvement even after 6 mo of continuous treatment.

History of past illness

No other health conditions are reported.

Personal and family history

She had no specific history of trauma or underlying disease.

Physical examination upon admission

On physical examination, limitation of range of motion was revealed due to pain. No evidence of infection was observed. There was evidence of infection such as fever, heating sensation, redness, fluctuation, and swelling.

Laboratory examinations

All routine laboratory findings were within normal limits.

Imaging examinations

Simple radiograph including anteroposterior view and lateral view revealed nodular-shaped deposits at the anterior inferior iliac spine site as the origin of rectus femoris muscle (Figure 1). For further evaluation and ESWT, B-mode ultrasonography was performed by a physiatrist with expertise in using a Philips iU 22 ultrasound system (Philips Health Care, Andover, MA, United States) with an L12-5 linear transducer. The patient was asked to lie in a supine position on the examination table while her knee was straightened and the ankle was relaxed. Longitudinal and transverse ultrasonographic images of the calcification of the left rectus femoris were evaluated before ESWT (Figure 2). Dornier Aries (Dornier MedTech, Wessling, Germany) was used for ESWT.

FINAL DIAGNOSIS

Calcific tendinitis of rectus femoris muscle.

TREATMENT

We marked the calcification with a pen to accurately deliver shock wave. Pressure pulses were focused at the marking area that was identified through the ultrasound. A single session of ESWT was given in the marking area under ultrasound guidance at 4 Hz, 2500 shots with intensity of stimulation using energy of 0.1 mJ/mm². ESWT was performed a total of six times at an interval of 3-4 d. The patient's posture was the same as that of the ultrasound scan. Complementary NSAIDs (Celecoxib) were started.

OUTCOME AND FOLLOW-UP

The hip pain of patient slowly decreased within four weeks after starting the ESWT. After 6 wk, her hip pain was completely resolved. However, the size of calcification showed almost no reduction in simple radiography at the final follow-up (Figure 3). We performed ultrasonography, showing that calcium deposit was decreased, with huge calcification disintegrated into smaller pieces on transverse image (Figure 4).

DISCUSSION

Several cases of calcific tendinopathy of the rectus femoris have been reported^[7]. However, there is only one report of treatment using ESWT of calcified tendinopathy of the rectus femoris^[1]. In that report, ESWT was administered in a total of three sessions at 7-d interval. The calcification was disintegrated in a month after ESWT and the pain was resolved completely at final 15-mo follow-up with complete resorption of calcific material in radiography. Calcific tendinopathy is usually a self-limiting condition. In light of this, improved pain after 15 mo can be caused by the natural course of pain, not by ESWT. In our case, ESWT was performed a total of six times. After six weeks of ESWT, calcium deposit showed almost no change in the radiography. However, calcium deposit was decreased and fragmented on ultrasonographic findings and her hip pain was completely resolved.

Conventional radiography is the technique used most frequently for the detection of calcifications in calcific tendinopathy. However, plain radiography can lead to

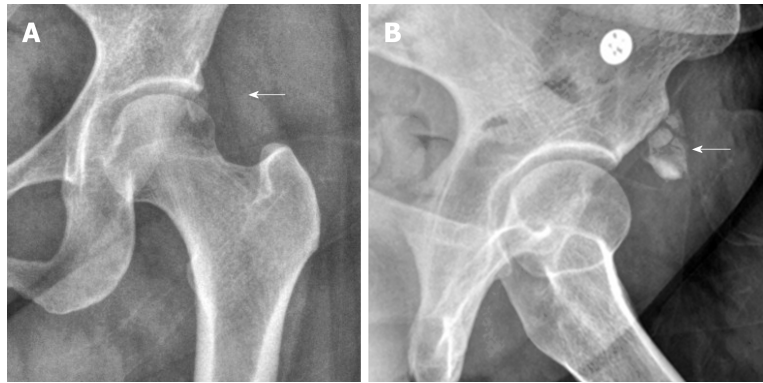


Figure 1 An anteroposterior radiography of the left hip. A: An anteroposterior radiography of the left hip showing an amorphous calcification (white arrow) adjacent to the anterior inferior iliac spine which is the attachment site of the rectus tendon, suggesting calcific tendinopathy of rectus femoris; B: The lesion (white arrow) was more clearly defined at the lateral view.

misdiagnosis without the use of additional diagnostic tools because of the limitation of two-dimensional projections^[8]. CT allows the best visualization and localization in calcific tendinopathy. It is rarely used for the assessment of non-traumatic joint^[9].

If possible, MRI can be an useful tool to diagnosis calcific tendinopathy as it confirms the presence of inflammation associated with the acute symptomatic phase of calcific tendinopathy excluding other etiologies of pain^[10]. Although these diagnostic tools could be used for additional examination, they are not appropriate as screening test because they are associated with high radiation and excessive cost. On the other hand, ultrasonography is useful for evaluating of calcific tendinopathy. Especially, the real-time nature of ultrasonography allows its use for both diagnostic and therapeutic purpose. In our patient, a huge calcific nodule disintegrated and showed reduction in size after ESWT. Even if it was not real-time, ESWT was exactly applied to the calcified nodule by marking the calcification with a pen under ultrasound guidance. As a feature of ultrasonography, high resolution shows the presence of deposits and defines their locations in the tendon, plus their size and texture. This technique enables staging of deposits by correlation of shadow cones. In the resting phase, deposits appear hyperechoic and arc shaped, whereas they appear non-arc shaped (fragmented/punctate and cystic) in the resolving phase. These appearances can also be correlated with symptomatic and asymptomatic phases of the disease. In our study, we founded that larger and more arc shaped calcification changed into smaller fragmented calcification after ESWT through ultrasonography.

CONCLUSION

In conclusion, ultrasonography is a very good modality not only for diagnosing calcified tendinitis based on classical appearance, but also for evaluating the effect of ESWT during follow-up period.

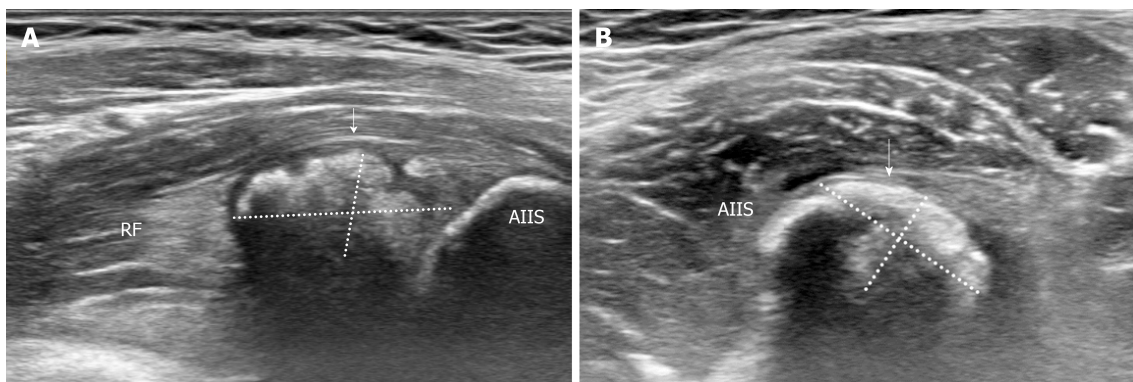


Figure 2 Longitudinal ultrasonographic image. A: Longitudinal ultrasonographic image showing a solid calcific nodule (white arrow) at 1.70 cm × 0.85 cm in size adjacent to the insertion site of the rectus femoris tendon; B: An arc shaped lesion (white arrow) of 1.43 cm × 0.94 cm was also defined at the transverse ultrasonographic image. AIIS: Anterior inferior iliac spine; RF: Rectus femoris.

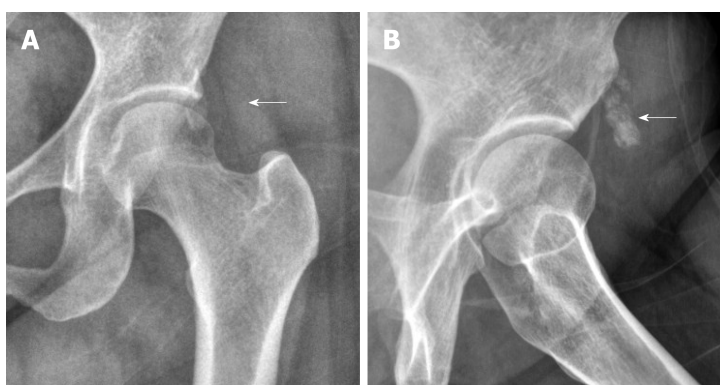


Figure 3 Simple radiography. A: The size of calcification was almost not reduced in simple radiography at the final follow-up; B: The lesion (white arrow) was still clearly defined at lateral view.

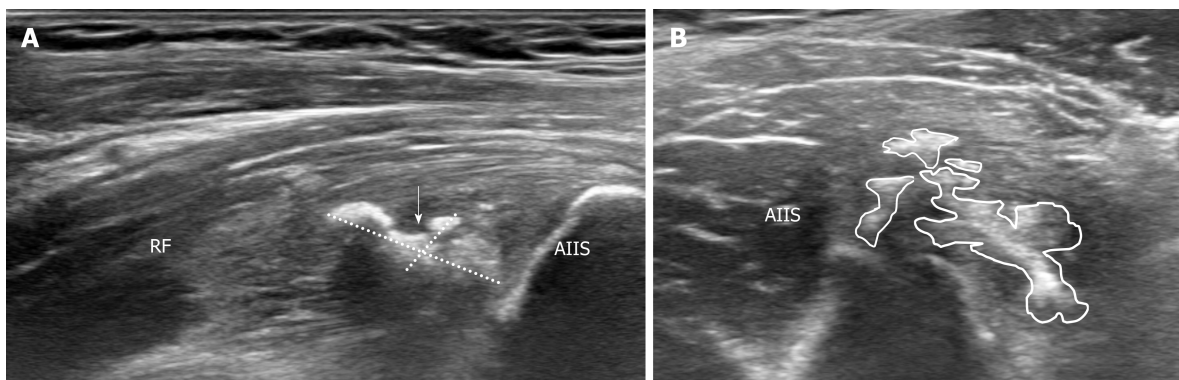


Figure 4 Ultrasonographic image of rectus femoris calcification after extracorporeal shock wave therapy. A: The calcium deposit was decreased (1.42 cm × 0.61 cm) on longitudinal image; B: Huge calcification disintegrates into smaller pieces on transverse image. AIIS: Anterior inferior iliac spine; RF: Rectus femoris.

REFERENCES

1. Oh KJ, Yoon JR, Shin DS, Yang JH. Extracorporeal shock wave therapy for calcific tendinitis at unusual sites around the hip. *Orthopedics* 2010; **33**: 769 [PMID: 20954651 DOI: 10.3928/01477447-20100826-30]
2. Durst HB, Kuster MS. [Extracorporeal shock-wave lithotripsy for the treatment of calcific tendonitis of the gluteus maximus tendon]. *Z Orthop Ihre Grenzgeb* 2006; **144**: 516-518 [PMID: 16991070 DOI: 10.1055/s-2006-942238]
3. Speed CA, Nichols D, Richards C, Humphreys H, Wies JT, Burnet S, Hazleman BL. Extracorporeal shock wave therapy for lateral epicondylitis--a double blind randomised controlled trial. *J Orthop Res* 2002; **20**: 895-898 [PMID: 12382950 DOI: 10.1016/S0736-0266(02)00013-X]
4. Chow HY, Recht MP, Schils J, Calabrese LH. Acute calcific tendinitis of the hip: case report with

- magnetic resonance imaging findings. *Arthritis Rheum* 1997; **40**: 974-977 [PMID: [9153562](#) DOI: [10.1002/art.1780400528](#)]
- 5 **Jo H**, Kim G, Baek S, Park HW. Calcific Tendinopathy of the Gluteus Medius Mimicking Lumbar Radicular Pain Successfully Treated With Barbotage: A Case Report. *Ann Rehabil Med* 2016; **40**: 368-372 [PMID: [27152290](#) DOI: [10.5535/arm.2016.40.2.368](#)]
- 6 **Hong MJ**, Kim YD, Park JK, Kang TU. Successful Treatment of Rectus Femoris Calcification with Ultrasound-guided Injection: A Case Report. *Korean J Pain* 2015; **28**: 52-56 [PMID: [25589947](#) DOI: [10.3344/kjp.2015.28.1.52](#)]
- 7 **IKobayashi H**, Kaneko H, Homma Y, Baba T, Kaneko K. Acute Calcific Tendinitis of the Rectus Femoris: A Case Series. *J Orthop Case Rep* 2015; **5**: 32-34 [PMID: [27299063](#) DOI: [10.13107/jocr.2250-0685.301](#)]
- 8 **Farin PU**, Räsänen H, Jaroma H, Harju A. Rotator cuff calcifications: treatment with ultrasound-guided percutaneous needle aspiration and lavage. *Skeletal Radiol* 1996; **25**: 551-554 [PMID: [8865489](#) DOI: [10.1007/s002560050133](#)]
- 9 **Farin PU**. Consistency of rotator-cuff calcifications. Observations on plain radiography, sonography, computed tomography, and at needle treatment. *Invest Radiol* 1996; **31**: 300-304 [PMID: [8724130](#) DOI: [10.1097/00004424-199605000-00010](#)]
- 10 **Holt PD**, Keats TE. Calcific tendinitis: a review of the usual and unusual. *Skeletal Radiol* 1993; **22**: 1-9 [PMID: [8430339](#) DOI: [10.1007/bf00191518](#)]



Published By Baishideng Publishing Group Inc
7041 Koll Center Parkway, Suite 160, Pleasanton, CA 94566, USA
Telephone: +1-925-2238242
E-mail: bpgoffice@wjgnet.com
Help Desk: <https://www.f6publishing.com/helpdesk>
<https://www.wjgnet.com>

