

World Journal of *Clinical Cases*

World J Clin Cases 2019 December 6; 7(23): 3915-4171



**REVIEW**

- 3915** Overview of organic anion transporters and organic anion transporter polypeptides and their roles in the liver
Li TT, An JX, Xu JY, Tuo BG

ORIGINAL ARTICLE**Observational Study**

- 3934** Value of early diagnosis of sepsis complicated with acute kidney injury by renal contrast-enhanced ultrasound
Wang XY, Pang YP, Jiang T, Wang S, Li JT, Shi BM, Yu C
- 3945** Value of elastography point quantification in improving the diagnostic accuracy of early diabetic kidney disease
Liu QY, Duan Q, Fu XH, Fu LQ, Xia HW, Wan YL
- 3957** Resection of recurrent third branchial cleft fistulas assisted by flexible pharyngotomy
Ding XQ, Zhu X, Li L, Feng X, Huang ZC
- 3964** Therapeutic efficacy of acupuncture combined with neuromuscular joint facilitation in treatment of hemiplegic shoulder pain
Wei YH, Du DC, Jiang K
- 3971** Comparison of intra-articular injection of parecoxib *vs* oral administration of celecoxib for the clinical efficacy in the treatment of early knee osteoarthritis
Lu L, Xie Y, Gan K, Huang XW

Retrospective Study

- 3980** Celiomesenteric trunk: New classification based on multidetector computed tomography angiographic findings and probable embryological mechanisms
Tang W, Shi J, Kuang LQ, Tang SY, Wang Y

Prospective Study

- 3990** Interaction of arylsulfatases A and B with maspin: A possible explanation for dysregulation of tumor cell metabolism and invasive potential of colorectal cancer
Kovacs Z, Jung I, Szalman K, Baniás L, Bara TJ, Gurzu S

CASE REPORT

- 4004** Recuperation of severe tumoral calcinosis in a dialysis patient: A case report
Westermann L, Isbell LK, Breitenfeldt MK, Arnold F, Röthele E, Schneider J, Widmeier E

- 4011** Robotic wedge resection of a rare gastric perivascular epithelioid cell tumor: A case report
Marano A, Maione F, Woo Y, Pellegrino L, Geretto P, Sasia D, Fortunato M, Orcioni GF, Priotto R, Fasoli R, Borghi F
- 4020** Primary parahiatal hernias: A case report and review of the literature
Preda SD, Pătrașcu Ș, Ungureanu BS, Cristian D, Bințișan V, Nica CM, Calu V, Strâmbu V, Sapalidis K, Șurlin VM
- 4029** Diagnosis of Laron syndrome using monoplex-polymerase chain reaction technology with a whole-genome amplification template: A case report
Neumann A, Alcántara-Ortigoza MÁ, González-del Ángel A, Camargo-Diaz F, López-Bayghen E
- 4036** *In-vitro* proliferation assay with recycled ascitic cancer cells in malignant pleural mesothelioma: A case report
Anayama T, Taguchi M, Tatenuma T, Okada H, Miyazaki R, Hirohashi K, Kume M, Matsusaki K, Orihashi K
- 4044** Distant metastasis in choroidal melanoma with spontaneous corneal perforation and intratumoral calcification: A case report
Wang TW, Liu HW, Bee YS
- 4052** Secondary Parkinson disease caused by breast cancer during pregnancy: A case report
Li L
- 4057** Pulmonary embolism and deep vein thrombosis caused by nitrous oxide abuse: A case report
Sun W, Liao JP, Hu Y, Zhang W, Ma J, Wang GF
- 4063** Micronodular thymic tumor with lymphoid stroma: A case report and review of the literature
Wang B, Li K, Song QK, Wang XH, Yang L, Zhang HL, Zhong DR
- 4075** Diffuse large B cell lymphoma with bilateral adrenal and hypothalamic involvement: A case report and literature review
An P, Chen K, Yang GQ, Dou JT, Chen YL, Jin XY, Wang XL, Mu YM, Wang QS
- 4084** Urethral pressure profilometry in artificial urinary sphincter implantation: A case report
Meng LF, Liu XD, Wang M, Zhang W, Zhang YG
- 4091** Hydroxyurea-induced cutaneous squamous cell carcinoma: A case report
Xu Y, Liu J
- 4098** Recurrent hypotension induced by sacubitril/valsartan in cardiomyopathy secondary to Duchenne muscular dystrophy: A case report
Li JM, Chen H
- 4106** Complete duodenal obstruction induced by groove pancreatitis: A case report
Wang YL, Tong CH, Yu JH, Chen ZL, Fu H, Yang JH, Zhu X, Lu BC

- 4111** Radiological aspects of giant hepatocellular adenoma of the left liver: A case report
Zheng LP, Hu CD, Wang J, Chen XJ, Shen YY
- 4119** Mixed serous-neuroendocrine neoplasm of the pancreas: A case report and review of the literature
Xu YM, Li ZW, Wu HY, Fan XS, Sun Q
- 4130** Rigid esophagoscopy combined with angle endoscopy for treatment of superior mediastinal foreign bodies penetrating into the esophagus caused by neck trauma: A case report
Wang D, Gao CB
- 4137** Left armpit subcutaneous metastasis of gastric cancer: A case report
He FJ, Zhang P, Wang MJ, Chen Y, Zhuang W
- 4144** Bouveret syndrome: A case report
Wang F, Du ZQ, Chen YL, Chen TM, Wang Y, Zhou XR
- 4150** Fatal complications in a patient with severe multi-space infections in the oral and maxillofacial head and neck regions: A case report
Dai TG, Ran HB, Qiu YX, Xu B, Cheng JQ, Liu YK
- 4157** Management of massive fistula bleeding after endoscopic ultrasound-guided pancreatic pseudocyst drainage using hemostatic forceps: A case report
Ge N, Sun SY
- 4163** Pure squamous cell carcinoma of the gallbladder locally invading the liver and abdominal cavity: A case report and review of the literature
Jin S, Zhang L, Wei YF, Zhang HJ, Wang CY, Zou H, Hu JM, Jiang JF, Pang LJ

ABOUT COVER

Editorial Board Member of *World Journal of Clinical Cases*, Consolato M Sergi, FRCP (C), MD, PhD, Professor, Department of Lab Medicine and Pathology, University of Alberta, Edmonton T6G 2B7, Canada

AIMS AND SCOPE

The primary aim of *World Journal of Clinical Cases* (WJCC, *World J Clin Cases*) is to provide scholars and readers from various fields of clinical medicine with a platform to publish high-quality clinical research articles and communicate their research findings online.

WJCC mainly publishes articles reporting research results and findings obtained in the field of clinical medicine and covering a wide range of topics, including case control studies, retrospective cohort studies, retrospective studies, clinical trials studies, observational studies, prospective studies, randomized controlled trials, randomized clinical trials, systematic reviews, meta-analysis, and case reports.

INDEXING/ABSTRACTING

The WJCC is now indexed in PubMed, PubMed Central, Science Citation Index Expanded (also known as SciSearch®), and Journal Citation Reports/Science Edition. The 2019 Edition of Journal Citation Reports cites the 2018 impact factor for WJCC as 1.153 (5-year impact factor: N/A), ranking WJCC as 99 among 160 journals in Medicine, General and Internal (quartile in category Q3).

RESPONSIBLE EDITORS FOR THIS ISSUE

Responsible Electronic Editor: *Yan-Xia Xing*

Proofing Production Department Director: *Xiang Li*

NAME OF JOURNAL

World Journal of Clinical Cases

ISSN

ISSN 2307-8960 (online)

LAUNCH DATE

April 16, 2013

FREQUENCY

Semimonthly

EDITORS-IN-CHIEF

Dennis A Bloomfield, Bao-Gan Peng, Sandro Vento

EDITORIAL BOARD MEMBERS

<https://www.wjnet.com/2307-8960/editorialboard.htm>

EDITORIAL OFFICE

Jin-Lei Wang, Director

PUBLICATION DATE

December 6, 2019

COPYRIGHT

© 2019 Baishideng Publishing Group Inc

INSTRUCTIONS TO AUTHORS

<https://www.wjnet.com/bpg/gerinfo/204>

GUIDELINES FOR ETHICS DOCUMENTS

<https://www.wjnet.com/bpg/GerInfo/287>

GUIDELINES FOR NON-NATIVE SPEAKERS OF ENGLISH

<https://www.wjnet.com/bpg/gerinfo/240>

PUBLICATION MISCONDUCT

<https://www.wjnet.com/bpg/gerinfo/208>

ARTICLE PROCESSING CHARGE

<https://www.wjnet.com/bpg/gerinfo/242>

STEPS FOR SUBMITTING MANUSCRIPTS

<https://www.wjnet.com/bpg/GerInfo/239>

ONLINE SUBMISSION

<https://www.f6publishing.com>

Fatal complications in a patient with severe multi-space infections in the oral and maxillofacial head and neck regions: A case report

Tian-Guo Dai, Hong-Bing Ran, Yin-Xiu Qiu, Bo Xu, Jin-Qiang Cheng, Ying-Kai Liu

ORCID number: Tian-Guo Dai (0000-0002-4183-8382); Hong-Bing Ran (0000-0003-0828-1516); Yin-Xiu Qiu (0000-0003-1715-6901); Bo Xu (0000-0001-7760-0707); Jin-Qiang Cheng (0000-0003-2312-4156); Ying-Kai Liu (0000-0001-7894-1300).

Author contributions: Dai TG, Xu B, Cheng JQ and Liu YK participated in patient management and surgery; Ran HB was the director of our department who decided on the patient's treatment plan; Dai TG and Qiu YX wrote the paper.

Informed consent statement: Consent was obtained from the patient.

Conflict-of-interest statement: No conflicts of interest.

CARE Checklist (2016) statement: The authors wrote the manuscript according to the requirements of the CARE Checklist.

Open-Access: This article is an open-access article which was selected by an in-house editor and fully peer-reviewed by external reviewers. It is distributed in accordance with the Creative Commons Attribution Non Commercial (CC BY-NC 4.0) license, which permits others to distribute, remix, adapt, build upon this work non-commercially, and license their derivative works on different terms, provided the original work is properly cited and the use is non-commercial. See: <http://creativecommons.org/licenses/by-nc/4.0/>

Manuscript source: Unsolicited

Tian-Guo Dai, Hong-Bing Ran, Bo Xu, Jin-Qiang Cheng, Ying-Kai Liu, Department of Oral and Maxillofacial Surgery, Central Hospital of Panzhihua City, Panzhihua 617067, Sichuan Province, China

Yin-Xiu Qiu, Department of Otolaryngology Head and Neck Surgery, Central Hospital of Panzhihua City, Panzhihua 617067, Sichuan Province, China

Corresponding author: Tian-Guo Dai, DDS, MD, Surgeon, Surgical Oncologist, Teacher, Department of Oral and Maxillofacial Surgery, Central Hospital of Panzhihua City, 34 Yikang Street, Panzhihua 617067, Sichuan Province, China. paradisidai@163.com
Telephone: +86-812-2238164

Abstract

BACKGROUND

Odontogenic infection is one of the common infectious diseases in oral and maxillofacial head and neck regions. Clinically, if early odontogenic infections such as acute periapical periodontitis, alveolar abscess, and pericoronitis of wisdom teeth are not treated timely, effectively and correctly, the infected tissue may spread up to the skull and brain, down to the thoracic cavity, abdominal cavity and other areas through the natural potential fascial space in the oral and maxillofacial head and neck. Severe multi-space infections are formed and can eventually lead to life-threatening complications (LTCs), such as intracranial infection, pleural effusion, empyema, sepsis and even death.

CASE SUMMARY

We report a rare case of death in a 41-year-old man with severe odontogenic multi-space infections in the oral and maxillofacial head and neck regions. One week before admission, due to pain in the right lower posterior teeth, the patient placed a cigarette butt dipped in the pesticide "Miehailin" into the "dental cavity" to relieve the pain. Within a week, the infection gradually spread bilaterally to the floor of the mouth, submandibular space, neck, chest, waist, back, temporal and other areas. The patient had difficulty breathing, swallowing and eating, and was transferred to our hospital as an emergency admission. Following admission, oral and maxillofacial surgeons immediately organized consultations with doctors in otolaryngology, thoracic surgery, general surgery, hematology, anesthesia and the intensive care unit to assist with treatment. The patient was treated with the highest level of antibiotics (vancomycin) and extensive abscess incision and drainage in the oral, maxillofacial, head and neck, chest and back regions. Unfortunately, the patient died of septic shock and multiple organ failure on the third day after admission.

manuscript

Received: August 8, 2019

Peer-review started: August 8, 2019

First decision: September 23, 2019

Revised: October 24, 2019

Accepted: November 14, 2019

Article in press: November 14, 2019

Published online: December 6, 2019

P-Reviewer: Abd-Elsalam S, Monti M

S-Editor: Wang JL

L-Editor: Webster JR

E-Editor: Qi LL


CONCLUSION

Odontogenic infection can cause serious multi-space infections in the oral and maxillofacial head and neck regions, which can result in multiple LTCs. The management and treatment of LTCs such as multi-space infections should be multidisciplinary led by oral and maxillofacial surgeons.

Key words: Odontogenic infection; Multi-space infections; Complication; Oral; Maxillofacial; Head and neck; Case report

©The Author(s) 2019. Published by Baishideng Publishing Group Inc. All rights reserved.

Core tip: As reported in this article, despite current medical advances, when a patient has fatal life-threatening complications, the risk of death is high. Prevention of early odontogenic diseases is more meaningful than the treatment of late odontogenic multi-space infections. Furthermore, it is also very important to raise awareness of oral health care in remote mountainous areas of China.

Citation: Dai TG, Ran HB, Qiu YX, Xu B, Cheng JQ, Liu YK. Fatal complications in a patient with severe multi-space infections in the oral and maxillofacial head and neck regions: A case report. *World J Clin Cases* 2019; 7(23): 4150-4156

URL: <https://www.wjcn.com/2307-8960/full/v7/i23/4150.htm>

DOI: <https://dx.doi.org/10.12998/wjcc.v7.i23.4150>

INTRODUCTION

Odontogenic infections such as acute periapical periodontitis, alveolar abscess, and pericoronitis of wisdom teeth are common infectious diseases in the oral and maxillofacial regions. Clinically, if these diseases are not treated timely, effectively and correctly in the early stage, the infected tissue may spread up to the skull and brain, down to the thoracic cavity, abdominal cavity and back through the natural potential fascial space in the oral and maxillofacial head and neck regions^[1]. Severe multi-space infections are formed, which can eventually lead to life-threatening complications (LTCs) such as intracranial infection, pleural effusion, empyema, sepsis and even death^[2]. When a patient develops LTCs, treatment becomes very complicated, the outcome is poor and the mortality rate is high^[3]. Nowadays, the occurrence of serious LTCs is less frequent due to rational use of antibiotics and early treatment of odontogenic diseases. Nevertheless, it is still difficult to predict the development of severe odontogenic multi-space infections in the oral and maxillofacial head and neck regions. We report a patient with odontogenic infection who was not effectively treated in the initial stage, and consequently developed severe multi-space infections in the oral, maxillofacial, head and neck, chest and back, mediastinum and posterior abdominal wall regions, and subsequently died of septic shock and acute multiple organ failure.

CASE PRESENTATION

Chief complaints

A 41-year-old man presented with pain in the right lower posterior teeth, followed by swelling and pain in the oral and maxillofacial head and neck regions for 7 d, and difficulty in breathing and swallowing for 2 d.

History of present illness

One week before admission, due to pain in the right lower posterior teeth, the patient placed a cigarette butt dipped in the pesticide "Miehailin" into the "dental cavity" to relieve the pain. However, two days later, there was no significant improvement in dental pain and he visited a local community clinic where the doctors removed the cigarette butt and the patient received an infusion of anti-inflammatory drugs for 4 d. However, the odontogenic infections gradually became aggravated, and spread bilaterally to the floor of the mouth, submandibular space, neck, chest, waist, back, temporal and other areas. The patient also began to have difficulty in breathing,

swallowing and eating. Due to these complications, the patient was transferred to our hospital for follow-up treatment as an emergency admission. Since the onset of illness, he had been mentally exhausted, with a poor diet, poor sleep, and weight loss of approximately 2.5 kg.

History of past illness

Healthy, with no specific diseases.

Personal and family history

None.

Physical examination upon admission

Physical examination showed that the patient had an acutely painful face, extensive swelling and pneumatosis in the bilateral temporal, oral, maxillofacial, neck, chest, waist and back regions, combined with skin redness and high temperature. The submandibular space and neck regions pulsated when touched. Puncture revealed purulent fluid which was black, thin, with bubbles and had a foul odor. When the patient was admitted to hospital, mouth opening was less than 1 cm; therefore, the tooth lesion could not be examined properly.

Laboratory examinations

Laboratory examination results on emergency admission were as follows: leukocyte count was $13.53 \times 10^9/L$, neutrophil ratio was 88.40%, hypersensitive C-reactive protein was $> 180 \text{ mg/L}$, and procalcitonin was 9.8 ng/mL . Electrolyte results were: potassium was 5.65 mmol/L , sodium was 136.4 mmol/L , chlorine was 101.9 mmol/L , calcium was 1.91 mmol/L , and magnesium was 0.93 mmol/L . Liver and kidney function test results were as follows: alanine aminotransferase was 19 U/L , glutamic oxaloacetic aminotransferase was 23 U/L , creatinine was $94 \text{ }\mu\text{mol/L}$, and urea was 19.1 mmol/L . The platelet count was $41.0 \times 10^9/L$ and the D-dimer level was 1184 ng/mL . The results of blood culture indicated infection with *Streptococcus viridans*. Drug sensitivity testing indicated that the organism was sensitive to penicillin antibiotics.

Imaging examinations

Computed tomography scans of the maxillofacial, neck and chest regions showed extensive swelling and pneumatosis in soft tissues bilaterally in the oral, maxillofacial, temporal, cervical, parapharyngeal space, chest, back, mediastinum and posterior abdominal wall regions (Figures 1 and 2). The upper respiratory tract was narrowed slightly and bilateral lung pneumothorax was observed. A small amount of effusion was seen bilaterally in the pleura and pericardium (Figure 3A). Lung pneumothorax was more serious on the left side and the compression ratio was approximately 20%-30% (Figure 3B). Pulmonary infection was seen in both lungs, particularly in the left lung.

FINAL DIAGNOSIS

Initial diagnosis on admission was severe multi-space infections bilaterally in the oral and maxillofacial head and neck regions; secondary infections in the thorax, back and waist; mediastinal abscess; bilateral pneumothorax; bilateral pulmonary infection; purulent pleural effusion; pericardial effusion; secondary thrombocytopenia.

TREATMENT

Immediately after admission, the patient was transferred to the intensive care unit (ICU) for specialized intensive care.

Oral and maxillofacial surgeons immediately organized consultations and discussion of treatment plans with doctors from otolaryngology, thoracic surgery, general surgery, hematology, anesthesiology and ICU.

Oral and maxillofacial surgeons were responsible for extensive abscess incision and drainage in the oral and maxillofacial head and neck regions under emergency general anesthesia. Thoracic surgeons were responsible for thoracic and pericardial puncture, catheter drainage and pneumothorax management. General surgeons were responsible for the management of back and waist infections. Otolaryngologists and anesthesiologists were responsible for anesthesia and respiratory management. The hematologist was responsible for platelets and blood transfusion. ICU doctors were responsible for intensive care, antimicrobial administration (Norvancomycin

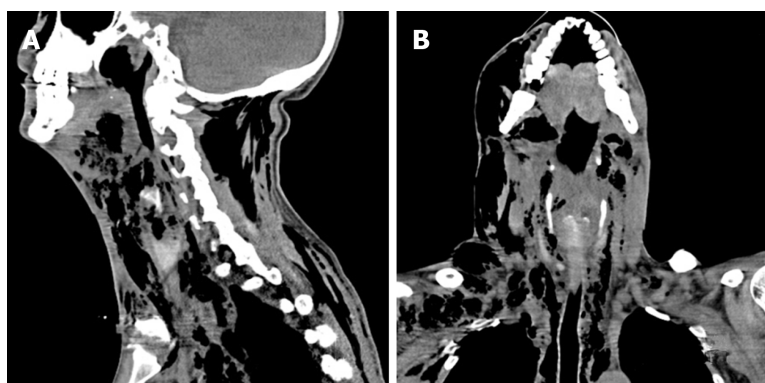


Figure 1 Sagittal and coronal computed tomography scans of the maxillofacial, neck and chest regions. Sagittal (A) and coronal (B) computed tomography scans of the maxillofacial, neck and chest regions showing extensive swelling and pneumatosis in soft tissues of bilateral oral, maxillofacial, temporal, cervical, parapharyngeal space, mediastinum, chest and back regions.

hydrochloride), nutritional support, water, electrolytes and acid-base stability. On the first day after surgery, platelets decreased to $22.00 \times 10^9/L$, and liver and kidney function tests were abnormal (alanine aminotransferase 186 U/L, glutamic oxalate aminotransferase 450 U/L, cholinesterase 968 U/L, urea 21.3 mmol/L, creatinine 153 $\mu\text{mol/L}$). Electrolytes were also abnormal (potassium 4.77 mmol/L, sodium 148.8 mmol/L, chlorine 114.6 mmol/L, calcium 1.38 mmol/L). On the second day after surgery, liver and kidney function continued to deteriorate (alanine aminotransferase increased to 168 U/L, glutamic oxalate aminotransferase increased to 1025 U/L, cholinesterase increased to 814 U/L, urea increased to 34.44 mmol/L, creatinine increased to 259 $\mu\text{mol/L}$). On the third day after surgery, the patient developed septic shock and sudden respiratory and cardiac arrest, and cardiopulmonary resuscitation was implemented immediately. Unfortunately, the rescue efforts were ineffective and the patient died.

OUTCOME AND FOLLOW-UP

Despite unremitting efforts by the doctors, the patient eventually died of septic shock and acute hepatic and renal insufficiency. Medical diagnoses at death were as follows: Septic shock; acute hepatic and renal insufficiency; severe multi-space infections bilaterally in the oral and maxillofacial head and neck regions; secondary infections of the thorax, back and waist; mediastinal abscess; bilateral pneumothorax; bilateral pulmonary infection; purulent pleural effusion; pericardial effusion; secondary thrombocytopenia.

DISCUSSION

Approximately 62.6% of oral and maxillofacial head and neck space infections are odontogenic and multiple spaces are involved in 22.5% of cases. The age of these patients ranged from 2 to 84 years and the mortality rate was 1%^[4]. Huang *et al*^[5] reported that the incidence of LTCs such as multi-space infections in the head and neck regions was about 12.20%, and descending mediastinitis was the most frequent (56.06%), followed by airway obstruction, pneumonia, pericarditis, intraorbital infection, multiple organ failure, intracranial infection and sudden cardiac death. Twelve patients (18.2%) with multi-space infections died during treatment.

In many remote rural areas of China, there is a proverb that toothache is not a disease. Due to this silly proverb, many people do not have a strong sense of oral health care, think that dental pain is not a disease, do not regularly see a dentist, or even use their own "indigenous method" to relieve pain. As reported in this case, the patient put a cigarette butt dipped in the pesticide "Miehailin" into the "dental cavity" to relieve the pain. Miehailin is a highly effective insecticide, which has a good quick-killing effect on mosquitoes, flies, cockroaches, bedbugs, ants and other pests. Why did our patient rapidly progress from having a simple odontogenic disease to multi-space infections in the oral, maxillofacial, head and neck regions, which quickly spread to the temporal, chest, mediastinum, back and waist regions? Firstly, we think that the toxicity of pesticides may play a role in the rapid development of diseases.

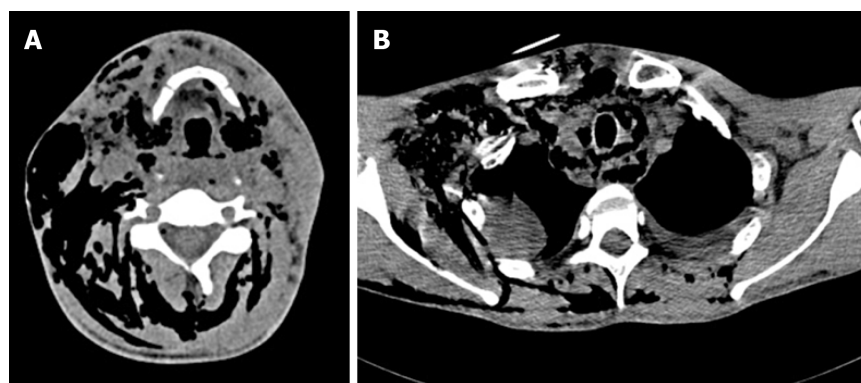


Figure 2 Transverse computed tomography scan of the hyoid plane and mediastinal plane. A: Transverse computed tomography (CT) scan of the hyoid plane showing extensive swelling and pneumatosis in soft tissues of the bilateral cervical region, parapharyngeal space, paracervical spine and posterior cervical region, especially in the right neck; B: Transverse CT scan of the mediastinal plane showing extensive pneumatosis in the mediastinal region.

Secondary thrombocytopenia in this patient is the best proof of this proposal. Secondly, in the early stage, the patient visited a non-dental medical institution. The clinician only removed the cigarette butt without any other treatment for the tooth lesion, which resulted in spread of the odontogenic infection. Thirdly, when the patient's odontogenic infection was confined to the oral and maxillofacial region, timely incision and drainage were not performed, which was an important factor in the rapid spread of infection throughout his body. When the patient was rushed to our hospital, oral and maxillofacial surgeons took the lead, and doctors from various departments were urgently consulted to assist in his treatment and formulate a reasonable and appropriate rescue plan. All available rescue measures were adopted, including timely intensive care, anesthesia intubation to ensure that the respiratory tract was unobstructed, extensive systemic abscess incision and drainage under general anesthesia, accurate thoracic and pericardial puncture abscess drainage, administration of the highest level of antibiotics, and platelet transfusion. Unfortunately, the patient died despite unremitting efforts by the doctors. In an analysis of the causes of death, we believe that there were many causes, but the main causes were septic shock, acute multiple organ failure, secondary thrombocytopenia, and pesticide poisoning.

Odontogenic infection can be treated effectively, but can also lead to severe multi-space infections in the oral and maxillofacial head and neck regions. The traditional treatment of multi-space infections in these regions is correct anti-bacterial drug administration and abscess incision and drainage^[6]. In recent years, Qiu *et al*^[7] and Li *et al*^[8] reported that a vacuum sealing drainage-assisted irrigation technique used in the treatment of severe multi-space infections in the oral and maxillofacial cervical regions showed high clinical and therapeutic efficacy. As the infection in our patient was very serious, following discussion and approval by the Drug Administration Committee, we administered the highest level of antibiotics (Norvancomycin hydrochloride) to combat the infection. For extensive incision and drainage of the multi-space infections in the oral and maxillofacial head and neck regions, we adopted disposable multi-functional tube drainage and irrigation technology. This technique can not only irrigate antibacterial drugs into the pus cavity continuously, but also remove infectious wastes by negative pressure suction.

Multi-space infections in the oral and maxillofacial head and neck regions can cause several LTCs. Effective prevention of the occurrence of LTCs is a challenge that oral and maxillofacial surgeons must address. Huang *et al*^[5] reported that older age and underlying systemic disease can increase the risk of multi-space infections. Gallo *et al*^[9] reported that algorithm-based management of head and neck space infections was successful in avoiding the onset LTCs. To identify the deep neck infection factors related to LTCs, Mejzlik *et al*^[10] conducted a multi-institutional study involving 586 patients. The results showed that patients with neck movement disturbances, dysphonia, dyspnea and swelling of the external neck, accompanied by severe pain, and inflammatory changes in the retropharyngeal space and large vessel areas, with culture-confirmed infection with *Candida albicans*, are likely to develop LTCs. Osunde *et al*^[11] reported that early recognition and treatment of established cases are necessary to prevent considerable morbidity and mortality. Heim *et al*^[12] showed that simultaneous removal of the infection focus (tooth) and abscess incision reduced the length of hospital stay. Combining literature results and our clinical practice, we

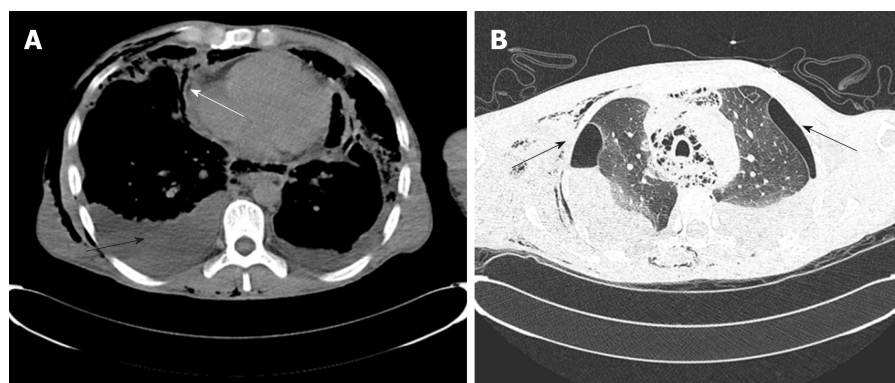


Figure 3 Transverse computed tomography scan of the cardiothoracic region. A: Bilateral pleural effusion (black arrow), pericardial effusion (white arrow); B: Bilateral pneumothorax and pulmonary infection.

believe that patients with serious systemic diseases, extensive infection, extremely abnormal blood and biochemical indicators, and severe respiratory obstruction can be used as predictors of mortality in multi-space infections.

CONCLUSION

Odontogenic infection can cause serious multi-space infections in oral and maxillofacial head and neck regions, which can cause several LTCs. As shown in the case reported herein, despite current medical advances, when a patient develops LTCs, the risk of death is high. The prevention of early odontogenic diseases is more meaningful than the treatment of late odontogenic multi-space infections. It is very important to treat the various stages of dental diseases, such as pulp diseases, periapical diseases, and periodontal diseases, effectively and promptly. Furthermore, it is also important to raise awareness of oral health care in remote mountainous areas of China.

REFERENCES

- 1 **Maroldi R**, Farina D, Ravanelli M, Lombardi D, Nicolai P. Emergency imaging assessment of deep neck space infections. *Semin Ultrasound CT MR* 2012; **33**: 432-442 [PMID: [22964409](#) DOI: [10.1053/j.sult.2012.06.008](#)]
- 2 **Wills PI**, Vernon RP. Complications of space infections of the head and neck. *Laryngoscope* 1981; **91**: 1129-1136 [PMID: [7242204](#)]
- 3 **Larawin V**, Naipao J, Dubey SP. Head and neck space infections. *Otolaryngol Head Neck Surg* 2006; **135**: 889-893 [PMID: [17141079](#) DOI: [10.1016/j.otohns.2006.07.007](#)]
- 4 **Pourdanesh F**, Dehghani N, Azarsina M, Malekhosein Z. Pattern of odontogenic infections at a tertiary hospital in tehran, iran: a 10-year retrospective study of 310 patients. *J Dent (Tehran)* 2013; **10**: 319-328 [PMID: [24396351](#)]
- 5 **Huang L**, Jiang B, Cai X, Zhang W, Qian W, Li Y, Guan X, Liang X, Zhou L, Zhu J, Zhang Z. Multi-Space Infections in the Head and Neck: Do Underlying Systemic Diseases Have a Predictive Role in Life-Threatening Complications? *J Oral Maxillofac Surg* 2015; **73**: 1320.e1-1320.10 [PMID: [25896569](#) DOI: [10.1016/j.joms.2015.04.002](#)]
- 6 **Bratton TA**, Jackson DC, Nkungula-Howlett T, Williams CW, Bennett CR. Management of complex multi-space odontogenic infections. *J Tenn Dent Assoc* 2002; **82**: 39-47 [PMID: [12572406](#)]
- 7 **Qiu Y**, Li Y, Gao B, Li J, Pan L, Ye Z, Lin Y, Lin L. Therapeutic efficacy of vacuum sealing drainage-assisted irrigation in patients with severe multiple-space infections in the oral, maxillofacial, and cervical regions. *J Craniomaxillofac Surg* 2019; **47**: 837-841 [PMID: [30808610](#) DOI: [10.1016/j.jcms.2019.01.031](#)]
- 8 **Li CM**, Xie CL, Hu S, Sun Q, Li GH, Niu ZX, Sun ML. [Clinical value of vacuum sealing drainage in the treatment of oral and maxillofacial space infection]. *Hua Xi Kou Qiang Yi Xue Za Zhi* 2019; **37**: 62-65 [PMID: [30854821](#) DOI: [10.7518/hxkq.2019.01.012](#)]
- 9 **Gallo O**, Mannelli G, Lazio MS, Santoro R. How to avoid life-threatening complications following head and neck space infections: an algorithm-based approach to apply during times of emergency. When and why to hospitalise a neck infection patient. *J Laryngol Otol* 2018; **132**: 53-59 [PMID: [29103390](#) DOI: [10.1017/S0022215117002201](#)]
- 10 **Mejzlik J**, Celakovsky P, Tucek L, Kotulek M, Vrbacky A, Matousek P, Stanikova L, Hoskova T, Pazu A, Mittu P, Chrobok V. Univariate and multivariate models for the prediction of life-threatening complications in 586 cases of deep neck space infections: retrospective multi-institutional study. *J Laryngol Otol* 2017; **131**: 779-784 [PMID: [28578716](#) DOI: [10.1017/S0022215117001153](#)]
- 11 **Osunde OD**, Akhiwu BI, Efunkoya AA, Adebola AR, Iyogun CA, Arotiba JT. Management of fascial space infections in a Nigerian teaching hospital: A 4-year review. *Niger Med J* 2012; **53**: 12-15 [PMID: [23271838](#) DOI: [10.4103/0300-1652.99823](#)]
- 12 **Heim N**, Warwas FB, Wiedemeyer V, Wilms CT, Reich RH, Martini M. The role of immediate versus

secondary removal of the odontogenic focus in treatment of deep head and neck space infections. A retrospective analysis of 248 patients. *Clin Oral Investig* 2019; **23**: 2921-2927 [PMID: [30623306](#) DOI: [10.1007/s00784-018-02796-7](#)]



Published By Baishideng Publishing Group Inc
7041 Koll Center Parkway, Suite 160, Pleasanton, CA 94566, USA
Telephone: +1-925-2238242
E-mail: bpgoffice@wjgnet.com
Help Desk: <https://www.f6publishing.com/helpdesk>
<https://www.wjgnet.com>

