

Dear Editor,

Thank you for carefully reviewing our manuscript previously titled “Resection of Recurrent Third Branchial Cleft Fistulas Assisted by Flexible Pharyngotomy” for possible publication in the World Journal of Clinical Cases. We are grateful to you and your reviewers for their constructive critique. We have revised the manuscript, highlighting our revisions in red, and have attached point-by-point responses detailing how we have revised the manuscript in response to the reviewers' comments below.

Thank you for your consideration and further review of our manuscript. Please do not hesitate to contact us with any further questions or recommendations.

Yours Sincerely,

Zhi-Chun Huang

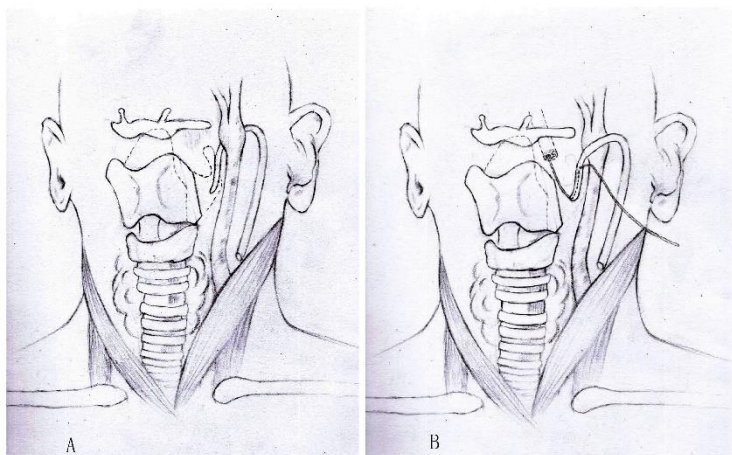
Reviewer Comments:

The authors have finished a good study of their method of surgical treatment of Recurrent Third Branchial Cleft Fistulas. About the procedure of their method, please add some drawing pictures to describe the procedure more clearly.

Response:

We have added two drawing pictures to describe the procedure in the manuscript:

Figure 2: Resection of the partial of the thyroid cartilage and the inner opening was located by flexible fiber-optic pharyngoscopy.



-A): The branchial cleft fistula was traced to the thyroid cartilage, and partial of the thyroid cartilage was resected to expose the pyriform clearly.

-B): The guidewire was inserted into the pyriform sinus to the fistula by pharyngoscopy, and then it was located in the neck incision.