

# World Journal of *Clinical Cases*

*World J Clin Cases* 2019 December 26; 7(24): 4172-4425



**REVIEW**

- 4172** Polyunsaturated fatty acids and DNA methylation in colorectal cancer  
*Moradi Sarabi M, Mohammadrezaei Khorramabadi R, Zare Z, Eftekhari E*

**ORIGINAL ARTICLE****Retrospective Study**

- 4186** Impact of resection margins on long-term survival after pancreaticoduodenectomy for pancreatic head carcinoma  
*Li CG, Zhou ZP, Tan XL, Gao YX, Wang ZZ, Liu Q, Zhao ZM*
- 4196** Arthroscopy combined with unicompartmental knee arthroplasty for treatment of isolated unicompartmental knee arthritis: A long-term comparison  
*Wang HR, Li ZL, Li J, Wang YX, Zhao ZD, Li W*
- 4208** Intact, pie-crusting and repairing the posterior cruciate ligament in posterior cruciate ligament-retaining total knee arthroplasty: A 5-year follow-up  
*Ma DS, Wen L, Wang ZW, Zhang B, Ren SX, Lin Y*
- 4218** Community-acquired pneumonia complicated by rhabdomyolysis: A clinical analysis of 11 cases  
*Zhao B, Zheng R*

**Clinical Trials Study**

- 4226** Dissection and ligation of the lateral circumflex femoral artery is not necessary when using the direct anterior approach for total hip arthroplasty  
*Zhao GY, Wang YJ, Xu NW, Liu F*

**Observational Study**

- 4234** Expression of interleukin-32 in bone marrow of patients with myeloma and its prognostic significance  
*Wang G, Ning FY, Wang JH, Yan HM, Kong HW, Zhang YT, Shen Q*

**Randomized Controlled Trial**

- 4245** Effect of different types of laryngeal mask airway placement on the right internal jugular vein: A prospective randomized controlled trial  
*Zhang JJ, Qu ZY, Hua Z, Zuo MZ, Zhang HY*

**SYSTEMATIC REVIEW**

- 4254** Chronic pain, posttraumatic stress disorder, and opioid intake: A systematic review  
*López-Martínez AE, Reyes-Pérez Á, Serrano-Ibáñez ER, Esteve R, Ramírez-Maestre C*

## CASE REPORT

- 4270 Acute appendicitis in a patient after a uterus transplant: A case report  
*Kristek J, Kudla M, Chlupac J, Novotny R, Mirejovsky T, Janousek L, Fronek J*
- 4277 Pneumococcal infection transmission between family members with congenital asplenia: A case report  
*Shibata J, Hiramatsu K, Kenzaka T, Kato T*
- 4285 Successful treatment of warfarin-induced skin necrosis using oral rivaroxaban: A case report  
*Kamada M, Kenzaka T*
- 4292 Simultaneous *Paragonimus* infection involving the breast and lung: A case report  
*Oh MY, Chu A, Park JH, Lee JY, Roh EY, Chai YJ, Hwang KT*
- 4299 Isolated peritoneal lymphomatosis defined as post-transplant lymphoproliferative disorder after a liver transplant: A case report  
*Kim HB, Hong R, Na YS, Choi WY, Park SG, Lee HJ*
- 4307 Three-dimensional image simulation of primary diaphragmatic hemangioma: A case report  
*Chu PY, Lin KH, Kao HL, Peng YJ, Huang TW*
- 4314 Natural orifice specimen extraction with laparoscopic radical gastrectomy for distal gastric cancer: A case report  
*Sun P, Wang XS, Liu Q, Luan YS, Tian YT*
- 4321 Huge brown tumor of the rib in an unlocatable hyperparathyroidism patient with “self-recovered” serum calcium and parathyroid hormone: A case report  
*Wang WD, Zhang N, Qu Q, He XD*
- 4327 Percutaneous management of atrium and lung perforation: A case report  
*Zhou X, Ze F, Li D, Li XB*
- 4334 Epstein-Barr virus-positive post-transplant lymphoproliferative disorder presenting as hematochezia and enterobrosis in renal transplant recipients in China: A report of two cases  
*Sun ZJ, Hu XP, Fan BH, Wang W*
- 4342 Postoperative multidrug-resistant *Acinetobacter baumannii* meningitis successfully treated with intravenous doxycycline and intraventricular gentamicin: A case report  
*Wu X, Wang L, Ye YZ, Yu H*
- 4349 Reconstruction of massive skin avulsion of the scrota and penis by combined application of dermal regeneration template (Pelnac) and split-thickness skin graft with vacuum-assisted closure: A case report  
*Fang JJ, Li PF, Wu JJ, Zhou HY, Xie LP, Lu H*

- 4355** Multisystem smooth muscle dysfunction syndrome in a Chinese girl: A case report and review of the literature  
*Chen SN, Wang YQ, Hao CL, Lu YH, Jiang WJ, Gao CY, Wu M*
- 4366** Kidney inflammatory myofibroblastic tumor masquerading as metastatic malignancy: A case report and literature review  
*Zhang GH, Guo XY, Liang GZ, Wang Q*
- 4377** Hydroxychloroquine-induced renal phospholipidosis resembling Fabry disease in undifferentiated connective tissue disease: A case report  
*Wu SZ, Liang X, Geng J, Zhang MB, Xie N, Su XY*
- 4384** Spontaneous ovarian hyperstimulation syndrome: Report of two cases  
*Gui J, Zhang J, Xu WM, Ming L*
- 4391** Castleman disease in the hepatic-gastric space: A case report  
*Xu XY, Liu XQ, Du HW, Liu JH*
- 4398** KIT and platelet-derived growth factor receptor  $\alpha$  wild-type gastrointestinal stromal tumor associated with neurofibromatosis type 1: Two case reports  
*Kou YW, Zhang Y, Fu YP, Wang Z*
- 4414** Isolated elevated aspartate aminotransferase in an asymptomatic woman due to macro-aspartate aminotransferase: A case report  
*Zhan MR, Liu X, Zhang MY, Niu JQ*
- 4420** Rehabilitation of anterior pituitary dysfunction combined with extrapontine myelinolysis: A case report  
*Yang MX, Chen XN*

**ABOUT COVER**

Editorial Board Member of *World Journal of Clinical Cases*, Ashu Seith Bhalla, MD, Professor, Department of Radiodiagnosis, All India Institute of Medical Sciences, New Delhi 110029, India

**AIMS AND SCOPE**

The primary aim of *World Journal of Clinical Cases* (WJCC, *World J Clin Cases*) is to provide scholars and readers from various fields of clinical medicine with a platform to publish high-quality clinical research articles and communicate their research findings online.

WJCC mainly publishes articles reporting research results and findings obtained in the field of clinical medicine and covering a wide range of topics, including case control studies, retrospective cohort studies, retrospective studies, clinical trials studies, observational studies, prospective studies, randomized controlled trials, randomized clinical trials, systematic reviews, meta-analysis, and case reports.

**INDEXING/ABSTRACTING**

The WJCC is now indexed in PubMed, PubMed Central, Science Citation Index Expanded (also known as SciSearch®), and Journal Citation Reports/Science Edition. The 2019 Edition of Journal Citation Reports cites the 2018 impact factor for WJCC as 1.153 (5-year impact factor: N/A), ranking WJCC as 99 among 160 journals in Medicine, General and Internal (quartile in category Q3).

**RESPONSIBLE EDITORS FOR THIS ISSUE**

Responsible Electronic Editor: Ji-Hong Liu

Proofing Production Department Director: Yun-Xiaojuan Wu

**NAME OF JOURNAL**

*World Journal of Clinical Cases*

**ISSN**

ISSN 2307-8960 (online)

**LAUNCH DATE**

April 16, 2013

**FREQUENCY**

Semimonthly

**EDITORS-IN-CHIEF**

Dennis A Bloomfield, Bao-Gan Peng, Sandro Vento

**EDITORIAL BOARD MEMBERS**

<https://www.wjnet.com/2307-8960/editorialboard.htm>

**EDITORIAL OFFICE**

Jin-Lei Wang, Director

**PUBLICATION DATE**

December 26, 2019

**COPYRIGHT**

© 2019 Baishideng Publishing Group Inc

**INSTRUCTIONS TO AUTHORS**

<https://www.wjnet.com/bpg/gerinfo/204>

**GUIDELINES FOR ETHICS DOCUMENTS**

<https://www.wjnet.com/bpg/GerInfo/287>

**GUIDELINES FOR NON-NATIVE SPEAKERS OF ENGLISH**

<https://www.wjnet.com/bpg/gerinfo/240>

**PUBLICATION MISCONDUCT**

<https://www.wjnet.com/bpg/gerinfo/208>

**ARTICLE PROCESSING CHARGE**

<https://www.wjnet.com/bpg/gerinfo/242>

**STEPS FOR SUBMITTING MANUSCRIPTS**

<https://www.wjnet.com/bpg/GerInfo/239>

**ONLINE SUBMISSION**

<https://www.f6publishing.com>



## Clinical Trials Study

## Dissection and ligation of the lateral circumflex femoral artery is not necessary when using the direct anterior approach for total hip arthroplasty

Gong-Yin Zhao, Yu-Ji Wang, Nan-Wei Xu, Feng Liu

**ORCID number:** Gong-Yin Zhao (0000-0001-7621-6834); Yu-Ji Wang (0000-0001-8790-8879); Nan-Wei Xu (0000-0002-5238-0127); Feng Liu (0000-0002-2259-4511).

**Author contributions:** Liu F designed research; Zhao GY, Wang YJ, and Xu NW performed research; Zhao GY and Wang YJ analyzed data; Zhao GY wrote the paper.

**Institutional review board**

**statement:** The approval for this study was obtained from the Institutional Review Board committees of the affiliated Changzhou NO. 2 People's Hospital of Nanjing Medical University.

**Clinical trial registration statement:**

The clinical trial was registered in the affiliated Changzhou NO. 2 People's Hospital of Nanjing Medical University, with the registration number of 2016-c-06-01.

**Informed consent statement:**

Informed consent was obtained from all individual participants included in the study.

**Conflict-of-interest statement:** The authors declare that there is no conflict of interest.

**Data sharing statement:** We declare that data from this experiment can be shared in a public database.

**CONSORT 2010 statement:** The design and composition of the

**Gong-Yin Zhao, Yu-Ji Wang, Nan-Wei Xu,** Department of Orthopedics, The Affiliated Changzhou NO. 2 People's Hospital of Nanjing Medical University, Changzhou 213003, Jiangsu Province, China

**Feng Liu,** Department of Orthopedics, The First Affiliated Hospital of Nanjing Medical University, Nanjing 210000, Jiangsu Province, China

**Corresponding author:** Feng Liu, MD, PhD, Chief Doctor, Department of Orthopedics, The First Affiliated Hospital of Nanjing Medical University, 300 Guangzhou Road, Nanjing 210000, Jiangsu Province, China. [njliuf@163.com](mailto:njliuf@163.com)

**Telephone:** +86-15961104432

## Abstract

**BACKGROUND**

Branches of the lateral circumflex femoral artery (LCFA) stretch across the surgical field during a direct anterior total hip arthroplasty. It is an anatomical marker in direct anterior approach. As an important vessel around the hip joint, this vessel was ligated in most situations. Although ligation of the vascular pedicle of the LCFA is a common, traditional procedure used to decrease bleeding, the ligation of the pedicle of the vessel is tedious and time-consuming.

**AIM**

To explore whether this ligation is truly necessary in a direct anterior approach to total hip arthroplasty.

**METHODS**

This single-center, single-surgeon, prospective study was performed to compare patients' bleeding undergoing ligation of the branches of the LCFA pedicle (group A) *vs* those treated with electrocautery from the branches of the LCFA (group B). In both groups, the pedicles were identified in the intermuscular plane between the tensor fasciae lata and the rectus femoris muscles. In group A, the pedicles were ligated with a silk ligature. In group B, the branches coming off the LCFA were controlled with electrocautery. We compared preoperative *vs* postoperative changes in blood hemoglobin levels, intraoperative blood loss, operative time, rates of transfusion, re-bleeding, and hematoma between the two groups.

**RESULTS**

clinical trials study conform to the CONSORT2010 statements.

**Open-Access:** This article is an open-access article which was selected by an in-house editor and fully peer-reviewed by external reviewers. It is distributed in accordance with the Creative Commons Attribution Non Commercial (CC BY-NC 4.0) license, which permits others to distribute, remix, adapt, build upon this work non-commercially, and license their derivative works on different terms, provided the original work is properly cited and the use is non-commercial. See: <http://creativecommons.org/licenses/by-nc/4.0/>

**Manuscript source:** Unsolicited manuscript

**Received:** August 17, 2019

**Peer-review started:** August 17, 2019

**First decision:** September 23, 2019

**Revised:** October 20, 2019

**Accepted:** November 19, 2019

**Article in press:** November 19, 2019

**Published online:** December 26, 2019

**P-Reviewer:** Widmer KH

**S-Editor:** Gong ZM

**L-Editor:** Filipodia

**E-Editor:** Liu MY



The reduction of hemoglobin in group A was  $20.9 \pm 7.0$ , and in group B it was  $21.2 \pm 4.9$ . There was no statistically significant difference between the two groups ( $P > 0.05$ ). The actual calculated blood loss in group A was  $784 \pm 125$  mL, and in group B it was  $722 \pm 153$  mL. There was a trend in group A having more blood loss ( $P = 0.078$ ). The estimated blood loss in group A was  $344 \pm 88$  mL, and in group B it was  $346 \pm 73$  mL. There was no statistically significant difference between the two groups ( $P = 0.883$ ). In addition, there were no significant differences in the rates of postoperative transfusion (10% *vs* 6.7%,  $P > 0.05$ ), postoperative hematomas (6.7% *vs* 13.3%,  $P > 0.05$ ), or re-bleeding (13.3% *vs* 20%,  $P > 0.05$ ) between the two groups.

## CONCLUSION

Ligation of the pedicle of the LCFA has no advantage in preventing or decreasing bleeding during or after a total hip arthroplasty using the direct anterior approach. Ligation of the pedicle of the vessel is a cumbersome, unnecessary procedure and can be replaced by electrocautery control of the branches off this artery that course through the surgical field.

**Key words:** Total hip arthroplasty; Direct anterior approach; Lateral circumflex femoral artery; Ligation; Blood loss; Electrocautery

©The Author(s) 2019. Published by Baishideng Publishing Group Inc. All rights reserved.

**Core tip:** Most surgeons ligate the ascending branch of the lateral circumflex femoral artery during direct anterior total hip arthroplasty, but it may not be necessary. In our study, ligation of the lateral femoral circumflex artery does not reduce bleeding in direct anterior total hip arthroplasty and can be replaced by electrocautery.

**Citation:** Zhao GY, Wang YJ, Xu NW, Liu F. Dissection and ligation of the lateral circumflex femoral artery is not necessary when using the direct anterior approach for total hip arthroplasty. *World J Clin Cases* 2019; 7(24): 4226-4233

**URL:** <https://www.wjnet.com/2307-8960/full/v7/i24/4226.htm>

**DOI:** <https://dx.doi.org/10.12998/wjcc.v7.i24.4226>

## INTRODUCTION

Hemorrhage during a total hip arthroplasty (THA) involves an expected blood loss as well as perioperative "hidden blood loss"<sup>[1-4]</sup>. Specific measures designed to minimize blood loss are important not only to decrease unnecessary bleeding, but also to promote a more rapid, functional recovery and to decrease the need for blood transfusion<sup>[5,6]</sup>. The direct anterior approach (DAA) to performing a THA utilizes an approach *via* the intermuscular plane, which is designed to minimize muscle damage and blood loss. Moreover, this approach is associated with accelerated postoperative recovery and low rates of dislocation.

The lateral circumflex femoral artery (LCFA) arises from the profunda femoris artery or the femoral artery and supplies blood to the inferior-medial cortex of the femoral neck and the periarticular soft tissues. In most cases, the LCFA usually divides into an ascending and a descending branch; however, in some patients, the LCFA has a third, transverse branch<sup>[7-10]</sup>. During a DAA, the ascending and transverse branches of LCFA span across the incision between the distal and the middle third of this approach. Most surgeons believe that these vessels are involved in extra blood loss and therefore believe that their ligation is necessary to minimize otherwise unnecessary bleeding<sup>[11-14]</sup>. Their control *via* ligation of their pedicle is a troublesome procedure for orthopedists, requiring a bit of extra time and effort to dissect the pedicle.

The aim of this study was to investigate whether ligation of the pedicle of the LCFA will decrease blood loss and lead to better surgical results compared to electrocauterization of the branches off the LCFA.

## MATERIALS AND METHODS

### Subjects

We conducted a 2-year study of 103 patients with femoral neck fractures undergoing a THA *via* a DAA from October 2016 to October 2018. Patients older than 90 years ( $n = 7$ ) were excluded. Patients who had a history of stroke ( $n = 10$ ), hepatic or renal failure ( $n = 3$ ), coagulation abnormalities ( $n = 4$ ), taking anticoagulants ( $n = 6$ ), myocardial infarction ( $n = 3$ ), previous venous thromboembolism ( $n = 4$ ), and surgery lasting more than 90 min or had an unexpected condition, such as an intraoperative fracture ( $n = 6$ ) were also excluded.

In the end, 60 patients were enrolled in the study, ranging in age from 52- to 87-years-old. Patients were numbered according to the order of admission. Patients with an odd number were included in group A, and patients with even number were included in group B. The patients were assigned to groups by a supervisor nurse who did not know the surgery situation. Patients who underwent ligation of the pedicle comprised Group A; those whose branches off the LCFA were treated by electrocautery comprised Group B. Approval for this study was obtained from the Institutional Review Board committees of the authors' affiliated institutions. The patients were informed of the intraoperative vascular management and signed the informed consent after obtaining the consent. Patients were blinded of their grouping.

### Operative technique

For this DAA approach, a vertical incision was made over the medial edge of the tensor fasciae lata muscle (TFLM). After the location of the TFLM was confirmed, the overlying fascia was incised and the plane between the TFLM and rectus femoris muscles was identified and dissected with retraction of the TFLM laterally. The branches of the LCFA were seen to course anterior to the underlying fat (Figure 1A). The pedicle of the LCFA in group A was ligated with silk suture material and transected; this maneuver required dissection of their pedicles deep into the wound. In group B, the branches off the LCFA were controlled with electrocautery set at a power of 55 W. Electrocautery was easily and rapidly carried out along the blood vessels, and satisfactory hemostasis was evident (Figure 1B).

All operations were performed by the same group of surgeons using the DAA. Each patient received a cementless hip stem prosthesis and a cementless acetabular cup from a single manufacturer (Waldemar Link GmbH and Co, Hamburg, Germany). After the operation, all patients received subcutaneous injections of 4100 IU of low molecular weight heparin calcium once a day and application of mechanical intermittent pneumatic compression devices in bed twice a day (30 min each time) to prevent venous thromboembolism. All patients started to walk with a walking aid within 24 h of surgery.

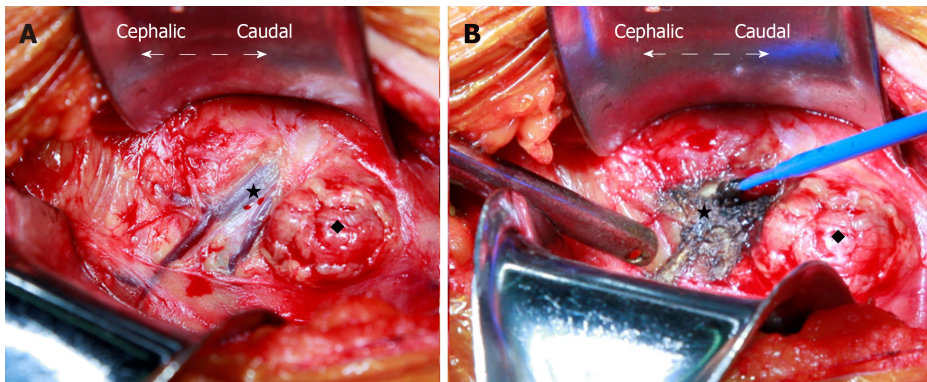
We measured the decrease in hemoglobin (Hgb), estimated intraoperative blood loss, actual (calculated) blood loss, transfusion rate, re-bleeding rate, and hematoma rate. The decrease in Hgb was associated with changes in Hgb concentrations between the preoperative value and the values at 48 h postoperative. The actual blood loss was calculated using the equation: Actual blood loss = blood volume [preoperative hematocrit - postoperative hematocrit]/[mean hematocrit], where blood volume = body weight in kilograms  $\times$  70 mL/kg<sup>[15]</sup>.

The estimated blood loss was determined from the anesthesia record and postoperative drainage. The indications for transfusion were Hgb < 7 g/L and/or hematocrit < 22 in patients less than 75 years of age. In contrast, patients older than 75 years with Hgb < 9 g/L were given transfusions if the clinical evaluation showed tachycardia, poor urine output, hypotension, fatigue, light-headedness, or other symptoms of acute anemia as determined by the postoperative team. The duration of the operation was determined from the anesthesia record. The relevant clinical data were collected by a single observer, who was blinded to the patient's operative approach.

### Statistical analysis

Data were recorded and collected into an Excel database (Microsoft). Statistical analysis was performed using GraphPad Prism 5. All variables were analyzed using a paired Student's *t* test except the rates of transfusion, hematoma, re-bleeding, and prosthetic loosening, which were analyzed using Fisher's exact test. Statistical significance was defined at  $P < 0.05$ . All variables were analyzed by an independent orthopedist who was not part of the operative team, was blinded to the patient groups, and who received no funding, has no competing interests, and confirmed the accuracy of the findings.





**Figure 1** Plane between tensor fasciae lata muscle and rectus femoris showing the branches of the lateral circumflex femoral artery spanning the wound. "Star" represents the ascending branch of lateral circumflex femoral artery. "Diamond" represents the fat strip.

## RESULTS

### *Patient characteristics*

From October 2016 to October 2017, 103 patients scheduled for a primary THA with a single surgeon were screened and assessed for eligibility. Forty-three of the patients were excluded for failing to meet the selection criteria. After randomization, 60 patients (30 patients in group A; 30 patients in group B) were included in the statistical analysis of our trial (Figure 2). The patients were evenly matched in demographics (Table 1). There were no statistically significant differences in body mass index, age, or sex (all  $P$  values were  $> 0.05$ ).

### *Postoperative outcomes*

There were no statistically significant differences in the decrease of Hgb between group A and group B ( $20.9 \pm 7.0$  g *vs*  $21.2 \pm 4.9$  g, respectively;  $P = 0.805$ ) and the actual calculated blood loss ( $784 \pm 125$  mL *vs*  $722 \pm 152$  mL). However, there was a trend in group A towards having more blood loss ( $P = 0.078$ ). However, this trend did not explain the problem, and the difference would be narrowed after the sample size increased. The estimated blood loss ( $344 \pm 88$  mL *vs*  $346 \pm 73$  mL;  $P > 0.5$ ) did not show significant differences. Importantly, there were no statistically significant differences between the two methods in the rate of blood transfusion, hematoma, or re-bleeding ( $P > 0.2$  for each) (Table 2).

## DISCUSSION

DAA is associated with less trauma than the posterolateral approach for THA. Because it is a less traumatic approach, finding a method to address the relevant blood vessels to prevent unnecessary bleeding during the operation is particularly important. In the posterolateral approach, the pedicle to be ligated is the medial circumflex femoral artery. Chiron *et al*<sup>[6]</sup> reported that ligation of the pedicle of the medial circumflex femoral artery can decrease bleeding effectively during a posterolateral approach. In the DAA, the ascending branch of LCFA is the important vessel in the surgical field and must be controlled. The LCFA originates from the profunda femoris artery or the common femoral artery. The ascending branch continues along the capsule and crosses the hip joint to supply the anterolateral capsule and thereby crosses the operative field in a DAA<sup>[16,17]</sup>. Because it is the donor and must be anastomosed by vascularized grafts in the treatment of osteonecrosis of the femoral head, the ascending branch also can be used as both a pedicle and free flap. Because the LCFA provides a less plentiful blood supply than the medial circumflex femoral artery, ligating it does not appear to have any pronounced negative effects<sup>[10,18,19]</sup>.

Previous studies have described a number of surgical procedures and techniques during a DAA, but few works have focused on the treatment of this troublesome vessel<sup>[15,20-22]</sup>. Our study compared the consequences of two methods of dealing with the ascending branch of LCFA during a DAA and demonstrated that formal ligation of the ascending branch of the LCFA is unnecessary. Electrocautery is a simple and effective method to control this vessel; electrocautery can transect the vessel without causing bleeding, which simplifies the procedure. In the ligation group, there was no increased risk of re-bleeding or hematoma, suggesting that it is a relatively safe

**Table 1** Demographics<sup>1</sup> of patients in both groups

	Group A	Control B	t-test	P value
Age (yr)	71 (9)	71 (9)	0.447	0.657
Male, <i>n</i> (%)	11 (37)	8 (27)	-	
BMI (kg/m <sup>2</sup> )	24.0 (2.6)	24.0 (2.5)	0.092	0.927

<sup>1</sup>Values are presented as mean ± SD. BMI: Body mass index.

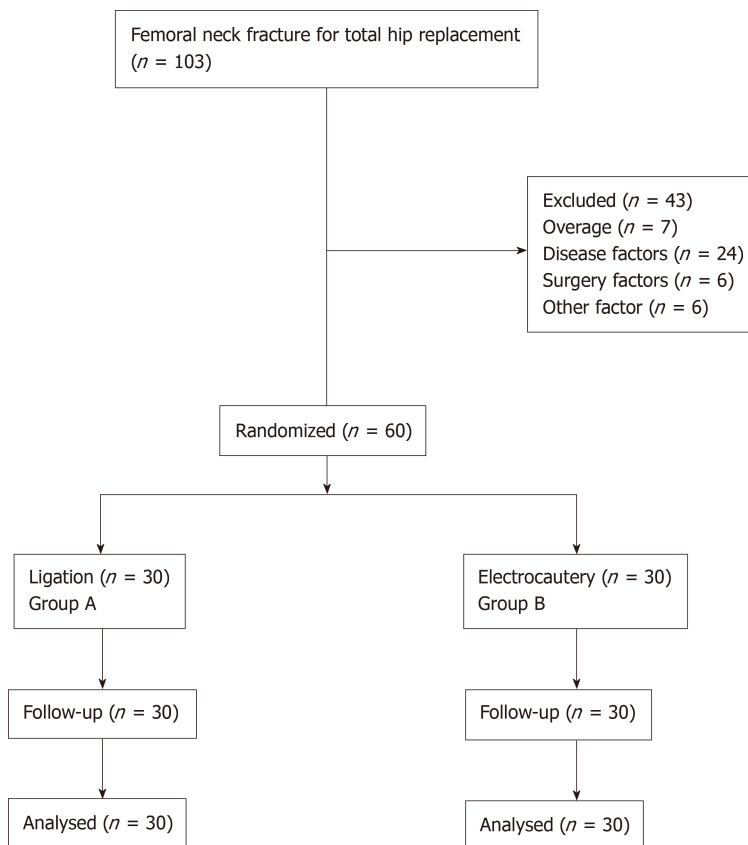
hemostatic technique and can replace the dissection of and subsequent ligation of its pedicle as a means of preventing unnecessary bleeding from the ascending branch of the LCFA.

We emphasize that our study did not include patients with coagulation disorders, hematologic disorders, or other related diseases affecting coagulation. For these patients, whether suture ligating the vessel is safe and effective still needs further verification. This study should be supplemented by a larger, randomized study to verify these preliminary conclusions.

Leaving the lateral circumflex pedicle unligated and addressing any bleeding using electrocauterization alone does not increase blood loss in the perioperative period and does not increase the incidence of postoperative hematomas in patients undergoing THA by a DAA. Although ligation did not significantly increase the operative time, it did require some additional time and effort, while offering no obvious benefit. Therefore, it is unnecessary to ligate the LCFA during a DAA.

**Table 2** Comparison of group outcomes<sup>1</sup>

	Group A	Group B	t-test	P value
Decrease in Hgb (g/L)	20.9 (7.0)	21.2 (4.9)	0.248	0.805
Actual blood loss (mL)	784 (125)	722 (153)	1.829	0.078
Estimated blood loss (mL)	344 (88)	346 (73)	0.147	0.883
Hematoma rate <sup>2</sup>	7%	13%	-	0.238
Re-bleeding rate <sup>2</sup>	13%	20%	-	0.216
Transfusion rate <sup>2</sup>	10%	7%	-	0.323

<sup>1</sup>Values are presented as mean  $\pm$  SD.<sup>2</sup>Fisher's exact test.**Figure 2** Flow diagram illustrating patients enrolled in the study.

## ARTICLE HIGHLIGHTS

### Research background

Direct anterior approach total hip arthroplasty is widely accepted and becoming more and more popular all over the world. More orthopedists have switched from posterior to anterior approaches. Although the procedure is generally the same, no consensus has been reached on some details.

### Research motivation

In the direct anterior approach, there are different opinions on the treatment of the ascending branch of the lateral femoral circumflex artery. The hope is that these studies will lead to a consensus on some of the details of direct anterior approach total hip arthroplasty.

### Research objectives

Whether ligation of the ascending branch of the lateral femoral circumflex artery during direct anterior approach total hip arthroplasty is advantageous in reducing bleeding and whether this procedure is necessary.

### Research methods

The manuscript compared the surgical bleeding, hemoglobin reduction, hematoma rate, and other indicators of two groups that received different treatments for the ascending branch of the lateral femoral circumflex artery during direct anterior approach total hip arthroplasty.

### Research results

According to the results, the ligation of the ascending branch of the lateral femoral circumflex artery was not a necessary procedure. Electrocautery is a simple and effective method. However, due to the small sample size and short follow-up time, further observation is needed to see whether there is any difference between the two treatment methods.

### Research conclusions

The intraoperative and postoperative blood loss were calculated to indirectly reflect vascular bleeding. Excision of the ascending branch of the lateral femoral artery by electrocautery did not increase bleeding. In the treatment of the ascending branch of the lateral circumflex femoral artery, cumbersome ligation can be replaced by electrocoagulation.

### Research perspectives

Ligation is unnecessary and should be replaced by electrocautery in the treatment of the lateral circumflex femoral artery during the direct anterior approach total hip arthroplasty.

## REFERENCES

- 1 **Borgen PO**, Dahl OE, Reikerås O. Blood loss in cemented THA is not reduced with postoperative versus preoperative start of thromboprophylaxis. *Clin Orthop Relat Res* 2012; **470**: 2591-2598 [PMID: [22476844](#) DOI: [10.1007/s11999-012-2320-9](#)]
- 2 **Bao N**, Zhou L, Cong Y, Guo T, Fan W, Chang Z, Zhao J. Free fatty acids are responsible for the hidden blood loss in total hip and knee arthroplasty. *Med Hypotheses* 2013; **81**: 104-107 [PMID: [23623296](#) DOI: [10.1016/j.mehy.2013.03.038](#)]
- 3 **Johansson T**, Engquist M, Pettersson LG, Lisander B. Blood loss after total hip replacement: a prospective randomized study between wound compression and drainage. *J Arthroplasty* 2005; **20**: 967-971 [PMID: [16376249](#) DOI: [10.1016/j.arth.2005.02.004](#)]
- 4 **Liu X**, Zhang X, Chen Y, Wang Q, Jiang Y, Zeng B. Hidden blood loss after total hip arthroplasty. *J Arthroplasty* 2011; **26**: 1100-1105.e1 [PMID: [21256705](#) DOI: [10.1016/j.arth.2010.11.013](#)]
- 5 **Alshryda S**, Mason J, Sarda P, Nargol A, Cooke N, Ahmad H, Tang S, Logishetty R, Vaghela M, McPartlin L, Hungin AP. Topical (intra-articular) tranexamic acid reduces blood loss and transfusion rates following total hip replacement: a randomized controlled trial (TRANX-H). *J Bone Joint Surg Am* 2013; **95**: 1969-1974 [PMID: [24196467](#) DOI: [10.2106/JBJS.L.00908](#)]
- 6 **Chiron P**, Murgier J, Reina N. Reduced blood loss with ligation of medial circumflex pedicle during total hip arthroplasty with minimally invasive posterior approach. *Orthop Traumatol Surg Res* 2014; **100**: 237-238 [PMID: [24559883](#) DOI: [10.1016/j.otsr.2013.11.013](#)]
- 7 **Gradman WS**. Bypass to the lateral circumflex femoral artery. *Ann Vasc Surg* 1992; **6**: 344-346 [PMID: [1390022](#) DOI: [10.1007/BF02008791](#)]
- 8 **Goel S**, Arora J, Mehta V, Sharma M, Suri RK, Rath G. Unusual disposition of lateral circumflex femoral artery: Anatomical description and clinical implications. *World J Clin Cases* 2015; **3**: 85-88 [PMID: [25610855](#) DOI: [10.12998/wjcc.v3.i1.85](#)]
- 9 **Vuksanovic-Bozagic A**, Radojevic N, Muhovic D, Abramovic M, Radunovic M. Significance of anatomical variations of the lateral circumflex femoral artery for the tensor fasciae latae flapping. *Folia Morphol (Warsz)* 2015; **74**: 389-395 [PMID: [26339822](#) DOI: [10.5603/FM.2015.0060](#)]
- 10 **Zlotorowicz M**, Czubak-Wrzosek M, Wrzosek P, Czubak J. The origin of the medial femoral circumflex artery, lateral femoral circumflex artery and obturator artery. *Surg Radiol Anat* 2018; **40**: 515-520 [PMID: [29651567](#) DOI: [10.1007/s00276-018-2012-6](#)]
- 11 **Post ZD**, Orozco F, Diaz-Ledezma C, Hozack WJ, Ong A. Direct anterior approach for total hip arthroplasty: indications, technique, and results. *J Am Acad Orthop Surg* 2014; **22**: 595-603 [PMID: [25157041](#) DOI: [10.5435/JAAOS-22-09-595](#)]
- 12 **De Geest T**, Vansintjan P, De Loore G. Direct anterior total hip arthroplasty: complications and early outcome in a series of 300 cases. *Acta Orthop Belg* 2013; **79**: 166-173 [PMID: [23821968](#)]
- 13 **Cadossi M**, Sambri A, Tedesco G, Mazzotti A, Terrando S, Faldini C. Anterior Approach in Total Hip Replacement. *Orthopedics* 2017; **40**: e553-e556 [PMID: [27942738](#) DOI: [10.3928/01477447-20161202-06](#)]
- 14 **Connolly KP**, Kamath AF. Direct anterior total hip arthroplasty: Literature review of variations in surgical technique. *World J Orthop* 2016; **7**: 38-43 [PMID: [26807354](#) DOI: [10.5312/wjo.v7.i1.38](#)]
- 15 **Horne PH**, Olson SA. Direct anterior approach for total hip arthroplasty using the fracture table. *Curr Rev Musculoskelet Med* 2011; **4**: 139-145 [PMID: [21713379](#) DOI: [10.1007/s12178-011-9087-6](#)]
- 16 **Burusapat C**, Nanasilp T, Kunaphensaeng P, Ruamthanthong A. Effect of Atherosclerosis on the Lateral Circumflex Femoral Artery and Its Descending Branch: Comparative Study to Nonatherosclerotic Risk. *Plast Reconstr Surg Glob Open* 2016; **4**: e856 [PMID: [27757321](#) DOI: [10.1097/GOX.0000000000000849](#)]
- 17 **Kalhor M**, Horowitz K, Gharehdaghi J, Beck M, Ganz R. Anatomic variations in femoral head circulation. *Hip Int* 2012; **22**: 307-312 [PMID: [22740271](#) DOI: [10.5301/HIP.2012.9242](#)]
- 18 **Nakano N**, Lisenda L, Khanduja V. Pseudoaneurysm of a branch of the femoral circumflex artery as a complication of revision arthroscopic release of the iliopsoas tendon. *SICOT J* 2017; **3**: 26 [PMID: [28322718](#) DOI: [10.1051/sicotj/2017012](#)]
- 19 **Seeley MA**, Georgiadis AG, Sankar WN. Hip Vascularity: A Review of the Anatomy and Clinical Implications. *J Am Acad Orthop Surg* 2016; **24**: 515-526 [PMID: [27428883](#) DOI: [10.5435/JAAOS-D-15-00237](#)]
- 20 **Manrique J**, Chen AF, Heller S, Hozack WJ. Direct anterior approach for revision total hip arthroplasty. *Ann Transl Med* 2014; **2**: 100 [PMID: [25405154](#) DOI: [10.3978/j.issn.2305-5839.2014.09.11](#)]
- 21 **Ochi H**, Baba T, Homma Y, Matsumoto M, Watari T, Ozaki Y, Kobayashi H, Kaneko K. Total hip

arthroplasty via the direct anterior approach with a dual mobility cup for displaced femoral neck fracture in patients with a high risk of dislocation. *SICOT J* 2017; **3**: 56 [PMID: [28984572](#) DOI: [10.1051/sicotj/2017048](#)]

- 22 **Tamaki T**, Oinuma K, Miura Y, Shiratsuchi H. Total hip arthroplasty through a direct anterior approach for fused hips. *Hip Int* 2015; **25**: 549-552 [PMID: [26449331](#) DOI: [10.5301/hipint.5000308](#)]





Published By Baishideng Publishing Group Inc  
7041 Koll Center Parkway, Suite 160, Pleasanton, CA 94566, USA  
Telephone: +1-925-2238242  
E-mail: [bpgoffice@wjgnet.com](mailto:bpgoffice@wjgnet.com)  
Help Desk: <https://www.f6publishing.com/helpdesk>  
<https://www.wjgnet.com>

