

World Journal of *Clinical Cases*

World J Clin Cases 2019 November 26; 7(22): 3683-3914



**REVIEW**

- 3683** Colorectal cancer: The epigenetic role of microbiome
Sabit H, Cevik E, Tombuloglu H

ORIGINAL ARTICLE**Case Control Study**

- 3698** Human podocyte injury in the early course of hypertensive renal injury
Sun D, Wang JJ, Wang W, Wang J, Wang LN, Yao L, Sun YH, Li ZL

Retrospective Cohort Study

- 3711** Relationship between acute hypercarbia and hyperkalaemia during surgery
Weinberg L, Russell A, Mackley L, Dunnachie C, Meyerov J, Tan C, Li M, Hu R, Karalapillai D

Retrospective Study

- 3718** Surgical treatment of patients with severe non-flail chest rib fractures
Zhang JP, Sun L, Li WQ, Wang YY, Li XZ, Liu Y
- 3728** Super-selective arterial embolization in the control of acute lower gastrointestinal hemorrhage
Ly LS, Gu JT
- 3734** End-stage liver disease score and future liver remnant volume predict post-hepatectomy liver failure in hepatocellular carcinoma
Kong FH, Miao XY, Zou H, Xiong L, Wen Y, Chen B, Liu X, Zhou JJ

Observational Study

- 3742** Treatment of hemorrhoids: A survey of surgical practice in Australia and New Zealand
Fowler GE, Siddiqui J, Zahid A, Young CJ
- 3751** Relationship between homocysteine level and prognosis of elderly patients with acute ischemic stroke treated by thrombolysis with recombinant tissue plasminogen activator
Li J, Zhou F, Wu FX

CASE REPORT

- 3757** Cystic fibrosis transmembrane conductance regulator functional evaluations in a G542X+/- IVS8Tn:T7/9 patient with acute recurrent pancreatitis
Caldrer S, Bergamini G, Sandri A, Vercellone S, Rodella L, Cerofolini A, Tomba F, Catalano F, Frulloni L, Buffelli M, Tridello G, de Jonge H, Assael BM, Sorio C, Melotti P

- 3765** Ulcerated intussuscepted jejunal lipoma-uncommon cause of obscure gastrointestinal bleeding: A case report
Cuciureanu T, Huiban L, Chiriac S, Singeap AM, Danciu M, Mihai F, Stanciu C, Trifan A, Vlad N
- 3772** Ultrasonographic evaluation of the effect of extracorporeal shock wave therapy on calcific tendinopathy of the rectus femoris tendon: A case report
Lee CH, Oh MK, Yoo JI
- 3778** Contrast-enhanced computed tomography findings of a huge perianal epidermoid cyst: A case report
Sun PM, Yang HM, Zhao Y, Yang JW, Yan HF, Liu JX, Sun HW, Cui Y
- 3784** Iatrogenic crystalline lens injury during intravitreal injection of triamcinolone acetonide: A report of two cases
Su J, Zheng LJ, Liu XQ
- 3792** Sagliker syndrome: A case report of a rare manifestation of uncontrolled secondary hyperparathyroidism in chronic renal failure
Yu Y, Zhu CF, Fu X, Xu H
- 3800** Pre-eclampsia with new-onset systemic lupus erythematosus during pregnancy: A case report
Huang PZ, Du PY, Han C, Xia J, Wang C, Li J, Xue FX
- 3807** Unilateral congenital scrotal agenesis with ipsilateral cryptorchidism: A case report
Fang Y, Lin J, Wang WW, Qiu J, Xie Y, Sang LP, Mo JC, Luo JH, Wei JH
- 3812** Metastatic infection caused by hypervirulent *Klebsiella pneumonia* and co-infection with *Cryptococcus meningitis*: A case report
Shi YF, Wang YK, Wang YH, Liu H, Shi XH, Li XJ, Wu BQ
- 3821** Allergic fungal rhinosinusitis accompanied by allergic bronchopulmonary aspergillosis: A case report and literature review
Cheng KJ, Zhou ML, Liu YC, Zhou SH
- 3832** Invasive aspergillosis presenting as hilar masses with stenosis of bronchus: A case report
Su SS, Zhou Y, Xu HY, Zhou LP, Chen CS, Li YP
- 3838** Retropharyngeal abscess presenting as acute airway obstruction in a 66-year-old woman: A case report
Lin J, Wu XM, Feng JX, Chen MF
- 3844** Thoracoscopic segmentectomy assisted by three-dimensional computed tomography bronchography and angiography for lung cancer in a patient living with situs inversus totalis: A case report
Wu YJ, Bao Y, Wang YL
- 3851** Single-lung transplantation for pulmonary alveolar microlithiasis: A case report
Ren XY, Fang XM, Chen JY, Ding H, Wang Y, Lu Q, Ming JL, Zhou LJ, Chen HW

- 3859** Respiratory failure and macrophage activation syndrome as an onset of systemic lupus erythematosus: A case report
Sun J, Wang JW, Wang R, Zhang H, Sun J
- 3866** Diagnosis of gastric duplication cyst by positron emission tomography/computed tomography: A case report
Hu YB, Gui HW
- 3872** Peritoneal cancer after bilateral mastectomy, hysterectomy, and bilateral salpingo-oophorectomy with a poor prognosis: A case report and review of the literature
Ma YN, Bu HL, Jin CJ, Wang X, Zhang YZ, Zhang H
- 3881** Apatinib for treatment of a pseudomyxoma peritonei patient after surgical treatment and hyperthermic intraperitoneal chemotherapy: A case report
Huang R, Shi XL, Wang YF, Yang F, Wang TT, Peng CX
- 3887** Novel frameshift mutation causes early termination of the thyroxine-binding globulin protein and complete thyroxine-binding globulin deficiency in a Chinese family: A case report
Dang PP, Xiao WW, Shan ZY, Xi Y, Wang RR, Yu XH, Teng WP, Teng XC
- 3895** Diffuse large B-cell lymphoma arising from follicular lymphoma with warthin's tumor of the parotid gland - immunophenotypic and genetic features: A case report
Wang CS, Chu X, Yang D, Ren L, Meng NL, Lv XX, Yun T, Cao YS
- 3904** Exogenous endophthalmitis caused by *Enterococcus casseliflavus*: A case report
Bao QD, Liu TX, Xie M, Tian X

LETTER TO THE EDITOR

- 3912** Microbial transglutaminase should be considered as an environmental inducer of celiac disease
Lerner A, Matthias T

ABOUT COVER

Editorial Board Member of *World Journal of Clinical Cases*, Ridvan Hamid Alimehmeti, MD, PhD, Associate Professor, Lecturer, Surgeon, Department of Neuroscience, University of Medicine, Tirana 1000, Albania

AIMS AND SCOPE

The primary aim of *World Journal of Clinical Cases* (WJCC, *World J Clin Cases*) is to provide scholars and readers from various fields of clinical medicine with a platform to publish high-quality clinical research articles and communicate their research findings online.

WJCC mainly publishes articles reporting research results and findings obtained in the field of clinical medicine and covering a wide range of topics, including case control studies, retrospective cohort studies, retrospective studies, clinical trials studies, observational studies, prospective studies, randomized controlled trials, randomized clinical trials, systematic reviews, meta-analysis, and case reports.

INDEXING/ABSTRACTING

The WJCC is now indexed in PubMed, PubMed Central, Science Citation Index Expanded (also known as SciSearch®), and Journal Citation Reports/Science Edition. The 2019 Edition of Journal Citation Reports cites the 2018 impact factor for WJCC as 1.153 (5-year impact factor: N/A), ranking WJCC as 99 among 160 journals in Medicine, General and Internal (quartile in category Q3).

RESPONSIBLE EDITORS FOR THIS ISSUE

Responsible Electronic Editor: Ji-Hong Liu

Proofing Production Department Director: Yun-Xiaojuan Wu

NAME OF JOURNAL

World Journal of Clinical Cases

ISSN

ISSN 2307-8960 (online)

LAUNCH DATE

April 16, 2013

FREQUENCY

Semimonthly

EDITORS-IN-CHIEF

Dennis A Bloomfield, Bao-Gan Peng, Sandro Vento

EDITORIAL BOARD MEMBERS

<https://www.wjnet.com/2307-8960/editorialboard.htm>

EDITORIAL OFFICE

Jin-Lei Wang, Director

PUBLICATION DATE

November 26, 2019

COPYRIGHT

© 2019 Baishideng Publishing Group Inc

INSTRUCTIONS TO AUTHORS

<https://www.wjnet.com/bpg/gerinfo/204>

GUIDELINES FOR ETHICS DOCUMENTS

<https://www.wjnet.com/bpg/GerInfo/287>

GUIDELINES FOR NON-NATIVE SPEAKERS OF ENGLISH

<https://www.wjnet.com/bpg/gerinfo/240>

PUBLICATION MISCONDUCT

<https://www.wjnet.com/bpg/gerinfo/208>

ARTICLE PROCESSING CHARGE

<https://www.wjnet.com/bpg/gerinfo/242>

STEPS FOR SUBMITTING MANUSCRIPTS

<https://www.wjnet.com/bpg/GerInfo/239>

ONLINE SUBMISSION

<https://www.f6publishing.com>

Exogenous endophthalmitis caused by *Enterococcus casseliflavus*: A case report

Qing-Dong Bao, Tai-Xiang Liu, Meng Xie, Xiang Tian

ORCID number: Qing-Dong Bao (0000-0002-8280-0540); Tai-Xiang Liu (0000-0003-0573-8349); Meng Xie (0000-0002-8498-2608); Xiang Tian (0000-0001-6858-731X).

Author contributions: Liu TX designed the study; Liu TX, Tian X and Bao QD contributed surgical treatment and collection of follow-up data; Bao QD wrote the paper; Xie M revised the manuscript; All authors read and approved the final manuscript.

Supported by National Natural Science Foundation of China, No. 81660169.

Informed consent statement: Consent was obtained from the patient for publication of this report and any accompanying images.

Conflict-of-interest statement: The authors declare that they have no conflicts of interest.

CARE Checklist (2016) statement: The authors have read the CARE Checklist (2016), and the manuscript was prepared and revised according to the CARE Checklist (2016).

Open-Access: This article is an open-access article which was selected by an in-house editor and fully peer-reviewed by external reviewers. It is distributed in accordance with the Creative Commons Attribution Non Commercial (CC BY-NC 4.0) license, which permits others to distribute, remix, adapt, build upon this work non-commercially, and license their derivative works

Qing-Dong Bao, Tai-Xiang Liu, Meng Xie, Xiang Tian, Department of Ophthalmology, Affiliated Hospital of Zunyi Medical University, Zunyi 563000, Guizhou Province, China

Corresponding author: Tai-Xiang Liu, MD, Professor, Department of Ophthalmology, Affiliated Hospital of Zunyi Medical University, 149 Dalian Road, Huichuan District, Zunyi 563000, Guizhou Province, China. 0852.ltx@163.com
Telephone: +86-18886205044

Abstract

BACKGROUND

Endophthalmitis caused by *Enterococci* is rare, and cases involving vancomycin-resistant enterococci are even rarer. We report the first case of *Enterococcus casseliflavus* endophthalmitis associated with injury caused by a pig. We also review reported cases of exogenous endophthalmitis caused by *Enterococcus casseliflavus* and discuss the clinical management and prognosis of this disease.

CASE SUMMARY

A 43-year-old man with no previous visual problems complained of endophthalmitis in his left eye following injury caused by a pig. Visual acuity was light perception and B-ultrasonography revealed vitreous opacities with retinal detachment. He was treated with intravitreal vancomycin and ceftazidime after refusing vitrectomy. However, the vitreous opacities and retinal detachment deteriorated and he underwent vitrectomy 5 d post-injury. Intraoperatively, advanced rhegmatogenous and tractional retinal detachment with proliferative vitreoretinopathy were observed. On postoperative day 5, vitreous cultures grew Gram-positive cocci identified as *Enterococcus casseliflavus*. A 2-wk course of intravenous ampicillin and dexamethasone was commenced. On postoperative day 14, visual acuity improved to hand movement. At 6 mo post-injury, visual acuity improved to 20/667, but optic atrophy was present.

CONCLUSION

Systemic administration of linezolid in the treatment of *Enterococcus casseliflavus* endophthalmitis can improve visual acuity. However, intravitreal amikacin should be considered despite concerns of toxicity when oral linezolid fails to prompt improvement.

Key words: Vancomycin-resistant; Enterococci; *Enterococcus casseliflavus* endophthalmitis; Treatment; Case report

©The Author(s) 2019. Published by Baishideng Publishing Group Inc. All rights reserved.

on different terms, provided the original work is properly cited and the use is non-commercial. See: <http://creativecommons.org/licenses/by-nc/4.0/>

Manuscript source: Unsolicited manuscript

Received: August 19, 2019

Peer-review started: August 19, 2019

First decision: September 23, 2019

Revised: October 13, 2019

Accepted: October 30, 2019

Article in press: October 30, 2019

Published online: November 26, 2019

P-Reviewer: Ahmed M, Kakaei F, Nowak MS

S-Editor: Dou Y

L-Editor: Webster JR

E-Editor: Liu MY



Core tip: The emergence of vancomycin-resistant enterococci endophthalmitis is of grave concern. To date, four cases of *Enterococcus casseliflavus* endophthalmitis have been reported in the literature. We describe the first case of *Enterococcus casseliflavus* endophthalmitis associated with injury caused by a pig and the treatment regimen. In addition, we review the literature and discuss the clinical management and prognosis of this disease.

Citation: Bao QD, Liu TX, Xie M, Tian X. Exogenous endophthalmitis caused by *Enterococcus casseliflavus*: A case report. *World J Clin Cases* 2019; 7(22): 3904-3911
URL: <https://www.wjgnet.com/2307-8960/full/v7/i22/3904.htm>
DOI: <https://dx.doi.org/10.12998/wjcc.v7.i22.3904>

INTRODUCTION

Exogenous endophthalmitis is often caused by penetrating eyeball injury, endophthalmic surgery, and penetrating bacteria of a corneal ulcer. The emergence of vancomycin-resistant enterococci (VRE) endophthalmitis is of grave concern. We report the first case of *Enterococcus casseliflavus* endophthalmitis associated with injury caused by a pig. On examination, the patient did not have an entry site for the bacterium. Bacterial endophthalmitis is difficult to treat, as virulent bacteria can damage the eye tissue in a short time, and infectious endophthalmitis often leads to loss of vision and even atrophy of the eyeball if not treated in time. If infection can be controlled in time, it may partly restore patient vision. Therefore, if endophthalmitis is suspected, effective treatment should be given as soon as possible^[1]. In addition, we also reviewed reported cases of exogenous endophthalmitis caused by *Enterococcus casseliflavus* and their clinical management and prognosis.

CASE PRESENTATION

Chief complaints

A healthy 43-year-old man presented with sudden swelling and pain in his left eye for one day, accompanied by visual impairment.

History of present illness

One day earlier while on his pig farm (Figure 1), he received a facial injury caused by a pig's tail. Approximately 6 h later, his left eye became painful, and 13 h after the initial injury he noted redness in the conjunctiva. He was taken to hospital the following day.

History of past illness

He had no history of systemic diseases, surgery, recent bacterial or viral infections, and no previous visual disorders. No iatrogenic operations had been performed in the previous year.

Physical examination

Following examination, it was found that his vision was 20/20 OD and light perception was OS. There were no abnormal extraocular movements and skin abrasions on his forehead. The left eye slit lamp examination showed a + 2 conjunctival chemical reaction and + 2 corneal edema without epithelial defects. The anterior chamber showed a fibrinoid response, accompanied by a 2 mm decrease intraocular pressure. Exudates had formed a film over the exposed surface of the anterior lens capsule in the pupillary area, resulting in an occluded pupil. His vitreous cavity was filled with purulent debris and the fundus could not be seen.

Laboratory examinations

The total number of leukocytes was $15 \times 10^9/L$. No abnormalities in biochemical tests, chest X-ray films and electrocardiography were observed.

Imaging examinations

Contact B-ultrasonography revealed vitreous opacities with retinal detachment (Figure 2A).



Figure 1 The pig farm environment.

FINAL DIAGNOSIS

Exogenous endophthalmitis.

TREATMENT

The patient refused to undergo vitrectomy. A vitreous specimen was examined by microbiological methods. At the same time, the patient was given intravitreal vancomycin 1 mg/0.1 mL and ceftazidime 2 mg/0.1 mL, plus intravenous cefuroxime sodium 2500 mg and dexamethasone 10 mg were administered. Topical 0.3% tobramycin and 0.1% dexamethasone were applied every 3 h, 1% atropine and 0.3% gatifloxacin twice a day, and 0.5% pranoprofen every 6 h.

OUTCOME AND FOLLOW-UP

Vitreous cultures were typically negative. Anterior segment inflammation decreased (Figure 3), but vitreous opacities and retinal detachment deteriorated (Figure 2B). The patient underwent left pars plana lensectomy, vitrectomy, peripheral iridectomy and silicone oil tamponade 5 d after the injury. During the operation, compact hyaluronitis and vasculitis had occurred in the short period between the injury and the operation, which covered the optic disc and blood vessels. After the vitreous debris was removed, advanced rhegmatogenous and tractional retinal detachment with proliferative vitreoretinopathy were found obscuring a retinal tear 3PD in size. On postoperative day 5, Gram-positive *Enterococcus casseliflavus* was grown in culture, which was sensitive to linezolid, ampicillin, streptomycin, gentamicin, tetracycline and penicillin, but resistant to vancomycin. Therefore ampicillin was injected intravenously at 2 g/4 h and dexamethasone 600 mg/d for 2 wk.

On postoperative day 14, visual acuity in the left eye improved to hand movement. At 6 mo post-injury, visual acuity improved to 20/667 (aphakic correction), but optic atrophy occurred.

DISCUSSION

Enterococcus casseliflavus is commonly found in the gastrointestinal tract of livestock, and in soil and plants^[2]. It is rarely associated with human infection. An exhaustive review of the literature showed that there are only 4 previously reported cases of microbiologically proven exogenous endophthalmitis caused by *Enterococcus casseliflavus* and this is the 5th such case^[2-5]. The salient clinical findings in these cases are summarized in Table 1.

Four previously healthy men presented with endophthalmitis of the left eye following outdoor activities. The affected left eye had direct or indirect contact with the gastrointestinal tract of livestock, soil or plants. Typical endophthalmitis symptoms can develop within a few hours to 1 d after injury. However, on slit-lamp examinations, three of the five cases had no entry site for the bacterium. Cataract, retinal detachment and other complications occurred in all 5 cases after vitrectomy. Patients with timely vitrectomy, systemic administration of linezolid and intravitreal

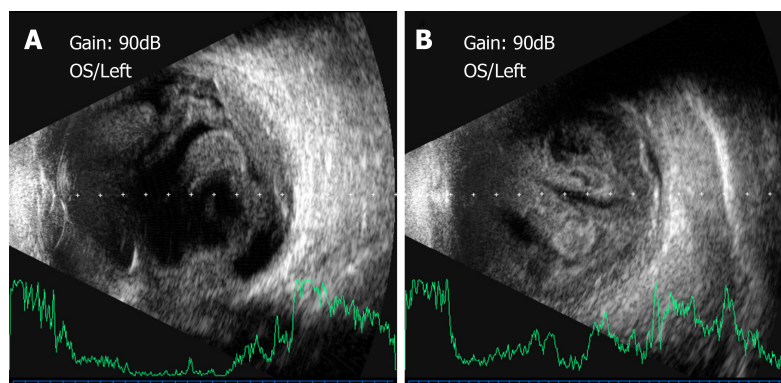


Figure 2 B-ultrasonography. A: Vitreous opacities with retinal detachment; B: Deteriorating vitreous opacities and retinal detachment.

amikacin had better visual acuity.

In the present case, the injury caused by the pig may have introduced the pathogen. *Enterococcus casseliflavus* is a common strain found on pig farms^[6] and the environment in the patient's farm was extremely harsh, leading to a high risk of infection. There was a chemical reaction in the conjunctiva, but slit lamp examination showed no obvious perforation. Damage caused by the pig's tail may have led to a self-sealing microperforation of the cornea or conjunctiva, which may explain how bacteria entered the eye. Similar case reports have been reported previously^[3,7,8].

It is reported that 15% to 40% of patients with exogenous endophthalmitis have visual acuity of 0.5 or more^[1]. The poor vision in our patient was due to the failure to perform timely vitrectomy. Vitrectomy is one of the preferred treatments for endophthalmitis, as it has the following advantages: Can clear vitreous infection, remove vitreous opacity, allows collection of intraocular specimens for culture, and better distribution of antibiotics in the vitreous cavity^[9]. However, our patient had no obvious pain symptoms and refused the operation, which caused irreparable damage.

Etiological examination is inefficient and interdisciplinary cooperation is poor in exogenous endophthalmitis. The present case did not demonstrate the importance of interdisciplinary medical care, and failed to initiate early and appropriate antimicrobial treatment using laboratory technology. It has been found that the negative rate of endophthalmitis bacterial culture is up to 30%^[10]. The combination of genetic diagnosis and polymerase chain reaction (PCR) detection can improve the detection rate of pathogens^[11]. Due to its high specificity and sensitivity, PCR has been used to confidently exclude pathogens, which is unique. However, PCR is easily contaminated in the laboratory; thus, it is currently only used to detect targeted microorganisms. The toxigenicity of cultured strains can be tested for drug sensitivity. Bacterial culture and molecular diagnostic tests should be carried out simultaneously to complement each other. Combining the use of an automated blood culture system with matrix-assisted laser desorption/ionization-time of flight mass spectrometry methodology, 45 strains of bacteria were isolated from vitreous specimens after acute endophthalmitis surgery, of which 96% were identified^[12].

Poor use of antibiotics in this disease can result in treatment failure, for example, ampicillin has poor penetration into the vitreous fluid. Studies have shown that ampicillin levels in vitreous fluid are about 2-log lower than those in serum following intravenous injection^[13]. There is concern regarding the use of aminoglycosides as they can cause retinal infarction. However, intravitreal injection of amikacin can reduce the incidence of macular infarction^[14]. In cases of traumatic exogenous vancomycin-resistant enterococcus endophthalmitis, intravitreal amikacin led to a good visual outcome.

CONCLUSION

Following rapid vitrectomy, it is important to understand the entry of antibiotics into the vitreous space to guide treatment. The treatment of endophthalmitis caused by *Enterococcus casseliflavus* is challenging, the ability of local and systemic antibiotics to enter the vitreous space is poor due to a reduced choice of antibiotics. Linezolid penetrates the vitreous chamber when administered orally or intravenously, the concentration of linezolid in the vitreous cavity was higher than the minimum inhibitory concentration of most enterococci^[15]. When linezolid was used systemically,

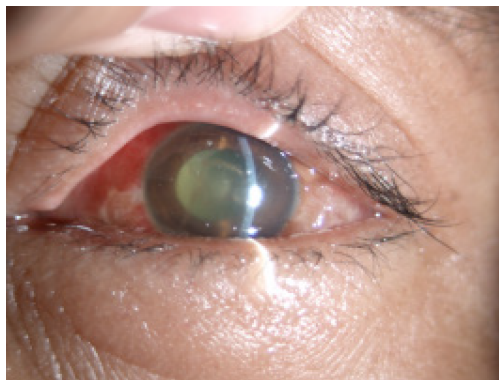


Figure 3 Slit-lamp examination showed reduced anterior segment inflammation.

the intravitreal concentration was higher than the lowest inhibitory concentration for VRE, and linezolid resistance in *Enterococcus* is rare. In the case of VRE endophthalmitis, intravitreal amikacin should be considered in the vitreous cavity as oral linezolid can produce toxicity and cannot quickly relieve symptoms.

Table 1 Summary of the findings in previously published cases of exogenous *Enterococcus casseliflavus* endophthalmitis

NO.	Author/ Yr	Age/Sex	Cause of injury	Time interval between injury and symp- toms	Eye	Visual acuity	Present- ing feature	Time interval between injury and vitrec- tomy	Treat- ment	Labora- tory diagno- sis	Disease progres- sion	Outcome
1	Khurana <i>et al</i> ^[2] , 2009	37/M	A horse tail injury	24 h	Left	PL	+2 conjunct- ival chemosis, +2 corneal edema, intact corneal epithe- lium, 1- mm hypopyon , dense vitritis	24 h	Vitrec- tomy; Intravit- real hydrochlo- -ride and ceftazi- dime	Vitreous; cultures	On post- operative day 7: The patient's pain and anterior segment inflamma- tion resolved. On post- operative day 21: Cataract and vitreous debris. On post- operative day 56: Vitrec- tomy; Retinal detach- ment with prolifera- tive vitreore- tinopathy	PL
2	Berenger <i>et al</i> ^[3] , 2015	6/M	High- velocity water stream trauma	2 h	Left	Not reported	Intact corneal epithe- lium, severe anterior chamber inflamma- tion, miosis and inferior hypopyon , vitreous opacities	26 h	Vitrec- tomy; Intravit- real hydrochlo- -ride and ceftazi- dime; Topical therapy: moxiflox- acin, predniso- lone, homatro- pine; Ciproflox- acin (PO); Vancom- ycin (IV)	Mass spectro- metry	On post- operative min 45: Vitrec- tomy; Intravit- real ampicillin and amikacin; Topical therapy: gentam- icin and predniso- lone; ampicillin, linezolid (IV). On post- operative day 7: Outer cortical vitreous separation . Over time, the vitreous cavity and anterior segment cleared	20/70

3	Nguyen <i>et al</i> ^[4] , 2017	6/M	An object projected from a lawn mower	Immediately	Left	HM	2 + conjunctival chemosis, chemosis temporarily, irregular iris, 4 + anterior chamber cells, 1 mm layered hypopyon, 1.5 mm hyphema	27 h	Vitrectomy; Intravitreal hydrochloride and ceftazidime; Subconjunctival injection: dexamethasone; Topical therapy: atropine, prednisolone acetate and moxifloxacin; Cephalexin (PO)	Vitreous cultures	On post-operative day 5: Topical therapy: tobramycin and linezolid; Linezolid (PO); On post-operative day 17: Vitrectomy; Intravitreal amikacin; On post-operative day 77: Phacoemulsification with intraocular lens placement and macula-sparing retinal detachment	20/40
4	Low <i>et al</i> ^[5] , 2015	54/M	Metallic intraocular foreign body	Immediately	Left	HM	Conjunctival chemosis, corneal edema, inferonasal corneal laceration with iris prolapse. The anterior chamber was shallow with a fibrinous reaction, 1.6-mm hypopyon	72 h	Vitrectomy; Intravitreal vancomycin and ceftazidime; Topical therapy: cefazolin, gentamicin, and atropine		Amoxicillin, linezolid, gentamicin (IV), amoxicillin (PO)	6/90
5	Present case	47/M		6 h	Left	PL	+2 conjunctival chemosis, +2 corneal edema, intact corneal epithelium, 2-mm hypopyon, vitreous opacities, retinal detachment	120 h	Vitrectomy; Intravitreal hydrochloride and ceftazidime; Topical therapy: Tobramycin, dexamethasone, atropine, gatifloxacin, pranop- rofen, dexamethasone (IV)	Vitreous cultures	Intravenous dexamethasone (IV); On post-operative day 2: optic atrophy	20/667

Only cultures that grew identifiable organisms are mentioned here. IV: Intravenous; PO: Per Os/oral administration; PL: Perception of light; HM: Hand

movement.

REFERENCES

- 1 **Vaziri K**, Schwartz SG, Kishor K, Flynn HW. Endophthalmitis: state of the art. *Clin Ophthalmol* 2015; **9**: 95-108 [PMID: [25609911](#) DOI: [10.2147/OPTH.S76406](#)]
- 2 **Khurana RN**, Leder HA, Nguyen QD, Do DV. Enterococcus casseliflavus endophthalmitis associated with a horse tail injury. *Arch Ophthalmol* 2009; **127**: 1551-1552 [PMID: [19901232](#) DOI: [10.1001/archophthalmol.2009.282](#)]
- 3 **Berenger BM**, Kulkarni S, Hinz BJ, Forgie SE. Exogenous endophthalmitis caused by Enterococcus casseliflavus: A case report and discussion regarding treatment of intraocular infection with vancomycin-resistant enterococci. *Can J Infect Dis Med Microbiol* 2015; **26**: 330-332 [PMID: [26744592](#) DOI: [10.1155/2015/784910](#)]
- 4 **Nguyen J**, Hartnett ME. Successful management of post-traumatic vancomycin-resistant enterococcus endophthalmitis. *Am J Ophthalmol Case Rep* 2017; **5**: 117-118 [PMID: [28848938](#) DOI: [10.1016/j.ajoc.2016.12.022](#)]
- 5 **Low JR**, Teoh CS, Chien JM, Huang EH. Enterococcus casseliflavus endophthalmitis due to metallic intraocular foreign body. *Eye (Lond)* 2015; **29**: 840-841 [PMID: [25657040](#) DOI: [10.1038/eye.2014.332](#)]
- 6 **Kühn I**, Iversen A, Burman LG, Olsson-Liljequist B, Franklin A, Finn M, Aarestrup F, Seyfarth AM, Blanch AR, Vilanova X, Taylor H, Caplin J, Moreno MA, Dominguez L, Herrero IA, Möllby R. Comparison of enterococcal populations in animals, humans, and the environment--a European study. *Int J Food Microbiol* 2003; **88**: 133-145 [PMID: [14596986](#) DOI: [10.1016/s0168-1605\(03\)00176-4](#)]
- 7 **Al-Khatib TK**, Al-Khulaidi NA. Traumatic subconjunctival crystalline lens. Dislocation by the tail of a cow. *Saudi Med J* 2004; **25**: 2018-2019 [PMID: [15711691](#) DOI: [10.1016/S0886-3350\(03\)00332-8](#)]
- 8 **Chaddah MR**, Ahluwalia BK. A rare intraocular foreign body; hair from buffalo's tail. *J All India Ophthalmol Soc* 1968; **16**: 251-252 [PMID: [5754268](#) DOI: [10.3923/javaa.2011.987.990](#)]
- 9 **Flynn HW**, Scott IU. Legacy of the endophthalmitis vitrectomy study. *Arch Ophthalmol* 2008; **126**: 559-561 [PMID: [18413530](#) DOI: [10.1001/archophth.126.4.559](#)]
- 10 **Durand ML**. Endophthalmitis. *Clin Microbiol Infect* 2013; **19**: 227-234 [PMID: [23438028](#) DOI: [10.1111/1469-0691.12118](#)]
- 11 **Faigenbaum SJ**, Boyle GL, Prywes AS, Abel R, Leopold IH. Intraocular penetrating of amoxicillin. *Am J Ophthalmol* 1976; **82**: 598-603 [PMID: [970423](#) DOI: [10.1016/0002-9394\(76\)90548-1](#)]
- 12 **Mailhac A**, Durand H, Boisset S, Maubon D, Berger F, Maurin M, Chiquet C, Bidart M. MALDI-TOF mass spectrometry for rapid diagnosis of postoperative endophthalmitis. *J Proteomics* 2017; **152**: 150-152 [PMID: [27989942](#) DOI: [10.1016/j.jprot.2016.10.017](#)]
- 13 **Röber H**, Göring W, Sous H, Reim M. Concentration of ampicillin in the vitreous after cryocoagulation. *Albrecht Von Graefes Arch Klin Exp Ophthalmol* 1977; **204**: 275-280 [PMID: [304686](#) DOI: [10.1007/bf00415321](#)]
- 14 **D'Amico DJ**, Caspers-Velu L, Libert J, Shanks E, Schrooyen M, Hanninen LA, Kenyon KR. Comparative toxicity of intravitreal aminoglycoside antibiotics. *Am J Ophthalmol* 1985; **100**: 264-275 [PMID: [4025468](#) DOI: [10.1016/0002-9394\(85\)90792-5](#)]
- 15 **Horcajada JP**, Atienza R, Sarasa M, Soy D, Adán A, Mensa J. Pharmacokinetics of linezolid in human non-inflamed vitreous after systemic administration. *J Antimicrob Chemother* 2009; **63**: 550-552 [PMID: [19109336](#) DOI: [10.1093/jac/dkn516](#)]



Published By Baishideng Publishing Group Inc
7041 Koll Center Parkway, Suite 160, Pleasanton, CA 94566, USA
Telephone: +1-925-2238242
E-mail: bpgoffice@wjgnet.com
Help Desk: <https://www.f6publishing.com/helpdesk>
<https://www.wjgnet.com>

