

World Journal of *Clinical Cases*

World J Clin Cases 2019 December 26; 7(24): 4172-4425



**REVIEW**

- 4172** Polyunsaturated fatty acids and DNA methylation in colorectal cancer
Moradi Sarabi M, Mohammadrezaei Khorramabadi R, Zare Z, Eftekhar E

ORIGINAL ARTICLE**Retrospective Study**

- 4186** Impact of resection margins on long-term survival after pancreaticoduodenectomy for pancreatic head carcinoma
Li CG, Zhou ZP, Tan XL, Gao YX, Wang ZZ, Liu Q, Zhao ZM
- 4196** Arthroscopy combined with unicondylar knee arthroplasty for treatment of isolated unicompartmental knee arthritis: A long-term comparison
Wang HR, Li ZL, Li J, Wang YX, Zhao ZD, Li W
- 4208** Intact, pie-crusting and repairing the posterior cruciate ligament in posterior cruciate ligament-retaining total knee arthroplasty: A 5-year follow-up
Ma DS, Wen L, Wang ZW, Zhang B, Ren SX, Lin Y
- 4218** Community-acquired pneumonia complicated by rhabdomyolysis: A clinical analysis of 11 cases
Zhao B, Zheng R

Clinical Trials Study

- 4226** Dissection and ligation of the lateral circumflex femoral artery is not necessary when using the direct anterior approach for total hip arthroplasty
Zhao GY, Wang YJ, Xu NW, Liu F

Observational Study

- 4234** Expression of interleukin-32 in bone marrow of patients with myeloma and its prognostic significance
Wang G, Ning FY, Wang JH, Yan HM, Kong HW, Zhang YT, Shen Q

Randomized Controlled Trial

- 4245** Effect of different types of laryngeal mask airway placement on the right internal jugular vein: A prospective randomized controlled trial
Zhang JJ, Qu ZY, Hua Z, Zuo MZ, Zhang HY

SYSTEMATIC REVIEW

- 4254** Chronic pain, posttraumatic stress disorder, and opioid intake: A systematic review
López-Martínez AE, Reyes-Pérez Á, Serrano-Ibáñez ER, Esteve R, Ramírez-Maestre C

CASE REPORT

- 4270 Acute appendicitis in a patient after a uterus transplant: A case report
Kristek J, Kudla M, Chlupac J, Novotny R, Mirejovsky T, Janousek L, Fronek J
- 4277 Pneumococcal infection transmission between family members with congenital asplenia: A case report
Shibata J, Hiramatsu K, Kenzaka T, Kato T
- 4285 Successful treatment of warfarin-induced skin necrosis using oral rivaroxaban: A case report
Kamada M, Kenzaka T
- 4292 Simultaneous *Paragonimus* infection involving the breast and lung: A case report
Oh MY, Chu A, Park JH, Lee JY, Roh EY, Chai YJ, Hwang KT
- 4299 Isolated peritoneal lymphomatosis defined as post-transplant lymphoproliferative disorder after a liver transplant: A case report
Kim HB, Hong R, Na YS, Choi WY, Park SG, Lee HJ
- 4307 Three-dimensional image simulation of primary diaphragmatic hemangioma: A case report
Chu PY, Lin KH, Kao HL, Peng YJ, Huang TW
- 4314 Natural orifice specimen extraction with laparoscopic radical gastrectomy for distal gastric cancer: A case report
Sun P, Wang XS, Liu Q, Luan YS, Tian YT
- 4321 Huge brown tumor of the rib in an unlocatable hyperparathyroidism patient with “self-recovered” serum calcium and parathyroid hormone: A case report
Wang WD, Zhang N, Qu Q, He XD
- 4327 Percutaneous management of atrium and lung perforation: A case report
Zhou X, Ze F, Li D, Li XB
- 4334 Epstein-Barr virus-positive post-transplant lymphoproliferative disorder presenting as hematochezia and enterobrosis in renal transplant recipients in China: A report of two cases
Sun ZJ, Hu XP, Fan BH, Wang W
- 4342 Postoperative multidrug-resistant *Acinetobacter baumannii* meningitis successfully treated with intravenous doxycycline and intraventricular gentamicin: A case report
Wu X, Wang L, Ye YZ, Yu H
- 4349 Reconstruction of massive skin avulsion of the scrota and penis by combined application of dermal regeneration template (Pelnac) and split-thickness skin graft with vacuum-assisted closure: A case report
Fang JJ, Li PF, Wu JJ, Zhou HY, Xie LP, Lu H

- 4355** Multisystem smooth muscle dysfunction syndrome in a Chinese girl: A case report and review of the literature
Chen SN, Wang YQ, Hao CL, Lu YH, Jiang WJ, Gao CY, Wu M
- 4366** Kidney inflammatory myofibroblastic tumor masquerading as metastatic malignancy: A case report and literature review
Zhang GH, Guo XY, Liang GZ, Wang Q
- 4377** Hydroxychloroquine-induced renal phospholipidosis resembling Fabry disease in undifferentiated connective tissue disease: A case report
Wu SZ, Liang X, Geng J, Zhang MB, Xie N, Su XY
- 4384** Spontaneous ovarian hyperstimulation syndrome: Report of two cases
Gui J, Zhang J, Xu WM, Ming L
- 4391** Castleman disease in the hepatic-gastric space: A case report
Xu XY, Liu XQ, Du HW, Liu JH
- 4398** KIT and platelet-derived growth factor receptor α wild-type gastrointestinal stromal tumor associated with neurofibromatosis type 1: Two case reports
Kou YW, Zhang Y, Fu YP, Wang Z
- 4414** Isolated elevated aspartate aminotransferase in an asymptomatic woman due to macro-aspartate aminotransferase: A case report
Zhan MR, Liu X, Zhang MY, Niu JQ
- 4420** Rehabilitation of anterior pituitary dysfunction combined with extrapontine myelinolysis: A case report
Yang MX, Chen XN

ABOUT COVER

Editorial Board Member of *World Journal of Clinical Cases*, Ashu Seith Bhalla, MD, Professor, Department of Radiodiagnosis, All India Institute of Medical Sciences, New Delhi 110029, India

AIMS AND SCOPE

The primary aim of *World Journal of Clinical Cases* (WJCC, *World J Clin Cases*) is to provide scholars and readers from various fields of clinical medicine with a platform to publish high-quality clinical research articles and communicate their research findings online.

WJCC mainly publishes articles reporting research results and findings obtained in the field of clinical medicine and covering a wide range of topics, including case control studies, retrospective cohort studies, retrospective studies, clinical trials studies, observational studies, prospective studies, randomized controlled trials, randomized clinical trials, systematic reviews, meta-analysis, and case reports.

INDEXING/ABSTRACTING

The WJCC is now indexed in PubMed, PubMed Central, Science Citation Index Expanded (also known as SciSearch®), and Journal Citation Reports/Science Edition. The 2019 Edition of Journal Citation Reports cites the 2018 impact factor for WJCC as 1.153 (5-year impact factor: N/A), ranking WJCC as 99 among 160 journals in Medicine, General and Internal (quartile in category Q3).

RESPONSIBLE EDITORS FOR THIS ISSUE

Responsible Electronic Editor: Ji-Hong Liu

Proofing Production Department Director: Yun-Xiaojuan Wu

NAME OF JOURNAL

World Journal of Clinical Cases

ISSN

ISSN 2307-8960 (online)

LAUNCH DATE

April 16, 2013

FREQUENCY

Semimonthly

EDITORS-IN-CHIEF

Dennis A Bloomfield, Bao-Gan Peng, Sandro Vento

EDITORIAL BOARD MEMBERS

<https://www.wjnet.com/2307-8960/editorialboard.htm>

EDITORIAL OFFICE

Jin-Lei Wang, Director

PUBLICATION DATE

December 26, 2019

COPYRIGHT

© 2019 Baishideng Publishing Group Inc

INSTRUCTIONS TO AUTHORS

<https://www.wjnet.com/bpg/gerinfo/204>

GUIDELINES FOR ETHICS DOCUMENTS

<https://www.wjnet.com/bpg/GerInfo/287>

GUIDELINES FOR NON-NATIVE SPEAKERS OF ENGLISH

<https://www.wjnet.com/bpg/gerinfo/240>

PUBLICATION MISCONDUCT

<https://www.wjnet.com/bpg/gerinfo/208>

ARTICLE PROCESSING CHARGE

<https://www.wjnet.com/bpg/gerinfo/242>

STEPS FOR SUBMITTING MANUSCRIPTS

<https://www.wjnet.com/bpg/GerInfo/239>

ONLINE SUBMISSION

<https://www.f6publishing.com>

Isolated peritoneal lymphomatosis defined as post-transplant lymphoproliferative disorder after a liver transplant: A case report

Hong Beum Kim, Ran Hong, Yung Sub Na, Woo Young Choi, Sang Gon Park, Hee Jeong Lee

ORCID number: Hong Beum Kim (0000-0001-9434-0708); Ran Hong (0000-0001-7011-5215); Yung Sub Na (0000-0003-2506-2673); Woo Young Choi (0000-0001-8849-1569); Sang-Gon Park (0000-0001-5816-0726); Hee Jeong Lee (0000-0001-8295-6097).

Author contributions: Kim HB were the major contributors in writing the manuscript; Na YS and Choi WY advised the manuscript; Park SG and Lee HJ were involved in drafting, writing and editing the manuscript; Lee HJ reviewed the manuscript as corresponding author; All authors read and approved the final manuscript.

Supported by the National Research Foundation of Korea, No. NRF-2017R1C1B5076793.

Informed consent statement: Written informed consent was obtained from the patient for publication of this case report and any accompanying images.

Conflict-of-interest statement: The authors declare no conflict-of-interest.

CARE Checklist (2016) statement: The manuscript was prepared and revised according to the CARE Checklist (2016).

Open-Access: This article is an open-access article which was selected by an in-house editor and fully peer-reviewed by external reviewers. It is distributed in accordance with the Creative Commons Attribution Non Commercial (CC BY-NC 4.0) license, which permits others to

Hong Beum Kim, Department of Premedical Course, Chosun University School of Medicine, Gwangju 501-717, South Korea

Ran Hong, Department of Pathology, Chosun University Hospital, 365 Pilmun-daero, Dong-gu, Gwangju 501-717, South Korea

Yung Sub Na, Department of Internal Medicine, Pulmonology, Chosun University Hospital, Gwangju 501-717, South Korea

Woo Young Choi, Department of Plastic and Reconstructive Surgery, Chosun University Hospital, Gwangju 501-717, South Korea

Sang Gon Park, Hee Jeong Lee, Department of Internal Medicine, Hemato-oncology, Chosun University Hospital, Gwangju 501-717, South Korea

Hee Jeong Lee, MD, PhD, Department of HematoOncology, Chosun University Hospital, 365 Pilmun-daero, Dong-gu, Gwangju 501-717, South Korea

Corresponding author: Hee Jeong Lee, MD, PhD, Assistant Professor, Doctor, Department of HematoOncology, Chosun University Hospital, 365 Pilmun-daero, Dong-gu, Gwangju 501-717, South Korea. hjangel21c@hanmail.net

Telephone: +82-62-2203984

Fax: +82-62-2349653

Abstract

BACKGROUND

Post-transplant lymphoproliferative disorder (PTLD) is a fatal complication of solid organ transplantation or allogeneic hematopoietic stem cell transplantation that is associated with immunosuppressive therapy. Potential manifestations are diverse, ranging from reactive lymphoid hyperplasia to high-grade lymphoma. PTLD is usually of B-cell origin and associated with Epstein-Barr virus (EBV) infection. Herein, we describe a case of PTLD involving the peritoneal omentum. There has been only case of PTLD as a diffuse large B-cell lymphoma (DLBCL) in the peritoneum.

CASE SUMMARY

The patient was a 62-year-old man who had been receiving immunosuppressive therapy with tacrolimus since undergoing a liver transplant 15 years prior. He reported that he had experienced abdominal discomfort and anorexia 1 month prior to the current admission. Abdominal pelvic computed tomography (CT) revealed peritoneal and omental mass-like lesions without bowel obstruction. Ultrasonography-guided biopsy was performed, and he was histologically

distribute, remix, adapt, build upon this work non-commercially, and license their derivative works on different terms, provided the original work is properly cited and the use is non-commercial. See: <http://creativecommons.org/licenses/by-nc/4.0/>

Manuscript source: Unsolicited manuscript

Received: October 7, 2019

Peer-review started: October 7, 2019

First decision: October 23, 2019

Revised: October 31, 2019

Accepted: November 15, 2019

Article in press: November 15, 2019

Published online: December 26, 2019

P-Reviewer: Nacif L, Shrestha B, Sun WB

S-Editor: Ma YJ

L-Editor: A

E-Editor: Liu JH



diagnosed with EBV-negative DLBCL. Positron emission tomography (PET)-CT depicted peritoneum and omentum involvement only, without any lymphadenopathy or organ masses, including in the gastrointestinal tract. Six cycles of chemotherapy with a "R-CHOP" regimen (rituximab-cyclophosphamide, doxorubicin, vincristine, prednisolone) were administered, and PET-CT performed thereafter indicated complete remission.

CONCLUSION

This is the first report of isolated peritoneal lymphomatosis defined as PTLTD in a liver transplant recipient.

Key words: Case report; Diffuse large B-cell lymphoma; Epstein-Barr virus infection; Posttransplant lymphoproliferative disorder; R-CHOP; Isolated peritoneal lymphomatosis

©The Author(s) 2019. Published by Baishideng Publishing Group Inc. All rights reserved.

Core tip: Post-transplant lymphoproliferative disorder (PTLD) is a fatal complication of solid organ transplantation or allogeneic hematopoietic stem cell transplantation that is associated with immunosuppressive therapy. Herein we present the first report of isolated peritoneal lymphomatosis defined as PTLTD in a liver transplant recipient.

Citation: Kim HB, Hong R, Na YS, Choi WY, Park SG, Lee HJ. Isolated peritoneal lymphomatosis defined as post-transplant lymphoproliferative disorder after a liver transplant: A case report. *World J Clin Cases* 2019; 7(24): 4299-4306

URL: <https://www.wjgnet.com/2307-8960/full/v7/i24/4299.htm>

DOI: <https://dx.doi.org/10.12998/wjcc.v7.i24.4299>

INTRODUCTION

Post-transplant lymphoproliferative disorder (PTLD) is a fatal disease that occurs in patients who have undergone solid organ transplantation and allogeneic hematopoietic stem cell transplantation. Its incidence varies depending on the organ transplanted, and after liver transplantation the incidence of PTLTD is approximately 1.0%–5.5%^[1,2]. Epstein-Barr virus (EBV) infection is known to be the most common etiology. It is typically classified into four histologic types; early lesion, polymorphic, monomorphic, and Hodgkin-like, and it can also be categorized as early-onset (< 2 years) or late-onset (≥ 2 years)^[3-5]. PTLTD in the form of extranodal lymphoma is slightly more common than other forms, and the gastrointestinal tract, transplanted organs, and central nervous system are the most frequently affected sites^[2,6-9]. To date, no cases of peritoneal lymphomatosis have been reported.

Herein, we describe the case of a patient with diffuse large B-cell lymphoma (DLBCL) constituting late-onset monomorphic PTLTD, which developed 15 years after a liver transplant. The case involved isolated peritoneal lymphomatosis, which has never been reported in the context of PTLTD, and complete remission was achieved *via* chemotherapy.

CASE PRESENTATION

Chief complaints

A 62-year-old man was admitted due to reduced appetite and abdominal distension, which he had reportedly been experiencing for the last month.

History

The patient had been followed up regularly since undergoing a liver transplant 15 years prior due to fulminant hepatic failure associated with hepatitis B, and he had been taking tacrolimus 2 mg regularly since that transplant. He had been taking linagliptin and metformin for the past 10 years due to diabetes mellitus. Abdominopelvic computed tomography (CT) had been conducted 6 months prior to the current presentation as part of a periodic check-up, and it had not depicted any abnormal findings. He had developed abdominal discomfort 1 month prior to the

current admission, and 2 weeks after its initial onset he developed abdominal distension that was so severe that he could not eat. He then visited the hospital for testing.

Physical examination upon admission

There was no tenderness upon abdominal palpation but distension was severe, with fluid wave and shifting dullness indicating ascites.

Laboratory examinations

Complete blood count results were as follows, with normal ranges in parentheses: white blood cells $2.1 \times 10^3/\mu\text{L}$ (4.0–10.0 $10^3/\mu\text{L}$), hemoglobin 13.8 g/dL (12–16 g/dL), platelets $318 \times 10^3/\mu\text{L}$ (150–400 $10^3/\mu\text{L}$). Blood biochemistry results were total bilirubin 0.6 mg/dL (0.2–1.1 mg/dL), aspartate aminotransferase 21 U/L (5–40 U/L), alanine aminotransferase 9 U/L (5–40 U/L), albumin 3.7 g/dL (3.5–5.2 g/dL), blood urea nitrogen 14.4 mg/dL (8.0–20.0 mg/dL), creatinine 0.9 mg/dL (0.5–1.3 mg/dL), C-reactive protein 10.8 mg/dL (0.0–0.5 mg/dL). Among the tumor markers tested for, carcinoembryonic antigen was normal (1.3 ng/mL; normal range 0.0–5.0 ng/mL) but lactate dehydrogenase was elevated (746 U/L; normal range 200–450 U/L).

Imaging examinations

Abdominopelvic CT depicted diffuse peritoneal thickening, omental masses and nodules, and ascites with omental fat infiltration, but no mass-like lesions or bowel obstruction were evident in the gastrointestinal tract (Figure 1). A primary peritoneal disease such as tuberculous peritonitis or malignant mesothelioma was suspected. Positron emission tomography (PET)-CT was performed, and it did not depict abnormal hypermetabolism in solid organs, lymph nodes, or digestive organs but it did reveal diffuse hypermetabolism in the peritoneum and omentum (Figure 2).

FINAL DIAGNOSIS

Histological examination was performed on the omental mass using a percutaneous ultrasonography guided core needle, and the mass was definitively diagnosed as DLBCL that was positive for CD20, CD45, and B-cell lymphoma 6, and negative for CD3 and cytokeratin (Figure 3). Other tissue markers were negative for EBV and human herpesvirus 8 (HHV-8). Serum EBV PCR was negative as was serum EBV viral capsid IgM testing, indicating that manifest EBV infection was not present. Serum EBV viral capsid IgG testing was positive. Hepatitis B antigen testing was negative, hepatitis B antibody testing was positive, and hepatitis C antibody testing was negative. Based on these results, the patient was diagnosed with DLBCL as an EBV-negative monomorphic PTLT that had developed 15 years after a liver transplant. The condition was further classified as an isolated peritoneal stage IIE DLBCL with lymph node infiltration but no bone marrow or other solid organ infiltration. The International Prognostic Index score was in the intermediate-low-risk group, as the patient was 62 years of age with elevated lactate dehydrogenase.

TREATMENT

The dosage of tacrolimus, an immunosuppressor, should be reduced in patients with PTLT, but he did not want to reduce the dose of the tacrolimus; the tacrolimus level was maintained at a slightly low level of 4. Two cycles of an “RCHOP” (rituximab-cyclophosphamide, doxorubicin, vincristine, prednisolone) regimen, the standard treatment for DLBCL, were administered without a dosage reduction. While on chemotherapy diabetes was not controlled, so response evaluation was performed *via* CT. CT depicted marked peritoneal mass reduction, indicating a partial response, so 6 cycles were administered without dosage reduction. Subsequent CT scanning did not depict any signs of omental mass or ascites, but there was still mild haziness in the omental fat (Figure 1). PET-CT following an aggressive diabetes management regimen indicated complete remission, with loss of diffuse hypermetabolism lesion in the peritoneum (Figure 2).

OUTCOME AND FOLLOW-UP

Although PET-CT suggested complete remission, CT was performed 2 mo later to monitor the previously observed mild haziness on omentum fat. The haziness had

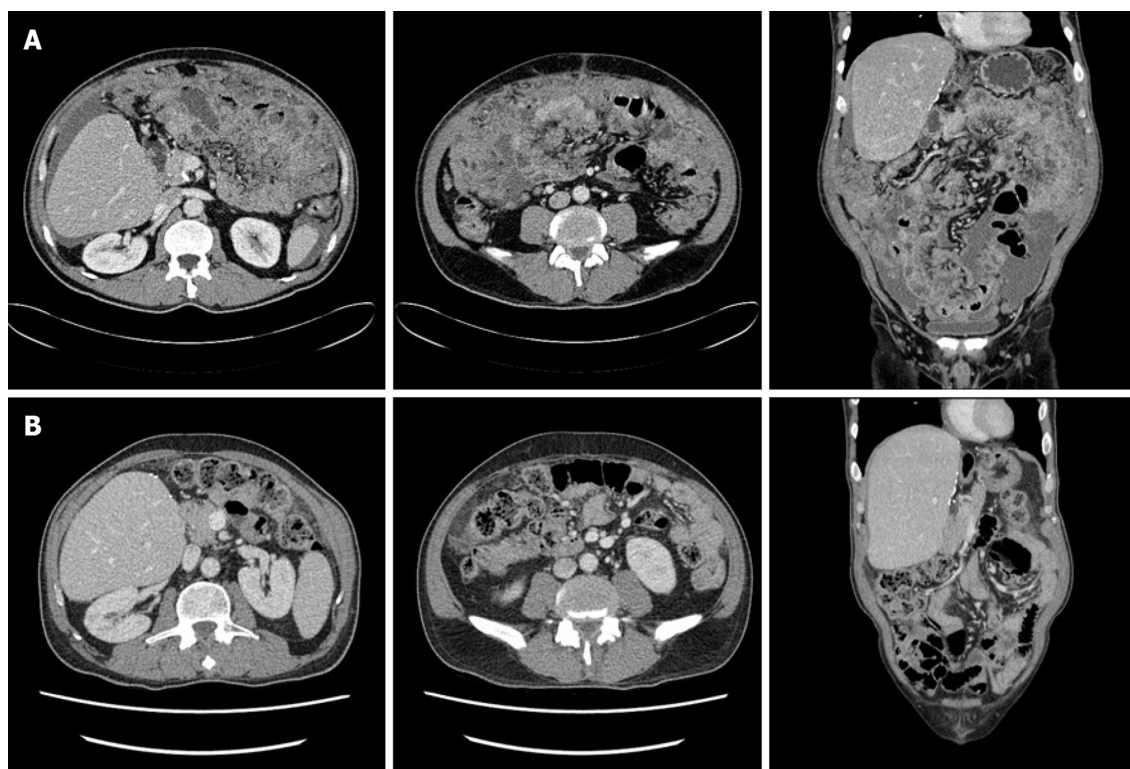


Figure 1 Abdominopelvic computed tomography. A: Computed tomography (CT) depicting a large volume of ascites and diffuse peritoneal infiltrative lesions at the mesentery and omentum, but no mass-like lesions in the gastrointestinal tract and no bowel obstruction; B: Post-chemotherapy CT depicting no signs of omental mass or ascites, but mild haziness in the omental fat.

reduced, suggesting that the omentum was undergoing a healing process. The patient currently remains under observation.

DISCUSSION

PTLD is defined as a lymphoma that develops after solid organ or hematopoietic stem cell transplantation. Since some researchers reported five cases of PTLD as a severe complication of transplantation in 1966, the incidence of PTLD has risen in conjunction with an exponential increase in the number of transplants performed. Although the incidence varies depending on the organ transplanted and the use of immunosuppressors, the incidence of PTLD in cases of liver transplantation is approximately 1.0%–5.5%^[1,2]. Of the four pathological types, monomorphic PTLD exhibits the typical characteristics of a malignant lymphoma. DLBCL is the most common, followed by Burkitt lymphoma and aggressive T-cell lymphoma^[10].

Approximately 50%–70% of PTLD cases are early-onset, more than 80% of these early onset cases are of B-cell origin, and more than 90% are EBV-positive^[4,11–13]. Conversely, EBV-negativity is more common in cases of late-onset PTLD^[14]. EBV-induced pathogenesis of PTLD is relatively well known. With immunosurveillance by T lymphocytes diminished *via* immunosuppressors, which are used to prevent rejection responses in transplant recipients, primary infection or reactivation of EBV may thwart regulation of the proliferation of transformed B-cells, ultimately causing PTLD^[15,16].

The mechanisms involved in EBV-negative PTLD remain unclear. The “hit and run” hypothesis suggests that EBV infection occurs but is then lost after causing PTLD^[17,18]. Some reports suggest that other viruses such as HHV-8, hepatitis B virus, hepatitis C virus, and cytomegalovirus may be causative, and some reports note that PTLD can have similar characteristics to p53 mutation lymphoma^[19–23]. The manifestation of PTLD varies widely, from asymptomatic to fulminant onset. Extranodal lymphoma is relatively common, and the gastrointestinal tract (20%–30%), transplanted organ (10%–15%), and central nervous system (5%–20%) are commonly affected^[2,6–9]. To date however, there have been no reports of primary peritoneal onset as was observed in the present case.

PTLD has a poorer prognosis than malignant lymphoma, and the 5-year survival

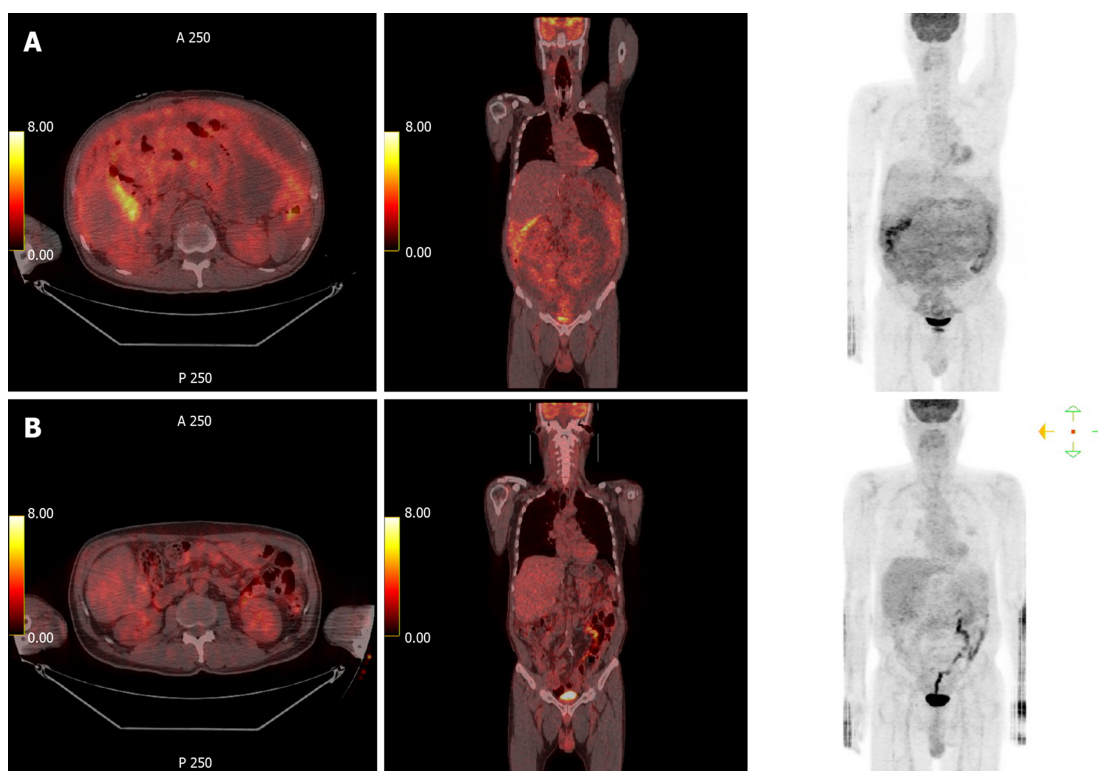


Figure 2 Positron emission tomography-computed tomography. A: Positron emission tomography (PET)-computed tomography (CT) did not depict abnormal hypermetabolism in solid organs, lymph nodes, or digestive organs, but it did depict diffuse hypermetabolism in the peritoneum and omentum; B: Post-chemotherapy PET-CT depicted loss of diffuse hypermetabolic lesion in the peritoneum.

rate of DLBCL as a PTLD is approximately 40%–60%^[2,9,24]. It is not clear whether the prognosis of malignant lymphoma that develops as PTLD is poor or whether transplant recipients' underlying disease and reduced organ function and infection due to immunosuppressors are the main problems, but the International Prognostic Index score is evidently an important prognostic factor^[2,25,26].

For PTLD treatment, lowering the dose of immunosuppressors is suggested in most cases if it has not manifested as an EBV-related aggressive lymphoma, but in practice, this is difficult. It has been reported that rituximab therapy alone can be effective in DLBCL, but the R-CHOP regimen is still considered the standard treatment; thus, further research is warranted^[27,28].

It is known that malignant lymphoma can develop in any part of the body, but malignant lymphomas that involve the omentum or peritoneum are very rare^[29]. Peritoneal lymphomatosis progresses in a manner similar to peritoneal cancer metastasis, where peritoneal thickening with malignant ascites and diffuse infiltration of omental fat-known as omental cake-are observed and the patient complains of severe abdominal discomfort and distension. Usually high-grade malignant lymphoma severely infiltrates the gastrointestinal tract or abdominal lymph node and the peritoneum, but isolated peritoneal lymphomatosis that is restricted to the peritoneum and omentum without involving other gastrointestinal organs is very rare, with no such cases reported as a PTLD to date^[30-34]. Thus, there are no data available on the likely prognosis of the present patient.

Some potentially relevant observations pertaining to therapeutic effects and prognoses of primary effusion lymphoma, a body cavity-based lymphoma, may warrant consideration. Primary effusion lymphoma is a rare but officially acknowledged DLBCL in the WHO classification system that specifically occurs in the serosal surface of the pleura or pericardium in the body cavity^[35]. HHV-8, which occurs as a result of human immunodeficiency virus infection, is known to be the major cause of primary effusion lymphoma but it commonly affects patients receiving immunosuppressant therapy after a transplant^[36]. Given the growing number of reports of HHV-8-negative primary effusion lymphoma, some studies suggest that it should be differentiated from HHV-8-positive lymphoma, but relevant research data are scarce^[37]. However, in light of the fact that it occurs in immunosuppressed patients and in the body cavity, the possibility of peritoneal expression of primary effusion lymphoma can be considered.

Peritoneal lymphomatosis is treated with chemotherapy, and unlike peritoneal

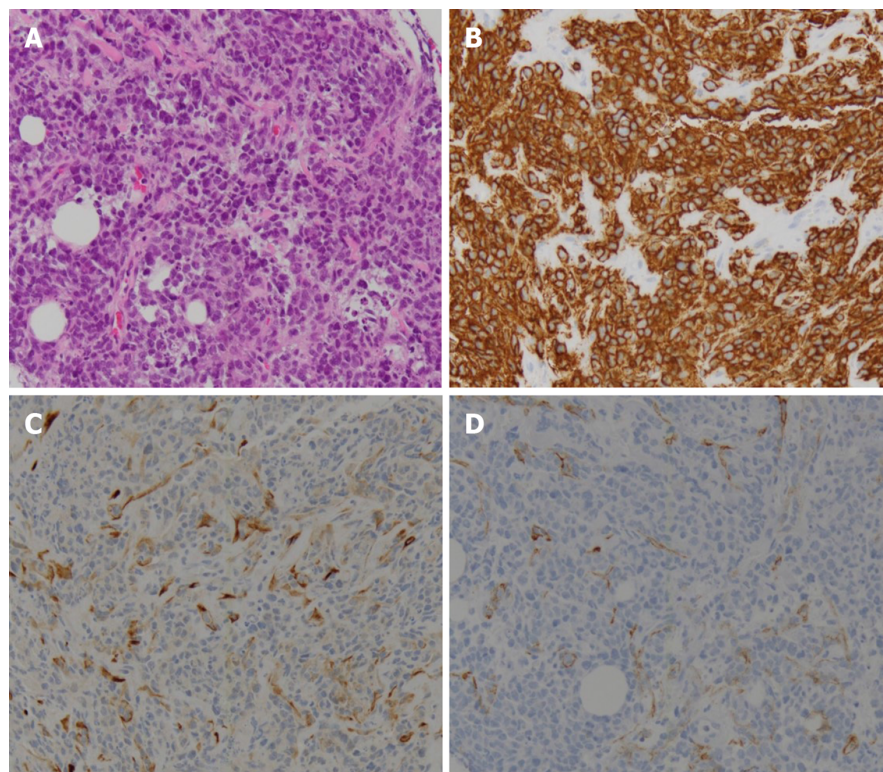


Figure 3 Pathologic findings. Highly pleomorphic, atypical, small, round, blue cells were observed infiltrating the fibrocollagenous tissue (A). On immunohistochemical testing, these cells were positive for CD20 (B) and LCA, but they were negative for the mesothelial cell marker D2-40 (C) and the epithelial cell marker cytokeratin (D).

carcinomatosis, it is curable. Although therapeutic efficacy is predicted to be low due to problems such as reduced peritoneal infiltration by anticancer agents, relevant data are lacking. The present patient is in stage II and classified as low-to-intermediate-risk based on the International Prognostic Index, and PTLD has a relatively low cure rate. Thus, despite the fact that he has currently achieved complete remission, close follow-up will be maintained, given the poor prognosis of primary pleural effusion lymphoma and the possibility of relapse.

CONCLUSION

This is a valuable report as it presents an extremely rare case of isolated peritoneal lymphomatosis after liver transplantation. Moreover, it is the first report of isolated peritoneal lymphomatosis defined as PTLT in a liver transplant recipient.

REFERENCES

- 1 **Opelz G, Döhler B.** Lymphomas after solid organ transplantation: a collaborative transplant study report. *Am J Transplant* 2004; **4**: 222-230 [PMID: [14974943](#) DOI: [10.1046/j.1600-6143.2003.00325.x](#)]
- 2 **Dierickx D, Tousseyn T, Sagaert X, Fieuws S, Wlodarska I, Morscio J, Brepoels L, Kuypers D, Vanhaecke J, Nevens F, Verleden G, Van Damme-Lombaerts R, Renard M, Pirenne J, De Wolf-Peeters C, Verhoef G.** Single-center analysis of biopsy-confirmed posttransplant lymphoproliferative disorder: incidence, clinicopathological characteristics and prognostic factors. *Leuk Lymphoma* 2013; **54**: 2433-2440 [PMID: [23442063](#) DOI: [10.3109/10428194.2013.780655](#)]
- 3 **Campo E, Swerdlow SH, Harris NL, Pileri S, Stein H, Jaffe ES.** The 2008 WHO classification of lymphoid neoplasms and beyond: evolving concepts and practical applications. *Blood* 2011; **117**: 5019-5032 [PMID: [21300984](#) DOI: [10.1182/blood-2011-01-293050](#)]
- 4 **Hsiao CY, Lee PH, Ho CM, Wu YM, Ho MC, Hu RH.** Post-transplant malignancy in liver transplantation: a single center experience. *Medicine (Baltimore)* 2014; **93**: e310 [PMID: [25526480](#) DOI: [10.1097/MD.0000000000000310](#)]
- 5 **Engels EA, Jennings LW, Everly MJ, Landgren O, Murata K, Yanik EL, Pfeiffer RM, Onaca N, Klintmalm GB.** Donor-specific Antibodies, Immunoglobulin-free Light Chains, and BAFF Levels in Relation to Risk of Late-onset PTLT in Liver Recipients. *Transplant Direct* 2018; **4**: e353 [PMID: [30123826](#) DOI: [10.1097/TXD.0000000000000792](#)]
- 6 **Styczynski J, Gil L, Tridello G, Ljungman P, Donnelly JP, van der Velden W, Omar H, Martino R, Halkes C, Faraci M, Theunissen K, Kalwak K, Hubacek P, Sica S, Nozzoli C, Fagioli F, Matthes S, Diaz MA,**

- Migliavacca M, Balduzzi A, Tomaszewska A, Camara Rde L, van Biezen A, Hoek J, Iacobelli S, Einsele H, Cesaro S; Infectious Diseases Working Party of the European Group for Blood and Marrow Transplantation. Response to rituximab-based therapy and risk factor analysis in Epstein Barr Virus-related lymphoproliferative disorder after hematopoietic stem cell transplant in children and adults: a study from the Infectious Diseases Working Party of the European Group for Blood and Marrow Transplantation. *Clin Infect Dis* 2013; **57**: 794-802 [PMID: 23771985 DOI: 10.1093/cid/cit391]
- 7 Aull MJ, Buell JF, Trofe J, First MR, Alloway RR, Hanaway MJ, Wagoner L, Gross TG, Beebe T, Woodle ES. Experience with 274 cardiac transplant recipients with posttransplant lymphoproliferative disorder: a report from the Israel Penn International Transplant Tumor Registry. *Transplantation* 2004; **78**: 1676-1682 [PMID: 15591959 DOI: 10.1097/01.tp.0000144333.19106.58]
- 8 Caillard S, Porcher R, Provot F, Dantal J, Choquet S, Durrbach A, Morelon E, Moal V, Janbon B, Alamartine E, Pouteil Noble C, Morel D, Kamar N, Buchler M, Mamzer MF, Peraldi MN, Hiesse C, Renoult E, Toupance O, Rerolle JP, Delmas S, Lang P, Lebranchu Y, Heng AE, Rebibou JM, Mousson C, Glotz D, Rivalan J, Thierry A, Etienne I, Moal MC, Albano L, Subra JF, Ouali N, Westeel PF, Delahousse M, Genin R, Hurault de Ligny B, Moulin B. Post-transplantation lymphoproliferative disorder after kidney transplantation: report of a nationwide French registry and the development of a new prognostic score. *J Clin Oncol* 2013; **31**: 1302-1309 [PMID: 23423742 DOI: 10.1200/JCO.2012.43.2344]
- 9 Kinch A, Baecklund E, Backlin C, Ekman T, Molin D, Tufveson G, Fernberg P, Sundström C, Pauksens K, Enblad G. A population-based study of 135 lymphomas after solid organ transplantation: The role of Epstein-Barr virus, hepatitis C and diffuse large B-cell lymphoma subtype in clinical presentation and survival. *Acta Oncol* 2014; **53**: 669-679 [PMID: 24164103 DOI: 10.3109/0284186X.2013.844853]
- 10 Morovic A, Jaffe ES, Raffeld M, Schrag JA. Metachronous EBV-associated B-cell and T-cell posttransplant lymphoproliferative disorders in a heart transplant recipient. *Am J Surg Pathol* 2009; **33**: 149-154 [PMID: 18941401 DOI: 10.1097/PAS.0b013e318181a826]
- 11 Quinlan SC, Pfeiffer RM, Morton LM, Engels EA. Risk factors for early-onset and late-onset post-transplant lymphoproliferative disorder in kidney recipients in the United States. *Am J Hematol* 2011; **86**: 206-209 [PMID: 21264909 DOI: 10.1002/ajh.21911]
- 12 Morton M, Coupes B, Roberts SA, Klapper PE, Byers RJ, Vallely PJ, Ryan K, Picton ML. Epidemiology of posttransplantation lymphoproliferative disorder in adult renal transplant recipients. *Transplantation* 2013; **95**: 470-478 [PMID: 23222821 DOI: 10.1097/TP.0b013e318276a237]
- 13 Khedmat H, Taheri S. Ultra-early onset post-transplantation lymphoproliferative disease. *Saudi J Kidney Dis Transpl* 2013; **24**: 1144-1152 [PMID: 24231475 DOI: 10.4103/1319-2442.121270]
- 14 Leblond V, Davi F, Charlotte F, Dorent R, Bitker MO, Sutton L, Gandjbakhch I, Binet JL, Raphael M. Posttransplant lymphoproliferative disorders not associated with Epstein-Barr virus: a distinct entity? *J Clin Oncol* 1998; **16**: 2052-2059 [PMID: 9626203 DOI: 10.1200/JCO.1998.16.6.2052]
- 15 Allen U, Preiksaitis J; AST Infectious Diseases Community of Practice. Epstein-barr virus and posttransplant lymphoproliferative disorder in solid organ transplant recipients. *Am J Transplant* 2009; **9** Suppl 4: S87-S96 [PMID: 20070701 DOI: 10.1111/j.1600-6143.2009.02898.x]
- 16 Thorley-Lawson DA, Gross A. Persistence of the Epstein-Barr virus and the origins of associated lymphomas. *N Engl J Med* 2004; **350**: 1328-1337 [PMID: 15044644 DOI: 10.1056/NEJMra032015]
- 17 Ambinder RF. Gammaherpesviruses and "Hit-and-Run" oncogenesis. *Am J Pathol* 2000; **156**: 1-3 [PMID: 10623645 DOI: 10.1016/S0002-9440(10)64697-4]
- 18 Shimizu N, Tanabe-Tochikura A, Kuroiwa Y, Takada K. Isolation of Epstein-Barr virus (EBV)-negative cell clones from the EBV-positive Burkitt's lymphoma (BL) line Akata: malignant phenotypes of BL cells are dependent on EBV. *J Virol* 1994; **68**: 6069-6073 [PMID: 8057484 DOI: 10.1016/0166-0934(94)90047-7]
- 19 Mañez R, Breinig MC, Linden P, Wilson J, Torre-Cisneros J, Kusne S, Dummer S, Ho M. Posttransplant lymphoproliferative disease in primary Epstein-Barr virus infection after liver transplantation: the role of cytomegalovirus disease. *J Infect Dis* 1997; **176**: 1462-1467 [PMID: 9395355 DOI: 10.1086/514142]
- 20 Buda A, Caforio A, Calabrese F, Fagioli S, Pevero S, Livi U, Naccarato R, Burra P. Lymphoproliferative disorders in heart transplant recipients: role of hepatitis C virus (HCV) and Epstein-Barr virus (EBV) infection. *Transpl Int* 2000; **13** Suppl 1: S402-S405 [PMID: 11112042 DOI: 10.1007/s001470050371]
- 21 Tsao L, Hsi ED. The clinicopathologic spectrum of posttransplantation lymphoproliferative disorders. *Arch Pathol Lab Med* 2007; **131**: 1209-1218 [PMID: 17683183 DOI: 10.1043/1543-2165(2007)131[1209:TCSOPL]2.0.CO;2]
- 22 Zhang A, Zhang M, Shen Y, Wang W, Zheng S. Hepatitis B virus reactivation is a risk factor for development of post-transplant lymphoproliferative disease after liver transplantation. *Clin Transplant* 2009; **23**: 756-760 [PMID: 19664018 DOI: 10.1111/j.1399-0012.2009.01049.x]
- 23 Courville EL, Yohe S, Chou D, Nardi V, Lazaryan A, Thakral B, Nelson AC, Ferry JA, Sohani AR. EBV-negative monomorphic B-cell post-transplant lymphoproliferative disorders are pathologically distinct from EBV-positive cases and frequently contain TP53 mutations. *Mod Pathol* 2016; **29**: 1200-1211 [PMID: 27443517 DOI: 10.1038/modpathol.2016.130]
- 24 Evens AM, David KA, Helenowski I, Nelson B, Kaufman D, Kircher SM, Gimelfarb A, Hattersley E, Mauro LA, Jovanovic B, Chadburn A, Stiff P, Winter JN, Mehta J, Van Besien K, Gregory S, Gordon LI, Shammo JM, Smith SE, Smith SM. Multicenter analysis of 80 solid organ transplantation recipients with post-transplantation lymphoproliferative disease: outcomes and prognostic factors in the modern era. *J Clin Oncol* 2010; **28**: 1038-1046 [PMID: 20085936 DOI: 10.1200/JCO.2009.25.4961]
- 25 Dierickx D, Tousseyn T, Morscio J, Fieuws S, Verhoef G. Validation of prognostic scores in post-transplantation lymphoproliferative disorders. *J Clin Oncol* 2013; **31**: 3443-3444 [PMID: 23960181 DOI: 10.1200/JCO.2013.50.3326]
- 26 Trappe RU, Choquet S, Dierickx D, Mollee P, Zaucha JM, Dreyling MH, Dührsen U, Tarella C, Shpilberg O, Sender M, Salles G, Morschhauser F, Jaccard A, Lamy T, Reinke P, Neuhaus R, Lehmkuhl H, Horst HA, Leithäuser M, Schlattmann P, Anagnostopoulos I, Raphael M, Riess H, Leblond V, Oertel S; German PTLN Study Group and the European PTLN Network. International prognostic index, type of transplant and response to rituximab are key parameters to tailor treatment in adults with CD20-positive B cell PTLN: clues from the PTLN-1 trial. *Am J Transplant* 2015; **15**: 1091-1100 [PMID: 25736912 DOI: 10.1111/ajt.13086]
- 27 Trappe R, Oertel S, Leblond V, Mollee P, Sender M, Reinke P, Neuhaus R, Lehmkuhl H, Horst HA, Salles G, Morschhauser F, Jaccard A, Lamy T, Leithäuser M, Zimmermann H, Anagnostopoulos I, Raphael M, Riess H, Choquet S; German PTLN Study Group; European PTLN Network. Sequential treatment with rituximab followed by CHOP chemotherapy in adult B-cell post-transplant

- lymphoproliferative disorder (PTLD): the prospective international multicentre phase 2 PTLD-1 trial. *Lancet Oncol* 2012; **13**: 196-206 [PMID: [22173060](#) DOI: [10.1016/S1470-2045\(11\)70300-X](#)]
- 28 **Trappe RU**, Dierickx D, Zimmermann H, Morschhauser F, Mollee P, Zaucha JM, Dreyling MH, Dührsen U, Reinke P, Verhoef G, Subklewe M, Hüttmann A, Tousseyn T, Salles G, Kliem V, Hauser IA, Tarella C, Van Den Neste E, Gheysens O, Anagnostopoulos I, Leblond V, Riess H, Choquet S. Response to Rituximab Induction Is a Predictive Marker in B-Cell Post-Transplant Lymphoproliferative Disorder and Allows Successful Stratification Into Rituximab or R-CHOP Consolidation in an International, Prospective, Multicenter Phase II Trial. *J Clin Oncol* 2017; **35**: 536-543 [PMID: [27992268](#) DOI: [10.1200/JCO.2016.69.3564](#)]
- 29 **Runyon BA**, Hoefs JC. Peritoneal lymphomatosis with ascites. A characterization. *Arch Intern Med* 1986; **146**: 887-888 [PMID: [3963980](#) DOI: [10.1001/archinte.146.5.887](#)]
- 30 **Horger M**, Müller-Schimpfle M, Yirkin I, Wehrmann M, Clausen CD. Extensive peritoneal and omental lymphomatosis with raised CA 125 mimicking carcinomatosis: CT and intraoperative findings. *Br J Radiol* 2004; **77**: 71-73 [PMID: [14988144](#) DOI: [10.1259/bjr/35139284](#)]
- 31 **Cunningham N**, Ffrench-Constant S, Planche K, Gillmore R. Peritoneal lymphomatosis: a rare presentation of follicular lymphoma mimicking peritoneal carcinomatosis. *BMJ Case Rep* 2015; **2015**: bcr2014207136 [PMID: [25694630](#) DOI: [10.1136/bcr-2014-207136](#)]
- 32 **Weng SC**, Wu CY. Lymphoma presenting as peritoneal lymphomatosis with ascites. *J Chin Med Assoc* 2008; **71**: 646-650 [PMID: [19114331](#) DOI: [10.1016/S1726-4901\(09\)70009-7](#)]
- 33 **Kim YG**, Baek JY, Kim SY, Lee DH, Park WS, Kwon Y, Kim MJ, Kang J, Lee JM. Peritoneal lymphomatosis confounded by prior history of colon cancer: a case report. *BMC Cancer* 2011; **11**: 276 [PMID: [21708008](#) DOI: [10.1186/1471-2407-11-276](#)]
- 34 **Choi WY**, Kim JH, Choi SJ, Park J, Park YH, Lim JH, Lee MH, Kim CS, Yi HG. Peritoneal lymphomatosis confused with peritoneal carcinomatosis due to the previous history of gastric cancer: a case report. *Clin Imaging* 2016; **40**: 837-839 [PMID: [27179155](#) DOI: [10.1016/j.clinimag.2016.03.006](#)]
- 35 **Chen YB**, Rahemtullah A, Hochberg E. Primary effusion lymphoma. *Oncologist* 2007; **12**: 569-576 [PMID: [17522245](#) DOI: [10.1634/theoncologist.12-5-569](#)]
- 36 **Carbone A**, Gloghini A. PEL and HHV8-unrelated effusion lymphomas: classification and diagnosis. *Cancer* 2008; **114**: 225-227 [PMID: [18473348](#) DOI: [10.1002/cncr.23597](#)]
- 37 **Saini N**, Hochberg EP, Linden EA, Jha S, Grohs HK, Sohani AR. HHV8-Negative Primary Effusion Lymphoma of B-Cell Lineage: Two Cases and a Comprehensive Review of the Literature. *Case Rep Oncol Med* 2013; **2013**: 292301 [PMID: [23401819](#) DOI: [10.1155/2013/292301](#)]



Published By Baishideng Publishing Group Inc
7041 Koll Center Parkway, Suite 160, Pleasanton, CA 94566, USA
Telephone: +1-925-2238242
E-mail: bpgoffice@wjgnet.com
Help Desk: <https://www.f6publishing.com/helpdesk>
<https://www.wjgnet.com>

