

# World Journal of *Clinical Cases*

*World J Clin Cases* 2020 January 6; 8(1): 1-244





### REVIEW

- 1 Role of oxysterol-binding protein-related proteins in malignant human tumours  
*Liu H, Huang S*

### ORIGINAL ARTICLE

#### Case Control Study

- 11 Oncogenic role of Tc17 cells in cervical cancer development  
*Zhang ZS, Gu Y, Liu BG, Tang H, Hua Y, Wang J*

#### Retrospective Study

- 20 Acute distal common bile duct angle is risk factor for post-endoscopic retrograde cholangiopancreatography pancreatitis in beginner endoscopist  
*Han SY, Kim DU, Lee MW, Park YJ, Baek DH, Kim GH, Song GA*
- 29 Three-dimensional computed tomography mapping of posterior malleolar fractures  
*Su QH, Liu J, Zhang Y, Tan J, Yan MJ, Zhu K, Zhang J, Li C*
- 38 Application of a modified surgical position in anterior approach for total cervical artificial disc replacement  
*Hou WX, Zhang HX, Wang X, Yang HL, Luan XR*
- 46 Potential role of the compound Eucommia bone tonic granules in patients with osteoarthritis and osteonecrosis: A retrospective study  
*Hu CX, Hu KY, Wang JF*
- 54 Prognostic factors for overall survival in prostate cancer patients with different site-specific visceral metastases: A study of 1358 patients  
*Cui PF, Cong XF, Gao F, Yin JX, Niu ZR, Zhao SC, Liu ZL*
- 68 Application of multiple Roux-en-Y hepaticojejunostomy reconstruction by formation of bile hilar duct lake in the operation of hilar cholangiocarcinoma  
*Yang XJ, Dong XH, Chen SY, Wu B, He Y, Dong BL, Ma BQ, Gao P*

#### Observational Study

- 76 Relationship between  $\beta$ -amyloid protein 1-42, thyroid hormone levels and the risk of cognitive impairment after ischemic stroke  
*Mao L, Chen XH, Zhuang JH, Li P, Xu YX, Zhao YC, Ma YJ, He B, Yin Y*

**Prospective Study**

- 88 Can the wet suction technique change the efficacy of endoscopic ultrasound-guided fine-needle aspiration for diagnosing autoimmune pancreatitis type 1? A prospective single-arm study  
*Sugimoto M, Takagi T, Suzuki R, Konno N, Asama H, Sato Y, Irie H, Watanabe K, Nakamura J, Kikuchi H, Takasumi M, Hashimoto M, Kato T, Hikichi T, Notohara K, Ohira H*

**CASE REPORT**

- 97 Pembrolizumab - emerging treatment of pulmonary sarcomatoid carcinoma: A case report  
*Cimpeanu E, Ahmed J, Zafar W, DeMarinis A, Bardarov SS, Salman S, Bloomfield D*
- 103 Sclerosing angiomatoid nodular transformation of the spleen, a rare cause for splenectomy: Two case reports  
*Chikhladze S, Lederer AK, Fichtner-Feigl S, Wittel UA, Werner M, Aumann K*
- 110 Postpartum pubic symphysis diastasis-conservative and surgical treatment methods, incidence of complications: Two case reports and a review of the literature  
*Norvilaite K, Kezeviciute M, Ramasauskaite D, Arlauskienė A, Bartkeviciene D, Uvarovas V*
- 120 Use of omental patch and endoscopic closure technique as an alternative to surgery after endoscopic full thickness resection of gastric intestinal stromal tumors: A series of cases  
*Sachdev AH, Iqbal S, Ribeiro IB, de Moura DTH*
- 126 Primary maxillary chondrosarcoma: A case report  
*Cuevas-González JC, Reyes-Escalera JO, González JL, Sánchez-Romero C, Espinosa-Cristóbal LF, Reyes-López SY, Tovar Carrillo KL, Donohue Cornejo A*
- 133 Hyalinizing clear cell carcinoma-a rare entity in the oral cavity: A case report  
*Donohue-Cornejo A, Paes de Almeida O, Sánchez-Romero C, Espinosa-Cristóbal LF, Reyes-López SY, Cuevas-González JC*
- 140 Jejunal cavernous lymphangioma manifested as gastrointestinal bleeding with hypogammaglobulinemia in adult: A case report and literature review  
*Tan B, Zhang SY, Wang YN, Li Y, Shi XH, Qian JM*
- 149 Large pelvic mass arising from the cervical stump: A case report  
*Zhang K, Jiang JH, Hu JL, Liu YL, Zhang XH, Wang YM, Xue FX*
- 157 Mechanical intestinal obstruction due to isolated diffuse venous malformations in the gastrointestinal tract: A case report and review of literature  
*Li HB, Lv JF, Lu N, Lv ZS*
- 168 Two-level percutaneous endoscopic lumbar discectomy for highly migrated upper lumbar disc herniation: A case report  
*Wu XB, Li ZH, Yang YF, Gu X*

- 175 Successful treatment of congenital palate perforation: A case report  
*Zhang JF, Zhang WB*
- 179 Calcitonin-negative neuroendocrine tumor of the thyroid with metastasis to liver-rare presentation of an unusual tumor: A case report and review of literature  
*Cai HJ, Wang H, Cao N, Huang B, Kong FL, Lu LR, Huang YY, Wang W*
- 188 Giant exophytic cystic adenomyosis with a levonorgestrel containing intrauterine device out of the uterine cavity after uterine myomectomy: A case report  
*Zhou Y, Chen ZY, Zhang XM*
- 194 Unusual presentation of bladder neuroblastoma in a child: A case report  
*Cai JB, Wang JH, He M, Wang FL, Xiong JN, Mao JQ, Li MJ, Zhu K, Liang JW*
- 200 Value of dynamic plasma cell-free DNA monitoring in septic shock syndrome: A case report  
*Liu JP, Zhang SC, Pan SY*
- 208 Sarcomatoid intrahepatic cholangiocarcinoma mimicking liver abscess: A case report  
*Wang Y, Ming JL, Ren XY, Qiu L, Zhou LJ, Yang SD, Fang XM*
- 217 Clinical characteristics on manifestation and gene mutation of a transient neonatal cyanosis: A case report  
*Yuan J, Zhu XP*
- 222 Six families with balanced chromosome translocation associated with reproductive risks in Hainan Province: Case reports and review of the literature  
*Chen YC, Huang XN, Kong CY, Hu JD*
- 234 Primary intestinal extranodal natural killer/T-cell lymphoma, nasal type: A case report  
*Dong BL, Dong XH, Zhao HQ, Gao P, Yang XJ*

**LETTER TO THE EDITOR**

- 242 Cluster headache as a manifestation of a stroke-like episode in a carrier of the MT-ND3 variant m.10158T>C  
*Finsterer J*



**ABOUT COVER**

Editorial Board Member of *World Journal of Clinical Cases*, Maddalena Zippi, MD, PhD, Doctor, Unit of Gastroenterology and Digestive Endoscopy, Sandro Pertini Hospital, Rome 00157, Italy

**AIMS AND SCOPE**

The primary aim of *World Journal of Clinical Cases* (WJCC, *World J Clin Cases*) is to provide scholars and readers from various fields of clinical medicine with a platform to publish high-quality clinical research articles and communicate their research findings online.

WJCC mainly publishes articles reporting research results and findings obtained in the field of clinical medicine and covering a wide range of topics, including case control studies, retrospective cohort studies, retrospective studies, clinical trials studies, observational studies, prospective studies, randomized controlled trials, randomized clinical trials, systematic reviews, meta-analysis, and case reports.

**INDEXING/ABSTRACTING**

The WJCC is now indexed in PubMed, PubMed Central, Science Citation Index Expanded (also known as SciSearch®), and Journal Citation Reports/Science Edition. The 2019 Edition of Journal Citation Reports cites the 2018 impact factor for WJCC as 1.153 (5-year impact factor: N/A), ranking WJCC as 99 among 160 journals in Medicine, General and Internal (quartile in category Q3).

**RESPONSIBLE EDITORS FOR THIS ISSUE**

Responsible Electronic Editor: *Yan-Xia Xing*

Proofing Production Department Director: *Yun-Xiaojuan Wu*

**NAME OF JOURNAL**

*World Journal of Clinical Cases*

**ISSN**

ISSN 2307-8960 (online)

**LAUNCH DATE**

April 16, 2013

**FREQUENCY**

Semimonthly

**EDITORS-IN-CHIEF**

Dennis A Bloomfield, Bao-Gan Peng, Sandro Vento

**EDITORIAL BOARD MEMBERS**

<https://www.wjnet.com/2307-8960/editorialboard.htm>

**EDITORIAL OFFICE**

Jin-Lei Wang, Director

**PUBLICATION DATE**

January 6, 2020

**COPYRIGHT**

© 2020 Baishideng Publishing Group Inc

**INSTRUCTIONS TO AUTHORS**

<https://www.wjnet.com/bpg/gerinfo/204>

**GUIDELINES FOR ETHICS DOCUMENTS**

<https://www.wjnet.com/bpg/GerInfo/287>

**GUIDELINES FOR NON-NATIVE SPEAKERS OF ENGLISH**

<https://www.wjnet.com/bpg/gerinfo/240>

**PUBLICATION MISCONDUCT**

<https://www.wjnet.com/bpg/gerinfo/208>

**ARTICLE PROCESSING CHARGE**

<https://www.wjnet.com/bpg/gerinfo/242>

**STEPS FOR SUBMITTING MANUSCRIPTS**

<https://www.wjnet.com/bpg/GerInfo/239>

**ONLINE SUBMISSION**

<https://www.f6publishing.com>

## Two-level percutaneous endoscopic lumbar discectomy for highly migrated upper lumbar disc herniation: A case report

Xin-Bo Wu, Zi-Hua Li, Yun-Feng Yang, Xin Gu

**ORCID number:** Xin-Bo Wu (0000-0002-9846-2857); Zi-Hua Li (0000-0002-6087-7459); Yun-Feng Yang (0000-0001-5129-2347); Xin Gu (0000-0001-5074-1016).

**Author contributions:** Wu XB reviewed the literature and drafted the manuscript; Li ZH analyzed the data; Yang YF designed the report; Gu X collected the patient's clinical data.

### Informed consent statement:

Informed written consent was obtained from the patient for publication of this report and any accompanying images.

**Conflict-of-interest statement:** The authors declare that they have no conflict of interest.

### CARE Checklist (2016) statement:

The authors have read the CARE Checklist (2016), and the manuscript was prepared and revised according to the CARE Checklist (2016).

**Open-Access:** This article is an open-access article that was selected by an in-house editor and fully peer-reviewed by external reviewers. It is distributed in accordance with the Creative Commons Attribution Non Commercial (CC BY-NC 4.0) license, which permits others to distribute, remix, adapt, build upon this work non-commercially, and license their derivative works on different terms, provided the original work is properly cited and the use is non-commercial. See: <http://creativecommons.org/licenses/by-nc/4.0/>

**Xin-Bo Wu, Zi-Hua Li, Yun-Feng Yang,** Department of Orthopedics, Shanghai Tongji Hospital, Tongji University School of Medicine, Shanghai 200065, China

**Xin Gu,** Department of Orthopedics, Shanghai Changzheng Hospital, Second Military Medical University, Shanghai 200003, China

**Corresponding author:** Xin Gu, MD, PhD, Department of Orthopedics, Shanghai Changzheng Hospital, Second Military Medical University, No. 415 Fengyang Road, Shanghai 200003, China. [guxin2004ty@163.com](mailto:guxin2004ty@163.com)

## Abstract

### BACKGROUND

The technique of percutaneous endoscopic lumbar discectomy (PELD) as a transforaminal approach has been used to treat highly migrated lower lumbar disc herniations. However, due to the different anatomic characteristics of the upper lumbar spine, conventional transforaminal PELD may fail to remove the highly migrated upper lumbar disc nucleus pulposus. Therefore, the purpose of this study was to describe a novel surgical technique, two-level PELD, for the treatment of highly migrated upper lumbar disc herniations and to report its related clinical outcomes.

### CASE SUMMARY

A 60-year-old male presented with a complaint of pain at his lower back and right lower limb. The patient received 3 mo of conservative treatments but the symptoms were not alleviated. Physical examination revealed a positive femoral nerve stretch test and a negative straight leg raise test for the right leg, and preoperative visual analog scale (VAS) score for the lower back was 6 points and for the right leg was 8 points. Magnetic resonance imaging (MRI) demonstrated L2-L3 disc herniation on the right side and the herniated nucleus pulposus migrated to the upper margin of L2 vertebral body. According to physical examination and imaging findings, surgery was the primary consideration. Therefore, the patient underwent surgical treatment with two-level PELD. The pain symptom was relieved and the VAS score for back and thigh pain was one point postoperatively. The patient was asymptomatic and follow-up MRI scan 1 year after operation revealed no residual nucleus pulposus.

### CONCLUSION

Two-level PELD as a transforaminal approach can be a safe and effective procedure for highly migrated upper lumbar disc herniation.

**Manuscript source:** Unsolicited Manuscript

**Received:** October 19, 2019

**Peer-review started:** October 19, 2019

**First decision:** November 29, 2019

**Revised:** December 4, 2019

**Accepted:** December 6, 2019

**Article in press:** December 6, 2019

**Published online:** January 6, 2020

**P-Reviewer:** Kung WM

**S-Editor:** Wang YQ

**L-Editor:** Filipodia

**E-Editor:** Xing YX



**Key words:** Upper lumbar disc herniations; Two-level percutaneous endoscopic lumbar discectomy; Highly migrated disc herniations; Case report

©The Author(s) 2020. Published by Baishideng Publishing Group Inc. All rights reserved.

**Core tip:** Conventional open surgery has been considered a gold standard procedure for highly migrated upper lumbar disc herniations. However, conventional open surgery needs to remove extensive lamina and facet joint, which may induce iatrogenic instability. In this study, we creatively introduced the two-level percutaneous endoscopic lumbar discectomy for highly migrated upper lumbar disc herniations, enabling us to completely remove the highly migrated nucleus pulposus and reduce the incidence of surgical complications. Therefore, two-level percutaneous endoscopic lumbar discectomy is a safe and effective procedure for highly migrated upper lumbar disc herniations.

**Citation:** Wu XB, Li ZH, Yang YF, Gu X. Two-level percutaneous endoscopic lumbar discectomy for highly migrated upper lumbar disc herniation: A case report. *World J Clin Cases* 2020; 8(1): 168-174

**URL:** <https://www.wjnet.com/2307-8960/full/v8/i1/168.htm>

**DOI:** <https://dx.doi.org/10.12998/wjcc.v8.i1.168>

## INTRODUCTION

Upper lumbar disc herniations, including L1-L2 and L2-L3 level herniations, are less common than lower lumbar disc herniations, and the incidence is no more than 2% of all lumbar disc herniations<sup>[1-3]</sup>. Conventional open surgery has been considered a gold standard procedure for upper lumbar disc herniations when conservative treatments fail to relieve the symptoms<sup>[4]</sup>. However, conventional open surgery needs to extensively resect the lamina and facet joints, which may result in iatrogenic instability and back pain after surgery<sup>[4-7]</sup>. In addition, compared with lower lumbar disc herniations, upper lumbar disc herniations always have less favorable outcomes after open surgery due to the specific anatomic characteristics, such as narrow spinal canal and lamina window of the upper lumbar spine<sup>[2,8]</sup>. Therefore, the choice of surgical approach becomes an important issue.

Recently, the technique of percutaneous endoscopic lumbar discectomy (PELD) has been widely used for the treatment of upper lumbar disc herniations and its clinical efficacy has been validated by previous studies<sup>[9,10]</sup>. However, the indications of PELD are limited to non-migrated upper lumbar disc herniations due to the anatomic barriers. It is very difficult to use PELD as a transforaminal approach to remove highly migrated upper lumbar disc nucleus pulposus.

To improve the clinical outcomes, we introduced the two-level PELD technique for the treatment of highly migrated lower lumbar disc herniations<sup>[11]</sup>; however, its clinical efficacy to the highly migrated upper lumbar disc herniations is unclear. Therefore, the purpose of this study was to describe the surgical procedures and clinical outcomes of two-level PELD for the treatment of highly migrated upper lumbar disc herniations.

## CASE PRESENTATION

### Chief complaints

A 60-year-old male patient presented with a complaint of pain at his lower back and right lower limb, mainly around the groin and the front of the thigh.

### History of present illness

Patient's symptoms started 3 mo ago with no other concomitant symptoms.

### History of past illness

The patient had no previous medical history.

### Physical examination

Preoperative physical examinations demonstrated a positive femoral nerve stretch test and a negative straight leg raise test for the right leg. Muscle force and feelings in the right lower limb, as well as bilateral knee reflexes and Achilles tendon reflexes were normal.

### Imaging examination

Magnetic resonance imaging (MRI) showed L2-L3 disc herniation on the right side and the herniated nucleus pulposus migrated to the upper margin of L2 vertebral body. A dynamic imaging x-ray indicated instability of the L4-L5 disc space (Figure 1A-F).

## FINAL DIAGNOSIS

The patient was finally diagnosed as lumbar disc herniation (L2-L3), combined with lumbar spondylolisthesis (L4-L5).

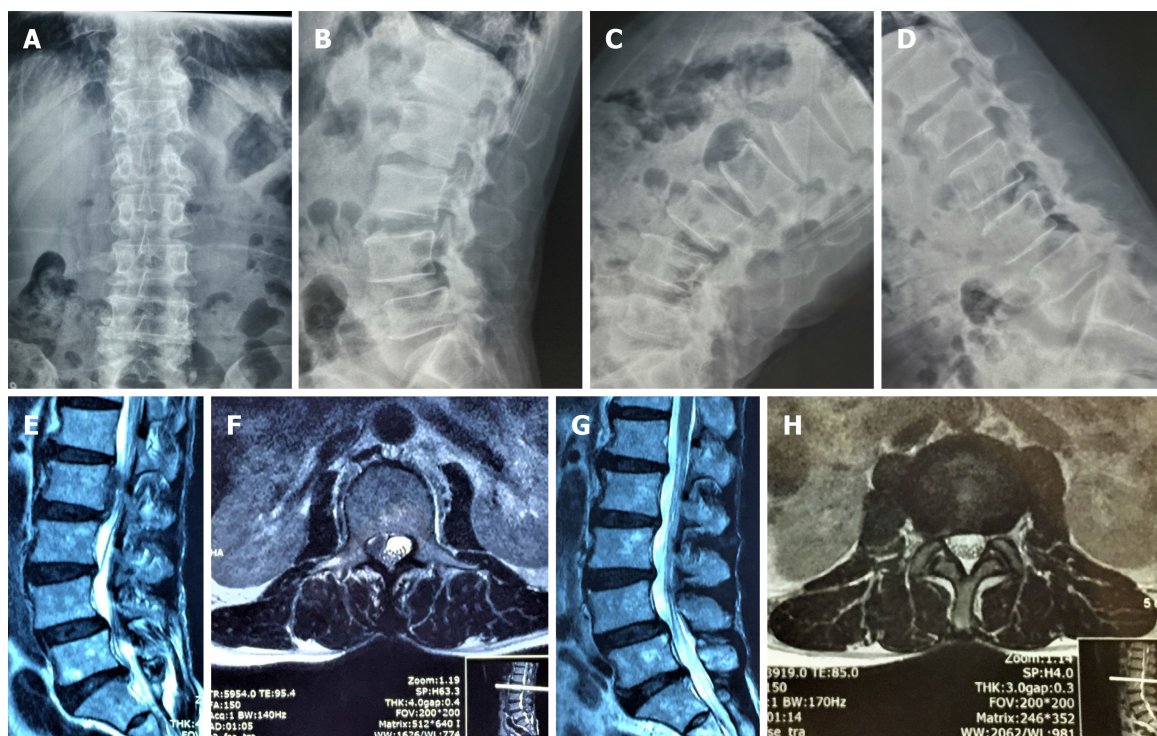
## TREATMENT

The patient obtained conservative treatments by using physiotherapy and symptomatic treatment for 3 mo, but the symptoms persisted. After obtaining an accurate diagnosis, we decided to remove the highly migrated nucleus pulposus with the two-level PELD technique.

Specifically, PELD with an outside-in approach was performed according to the standard procedure, which has been detailed in our previous study<sup>[11]</sup>. The patient was positioned in the prone position on a radiolucent operating table and C-arm fluoroscopy was used to confirm the target segment. We marked the lumbar spinous process, L1, L2, and L3 pedicles, intervertebral space, and target position according to preoperative localization. The surgical puncture point was 7 cm from the midline for the L1/2 and 8 cm for L2/3 segments according to safety puncture distance based on the cross-section measurement of preoperative MRI. The puncture path was deviated to the cranial direction for the L2/3 segment and deviated to the caudal direction for the L1/2 segment. Routine disinfection and shop towels were used. These procedures were performed under local anesthesia with 1% lidocaine solution, with continuous feedback permitted from the patient during the whole surgical procedure (Supplementary material). After local anesthesia was achieved around the puncture pathway, an 18-gauge needle was inserted under fluoroscopic guidance through the L2/3 right intervertebral foramen. The target point of the needle was the medial pedicle line on the anteroposterior view and the central of the intervertebral space on the lateral view. Subsequently, the needle was replaced by a guidewire and an 8-mm skin incision was made around it. Sequential dilators of increasing diameter were placed along the guide wire to widen the soft tissue channel and a guide rod was inserted. A 7.5-mm-diameter working channel was directly placed into the intervertebral foramen, and the intraoperative fluoroscopy showed that the working channel was completely placed diagonally in the intervertebral foramen. Then a spinal endoscope was inserted through the working channel and the soft tissue was gradually separated with a flexible bipolar radiofrequency probe. After revealing the position of the dural sac, the working channel was rotated upward along the dural sac to expose the migrated nucleus pulposus tissue. The migrated nucleus pulposus tissues could be removed with a straight forceps or curved forceps under direct vision and explored to the axilar of L2 nerve root. After removing the migrated nucleus pulposus, the endoscope was pulled out and the working channel was kept in place to prevent the nucleus pulposus from shifting downward (Figure 2A-C).

The anesthesia and puncture operation of the L1-L2 segments were the same as L2-L3 segments. The working channel was completely placed in the L1-L2 intervertebral foramen and its oblique face deviated to the caudal direction confirmed by intraoperative fluoroscopy. The soft tissue was isolated and the residual nucleus pulposus was found below the nerve root. Curved forceps were used to remove the free nucleus pulposus tissues until there were no compressions of the nerve root. After decompression of the L1-L2 intervertebral space, we re-entered the L2-L3 working channel to check if any nucleus shifted away. Finally, we confirmed that there were no further remnants *via* the two-level working channels and the incision was sutured after the working channel was removed (Figure 2D-F).





**Figure 1** Preoperative and postoperative imaging examination. A, B, C, D: Preoperative dynamic imaging x-ray examination indicated instability of the L4/5 vertebral body; E, F: Preoperative magnetic resonance imaging revealed L2/3 disc herniation with the nucleus pulposus highly migrating upward to the upper margin of the L2 vertebral body; G, H: Postoperative magnetic resonance imaging examination revealed clean removal of the nucleus pulposus.

## OUTCOME AND FOLLOW-UP

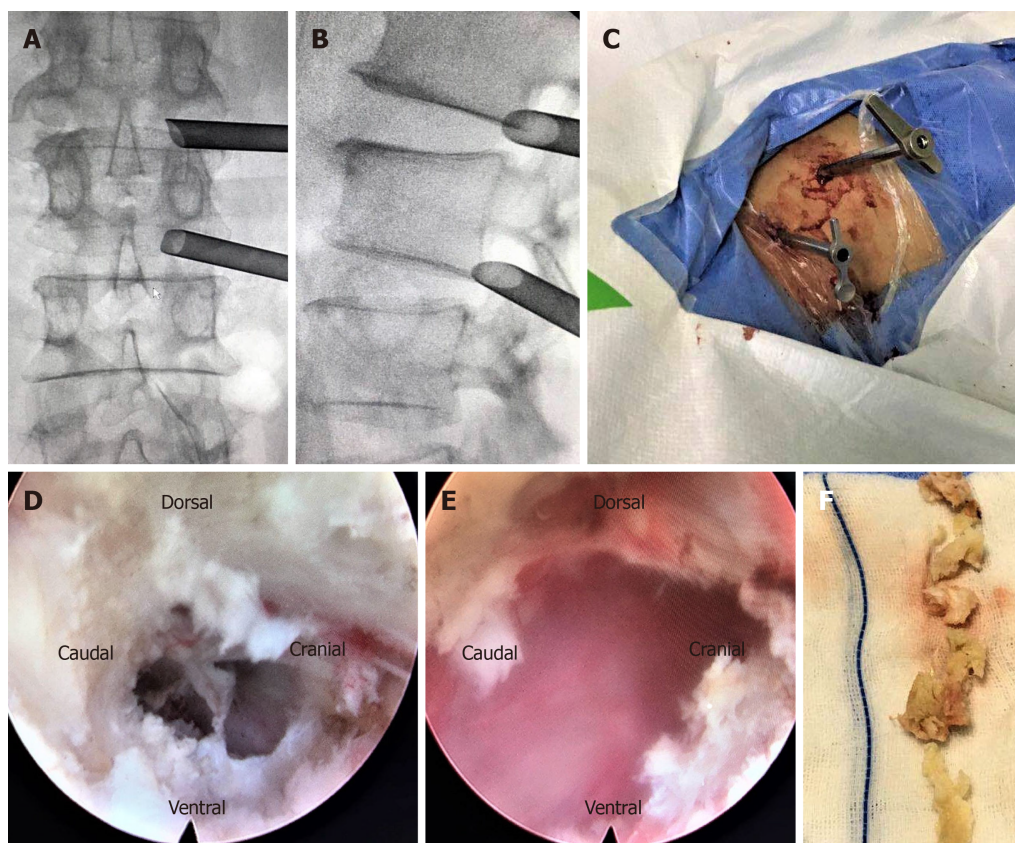
The preoperative visual analog scale (VAS) score for lower back was 6 points and that for the right leg was 8 points. The postoperative pain symptoms of the lower back and leg were significantly relieved and the VAS score for back and leg pain was one point. Physical examinations revealed that the femoral nerve stretch test was negative. The back and leg pain symptoms completely disappeared after 1-year of follow-up and no residual nucleus pulposus was found by MRI examination (Figure 1G-H).

## DISCUSSION

The definition of upper lumbar disc herniations remains controversial. Some authors consider upper lumbar disc herniations to be at L1-L2 and L2-L3, but others have expanded the definition to L3-L4. However, Sanderson *et al*<sup>[2]</sup> found that the anatomic characteristics of L3-L4 were similar to the lower lumbar spine and the postoperative outcomes for lumbar disc herniations at the L3-L4 level were significantly better than those occurring at L1-L2 and L2-L3. Therefore, the upper lumbar disc herniations should be defined as herniations occurring at the L1-L2 and L2-L3<sup>[1]</sup>. In addition, the herniated nucleus pulposus of upper lumbar rarely migrates due to the anatomic barriers such as large dural sac, smaller epidural space, and vascular structures<sup>[12]</sup>. Therefore, the unique anatomical characteristics are the major reasons for the low incidence of highly migrated disc herniations.

Upper lumbar disc herniations are associated with more severe clinical symptoms due to the complicated nerve structures such as the spinal cone<sup>[3]</sup>. Compared with lower lumbar disc herniations, it is difficult to accurately diagnose the disc herniation by only symptoms and signs (*e.g.*, deep tendon reflex and manual muscle testing), because the nerve root in the upper lumbar spine does not innervate any specific muscles<sup>[10]</sup>. Therefore, early diagnosis is most important which may benefit to the patient's postoperative recovery.

Due to the severe clinical symptoms, surgical treatment is necessary and conventional microdiscectomy surgery is the gold standard procedure for upper lumbar disc herniations<sup>[4]</sup>. During the process of microdiscectomy, extensive lamina and facet joint need to be resected in order to remove the migrated nucleus pulposus, which may locate at the inferior margin of upper pedicle, pedicle, and the upper margin of the upper pedicle<sup>[7]</sup>. However, wide laminectomy may induce iatrogenic



**Figure 2** Surgical procedure of two-level percutaneous endoscopic lumbar discectomy. A, B, C: Working channels placed into the intervertebral foramen at L1/2 and L2/3 level; D, E: Intraoperative endoscopic images of L1/2 and L2/3: complete removal of the nucleus pulposus; F: Removal of nucleus pulposus tissues.

instability and adjacent vertebral disease<sup>[13]</sup>. In this case, x-ray revealed instability of the L4/5 segment. Therefore, it would be inappropriate to conduct laminectomy unless screws are added, but it would increase the cost for the patient.

Compared with traditional open surgery, many randomized controlled trials have confirmed that the clinical outcomes of PELD technique for lower lumbar disc herniation are effective in selected patients, such as those with non-migrated disc herniations<sup>[14-17]</sup>. Furthermore, the PELD technique has many merits, *e.g.*, shorter length of hospital stay, less lumbosacral muscle dissection<sup>[14,16,18]</sup>. Therefore, the PELD technique has become a popular technique for the treatment of lower lumbar disc herniation. Recently, to improve the clinical efficacy and reduce the incidence of iatrogenic instability, some scholars have introduced PELD for upper lumbar disc herniation and demonstrated the safety and effectiveness of this technique<sup>[9,10,19]</sup>.

However, there are still limitations for traditional PELD techniques applied in the treatment of highly migrated upper lumbar disc herniations. Evidence has shown that PELD as a transforaminal approach cannot provide sufficient exposure due to anatomic barriers, such as short and fixed nerve roots and narrow spinal canal<sup>[5,6,20]</sup>, which may increase the incidence of nucleus pulposus residue and dural injury. In addition, implementation of the PELD as an interlaminar approach is also limited due to the relatively narrow window and low interlaminar gap for the highly migrated nucleus pulposus, and thus, this technique is only applicable to lower non-migrated and migrated lumbar disc herniations. By contrast, the two-level PELD technique is able to provide adequate surgical vision through two working channels, which can alleviate complications after surgery.

Xin *et al*<sup>[21]</sup> introduced PELD through translaminar osseous channel for highly migrated upper lumbar disc herniations and obtained good clinical outcomes. However, this procedure has some limitations. First, without the cover of the yellow ligament, dural tears and cauda equine injury can occur during the process of enlarging the bottom of the bony tunnel. Second, nucleus pulposus residues may occur due to special anatomical structures. Third, this technique limits the management of central disc herniation. Therefore, the application of this approach is limited. In this study, we first introduced two-level transforaminal PELD for highly migrated upper lumbar disc herniations and achieved favorable clinical outcomes. The preoperative VAS scores for back and leg pain were 7 and 8 points, respectively,



which completely disappeared 12 mo after surgery and no residual nucleus pulposus was found by MRI examination.

The most common complication of PELD for highly migrated disc herniations is nucleus pulposus residues. According to a literature review, it has been reported that approximately 5%-13% of patients have incomplete nucleus pulposus removal, which need reoperation<sup>[22,23]</sup>. However, there have been no reports on the incidence of nucleus pulposus residues of PELD for highly migrated upper lumbar disc herniations. The nucleus pulposus residue is associated with the characteristic of migrated nucleus pulposus and anatomical structure. First, the highly migrated nucleus pulposus are usually multi-fragmented. Kim *et al*<sup>[23]</sup> reported that multi-fragmented nucleus pulposus were found in 19 of 53 patients. In the current case, we found that the migrated nucleus pulposus was composed of several parts. Therefore, those fragmented herniations could not be completely removed just by grasping the proximal part of the herniation. In addition, due to the narrow epidural space and complex nerve tissues, the working channel could not be rotated freely to check whether there was residual nucleus pulposus. In contrast, through the two-level PELD technique, we were able to check whether the migrated nucleus pulposus had been completely removed through two different directions. In addition, we could also remove the residual nucleus pulposus through the other working channel. Therefore, the two-level PELD technique is of great benefit to reduce the incidence of postoperative nucleus pulposus residue.

## CONCLUSION

The two-level PELD as a transforaminal approach is a safe and effective procedure for highly migrated upper lumbar disc herniations.

## REFERENCES

- 1 Kim DS, Lee JK, Jang JW, Ko BS, Lee JH, Kim SH. Clinical features and treatments of upper lumbar disc herniations. *J Korean Neurosurg Soc* 2010; **48**: 119-124 [PMID: 20856659 DOI: 10.3340/jkns.2010.48.2.119]
- 2 Sanderson SP, Houten J, Errico T, Forshaw D, Bauman J, Cooper PR. The unique characteristics of "upper" lumbar disc herniations. *Neurosurgery* 2004; **55**: 385-9; discussion 389 [PMID: 15271245 DOI: 10.1227/01.neu.0000129548.14898.9b]
- 3 Albert TJ, Balderston RA, Heller JG, Herkowitz HN, Garfin SR, Tomany K, An HS, Simeone FA. Upper lumbar disc herniations. *J Spinal Disord* 1993; **6**: 351-359 [PMID: 8219549 DOI: 10.1097/00002517-199306040-00009]
- 4 Iwasaki M, Akino M, Hida K, Yano S, Aoyama T, Saito H, Iwasaki Y. Clinical and radiographic characteristics of upper lumbar disc herniation: ten-year microsurgical experience. *Neurol Med Chir (Tokyo)* 2011; **51**: 423-426 [PMID: 21701105 DOI: 10.2176/nmc.51.423]
- 5 Jha RT, Syed HR, Catalino M, Sandhu FA. Contralateral Approach for Minimally Invasive Treatment of Upper Lumbar Intervertebral Disc Herniation: Technical Note and Case Series. *World Neurosurg* 2017; **100**: 583-589 [PMID: 28137544 DOI: 10.1016/j.wneu.2017.01.059]
- 6 Karaaslan B, Aslan A, Börcek AO, Kaymaz M. Clinical and surgical outcomes of upper lumbar disc herniations: a retrospective study. *Turk J Med Sci* 2017; **47**: 1157-1160 [PMID: 29156856 DOI: 10.3906/sag-1604-113]
- 7 Son S, Lee SG, Kim WK, Ahn Y. Advantages of a Microsurgical Translaminar Approach (Keyhole Laminotomy) for Upper Lumbar Disc Herniation. *World Neurosurg* 2018; **119**: e16-e22 [PMID: 29902597 DOI: 10.1016/j.wneu.2018.06.004]
- 8 Ido K, Shimizu K, Tada H, Matsuda Y, Shikata J, Nakamura T. Considerations for surgical treatment of patients with upper lumbar disc herniations. *J Spinal Disord* 1998; **11**: 75-79 [PMID: 9493774 DOI: 10.1097/00002517-199802000-00012]
- 9 Ahn Y, Lee SH, Lee JH, Kim JU, Liu WC. Transforaminal percutaneous endoscopic lumbar discectomy for upper lumbar disc herniation: clinical outcome, prognostic factors, and technical consideration. *Acta Neurochir (Wien)* 2009; **151**: 199-206 [PMID: 19229467 DOI: 10.1007/s00701-009-0204-x]
- 10 Wu J, Zhang C, Zheng W, Hong CS, Li C, Zhou Y. Analysis of the Characteristics and Clinical Outcomes of Percutaneous Endoscopic Lumbar Discectomy for Upper Lumbar Disc Herniation. *World Neurosurg* 2016; **92**: 142-147 [PMID: 27168234 DOI: 10.1016/j.wneu.2016.04.127]
- 11 Wu X, Fan G, Gu X, Guan X, He S. Surgical Outcome of Two-Level Transforaminal Percutaneous Endoscopic Lumbar Discectomy for Far-Migrated Disc Herniation. *Biomed Res Int* 2016; **2016**: 4924013 [PMID: 28070509 DOI: 10.1155/2016/4924013]
- 12 Wiltse LL, Fonseca AS, Amster J, Dimartino P, Ravessoud FA. Relationship of the dura, Hofmann's ligaments, Batson's plexus, and a fibrovascular membrane lying on the posterior surface of the vertebral bodies and attaching to the deep layer of the posterior longitudinal ligament. An anatomical, radiologic, and clinical study. *Spine (Phila Pa 1976)* 1993; **18**: 1030-1043 [PMID: 8367771 DOI: 10.1097/00007632-199306150-00013]
- 13 Guha D, Heary RF, Shamji MF. Iatrogenic spondylolisthesis following laminectomy for degenerative lumbar stenosis: systematic review and current concepts. *Neurosurg Focus* 2015; **39**: E9 [PMID: 26424349 DOI: 10.3171/2015.7.FOCUS15259]
- 14 Ahn SS, Kim SH, Kim DW, Lee BH. Comparison of Outcomes of Percutaneous Endoscopic Lumbar Discectomy and Open Lumbar Microdiscectomy for Young Adults: A Retrospective Matched Cohort



- Study. *World Neurosurg* 2016; **86**: 250-258 [PMID: 26409086 DOI: 10.1016/j.wneu.2015.09.047]
- 15 **Lee SH**, Chung SE, Ahn Y, Kim TH, Park JY, Shin SW. Comparative radiologic evaluation of percutaneous endoscopic lumbar discectomy and open microdiscectomy: a matched cohort analysis. *Mt Sinai J Med* 2006; **73**: 795-801 [PMID: 17008941]
- 16 **Ruan W**, Feng F, Liu Z, Xie J, Cai L, Ping A. Comparison of percutaneous endoscopic lumbar discectomy versus open lumbar microdiscectomy for lumbar disc herniation: A meta-analysis. *Int J Surg* 2016; **31**: 86-92 [PMID: 27260312 DOI: 10.1016/j.ijssu.2016.05.061]
- 17 **Qin R**, Liu B, Hao J, Zhou P, Yao Y, Zhang F, Chen X. Percutaneous Endoscopic Lumbar Discectomy Versus Posterior Open Lumbar Microdiscectomy for the Treatment of Symptomatic Lumbar Disc Herniation: A Systemic Review and Meta-Analysis. *World Neurosurg* 2018; **120**: 352-362 [PMID: 30205219 DOI: 10.1016/j.wneu.2018.08.236]
- 18 **Pan L**, Zhang P, Yin Q. Comparison of tissue damages caused by endoscopic lumbar discectomy and traditional lumbar discectomy: a randomised controlled trial. *Int J Surg* 2014; **12**: 534-537 [PMID: 24583364 DOI: 10.1016/j.ijssu.2014.02.015]
- 19 **Shin MH**, Bae JS, Cho HL, Jang IT. Extradiscal Epiduroscopic Percutaneous Endoscopic Discectomy for Upper Lumbar Disc Herniation A Technical Note. *Clin Spine Surg* 2019; **32**: 98-103 [PMID: 30531356 DOI: 10.1097/BSD.0000000000000755]
- 20 **Bae J**, Lee SH, Shin SH, Seo JS, Kim KH, Jang JS. Radiological analysis of upper lumbar disc herniation and spinopelvic sagittal alignment. *Eur Spine J* 2016; **25**: 1382-1388 [PMID: 26818031 DOI: 10.1007/s00586-016-4382-y]
- 21 **Xin Z**, Liao W, Ao J, Qin J, Chen F, Ye Z, Cai Y. A Modified Translaminar Osseous Channel-Assisted Percutaneous Endoscopic Lumbar Discectomy for Highly Migrated and Sequestered Disc Herniations of the Upper Lumbar: Clinical Outcomes, Surgical Indications, and Technical Considerations. *Biomed Res Int* 2017; **2017**: 3069575 [PMID: 28466008 DOI: 10.1155/2017/3069575]
- 22 **Choi G**, Lee SH, Lokhande P, Kong BJ, Shim CS, Jung B, Kim JS. Percutaneous endoscopic approach for highly migrated intracanal disc herniations by foraminoplastic technique using rigid working channel endoscope. *Spine (Phila Pa 1976)* 2008; **33**: E508-E515 [PMID: 18594449 DOI: 10.1097/BRS.0b013e31817bfa1a]
- 23 **Kim HS**, Ju CI, Kim SW, Kim JG. Endoscopic transforaminal suprapedicular approach in high grade inferior migrated lumbar disc herniation. *J Korean Neurosurg Soc* 2009; **45**: 67-73 [PMID: 19274114 DOI: 10.3340/jkns.2009.45.2.67]



Published By Baishideng Publishing Group Inc  
7041 Koll Center Parkway, Suite 160, Pleasanton, CA 94566, USA  
Telephone: +1-925-2238242  
E-mail: [bpgoffice@wjgnet.com](mailto:bpgoffice@wjgnet.com)  
Help Desk: <https://www.f6publishing.com/helpdesk>  
<https://www.wjgnet.com>

