



国内版 国际版

Laparoscopic repair of complete intrathoracic stomach with ir



Chat with Bing

Sign in



ALL

IMAGES

VIDEOS

关闭取词

Add Bing Firefox extension >

26,200 Results

Any time ▾

### An unusual presentation of a patient with intrathoracic ...

<https://www.ncbi.nlm.nih.gov/pmc/articles/PMC2740075>

Jun 09, 2009 · Hematological and **gastro-intestinal evaluations** for other causes of **blood loss** are needed if **iron deficiency anemia** is present in patients with an **intrathoracic stomach** . Our patient had no signs of **blood loss** in the laboratory investigations; therefore no further evaluations were performed.

Cited by: 1

Author: Yavuz M Bilgin, Hans E van der Wiel

Publish Year: 2009

### An unusual presentation of a patient with intrathoracic ...

<https://casesjournal.biomedcentral.com/articles/10.4076/1757-1626-2-7514> ▾

Jun 09, 2009 · **Iron deficiency anemia** could also be a presenting clinical symptom of an **intrathoracic stomach**. **Anemia** could be the result of mechanical irritation of the **stomach** leading to **gastric erosions** and ulcerations causing occult blood loss. Hematological and gastro-intestinal evaluations for other causes of **blood loss** are needed if **iron deficiency anemia** is present in patients with an **intrathoracic stomach** ...

Cited by: 1

Author: Yavuz M Bilgin, Hans E van der Wiel

Publish Year: 2009

### Effect of iron deficiency anemia of laparospic repair of ...

[https://www.researchgate.net/publication/7566679\\_Effect\\_of\\_iron\\_deficiency\\_anemia\\_of...](https://www.researchgate.net/publication/7566679_Effect_of_iron_deficiency_anemia_of...)

Effect of iron deficiency anemia of laparospic repair of large paraesophageal hernias. There was one conversion in a patient with **dense adhesions** from previous **upper abdominal surgery**. Another patient required a **laparoscopic reoperation** for an early recurrence. Major morbidity occurred in three patients and there was no mortality.

### An unusual presentation of a patient with intrathoracic ...

[https://www.researchgate.net/publication/38012394\\_An\\_unusual\\_presentation\\_of\\_a\\_patient...](https://www.researchgate.net/publication/38012394_An_unusual_presentation_of_a_patient...)

**Iron deficiency anemia** in association with a large **paraesophageal hernia** can be treated by **laparoscopic repair** with acceptable morbidity and minimal mortality. The complications of a large ...

### Massive hiatus hernia: Evaluation and surgical management ...

<https://www.sciencedirect.com/science/article/pii/S0022522398704428>

Fig.3.Contrast barium radiograph demonstrating an intrathoracic stomach with complete obstruction at the pylorus. Esophagogastrosopy was performed in all cases by the operating



**Name of Journal:** World Journal of Clinical Cases

**Manuscript NO:** 52453

**Manuscript Type:** CASE REPORT

**Laparoscopic repair of complete intrathoracic stomach with iron deficiency anemia: A case report**

Yasheng D *et al.* Giant paraesophageal HH with IDA

Duolikun Yasheng, Wubulikasimu Wulamu, Yi-Liang Li, Airexiati Tuhongjiang, Kelimu Abudureyimu

## Abstract

### BACKGROUND

Giant paraesophageal hiatal hernias (HH) are very infrequent, and their spectrum of clinical manifestations is large. Giant HH mainly occurs in elderly patients and its relationship between anemia has been reported. For the surgical treatment of large HH, Nissen fundoplication is the most common anti-reflux procedure and the reinforcement of HH repair with a patch (either

## Match Overview

|    |   |    |
|----|---|----|
| 1  | <b>Crossref</b> 107 words<br>Antireflux Surgery, 2015.  | 5% |
| 2  | <b>Crossref</b> 32 words<br>Supakanya Wongrakpanich, Hilit Hassidim, Wikrom Chaivatcharayut, Wuttiorn Manatsathit. "A case of giant hiatal              | 2% |
| 3  | <b>Crossref</b> 27 words<br>Firas W. Obeidat, Reinhold A. Lang, Andreas Knauf, Michael N. Thomas et al. "Laparoscopic anterior hemifundoplica           | 1% |
| 4  | <b>Crossref</b> 25 words<br>D. Collet, G. Luc, L. Chiche. "Management of large para ...<br>sophageal hiatal hernias", Journal of Visceral Surgery, 201  | 1% |
| 5  | <b>Crossref</b> 24 words<br>Guoqing Jiang, Dousheng Bai, Jianjun Qian, Ping Chen, S<br>hengjie Jin. "Modified Laparoscopic Pyloroplasty During L        | 1% |
| 6  | <b>Internet</b> 20 words<br>crawled on 29-Jan-2020<br><a href="https://journals.plos.org">journals.plos.org</a>   | 1% |
| 7  | <b>Crossref</b> 15 words<br>Matar, Andrew, Jad Mroue, Enrico Camporesi, Devanand<br>Mangar, and Michael Albrink. "Large Hiatal Hernia Comp ...          | 1% |
| 8  | <b>Crossref</b> 15 words<br>D. M. Gray, V. Kushnir, G. Kalra, A. Rosenstock, M. A. Alsa<br>kka, A. Patel, G. Sayuk, C. P. Gyawali. "Cameron lesions ... | 1% |
| 9  | <b>Crossref</b> 12 words<br>"The SAGES Manual of Robotic Surgery", Springer Scienc<br>e and Business Media LLC, 2018                                    | 1% |
| 10 | <b>Crossref</b> 12 words<br>Kitagawa, Yuko, Hitoshi Idani, Haruhiro Inoue, Harushi Ud<br>agawa, Ichiro Uyama, Harushi Osugi, Natsuya Katada, Hir        | 1% |

Laparoscopic repair of complete intrathoracic stomach with



ALL

IMAGES

VIDEOS

关闭取词

27,600 Results

Any time ▾

## An unusual presentation of a patient with intrathoracic ...

<https://www.ncbi.nlm.nih.gov/pmc/articles/PMC2740075>

Jun 09, 2009 · **Anemia** could be the result of mechanical irritation of the **stomach** leading to **gastric erosions** and ulcerations causing occult **blood loss**. Hematological and **gastro-intestinal evaluations** for other causes of **blood loss** are needed if **iron deficiency anemia** is present in patients with an **intrathoracic stomach** [ 5 ].

**Cited by:** 1**Author:** Yavuz M Bilgin, Hans E van der Wiel**Publish Year:** 2009

## An iron deficiency anemia of unknown cause: a case report ...

<https://www.ncbi.nlm.nih.gov/pmc/articles/PMC2882551>

An **iron deficiency anemia** of unknown cause: **a case report** involving gossypiboma Fernando Ferraz de Campos , I Fabio Franco , I Linda Ferreira Maximiano , II João Augusto Santos Martinês , III Aloisio Souza Felipe-Silva , IV and Thiago Alexandre Kunitake V

**Cited by:** 7**Author:** Fernando Ferraz de Campos, Fabio Fr...**Publish Year:** 2010

## An unusual presentation of a patient with intrathoracic ...

<https://casesjournal.biomedcentral.com/articles/10.4076/1757-1626-2-7514> ▾

Jun 09, 2009 · **Iron deficiency anemia** could also be a presenting clinical symptom of an **intrathoracic stomach**. **Anemia** could be the result of mechanical irritation of the **stomach** leading to **gastric** erosions and ulcerations causing occult blood loss. Hematological and gastro-intestinal evaluations for other causes of **blood loss** are needed if **iron deficiency anemia** is present in patients with an **intrathoracic stomach** ...

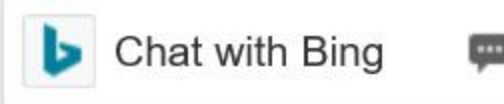
**Cited by:** 1**Author:** Yavuz M Bilgin, Hans E van der Wiel**Publish Year:** 2009





国内版

国际版



YJ



Laparoscopic repair of complete intrathoracic stomach with in



ALL

IMAGES

VIDEOS

27,300 Results

Any time ▼

## An unusual presentation of a patient with intrathoracic ...

<https://www.ncbi.nlm.nih.gov/pmc/articles/PMC2740075>

Jun 09, 2009 · **Anemia** could be the result of mechanical irritation of the **stomach** leading to **gastric erosions** and ulcerations causing occult **blood loss**. Hematological and **gastro-intestinal evaluations** for other causes of **blood loss** are needed if **iron deficiency anemia** is present in patients with an **intrathoracic stomach** [ 5 ].

Cited by: 1

Author: Yavuz M Bilgin, Hans E van der Wiel

Publish Year: 2009

## An iron deficiency anemia of unknown cause: a case report ...

<https://www.ncbi.nlm.nih.gov/pmc/articles/PMC2882551>

An **iron deficiency anemia** of unknown cause: **a case report** involving gossypiboma Fernando Ferraz de Campos , I Fabio Franco , I Linda Ferreira Maximiano , II João Augusto Santos Martinês , III Aloisio Souza Felipe-Silva , IV and Thiago Alexandre Kunitake V

Cited by: 7

Author: Fernando Ferraz de Campos, Fabio Fran...

Publish Year: 2010

## An unusual presentation of a patient with intrathoracic ...

<https://casesjournal.biomedcentral.com/articles/10.4076/1757-1626-2-7514> ▼