

World Journal of *Clinical Cases*

World J Clin Cases 2020 January 26; 8(2): 245-486



**MINIREVIEWS**

- 245 Awareness during emergence from anesthesia: Features and future research directions
Cascella M, Bimonte S, Amruthraj NJ

ORIGINAL ARTICLE**Case Control Study**

- 255 Risk factors for adverse cardiac events in adults with fulminant myocarditis during hospitalization
Kang TD, Ren YL, Zhao H, Ning SQ, Liu WX

Retrospective Study

- 264 Malignant tumors associated with Peutz-Jeghers syndrome: Five cases from a single surgical unit
Zheng Z, Xu R, Yin J, Cai J, Chen GY, Zhang J, Zhang ZT

Observational Study

- 276 Pathogens causing diarrhoea among Bangladeshi children with malignancy: Results from two pilot studies
Karim S, Begum F, Islam A, Tarafdar MA, Begum M, Islam MJ, Malik B, Ahsan MS, Khatami A, Rashid H
- 284 One-year rotational relapse frequency following conventional circumferential supracrestal fiberotomy
Al-Jasser R, Al-Jewair T, Al-Rasheed A

SYSTEMATIC REVIEW

- 294 LINX® reflux management system to bridge the “treatment gap” in gastroesophageal reflux disease: A systematic review of 35 studies
Schizas D, Mastoraki A, Papoutsis E, Giannakoulis VG, Kanavidis P, Tsilimigras D, Ntourakis D, Lyros O, Liakakos T, Moris D

CASE REPORT

- 306 Recurrent lymphoma presenting as painless, chronic intussusception: A case report
Giroux P, Collier A, Nowicki M
- 313 Role of a wireless surface electromyography in dystonic gait in functional movement disorders: A case report
Oh MK, Kim HS, Jang YJ, Lee CH
- 318 Cervicogenic exophthalmos: Possible etiology and pathogenesis
Wu CM, Liao HE, Hsu SW, Lan SJ
- 325 Catheter ablation of premature ventricular complexes associated with false tendons: A case report
Yang YB, Li XF, Guo TT, Jia YH, Liu J, Tang M, Fang PH, Zhang S

- 331** *OFD1* mutation induced renal failure and polycystic kidney disease in a pair of childhood male twins in China
Zhang HW, Su BG, Yao Y
- 337** Japanese encephalitis following liver transplantation: A rare case report
Qi ZL, Sun LY, Bai J, Zhuang HZ, Duan ML
- 343** Malignant solitary fibrous tumor of the pancreas with systemic metastasis: A case report and review of the literature
Geng H, Ye Y, Jin Y, Li BZ, Yu YQ, Feng YY, Li JT
- 353** Esophageal bronchogenic cyst excised by endoscopic submucosal tunnel dissection: A case report
Zhang FM, Chen HT, Ning LG, Xu Y, Xu GQ
- 362** Mesh repair of sacrococcygeal hernia *via* a combined laparoscopic and sacrococcygeal approach: A case report
Dong YQ, Liu LJ, Fu Z, Chen SM
- 370** Durable response to pulsatile icotinib for central nervous system metastases from *EGFR*-mutated non-small cell lung cancer: A case report
Li HY, Xie Y, Yu TT, Lin YJ, Yin ZY
- 377** Argon-helium cryoablation for thoracic vertebrae with metastasis of hepatocellular carcinoma-related hepatitis B: A case report
Tan YW, Ye Y, Sun L
- 382** Brainstem folding in an influenza child with Dandy-Walker variant
Li SY, Li PQ, Xiao WQ, Liu HS, Yang SD
- 390** Irreversible electroporation for liver metastasis from pancreatic cancer: A case report
Ma YY, Shi JJ, Chen JB, Xu KC, Niu LZ
- 398** Cryoablation for liver metastasis from solid pseudopapillary tumor of the pancreas: A case report
Ma YY, Chen JB, Shi JJ, Niu LZ, Xu KC
- 404** Goodpasture syndrome and hemorrhage after renal biopsy: A case report
Li WL, Wang X, Zhang SY, Xu ZG, Zhang YW, Wei X, Li CD, Zeng P, Luan SD
- 410** Eye metastasis in lung adenocarcinoma mimicking anterior scleritis: A case report
Chen HF, Wang WX, Li XF, Wu LX, Zhu YC, Du KQ, Xu CW
- 415** Myocarditis presenting as typical acute myocardial infarction: A case report and review of the literature
Hou YM, Han PX, Wu X, Lin JR, Zheng F, Lin L, Xu R

- 425** Excellent response of severe aplastic anemia to treatment of gut inflammation: A case report and review of the literature
Zhao XC, Zhao L, Sun XY, Xu ZS, Ju B, Meng FJ, Zhao HG
- 436** Spontaneous regression of stage III neuroblastoma: A case report
Liu J, Wu XW, Hao XW, Duan YH, Wu LL, Zhao J, Zhou XJ, Zhu CZ, Wei B, Dong Q
- 444** Efficacy of comprehensive rehabilitation therapy for cheekrein deformity: A case report
Feng XJ, Jiang Y, Wu JX, Zhou Y
- 451** Analysis of pathogenetic process of fungal rhinosinusitis: Report of two cases
Wang LL, Chen FJ, Yang LS, Li JE
- 464** Utility of multiple endoscopic techniques in differential diagnosis of gallbladder adenomyomatosis from gallbladder malignancy with bile duct invasion: A case report
Wen LJ, Chen JH, Chen YJ, Liu K
- 471** Transorbital nonmissile penetrating brain injury: Report of two cases
Xue H, Zhang WT, Wang GM, Shi L, Zhang YM, Yang HF
- 479** Multiple organ dysfunction and rhabdomyolysis associated with moonwort poisoning: Report of four cases
Li F, Chen AB, Duan YC, Liao R, Xu YW, Tao LL

ABOUT COVER

Editorial Board Member of *World Journal of Clinical Cases*, Forhad Chowdhury, FCPS, Assistant Professor, Department of Neurosurgery, National institute of neurosciences and hospital, Dhaka 1207, Bangladesh

AIMS AND SCOPE

The primary aim of *World Journal of Clinical Cases* (WJCC, *World J Clin Cases*) is to provide scholars and readers from various fields of clinical medicine with a platform to publish high-quality clinical research articles and communicate their research findings online.

WJCC mainly publishes articles reporting research results and findings obtained in the field of clinical medicine and covering a wide range of topics, including case control studies, retrospective cohort studies, retrospective studies, clinical trials studies, observational studies, prospective studies, randomized controlled trials, randomized clinical trials, systematic reviews, meta-analysis, and case reports.

INDEXING/ABSTRACTING

The WJCC is now indexed in PubMed, PubMed Central, Science Citation Index Expanded (also known as SciSearch®), and Journal Citation Reports/Science Edition. The 2019 Edition of Journal Citation Reports cites the 2018 impact factor for WJCC as 1.153 (5-year impact factor: N/A), ranking WJCC as 99 among 160 journals in Medicine, General and Internal (quartile in category Q3).

RESPONSIBLE EDITORS FOR THIS ISSUE

Responsible Electronic Editor: Ji-Hong Liu

Proofing Production Department Director: Xiang Li

NAME OF JOURNAL

World Journal of Clinical Cases

ISSN

ISSN 2307-8960 (online)

LAUNCH DATE

April 16, 2013

FREQUENCY

Semimonthly

EDITORS-IN-CHIEF

Dennis A Bloomfield, Bao-Gan Peng, Sandro Vento

EDITORIAL BOARD MEMBERS

<https://www.wjnet.com/2307-8960/editorialboard.htm>

EDITORIAL OFFICE

Jin-Lei Wang, Director

PUBLICATION DATE

January 26, 2020

COPYRIGHT

© 2020 Baishideng Publishing Group Inc

INSTRUCTIONS TO AUTHORS

<https://www.wjnet.com/bpg/gerinfo/204>

GUIDELINES FOR ETHICS DOCUMENTS

<https://www.wjnet.com/bpg/GerInfo/287>

GUIDELINES FOR NON-NATIVE SPEAKERS OF ENGLISH

<https://www.wjnet.com/bpg/gerinfo/240>

PUBLICATION MISCONDUCT

<https://www.wjnet.com/bpg/gerinfo/208>

ARTICLE PROCESSING CHARGE

<https://www.wjnet.com/bpg/gerinfo/242>

STEPS FOR SUBMITTING MANUSCRIPTS

<https://www.wjnet.com/bpg/GerInfo/239>

ONLINE SUBMISSION

<https://www.f6publishing.com>

Spontaneous regression of stage III neuroblastoma: A case report

Jie Liu, Xiong-Wei Wu, Xi-Wei Hao, Yu-He Duan, Ling-Ling Wu, Jing Zhao, Xian-Jun Zhou, Cheng-Zhan Zhu, Bin Wei, Qian Dong

ORCID number: Jie Liu (0000-0002-8185-9938); Xiong-Wei Wu (0000-0001-6267-1705); Xi-Wei Hao (0000-0003-2039-5313); Yu-He Duan (0000-0002-3957-3549); Ling-Ling Wu (0000-0003-4857-6343); Jing Zhao (0000-0003-4715-7630); Xian-Jun Zhou (0000-0003-1430-186X); Cheng-Zhan Zhu (0000-0002-3677-3887); Bin Wei (0000-0003-3015-3166); Qian Dong (0000-0002-4165-5930).

Author contributions: Liu J and Dong Q designed the research; Wu XW and Hao XW obtained the clinical data and measured the radiological parameters; Duan YH and Wu LL were responsible for the staining of pathological sections; Zhao J and Zhou XJ performed the three-dimensional image reconstruction; Zhu CZ and Wei B prepared the tables and figures; Liu J prepared the manuscript; Dong Q revised the manuscript.

Supported by Qingdao Civic Science and Technology Program, No. 17-3-3-8-nsh.

Informed consent statement: Written informed consent was obtained from the patient for publication of this report and any accompanying images.

Conflict-of-interest statement: The authors declare that they have no conflict of interest.

CARE Checklist (2016) statement: The authors have read the CARE Checklist (2016), and the manuscript was prepared and revised according to the CARE Checklist (2016).

Jie Liu, Xiong-Wei Wu, Xi-Wei Hao, Yu-He Duan, Ling-Ling Wu, Jing Zhao, Xian-Jun Zhou, Qian Dong, Department of Pediatric Surgery, Affiliated Hospital of Qingdao University, Qingdao 266000, Shandong Province, China

Jie Liu, Department of Pediatric Surgery, Yijishan Hospital of Wannan Medical College, Wuhu 241000, Anhui Province, China

Cheng-Zhan Zhu, Bin Wei, Shandong Key Laboratory of Digital Medicine and Computer Assisted Surgery, Qingdao 266000, Shandong Province, China

Corresponding author: Qian Dong, MD, Professor, Department of Pediatric Surgery, Affiliated Hospital of Qingdao University, No. 16, Jiangsu Road, Shinan District, Qingdao 266000, Shandong Province, China. dongqianyz1@163.com

Abstract

BACKGROUND

Neuroblastoma (NB) is the most common type of extracranial solid tumour in children. The overall prognosis of NB is poor, but at the same time, NB shows significant clinical diversity. NB can demonstrate spontaneous regression or can differentiate into benign ganglioneuroma.

CASE SUMMARY

This study retrospectively analyzed the clinical data of a patient with spontaneous regression of stage III NB who was admitted in May 2015. Studies of the spontaneous regression of NB published from October 1946 to September 2019 were retrieved through PubMed. The clinical manifestations, diagnosis, treatment, and follow-up results were analysed.

CONCLUSION

Spontaneous regression of stage III NB is rare in the clinic. The report of this case is an important supplement to the study of the spontaneous regression of NB.

Key words: Neuroblastoma; Stage; Neoplasm regression; Spontaneous; Case report

©The Author(s) 2020. Published by Baishideng Publishing Group Inc. All rights reserved.

Core tip: Neuroblastoma (NB) is the most common type of extracranial solid tumour in children. The overall prognosis of NB is poor, but at the same time, NB shows significant clinical diversity. NB can demonstrate spontaneous regression or can differentiate into benign ganglioneuroma. This study retrospectively analyzed the clinical data of a patient with spontaneous regression of stage III NB who was admitted in May

Open-Access: This article is an open-access article which was selected by an in-house editor and fully peer-reviewed by external reviewers. It is distributed in accordance with the Creative Commons Attribution Non Commercial (CC BY-NC 4.0) license, which permits others to distribute, remix, adapt, build upon this work non-commercially, and license their derivative works on different terms, provided the original work is properly cited and the use is non-commercial. See: <http://creativecommons.org/licenses/by-nc/4.0/>

Manuscript source: Unsolicited manuscript

Received: November 4, 2019

Peer-review started: November 4, 2019

First decision: December 4, 2019

Revised: December 5, 2019

Accepted: December 22, 2019

Article in press: December 22, 2019

Published online: January 26, 2020

P-Reviewer: Munoz M, Kupeli S

S-Editor: Dou Y

L-Editor: Wang TQ

E-Editor: Xing YX



2015. Studies of the spontaneous regression of NB published from October 1946 to September 2019 were retrieved through PubMed. The clinical manifestations, diagnosis, treatment, and follow-up results were analysed. Spontaneous regression of stage III NB is rare in the clinic. The report of this case is an important supplement to the study of the spontaneous regression of NB.

Citation: Liu J, Wu XW, Hao XW, Duan YH, Wu LL, Zhao J, Zhou XJ, Zhu CZ, Wei B, Dong Q. Spontaneous regression of stage III neuroblastoma: A case report. *World J Clin Cases* 2020; 8(2): 436-443

URL: <https://www.wjgnet.com/2307-8960/full/v8/i2/436.htm>

DOI: <https://dx.doi.org/10.12998/wjcc.v8.i2.436>

INTRODUCTION

Neuroblastoma (NB) is the most common type of extracranial solid tumour in children. It originates from primitive neural crest cells^[1]. NB occurs mainly in the retroperitoneum (mainly, the adrenal gland), mediastinum, pelvic cavity and neck as well as in the central nervous system^[2]. The overall prognosis of NB is poor, but at the same time, NB shows significant clinical diversity. NB can demonstrate spontaneous regression or can differentiate into benign ganglioneuroma^[3]. The spontaneous regression of stage IV NB has been reported in the literature^[4], but the occurrence of stage III NB is extremely rare, with only a few reports (Table 1)^[5-7]. This paper reports the case of a patient with spontaneous regression of stage III NB admitted in May 2015. A literature review was conducted to explore the regularity and mechanism of regression and to summarize the diagnosis and treatment. This study was approved by the Ethics Committee of the Affiliated Hospital of Qingdao University. Medical records and pictures were obtained *via* informed consent from the patient's parents or legal guardians, and written informed consent was obtained from the parents.

CASE PRESENTATION

Chief complaints

An 11-mo-old girl had an abdominal mass during a physical examination two days before her hospitalization.

History of present illness

Two days ago, the patient had abdominal ultrasound examination which revealed an abdominal mass.

History of past illness

The patient had a history of dilated cardiomyopathy.

Family history

The patient had no family history.

Physical examination

The abdomen was flat and soft, and a hard mass was palpated in the right abdomen. The boundary was not clear, and the activity was poor. There was no tenderness or rebound pain in the abdomen, and the mass could not be palpated under the ribs near the liver and spleen.

Imaging examinations

Abdominal enhanced computed tomography (CT) examination was performed on June 2, 2015, and three-dimensional (3D) reconstruction was performed by using a computer-assisted surgical system (Hisense CAS)^[8]. The CT results showed mass shadows of retroperitoneal lobulated soft tissue with a maximum cross section of 93 mm × 82 mm, and these shadows were considered to be possible NB. Hisense CAS 3D imaging showed that the tumour volume was 193.6 mL, and part of the boundary was infiltrating, with lesions surrounding the major retroperitoneal vessels such as the inferior vena cava, renal artery, renal vein, and abdominal aorta (Figures 1 and 2).

Table 1 Statistics from the reports of stage III NB spontaneous regression

Ref.	Country	Publication time	Number of study cases	Number of stage III cases	Number of stage III regression cases
Iwata <i>et al</i> ^[5]	Japan	1995	1	1	1
Hero <i>et al</i> ^[6]	Germany	2008	340	70	11
Fawzy <i>et al</i> ^[7]	Egypt	2019	32	4	1

NB: Neuroblastoma.

Pathological examination

Tumour biopsy specimens were diagnosed as NB. Immunohistochemical staining showed that Syn, NSE, and CD56 were positive, CgA was suspiciously positive, and CD99 was negative (Figure 3).

FINAL DIAGNOSIS

The normal bone marrow biopsy results suggested that the patient should be diagnosed with stage III NB.

TREATMENT

After discussion with the treatment group, it was suggested that the tumour could not be completely removed and that chemotherapy should be administered first. However, the parents of the children refused preoperative chemotherapy due to concerns about the side effects of chemotherapy drugs and left the hospital by themselves.

OUTCOME AND FOLLOW-UP

Abdominal B-ultrasound re-examination after 2 mo showed that the retroperitoneal tumour volume was approximately 46 mm × 52 mm × 46 mm, which was significantly smaller than before. Considering the possibility of spontaneous regression of the tumour, it was recommended that observation and treatment be continued. During the follow-up period from 2015 to 2019, the child was re-examined *via* abdominal CT six times (Figure 4 and Table 2). The patient was followed for 4 years without recurrence or distant metastasis. The child generally has a good condition, with growth and development similar to those of children of the same age.

DISCUSSION

NB is one of the most common types of malignant solid tumours in infants. It is not only insidious in onset but also rapidly develops. Despite some progress in treatment, the 5-year overall survival rate of the disease in high-risk groups is still very low, which has become a difficult problem in medical research^[9]. Cole *et al*^[10] first reported a special biological behaviour of spontaneous regression of tumours in 1956 and found that the incidence of spontaneous regression of malignant tumours was approximately 1/60000-100000, with the highest NB regression rate. At present, the mechanism of NB spontaneous regression is not very clear, and it is still a hot research topic. Nakagawara *et al*^[11] found that nerve growth factor could promote the growth and differentiation of NB tumour cells, and apoptosis occurred within 1 wk after removing the factor. Zhu *et al*^[12] found that UNC5D could indirectly regulate the effect of nerve growth factor on NB. Some scholars believe that the host immune response may be one of the reasons for the natural regression of NB. Inflammation and the tumour microenvironment may have an important impact on the prognosis of NB^[13]. Decock *et al*^[14] described the characteristics of the DNA methylation in patients with stage IVS NB for the first time, showing that such patients have unique DNA methylation patterns. This finding may be helpful for the study of new mechanisms of DNA-specific tumour biology and spontaneous regression in patients with stage IVS NB. Brodeur^[15] reported that the expression of TrkA in NB is related to good clinical and biological characteristics. The prognosis of these patients is good, but the case did

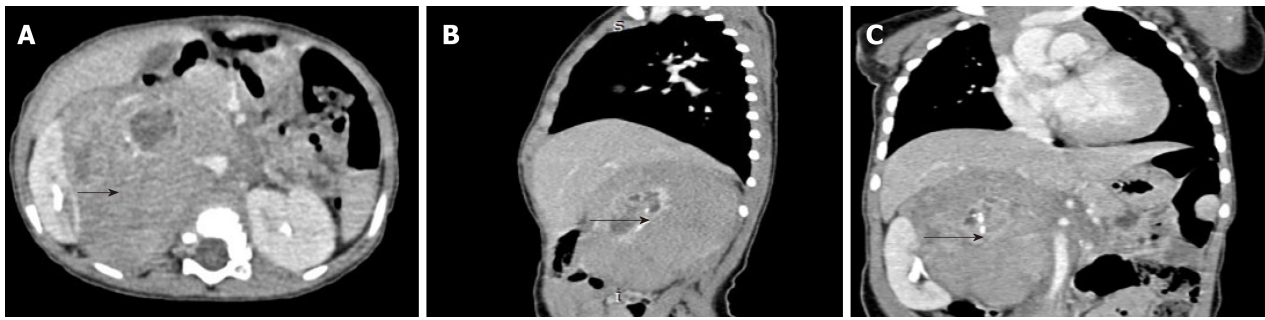

Figure 1 Plain and enhanced abdominal computed tomography scans on admission showed a lobulated soft tissue mass with a maximum cross-sectional area of 93 mm × 82 mm. A: Cross section; B: Sagittal plane; C: Coronal plane.

not undergo TrkA test due to the small amount of tumor fine needle aspiration samples.

Some scholars have also studied the law of spontaneous regression of NB. Evans *et al*^[16] reported in 1971 that there was a stage with the highest degradation rate in NB, namely, the IVS stage. The age of onset of patients with stage IVS NB is less than 1 years old. The stage of primary tumours is usually stage I, IIA, or IIB. The distant metastasis of tumours is limited to the skin, liver, and/or bone marrow. In addition, bone marrow biopsy results require that the proportion of neuroblasts in all nucleated cells must be less than 10%. The results of bone marrow scanning by metaiodobenzylguanidine imaging should be negative^[17]. Some scholars believe that spontaneous regression usually occurs within 6 mo after birth. For this age group or for the limited types of NB with diameters less than 5 cm, we can use the method of “Wait and See” without implementing any treatment measures^[18]. Yoneda *et al*^[19] studied the abovementioned observations and treatment of stages I and II NB with diameters less than 5 cm. A total of eight children were enrolled in the group. The study found that five children had spontaneous regression. Fritsch *et al*^[20] used the same treatment, and three of five patients had spontaneous regression. These studies regularly detected tumour markers *via* magnetic resonance imaging, abdominal B-mode ultrasound, or chest X-ray during follow-up. If there were signs of tumour enlargement, tumour marker elevation, or metastasis, and if parents have the intention of surgery, the researchers immediately stopped observations and provided surgical treatment^[19]. It was found that spontaneous regression also exists in children aged over 6 months and with tumours larger than 5 cm in diameter, but the researchers also pointed out that the “Wait and See” strategy for stage III NB and large tumours should be carried out cautiously^[7].

Some scholars believe that spontaneous regression of NB is not necessarily confined to stage IVS and may occur at any stage of the disease^[15]. However, the literature published from October 1946 to September 2019 was searched through PubMed for studies on stage III NB spontaneous regression, and only three studies were found to have reported cases of stage III NB spontaneous regression (Table 1). In 1995, Iwata *et al*^[5] reported a tumour size of approximately 55 mm × 38 mm × 36 mm in the case of a 6-mo-old male child with NB. In a patient with upper respiratory tract infections awaiting surgical treatment, re-examination showed that the tumour shrank by approximately 50% when the patient was re-hospitalized for surgery, but the patient finally underwent surgical treatment and complete resection. NB was diagnosed postoperatively, and no further treatment was given. A 3-year follow-up showed that the patient survived well without recurrence or metastasis. Hero *et al*^[6] studied a total of 340 NB patients from 1995 to 2004, including 70 patients with stage III NB. The researchers completed follow-up for up to 10 years and found that 44 of all patients (including those with stages I, II, III, IV, and IVS) had spontaneous regression, including 11 cases of stage III NB. Fawzy *et al*^[7] reported a total of 32 NB children aged less than 1.5 years from 2007 to 2016, among whom four were stage III patients, three were treated with chemotherapy intervention, and only one had spontaneous regression, with good follow-up survival. However, the authors did not specify the specific follow-up time of this patient.

Generally, spontaneous regression of stage III NB is extremely rare. At present, the mainstream view of treatment is still based on the combination of chemotherapy and surgery. Treatment requires that primary tumours be removed and metastatic lymph nodes be cleared on the premise of patient safety. If the tumours cannot be completely removed because they surround important vessels or organs, partial excision of the tumours is feasible during the operation. Postoperative radiotherapy or

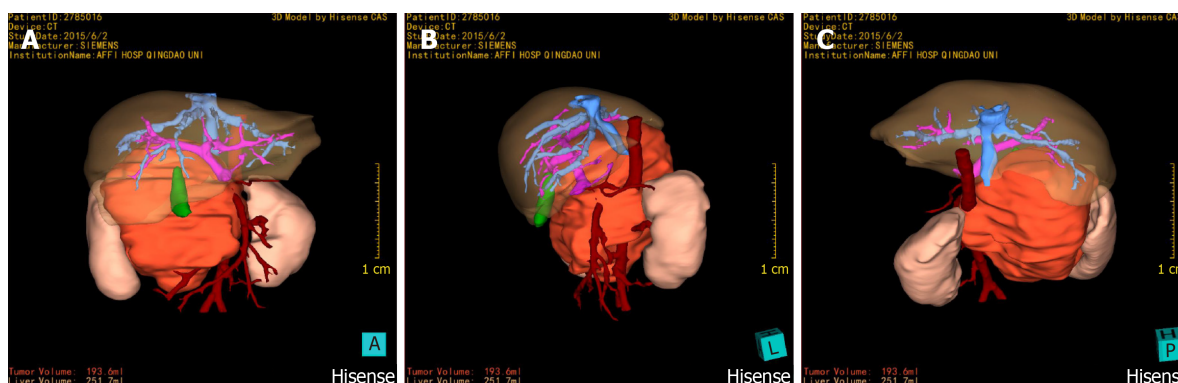


Figure 2 The volume of the tumour (red part) was 193.6 mL according to the three-dimensional reconstruction of the abdominal enhanced computed tomography images with a computer-assisted surgery system (Hisense CAS) upon admission. The boundary of the tumour was infiltrative. The tumour was surrounded by important retroperitoneal vessels such as the inferior vena cava, renal artery, renal vein, and abdominal aorta, as seen by rotating the three-dimensional images at any angle. A: Positive image; B: Right-side image; C: Posterior and anterior images.

chemotherapy can be used to further treat residual tumours^[21].

CONCLUSION

This paper reports that the tumour gradually shrank during the follow-up period. As of the date of publication, the patient has been followed for 4 years. No tumour recurrence or metastasis has been found, and the child has good survival. We realize that although NB spontaneous regression is more common in stage IVS, it may still occur in other stages of the disease. If there are obvious signs of regression in the course of diagnosis and treatment, the tumour can also be temporarily observed and treated, but regular follow-up is required. If there are signs of tumour enlargement or other metastasis, observation and waiting for treatment should be stopped in time. In conclusion, stage III spontaneous regression of NB is rare in the clinic. The report of this case is an important supplement to the study of the spontaneous regression of NB.

Table 2 Data of patient visits and follow-up examinations

Age (mo)	Abdominal CT examination time	Maximum transverse value of abdominal CT (mm)	Image number ¹
11	June, 2015	93 × 82	4A
16	October, 2015	35 × 21	4B
18	December, 2015	31 × 19	4C
26	August, 2016	28 × 17	4D
38	August, 2017	26 × 15	4E
50	October, 2018	23 × 14	4F
61	July, 2019	11 × 8	4G

¹The image number in the table corresponds to the number of computed tomography images in Figure 4. CT: Computed tomography.

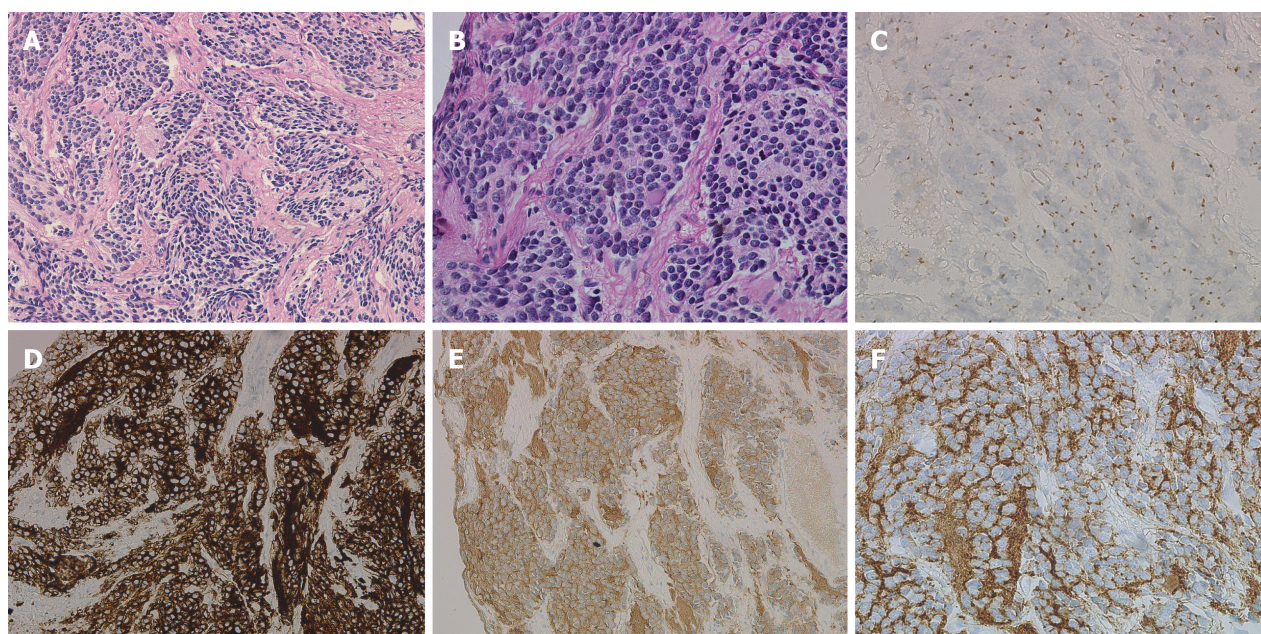


Figure 3 Histological and pathological images of the tumour biopsy specimens. A: HE staining, ×200; B: HE staining, ×400; C: CgA (suspiciously positive); D: CD56 (positive); E: NSE (positive); F: Syn (positive).

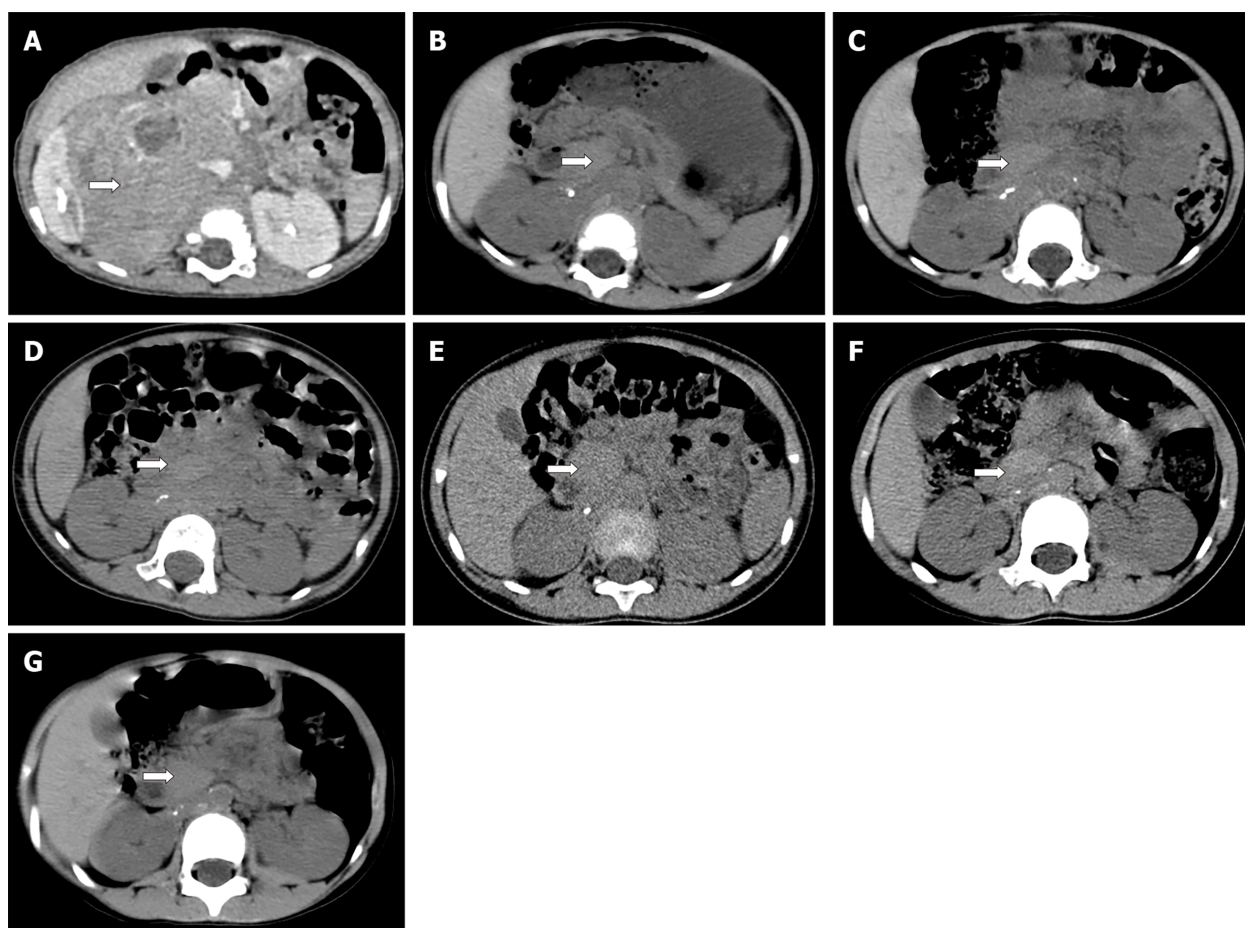


Figure 4 Abdominal computed tomography examination and follow-up images of the patient from June 2015 to July 2019; the arrow indicates the tumour. During the follow-up period, the tumour gradually shrank, showing typical spontaneous regression. A: June 2015; B: October 2015; C: December 2015; D: August 2016; E: August 2017; F: October 2018; G: July 2019.

ACKNOWLEDGEMENTS

We are grateful to our radiology department for their help with the radiological parameter's measurement.

REFERENCES

- 1 Zhi Y, Lu H, Duan Y, Sun W, Guan G, Dong Q, Yang C. Involvement of the nuclear factor- κ B signaling pathway in the regulation of CXCR4 chemokine receptor-4 expression in neuroblastoma cells induced by tumor necrosis factor- α . *Int J Mol Med* 2015; **35**: 349-357 [PMID: 25503960 DOI: 10.3892/ijmm.2014.2032]
- 2 Louis CU, Shohet JM. Neuroblastoma: molecular pathogenesis and therapy. *Annu Rev Med* 2015; **66**: 49-63 [PMID: 25386934 DOI: 10.1146/annurev-med-011514-023121]
- 3 Brodeur GM. Neuroblastoma: biological insights into a clinical enigma. *Nat Rev Cancer* 2003; **3**: 203-216 [PMID: 12612655 DOI: 10.1038/nrc1014]
- 4 Nakagawara A, Li Y, Izumi H, Muramori K, Inada H, Nishi M. Neuroblastoma. *Jpn J Clin Oncol* 2018; **48**: 214-241 [PMID: 29378002 DOI: 10.1093/jco/hyx176]
- 5 Iwata M, Koshinaga T, Okabe I, Kurosu Y, Esumi M. Biological characteristics of neuroblastoma with spontaneous tumor reduction: a case report. *J Pediatr Surg* 1995; **30**: 722-723 [PMID: 7623238 DOI: 10.1016/0022-3468(95)90700-9]
- 6 Hero B, Simon T, Spitz R, Ernestus K, Gnekow AK, Scheel-Walter HG, Schwabe D, Schilling FH, Benz-Bohm G, Berthold F. Localized infant neuroblastomas often show spontaneous regression: results of the prospective trials NB95-S and NB97. *J Clin Oncol* 2008; **26**: 1504-1510 [PMID: 18349403 DOI: 10.1200/JCO.2007.12.3349]
- 7 Fawzy M, El Zomor H, El Menawi S, Elkinaai N, Ahmed G, Refaat A, Elahmadawy M, Zaghloul M. Watch and See Strategy in Selected Neuroblastoma Case Scenarios: Success and Limitations. *J Pediatr Hematol Oncol* 2019; **41**: e384-e387 [PMID: 30676440 DOI: 10.1097/MPH.0000000000001421]
- 8 Zhang G, Zhou XJ, Zhu CZ, Dong Q, Su L. Usefulness of three-dimensional(3D) simulation software in hepatectomy for pediatric hepatoblastoma. *Surg Oncol* 2016; **25**: 236-243 [PMID: 27566028 DOI: 10.1016/j.suronc.2016.05.023]
- 9 Maris JM, Hogarty MD, Bagatell R, Cohn SL. Neuroblastoma. *Lancet* 2007; **369**: 2106-2120 [PMID: 17535760 DOI: 10.1016/S0140-6736(07)61311-1]

- 17586306 DOI: [10.1016/S0140-6736\(07\)60983-0](https://doi.org/10.1016/S0140-6736(07)60983-0)]
- 10 **Cole WH**, Everson TC. Spontaneous regression of cancer: preliminary report. *Ann Surg* 1956; **144**: 366-383 [PMID: [13363274](https://pubmed.ncbi.nlm.nih.gov/13363274/) DOI: [10.1097/0000658-195609000-00007](https://doi.org/10.1097/0000658-195609000-00007)]
- 11 **Nakagawara A**, Brodeur GM. Role of neurotrophins and their receptors in human neuroblastomas: a primary culture study. *Eur J Cancer* 1997; **33**: 2050-2053 [PMID: [9516851](https://pubmed.ncbi.nlm.nih.gov/9516851/) DOI: [10.1016/s0959-8049\(97\)00280-3](https://doi.org/10.1016/s0959-8049(97)00280-3)]
- 12 **Zhu Y**, Li Y, Haraguchi S, Yu M, Ohira M, Ozaki T, Nakagawa A, Ushijima T, Isogai E, Koseki H, Nakamura Y, Kong C, Mehlen P, Arakawa H, Nakagawara A. Dependence receptor UNC5D mediates nerve growth factor depletion-induced neuroblastoma regression. *J Clin Invest* 2013; **123**: 2935-2947 [PMID: [23778138](https://pubmed.ncbi.nlm.nih.gov/23778138/) DOI: [10.1172/JCI65988](https://doi.org/10.1172/JCI65988)]
- 13 **Vanichapol T**, Chutipongtanate S, Anurathapan U, Hongeng S. Immune Escape Mechanisms and Future Prospects for Immunotherapy in Neuroblastoma. *Biomed Res Int* 2018; **2018**: 1812535 [PMID: [29682521](https://pubmed.ncbi.nlm.nih.gov/29682521/) DOI: [10.1155/2018/1812535](https://doi.org/10.1155/2018/1812535)]
- 14 **Decock A**, Ongenaert M, De Wilde B, Brichard B, Noguera R, Speleman F, Vandesompele J. Stage 4S neuroblastoma tumors show a characteristic DNA methylation portrait. *Epigenetics* 2016; **11**: 761-771 [PMID: [27599161](https://pubmed.ncbi.nlm.nih.gov/27599161/) DOI: [10.1080/15592294.2016.1226739](https://doi.org/10.1080/15592294.2016.1226739)]
- 15 **Brodeur GM**. Spontaneous regression of neuroblastoma. *Cell Tissue Res* 2018; **372**: 277-286 [PMID: [29305654](https://pubmed.ncbi.nlm.nih.gov/29305654/) DOI: [10.1007/s00441-017-2761-2](https://doi.org/10.1007/s00441-017-2761-2)]
- 16 **Evans AE**, D'Angio GJ, Randolph J. A proposed staging for children with neuroblastoma. Children's cancer study group A. *Cancer* 1971; **27**: 374-378 [PMID: [5100400](https://pubmed.ncbi.nlm.nih.gov/5100400/) DOI: [10.1002/1097-0142\(197102\)27:2<374::aid-cnrcr2820270221>3.0.co;2-g](https://doi.org/10.1002/1097-0142(197102)27:2<374::aid-cnrcr2820270221>3.0.co;2-g)]
- 17 **Twist CJ**, Naranjo A, Schmidt ML, Tenney SC, Cohn SL, Meany HJ, Mattei P, Adkins ES, Shimada H, London WB, Park JR, Matthay KK, Maris JM. Defining Risk Factors for Chemotherapeutic Intervention in Infants With Stage 4S Neuroblastoma: A Report From Children's Oncology Group Study ANBL0531. *J Clin Oncol* 2019; **37**: 115-124 [PMID: [30444686](https://pubmed.ncbi.nlm.nih.gov/30444686/) DOI: [10.1200/JCO.18.00419](https://doi.org/10.1200/JCO.18.00419)]
- 18 **Cozzi DA**, Mele E, Ceccanti S, Natale F, Clerico A, Schiavetti A, Dominici C. Long-term follow-up of the "wait and see" approach to localized perinatal adrenal neuroblastoma. *World J Surg* 2013; **37**: 459-465 [PMID: [23135423](https://pubmed.ncbi.nlm.nih.gov/23135423/) DOI: [10.1007/s00268-012-1837-0](https://doi.org/10.1007/s00268-012-1837-0)]
- 19 **Yoneda A**, Oue T, Imura K, Inoue M, Yagi K, Kawa K, Nishikawa M, Morimoto S, Nakayama M. Observation of untreated patients with neuroblastoma detected by mass screening: a "wait and see" pilot study. *Med Pediatr Oncol* 2001; **36**: 160-162 [PMID: [11464874](https://pubmed.ncbi.nlm.nih.gov/11464874/) DOI: [10.1002/1096-911X\(20010101\)36:1<160::AID-MPO1039>3.0.CO;2-G](https://doi.org/10.1002/1096-911X(20010101)36:1<160::AID-MPO1039>3.0.CO;2-G)]
- 20 **Fritsch P**, Kerbl R, Lackner H, Urban C. "Wait and see" strategy in localized neuroblastoma in infants: an option not only for cases detected by mass screening. *Pediatr Blood Cancer* 2004; **43**: 679-682 [PMID: [15390301](https://pubmed.ncbi.nlm.nih.gov/15390301/) DOI: [10.1002/pbc.20126](https://doi.org/10.1002/pbc.20126)]
- 21 **Adkins ES**, Sawin R, Gerbing RB, London WB, Matthay KK, Haase GM. Efficacy of complete resection for high-risk neuroblastoma: a Children's Cancer Group study. *J Pediatr Surg* 2004; **39**: 931-936 [PMID: [15185228](https://pubmed.ncbi.nlm.nih.gov/15185228/) DOI: [10.1016/j.jpedsurg.2004.02.041](https://doi.org/10.1016/j.jpedsurg.2004.02.041)]



Published By Baishideng Publishing Group Inc
7041 Koll Center Parkway, Suite 160, Pleasanton, CA 94566, USA
Telephone: +1-925-3991568
E-mail: bpgoffice@wjgnet.com
Help Desk: <https://www.f6publishing.com/helpdesk>
<https://www.wjgnet.com>

