

World Journal of *Clinical Cases*

World J Clin Cases 2020 March 26; 8(6): 1002-1187





REVIEW

- 1002** Gut microbiota and nutrient interactions with skin in psoriasis: A comprehensive review of animal and human studies
Damiani G, Bragazzi NL, McCormick TS, Pigatto PDM, Leone S, Pacifico A, Todorovic D, Di Franco S, Alfieri A, Fiore M
- 1013** Microbiota-gut-brain axis and its affect inflammatory bowel disease: Pathophysiological concepts and insights for clinicians
Sinagra E, Utzeri E, Morreale GC, Fabbri C, Pace F, Anderloni A

MINIREVIEWS

- 1026** Distal esophageal spasm: Update on diagnosis and management in the era of high-resolution manometry
Gorti H, Samo S, Shahnava N, Qayed E

ORIGINAL ARTICLE

Retrospective Study

- 1033** Clinical course of percutaneous cholecystostomies: A cross-sectional study
Er S, Berkem H, Özden S, Birben B, Çetinkaya E, Tez M, Yüksel BC
- 1042** Clinical characteristics and 28-d outcomes of bacterial infections in patients with hepatitis B virus-related acute-on-chronic liver failure
Li C, Su HB, Liu XY, Hu JH
- 1056** Application of hybrid operating rooms for treating spinal dural arteriovenous fistula
Zhang N, Xin WQ
- 1065** Ruxolitinib add-on in corticosteroid-refractory graft-*vs*-host disease after allogeneic stem cell transplantation: Results from a retrospective study on 38 Chinese patients
Dang SH, Liu Q, Xie R, Shen N, Zhou S, Shi W, Liu W, Zou P, You Y, Zhong ZD

META-ANALYSIS

- 1074** Laparoscopic surgery for early gallbladder carcinoma: A systematic review and meta-analysis
Feng X, Cao JS, Chen MY, Zhang B, Juengpanich S, Hu JH, Topatana W, Li SJ, Shen JL, Xiao GY, Cai XJ, Yu H
- 1087** Long-term clinical performance of flapless implant surgery compared to the conventional approach with flap elevation: A systematic review and meta-analysis
Cai H, Liang X, Sun DY, Chen JY

CASE REPORT

- 1104** Diagnosis and management of glandular papilloma of lung: A case report
Wu CW, Chen A, Huang TW
- 1108** Abnormal serum carbohydrate antigen 19-9 levels in a patient with splenic retiform haemangioendothelioma concomitant with hepatic amyloidosis: A case report
Sun KD, Zhang YJ, Zhu LP, Yang B, Wang SY, Yu ZH, Zhang HC, Chen X
- 1116** Hepatoid carcinoma of the pancreas: A case report and review of the literature
Zeng SX, Tan SW, Fong CJTH, Liang Q, Zhao BL, Liu K, Guo JX, Tao J
- 1129** Successful treatment of systemic sclerosis complicated by ventricular tachycardia with a cardiac resynchronization therapy-defibrillator: A case report
Chen YY, Yan H, Zhu JH
- 1137** Metabolic and genetic assessments interpret unexplained aggressive pulmonary hypertension induced by methylmalonic acidemia: A case report
Liao HY, Shi XQ, Li YF
- 1142** Hyoid-complex elevation and stimulation technique restores swallowing function in patients with lateral medullary syndrome: Two case reports
Jiang YE, Lyu QQ, Lin F, You XT, Jiang ZL
- 1150** Microscopic removal of type III dens invaginatus and preparation of apical barrier with mineral trioxide aggregate in a maxillary lateral incisor: A case report and review of literature
Liu J, Zhang YR, Zhang FY, Zhang GD, Xu H
- 1158** Cerebral venous sinus thrombosis following transsphenoidal surgery for craniopharyngioma: A case report
Chang T, Yang YL, Gao L, Li LH
- 1164** Hepatoid adenocarcinoma of the stomach: Thirteen case reports and review of literature
Zhang ZR, Wu J, Li HW, Wang T
- 1172** Growth hormone therapy for children with KBG syndrome: A case report and review of literature
Ge XY, Ge L, Hu WW, Li XL, Hu YY
- 1180** Laparoscopic repair of complete intrathoracic stomach with iron deficiency anemia: A case report
Yasheng D, Wulamu W, Li YL, Tuhongjiang A, Abudureyimu K

ABOUT COVER

Editorial Board Member of *World Journal of Clinical Cases*, Woon-Man Kung, MD, MSc, Assistant Professor, Surgeon, Department of Exercise and Health Promotion, College of Education, Chinese Culture University, Taipei 11114, Taiwan

AIMS AND SCOPE

The primary aim of *World Journal of Clinical Cases (WJCC, World J Clin Cases)* is to provide scholars and readers from various fields of clinical medicine with a platform to publish high-quality clinical research articles and communicate their research findings online.

WJCC mainly publishes articles reporting research results and findings obtained in the field of clinical medicine and covering a wide range of topics, including case control studies, retrospective cohort studies, retrospective studies, clinical trials studies, observational studies, prospective studies, randomized controlled trials, randomized clinical trials, systematic reviews, meta-analysis, and case reports.

INDEXING/ABSTRACTING

The *WJCC* is now indexed in PubMed, PubMed Central, Science Citation Index Expanded (also known as SciSearch®), and Journal Citation Reports/Science Edition. The 2019 Edition of Journal Citation Reports cites the 2018 impact factor for *WJCC* as 1.153 (5-year impact factor: N/A), ranking *WJCC* as 99 among 160 journals in Medicine, General and Internal (quartile in category Q3).

RESPONSIBLE EDITORS FOR THIS ISSUE

Responsible Electronic Editor: Ji-Hong Liu

Proofing Production Department Director: Xiang Li

NAME OF JOURNAL

World Journal of Clinical Cases

ISSN

ISSN 2307-8960 (online)

LAUNCH DATE

April 16, 2013

FREQUENCY

Semimonthly

EDITORS-IN-CHIEF

Dennis A Bloomfield, Bao-Gan Peng, Sandro Vento

EDITORIAL BOARD MEMBERS

<https://www.wjgnet.com/2307-8960/editorialboard.htm>

EDITORIAL OFFICE

Jin-Lei Wang, Director

PUBLICATION DATE

March 26, 2020

COPYRIGHT

© 2020 Baishideng Publishing Group Inc

INSTRUCTIONS TO AUTHORS

<https://www.wjgnet.com/bpg/gerinfo/204>

GUIDELINES FOR ETHICS DOCUMENTS

<https://www.wjgnet.com/bpg/GerInfo/287>

GUIDELINES FOR NON-NATIVE SPEAKERS OF ENGLISH

<https://www.wjgnet.com/bpg/gerinfo/240>

PUBLICATION MISCONDUCT

<https://www.wjgnet.com/bpg/gerinfo/208>

ARTICLE PROCESSING CHARGE

<https://www.wjgnet.com/bpg/gerinfo/242>

STEPS FOR SUBMITTING MANUSCRIPTS

<https://www.wjgnet.com/bpg/GerInfo/239>

ONLINE SUBMISSION

<https://www.f6publishing.com>

Metabolic and genetic assessments interpret unexplained aggressive pulmonary hypertension induced by methylmalonic acidemia: A case report

Hong-Yu Liao, Xiao-Qing Shi, Yi-Fei Li

ORCID number: Hong-Yu Liao (0000-0001-9673-4372); Xiao-Qing Shi (0000-0003-3024-2820); Yi-Fei Li (0000-0002-3096-4287).

Author contributions: Liao H and Shi X contributed equally to this work. Shi X and Li Y were the patient's physician. All the authors reviewed the literature and contributed to manuscript drafting; Shi X interpreted the metabolic screening and genetic sequence results. Li Y conceptualized and designed the study, coordinated and supervised data collection, and critically reviewed the manuscript for important intellectual content. Liao H, Shi X and Li Y were responsible for the revision of the manuscript for important intellectual content; all authors issued final approval for the version to be submitted.

Informed consent statement:

Informed written consents were obtained from the patients for publication of this report and any accompanying images.

Conflict-of-interest statement: The authors declare that they have no conflict of interest.

CARE Checklist (2016) statement:

The authors have read the CARE Checklist (2016), and the manuscript was prepared and revised according to the CARE Checklist (2016).

Open-Access: This article is an open-access article that was selected by an in-house editor and fully peer-reviewed by external

Hong-Yu Liao, Xiao-Qing Shi, Yi-Fei Li, Department of Pediatrics and Ministry of Education Key Laboratory of Women and Children's Diseases and Birth Defects, West China Second University Hospital, Sichuan University, Chengdu 610041, Sichuan Province, China

Corresponding author: Yi-Fei Li, MD, Associate Professor, Department of Pediatrics and Ministry of Education Key Laboratory of Women and Children's Diseases and Birth Defects, West China Second University Hospital, Sichuan University, No. 20, 3rd section, South Renmin Road, Chengdu 610041, Sichuan Province, China. liyfwcsh@scu.edu.cn

Abstract

BACKGROUND

Pulmonary hypertension (PH) causes significant morbidity and mortality in diverse childhood diseases. However, limited information has been reported to obtain a good understanding of pediatric PH. Gaps exist between genome sequencing and metabolic assessments and lead to misinterpretations of the complicated symptoms of PH. Here, we report a rare case of a patient who presented with severe PH as the first manifestation without significant cardiovascular malformation and was finally diagnosed with methylmalonic aciduria (MMA) after metabolic and genomic assessments.

CASE SUMMARY

An 11-year-old female presented with an aggressive reduction in activity capability and shortness of breath for only 4 mo and suffered from unexplained PH. A series of examinations was performed to evaluate any possible malformations or abnormalities of the cardiovascular system and lungs, but negative results were obtained. The blood tests were normal except for manifestations of microcytic anemia and elevated total homocysteine. Computed tomography and magnetic resonance imaging failed to identify any pulmonary diseases. Cardiac catheterization examination identified a small right coronary artery to pulmonary artery shunt and severe PH. During the follow-up, PH progressed rapidly. Then, genome sequencing and metabolic disorder screening were performed, which confirmed a diagnosis of MMA with MMACHC c.80A > G/c and 609G > A mutations. Vitamin B12, betaine and bosentan were then administered as the main treatments. During the 6-mo follow-up, the pulmonary artery pressure dropped to 45 mmHg, while the right ventricle structure recovered. The patient's heart function recovered to NYHA class II. Metabolic disorder analysis failed to identify significant abnormalities.

reviewers. It is distributed in accordance with the Creative Commons Attribution NonCommercial (CC BY-NC 4.0) license, which permits others to distribute, remix, adapt, build upon this work non-commercially, and license their derivative works on different terms, provided the original work is properly cited and the use is non-commercial. See: <http://creativecommons.org/licenses/by-nc/4.0/>

Manuscript source: Unsolicited manuscript

Received: November 14, 2019

Peer-review started: November 14, 2019

First decision: December 23, 2019

Revised: December 31, 2019

Accepted: January 19, 2020

Article in press: January 19, 2020

Published online: March 26, 2020

P-Reviewer: Cheng TH, Yamaguchi K

S-Editor: Dou Y

L-Editor: MedE-Ma JY

E-Editor: Zhang YL



CONCLUSION

As emerging types of metabolic dysfunction have been shown to present as the first manifestation of PH, and taking advantage of next generation sequencing technology, genome sequencing and metabolic disorder screening are recommended to have a more superior role when attempting to understand unclear or aggressive PH.

Key words: Pulmonary hypertension; Methylmalonic acidemia; Genomic sequence; Metabolic disorder; Case report

©The Author(s) 2020. Published by Baishideng Publishing Group Inc. All rights reserved.

Core tip: This report describes a case who suffered an aggressive pulmonary hypertension (PH) as her first onset manifestation. Following the routine diagnostic and therapeutic procedure, we failed to address any abnormalities which could explain the origins of PH. However, taking the advantage of metabolic screening and genome sequencing, we achieved the diagnosis of methylmalonic acidemia and revealed that the severe PH is secondary to methylmalonic acidemia, which was not mentioned among several guidelines of PH. Although metabolic and genome screenings have been recommended in guideline, this case brought our reconsideration to the timing for perform metabolic and genomic screenings. So that, we would like to mention that for some aggressive unexplained PH patients who meets the criteria, such screening procedure should be applied in an earlier stage to prevent putting the patients into irreversible conditions.

Citation: Liao HY, Shi XQ, Li YF. Metabolic and genetic assessments interpret unexplained aggressive pulmonary hypertension induced by methylmalonic acidemia: A case report. *World J Clin Cases* 2020; 8(6): 1137-1141

URL: <https://www.wjgnet.com/2307-8960/full/v8/i6/1137.htm>

DOI: <https://dx.doi.org/10.12998/wjcc.v8.i6.1137>

INTRODUCTION

Pulmonary hypertension (PH) is a progressive disease that causes significant morbidity and mortality in various childhood diseases^[1]. In childhood, abnormal heart structures, especially left-to-right shunt congenital heart diseases, are the main causes of PH^[2]. Despite the availability of new medications, the long-term outcomes are still poor^[3]. Recently, emerging studies have reported that genetic and metabolic assessments have been performed to demonstrate the molecular basis of unexplained PH. However, it is unknown which patients need to receive a genomic and metabolic assessment. Here, we report a rare case of severe PH as the first manifestation in a patient who underwent a delayed genomic and metabolic assessment to accurately understand the disorder. In addition, we reconsidered the criteria for unexplained PH that indicate the need for a combined genomic and metabolic assessments.

CASE PRESENTATION

Chief complaints

An 11-year-old girl complained of an aggressive reduction in activity capability and shortness of breath and presented to our cardiovascular department.

History of illness

The patient started to demonstrate a reduction in activity capability 4 mo ago and progressed with accelerated worsening of her condition within the most recent 1 mo, presenting severe shortness of breath. However, the patient denied any history of past illness.

Physical, laboratory and imaging examinations

An enhanced P2 sound and a systolic murmur between sternal ribs 2 and 3 were

observed. She suffered from NYHA class II heart function. Echocardiography revealed a large right ventricle and pulmonary artery trunk, with an estimated 60 mmHg pulmonary arterial pressure and normal left heart function. Computed tomography and magnetic resonance imaging scans excluded lung disease and cardiomyopathy, which could lead to PH. In addition, the results of the autoimmune antibody analysis were negative and excluded any connective tissue or rheumatological diseases.

Cardiac catheterization examination

The right ventricular catheter examination showed an elevated right ventricular pressure of 50/2 (23) mmHg, main pulmonary artery pressure of 57/21 (55) mmHg, left pulmonary artery pressure of 50/29 (36) mmHg and right pulmonary artery pressure of 60/31 (45) mmHg with a total pulmonary resistance of 8.72 woods, Qp 6.3 L/min. Therefore, the catheter evaluation failed to identify a clear cause.

Further diagnostic work-up

Because of the rapid progression of pulmonary artery pressure with microcytic anemia and elevated homocysteine, metabolic disorders were suspected. Therefore, metabolic screening and genome sequencing was performed for this patient. Metabolic screening showed an elevation of methylmalonic acid of 51.82 µg/L, and two mutations c.80A > G/c and 609G > A were recognized at the gene for methylmalonic aciduria and homocystinuria type C protein (*MMACHC*), and these mutations were reported to be associated with methylmalonic acidemia, cobalamin C type.

FINAL DIAGNOSIS

This patient was finally diagnosed with methylmalonic acidemia with aggressive PH as the first clinical manifestation.

TREATMENT AND FOLLOW-UP OUTCOME

As metabolic and genome screening need almost 1 mo to be completed, we provided bosentan (endothelin-1 inhibitor) to this patient and performed frequent follow-up assessments while waiting for results. However, after 1 mo, the patient presented with aggressive worsening of the clinical manifestations. Her heart function worsened to NYHA class IV. The laboratory test demonstrated microcytic anemia with increasing brain natriuretic peptide as high as 3939.23 pg/mL (nv < 100) and total homocysteine as high as 119.99 µmol/L (nv < 15). Echocardiography revealed that the pulmonary artery pressure was elevated to 70 mmHg, with a right ventricular Tei index of 0.8, and her pulmonary artery size increased to 30 mm. According to the screening results, a diagnosis of methylmalonic acid was reached. Vitamin B12 (1 mg/d) and betaine (200 mg/kg/day) were immediately administered as supplemental therapy with bosentan. After 6 mo of treatment with vitamin B12 and betaine, her pulmonary artery hypertension decreased to 45 mmHg, right ventricular Tei-index dropped to 0.29, and pulmonary artery size decreased to 25 mm, according to the latest echocardiography (Figure 1). Her heart function reversed to NYHA class II. The metabolic disorder analysis failed to identify abnormalities, and a methylmalonic acid level of 6.53 µg/L was observed.

DISCUSSION

Methylmalonic acidemia is an autosomal recessive metabolic disorder that disrupts normal amino acid metabolism. However, this kind of disease rarely demonstrates severe PH as the first clinical manifestation. Defective synthesis of the coenzymes adenosylcobalamin and methylcobalamin has been reported to be the main mediator of PH as a result of mitochondrial dysfunction^[4]. These disorders might lead to capillary thrombosis in the lung, which would induce PH. In addition, a series of genome sequencing studies that focused on methylmalonic acidemia confirmed that the cobalamin C type was the most common type that would cause aggressive PH^[5,6].

According to the European Society of Cardiology and American Heart Association guidelines for the diagnosis and treatment of pediatric PH^[1,7], metabolic disorders have been listed in the 5th division. However, both of the guidelines only report glycogen storage disease, Gaucher disease and thyroid disorders. Although

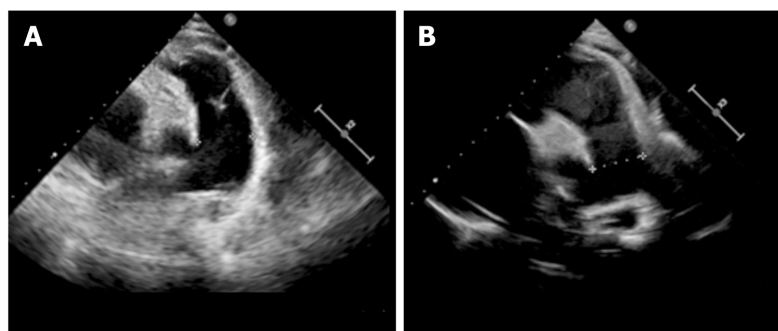


Figure 1 Echocardiography showed the changes in pulmonary artery diameter size before and after treatment. A: Before treatment, the size was 30 mm due to pulmonary hypertension; B: The size reduced to 25 with the decrease of pulmonary artery pressure.

methylmalonic acidemia was failed to be mentioned, several studies also reported limited cases of methylmalonic acidemia inducing PH, which was first described by Iodice *et al*^[8]. Beck *et al*^[9] reviewed a cohort of 36 methylmalonic acidemia patients with cobalamin C defects and found that 7 of them presented PH.

Electrocardiogram, X-ray, echocardiography, computed tomography, magnetic resonance imaging, pulmonary function test, and catheterization should always be performed as routinely recommended by guidelines. In this case, during the patient's first stay in the hospital, we followed the recommended process for obtaining PH diagnosis. However, we failed to confirm the diagnosis quickly, which aggravated the patient's condition. Then, during the second hospital stay, the combination of genome sequencing and metabolic disorder screening identified methylmalonic acidemia, cobalamin C type. After receiving targeted therapies, this patient's impaired pulmonary artery pressure and heart function were reversed.

CONCLUSION

In summary, as metabolic disorders have already been mentioned in the guidelines, emerging types of metabolic dysfunction have been proven to have a manifestation of PH. It is recommended that genome sequencing and metabolic disorder screening are initially performed to obtain a diagnosis for unexplained or aggressive PH. Based on the literature review and our experience, once the patients presented with the abovementioned symptoms, genome sequencing and metabolic disorder screening should be prioritized rather than performed last to explore possible reasons. We summarized the criteria that indicate a need for these tests, as follows: (1) Failed to detect a structural malformation of the cardiovascular and pulmonary system; (2) Negative results for autoimmune disease; and (3) Aggressive pulmonary artery pressure elevation for a limited time or very early-onset PH without other disorders affecting other systems.

REFERENCES

- 1 Abman SH, Hansmann G, Archer SL, Ivy DD, Adatia I, Chung WK, Hanna BD, Rosenzweig EB, Raj JU, Cornfield D, Stenmark KR, Steinhorn R, Thébaud B, Fineman JR, Kuehne T, Feinstein JA, Friedberg MK, Earing M, Barst RJ, Keller RL, Kinsella JP, Mullen M, Deterding R, Kulik T, Mallory G, Humpl T, Wessel DL; American Heart Association Council on Cardiopulmonary, Critical Care, Perioperative and Resuscitation; Council on Clinical Cardiology; Council on Cardiovascular Disease in the Young; Council on Cardiovascular Radiology and Intervention; Council on Cardiovascular Surgery and Anesthesia; and the American Thoracic Society. Pediatric Pulmonary Hypertension: Guidelines From the American Heart Association and American Thoracic Society. *Circulation* 2015; **132**: 2037-2099 [PMID: 26534956 DOI: 10.1161/CIR.0000000000000329]
- 2 Tonelli AR, Arelli V, Minai OA, Newman J, Bair N, Heresi GA, Dweik RA. Causes and circumstances of death in pulmonary arterial hypertension. *Am J Respir Crit Care Med* 2013; **188**: 365-369 [PMID: 23600433 DOI: 10.1164/rccm.201209-1640OC]
- 3 Barst RJ, McGoon MD, Elliott CG, Foreman AJ, Miller DP, Ivy DD. Survival in childhood pulmonary arterial hypertension: insights from the registry to evaluate early and long-term pulmonary arterial hypertension disease management. *Circulation* 2012; **125**: 113-122 [PMID: 22086881 DOI: 10.1161/CIRCULATIONAHA.111.026591]
- 4 Gündüz M, Ekici F, Özyayın E, Ceylaner S, Perez B. Reversible pulmonary arterial hypertension in cobalamin-dependent cobalamin C disease due to a novel mutation in the MMACHC gene. *Eur J Pediatr* 2014; **173**: 1707-1710 [PMID: 24853097 DOI: 10.1007/s00431-014-2330-6]

- 5 **De Simone L**, Capirchio L, Roperto RM, Romagnani P, Sacchini M, Donati MA, de Martino M. Favorable course of previously undiagnosed Methylmalonic Aciduria with Homocystinuria (cbLC type) presenting with pulmonary hypertension and aHUS in a young child: a case report. *Ital J Pediatr* 2018; **44**: 90 [PMID: [30103768](#) DOI: [10.1186/s13052-018-0530-9](#)]
- 6 **Kido J**, Mitsubuchi H, Sakanashi M, Matsubara J, Matsumoto S, Sakamoto R, Endo F, Nakamura K. Pulmonary artery hypertension in methylmalonic acidemia. *Hemodial Int* 2017; **21**: E25-E29 [PMID: [27804229](#) DOI: [10.1111/hdi.12506](#)]
- 7 **Galiè N**, Humbert M, Vachiery JL, Gibbs S, Lang I, Torbicki A, Simonneau G, Peacock A, Vonk Noordegraaf A, Beghetti M, Ghofrani A, Gomez Sanchez MA, Hansmann G, Klepetko W, Lancellotti P, Matucci M, McDonagh T, Pierard LA, Trindade PT, Zompatori M, Hoeper M. 2015 ESC/ERS Guidelines for the diagnosis and treatment of pulmonary hypertension: The Joint Task Force for the Diagnosis and Treatment of Pulmonary Hypertension of the European Society of Cardiology (ESC) and the European Respiratory Society (ERS): Endorsed by: Association for European Paediatric and Congenital Cardiology (AEPC), International Society for Heart and Lung Transplantation (ISHLT). *Eur Respir J* 2015; **46**: 903-975 [PMID: [26318161](#) DOI: [10.1183/13993003.01032-2015](#)]
- 8 **Iodice FG**, Di Chiara L, Boenzi S, Aiello C, Monti L, Cogo P, Dionisi-Vici C. Cobalamin C defect presenting with isolated pulmonary hypertension. *Pediatrics* 2013; **132**: e248-e251 [PMID: [23753090](#) DOI: [10.1542/peds.2012-1945](#)]
- 9 **Beck BB**, van Spronsen F, Diepstra A, Berger RM, Kömhoff M. Renal thrombotic microangiopathy in patients with cbLC defect: review of an under-recognized entity. *Pediatr Nephrol* 2017; **32**: 733-741 [PMID: [27289364](#) DOI: [10.1007/s00467-016-3399-0](#)]



Published By Baishideng Publishing Group Inc
7041 Koll Center Parkway, Suite 160, Pleasanton, CA 94566, USA
Telephone: +1-925-3991568
E-mail: bpgoffice@wjgnet.com
Help Desk: <https://www.f6publishing.com/helpdesk>
<https://www.wjgnet.com>

