

# World Journal of *Gastroenterology*

*World J Gastroenterol* 2020 February 21; 26(7): 696-776



**MINIREVIEWS**

- 696** Proteomic insights on the metabolism in inflammatory bowel disease  
*Pisani LF, Moriggi M, Gelfi C, Vecchi M, Pastorelli L*

**ORIGINAL ARTICLE****Basic Study**

- 706** Liver stiffness and perfusion changes for hepatic sinusoidal obstruction syndrome in rabbit model  
*Shin J, Yoon H, Cha YJ, Han K, Lee MJ, Kim MJ, Shin HJ*
- 717** Role of Tenascin-X in regulating TGF- $\beta$ /Smad signaling pathway in pathogenesis of slow transit constipation  
*Zhang YC, Chen BX, Xie XY, Zhou Y, Qian Q, Jiang CQ*

**Retrospective Cohort Study**

- 725** Pre-hepatectomy type IV collagen 7S predicts post-hepatectomy liver failure and recovery  
*Ishii M, Itano O, Shinoda M, Kitago M, Abe Y, Hibi T, Yagi H, Takeuchi A, Tsujikawa H, Abe T, Kitagawa Y*
- 740** Biliary spontaneous dislodgement spiral stent for patients who underwent mechanical lithotripsy  
*Ye LS, Yuan XL, Wu CC, Liu W, Du J, Yao MH, Tan QH, Hu B*

**Retrospective Study**

- 749** Modified Child-Pugh grade vs albumin-bilirubin grade for predicting prognosis of hepatocellular carcinoma patients after hepatectomy  
*Huang F, Gao J*

**Observational Study**

- 759** Benefits of implementing a rapid access clinic in a high-volume inflammatory bowel disease center: Access, resource utilization and outcomes  
*Nene S, Gonczi L, Kurti Z, Morin I, Chavez K, Verdon C, Reinglas J, Kohen R, Bessissow T, Afif W, Wild G, Seidman E, Bitton A, Lakatos PL*

**CASE REPORT**

- 770** Malignant glomus tumor of the intestinal ileum with multiorgan metastases: A case report and review of literature  
*Chen JH, Lin L, Liu KL, Su H, Wang LL, Ding PP, Zhou Q, Liu H, Wu J*

## Contents

*World Journal of Gastroenterology*

Volume 26 Number 7 February 21, 2020

### ABOUT COVER

Associate Editor of *World Journal of Gastroenterology*, Peter L Lakatos, DSc, FEBG, MD, PhD, Full Professor, Division of Gastroenterology, Montreal General Hospital C7-200, McGill University Health Center, Quebec H3G1A4, Canada

### AIMS AND SCOPE

The primary aim of *World Journal of Gastroenterology* (WJG, *World J Gastroenterol*) is to provide scholars and readers from various fields of gastroenterology and hepatology with a platform to publish high-quality basic and clinical research articles and communicate their research findings online.

WJG mainly publishes articles reporting research results and findings obtained in the field of gastroenterology and hepatology and covering a wide range of topics including gastroenterology, hepatology, gastrointestinal endoscopy, gastrointestinal surgery, gastrointestinal oncology, and pediatric gastroenterology.

### INDEXING/ABSTRACTING

The WJG is now indexed in Current Contents®/Clinical Medicine, Science Citation Index Expanded (also known as SciSearch®), Journal Citation Reports®, Index Medicus, MEDLINE, PubMed, PubMed Central, and Scopus. The 2019 edition of Journal Citation Report® cites the 2018 impact factor for WJG as 3.411 (5-year impact factor: 3.579), ranking WJG as 35<sup>th</sup> among 84 journals in gastroenterology and hepatology (quartile in category Q2). CiteScore (2018): 3.43.

### RESPONSIBLE EDITORS FOR THIS ISSUE

Responsible Electronic Editor: *Yu-Jie Ma*

Proofing Production Department Director: *Xiang Li*

#### NAME OF JOURNAL

*World Journal of Gastroenterology*

#### ISSN

ISSN 1007-9327 (print) ISSN 2219-2840 (online)

#### LAUNCH DATE

October 1, 1995

#### FREQUENCY

Weekly

#### EDITORS-IN-CHIEF

Subrata Ghosh, Andrzej S Tarnawski

#### EDITORIAL BOARD MEMBERS

<http://www.wjgnet.com/1007-9327/editorialboard.htm>

#### EDITORIAL OFFICE

Ze-Mao Gong, Director

#### PUBLICATION DATE

February 21, 2020

#### COPYRIGHT

© 2020 Baishideng Publishing Group Inc

#### INSTRUCTIONS TO AUTHORS

<https://www.wjgnet.com/bpg/gerinfo/204>

#### GUIDELINES FOR ETHICS DOCUMENTS

<https://www.wjgnet.com/bpg/GerInfo/287>

#### GUIDELINES FOR NON-NATIVE SPEAKERS OF ENGLISH

<https://www.wjgnet.com/bpg/gerinfo/240>

#### PUBLICATION MISCONDUCT

<https://www.wjgnet.com/bpg/gerinfo/208>

#### ARTICLE PROCESSING CHARGE

<https://www.wjgnet.com/bpg/gerinfo/242>

#### STEPS FOR SUBMITTING MANUSCRIPTS

<https://www.wjgnet.com/bpg/GerInfo/239>

#### ONLINE SUBMISSION

<https://www.f6publishing.com>

© 2020 Baishideng Publishing Group Inc. All rights reserved. 7041 Koll Center Parkway, Suite 160, Pleasanton, CA 94566, USA

E-mail: [bpgoffice@wjgnet.com](mailto:bpgoffice@wjgnet.com) <https://www.wjgnet.com>



## Retrospective Cohort Study

# Biliary spontaneous dislodgement spiral stent for patients who underwent mechanical lithotripsy

Lian-Song Ye, Xiang-Lei Yuan, Chun-Cheng Wu, Wei Liu, Jiang Du, Ming-Hong Yao, Qing-Hua Tan, Bing Hu

**ORCID number:** Lian-Song Ye (0000-0001-5542-2508); Xiang-Lei Yuan (0000-0003-2281-5094); Chun-Cheng Wu (0000-0002-8390-4202); Wei Liu (0000-0002-6904-9342); Jiang Du (0000-0002-6558-7047); Ming-Hong Yao (0000-0001-8151-6014); Qing-hua Tan (0000-0001-5032-9849); Bing Hu (0000-0002-9898-8656).

**Author contributions:** Ye LS, Yuan XL, Wu CC, Liu W, Du J, Yao MH, Tan QH, and Hu B conceived and designed; Ye LS, Yuan XL, Wu CC, Liu W, Du J, Yao MH, Tan QH, and Hu B analyzed and interpreted the data; Ye LS and Yuan XL drafted the article; Wu CC, Liu W, Du J, Yao MH, Tan QH, and Hu B critically revised the article; Ye LS, Yuan XL, Wu CC, Liu W, Du J, Yao MH, Tan QH and Hu B approved the article.

**Supported by** Sichuan Science and Technology Program, China, No. 2017SZ0009.

### Institutional review board

**statement:** The study protocol was reviewed and approved by the Biomedical Research Ethics Committee, West China Hospital, Sichuan University.

### Informed consent statement:

Informed consent was waived by the Ethics Committee.

**Conflict-of-interest statement:** All authors disclose no conflict of interest relevant to this study.

**Data sharing statement:** No additional unpublished data are available.

**Lian-Song Ye, Xiang-Lei Yuan, Chun-Cheng Wu, Wei Liu, Jiang Du, Qing-Hua Tan, Bing Hu,** Department of Gastroenterology, West China Hospital, Sichuan University, Chengdu 610041, Sichuan Province, China

**Ming-Hong Yao,** Department of Epidemiology and Health Statistics, West China School of Public Health, Sichuan University, Chengdu 610041, Sichuan Province, China

**Corresponding author:** Bing Hu, MD, Chief Doctor, Professor, Department of Gastroenterology, West China Hospital, Sichuan University, No. 37, Guo Xue Alley, Wu Hou District, Chengdu 610041, Sichuan Province, China. [hubingnj@163.com](mailto:hubingnj@163.com)

## Abstract

### BACKGROUND

The incidence of post-endoscopic retrograde cholangiopancreatography (ERCP) cholangitis (PEC) in patients who underwent mechanical lithotripsy (ML) for large stone removal is high (up to 13.3%). One of the main causes is remaining small fragments or sludge that can impair normal biliary drainage. Endoscopic placement of a nasobiliary tube or a conventional plastic biliary stent has been commonly used under such conditions, but the patient may suffer from significant discomfort after the placement of a nasobiliary tube, while additional endoscopy is required for stent removal. We developed a biliary spontaneous dislodgement spiral stent (BSDSS) to overcome those shortcomings.

### AIM

To evaluate the feasibility, safety, and effectiveness of inserting a BSDSS for patients who underwent ML for large stone removal.

### METHODS

We conducted a single-center, retrospective, cohort study at West China Hospital, Sichuan University. A total of 91 consecutive patients with large biliary stones ( $\geq 10$  mm) in the common bile duct who underwent ML between November 2017 and July 2018 were included. The 49 eligible patients were divided into the BSDSS group and the nasobiliary tube group. Technical success, post-ERCP adverse events (including PEC, post-ERCP pancreatitis, stone recurrence, BSDSS retention, self-extraction and dislocation of the nasobiliary tube), drainage time, and postoperative stay were measured and compared.

### RESULTS

Twenty-one patients in the BSDSS group and 28 patients in the nasobiliary tube group were included in the analyses. The baseline characteristics and clinical



**STROBE statement:** The authors have read the STORBE Statement-checklist of items, and the manuscript was prepared and revised according to the STORBE Statement-checklist of items.

**Open-Access:** This article is an open-access article that was selected by an in-house editor and fully peer-reviewed by external reviewers. It is distributed in accordance with the Creative Commons Attribution NonCommercial (CC BY-NC 4.0) license, which permits others to distribute, remix, adapt, build upon this work non-commercially, and license their derivative works on different terms, provided the original work is properly cited and the use is non-commercial. See: <http://creativecommons.org/licenses/by-nc/4.0/>

**Manuscript source:** Invited manuscript

**Received:** November 15, 2019

**Peer-review started:** November 15, 2019

**First decision:** December 4, 2019

**Revised:** December 5, 2019

**Accepted:** January 11, 2020

**Article in press:** January 11, 2020

**Published online:** February 21, 2020

**P-Reviewer:** Archibugi L, Langerth A

**S-Editor:** Wang LY

**L-Editor:** MedE- Ma JY

**E-Editor:** Zhang YL



information were similar in the two groups. Insertions of BSDSS and nasobiliary tube were technically successful in all 49 patients. There was no significant difference in the incidence of overall post-ERCP adverse events between the two groups (4.8% in the BSDSS group *vs* 17.9% in the nasobiliary tube group,  $P = 0.219$ ). The median duration of drainage time (3 d in the BSDSS group *vs* 4 d in the nasobiliary tube group) and length of postoperative stay (4 d in the BSDSS group *vs* 5 d in the nasobiliary tube group) also did not differ ( $P = 0.934$ , and  $P = 0.223$ , respectively).

## CONCLUSION

Endoscopic placement of a BSDSS appears to be feasible, safe and effective for patients who underwent ML for large stone removal.

**Key words:** Cholangitis; Choledocholithiasis; Drainage; Endoscopic nasobiliary drainage; Mechanical lithotripsy; Pancreatitis; Spiral; Stents

©The Author(s) 2020. Published by Baishideng Publishing Group Inc. All rights reserved.

**Core tip:** This retrospective cohort study describes the feasibility, safety, and effectiveness of inserting a biliary spontaneous dislodgement spiral stent (BSDSS) for patients who underwent mechanical lithotripsy for large stone removal. All BSDSSs were inserted successfully and evacuated spontaneously after a median duration of 3 d without additional injuries to the digestive tract. Comparable results of post-endoscopic retrograde cholangiopancreatography adverse events, drainage time, and length of postoperative stay were observed in the BSDSS group ( $n = 21$ ) and the nasobiliary tube group ( $n = 28$ ).

**Citation:** Ye LS, Yuan XL, Wu CC, Liu W, Du J, Yao MH, Tan QH, Hu B. Biliary spontaneous dislodgement spiral stent for patients who underwent mechanical lithotripsy. *World J Gastroenterol* 2020; 26(7): 740-748

**URL:** <https://www.wjgnet.com/1007-9327/full/v26/i7/740.htm>

**DOI:** <https://dx.doi.org/10.3748/wjg.v26.i7.740>

## INTRODUCTION

Endoscopic retrograde cholangiopancreatography (ERCP) is one of the main methods of removing biliary stones in the common bile duct (CBD)<sup>[1-3]</sup>. Endoscopic sphincterotomy (EST) and endoscopic papillary balloon dilation (EPBD) are the most commonly used modalities for stone removal<sup>[1-3]</sup>, but mechanical lithotripsy (ML) may also be required to remove large biliary stones. ML is the simplest method to fragment large CBD stones, but it carries the risk of remaining debris (including small fragments and sludge), even in patients with successful stone removal according to the judgment of the operating endoscopists. In general, placement of a nasobiliary tube or a conventional plastic biliary stent<sup>[4]</sup> can be performed in this setting, but the applications of both devices have obvious shortcomings. Patients with nasobiliary tubes may suffer from significant discomfort due to the transnasal placement<sup>[5,6]</sup>, which could lead to self-extraction and dislocation of the tube; additionally, bile loss caused by external drainage can lead to electrolyte imbalance<sup>[5,6]</sup>, which is especially risky for patients with arrhythmia. Patients with conventional plastic biliary stents have to undergo another endoscopy for stent removal<sup>[6]</sup>, which incurs additional medical costs. We developed a biliary spontaneous dislodgement spiral stent (BSDSS) to overcome the above shortcomings of nasobiliary tubes and conventional biliary stents<sup>[7,8]</sup>. This retrospective cohort study assessed the feasibility, safety, and effectiveness of the placement of a BSDSS for patients who underwent ML for large stone ( $\geq 10$  mm) removal by comparing the clinical outcomes of BSDSS patients with those of nasobiliary tube patients.

## MATERIALS AND METHODS

### Study design

This single-center, retrospective cohort study was conducted at West China Hospital, Sichuan University, a tertiary hospital. The study protocol was approved by the Biomedical Research Ethics Committee, West China Hospital, Sichuan University.

### Design of the BSDSS

The BSDSS used in this study is made of soft and pliable thermoplastic polyurethane, which is different from the commonly used plastic biliary stent (polytetrafluoroethylene). The main difference in shape between the BSDSS and the conventional plastic biliary stent is the duodenal end (Figure 1). The BSDSS has more than one spiral, whereas the conventional has no or only one spiral (straight type and pigtail type, respectively). There are several side holes in the spirals of the BSDSS, and the diameter of the spirals is 12 mm. Another difference lies in the shape of the flanges in the bile duct end. Unlike the long flanges in the conventional stents, the BSDSSs have two short, thin flanges. The outer diameter of the BSDSS is 7 Fr, and its length is 7 cm.

### Patients

Consecutive patients with large biliary stones ( $\geq 10$  mm) who underwent ML for stone removal between November 2017 and July 2018 were retrospectively collected from our prospectively collected database and the hospital medical records. The exclusion criteria were as follows: (1) Patients with altered anatomy; (2) Patients with percutaneous transhepatic cholangial drainage; (3) Patients with biliary stricture; (4) Patients with intrahepatic stones; and (5) Patients with incomplete stone removal (including failed ML and intolerance to repeated stone extraction).

### ERCP procedures

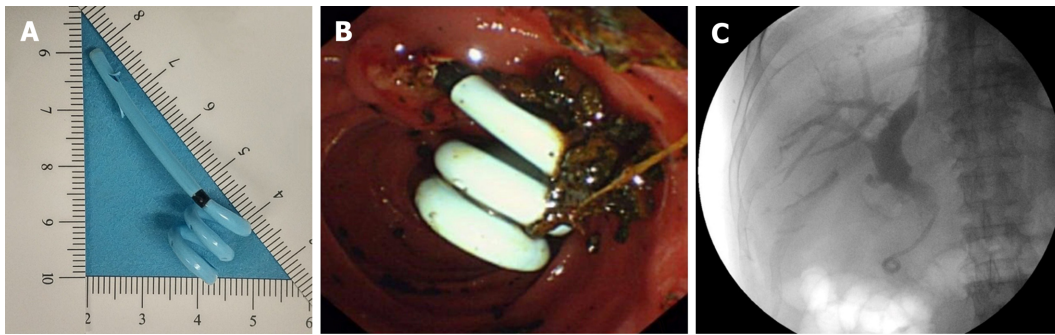All ERCP procedures were performed by an experienced endoscopist who underwent > 300 ERCP procedures per year. Patients were administered diazepam, pethidine, and anisodamine for conscious sedation, pain control, and bowel relaxation. ERCP was performed in the prone position using a standard duodenoscope (TJF-260V; Olympus, Tokyo, Japan). After selective cannulation of the CBD, a minimum of 25% omipaque was injected to confirm the number and size of CBD stones. According to the endoscopist's judgment, limited EST (3-5 mm), with or without small EPBD (8-10 mm), was performed to facilitate stone removal, followed by the application of ML. A trapezoid RX wire-guided retrieval basket (Boston Scientific Corporation; Marlborough, MA, USA) was used to fragment the stone, and then a grasping basket (FG-22Q-1; Olympus, Tokyo, Japan) was applied to extract fragments repeatedly.

For patients with nasobiliary tubes, a nasobiliary tube (7 Fr; Micro-Tech (Nanjing) Co., Ltd, Nanjing, China) was inserted into the intrahepatic duct using routine instruments and methods<sup>[5]</sup>. For patients with BSDSSs, a BSDSS [7 Fr  $\times$  7 cm; Micro-Tech (Nanjing) Co., Ltd, Nanjing, China] was advanced into the CBD using a guide wire (Jagwire™; Boston Scientific, Natick, MA, USA) aided by a plastic stent introduction device. The BSDSS was then released under fluoroscopic guidance, leaving the duodenal end with spirals outside the duodenal papilla. The BSDSS location was adjusted by the stent introduction device or endoscopic forceps according to the reference mark. Drainage of bile, small fragments or sludge, were confirmed before withdrawal of the duodenoscope.

### Post-ERCP management

After the procedure, the patients fasted for at least 24 h. Blood tests, including complete blood counts, liver function tests, and pancreatic enzymes, were performed 6-48 h after the procedure. Computed tomography (CT) or magnetic resonance cholangiopancreatography (MRCP) was performed when needed. Daily abdominal radiography was scheduled to determine the BSDSS location until the BSDSS was noted when the patient had a bowel movement. Postoperative cholangiography (for patients with nasobiliary tube and without self-extraction or dislocation of nasobiliary tube) or abdominal ultrasound (for patient with BSDSS, and for patients with nasobiliary tube but with self-extraction or dislocation of nasobiliary tube) was performed to detect residual debris, and additional ERCP was performed when needed. Cholecystectomy was recommended for patients with cystic stones.

Patients were followed *via* clinical visits every 3-6 mo, during which clinical symptoms and laboratory tests including liver function tests were recorded; abdominal ultrasound, CT, or MRCP were performed to identify CBD stone recurrence. Follow-up for each patient was discontinued till CBD stone recurrence or October 2019.



**Figure 1** Biliary spontaneous dislodgement spiral stent and its clinical application in a patient who underwent mechanical lithotripsy for large stone removal. A: the 7-cm × 7-Fr biliary spontaneous dislodgement spiral stent with 12-mm spirals; B and C: the endoscopic and fluoroscopic view of the biliary spontaneous dislodgement spiral stent, respectively, after insertion into the common bile duct.

### Outcome measurements

We evaluated the technical success, post-ERCP adverse events, drainage time, and postoperative stay.

Technical success was defined as the successful insertion of the BSDSS or nasobiliary tube into the bile duct in an appropriate position based on endoscopic and fluoroscopic confirmation.

Post-ERCP adverse events mainly included post-ERCP cholangitis (PEC), post-ERCP pancreatitis (PEP) and CBD stone recurrence. Other events relevant to the BSDSS (BSDSS retention and BSDSS-related injuries to the digestive tract) or nasobiliary tube (self-extraction and dislocation of the nasobiliary tube) were also recorded. PEC was defined as a fever ( $> 38^{\circ}\text{C}$ ), leukocytosis, and evidence of cholestasis<sup>[9]</sup>. PEP was defined as persistent pain associated with a serum amylase (or serum lipase) level  $\geq 3$  times the normal upper limit.<sup>[9]</sup> As a recent study<sup>[10]</sup> revealed that the revised Atlanta criteria<sup>[11]</sup> better reflect the severity of PEP than a previous consensus by Cotton *et al*<sup>[12]</sup>, the revised Atlanta classification was used as a grading standard in this study. CBD stone recurrence was defined as the observation of CBD stones six months or more after ERCP<sup>[13]</sup>.

Because BSDSS dislodgement cannot be precisely detected, the duration from BSDSS placement to evacuation (*i.e.*, evacuation time) was measured as the drainage time for the BSDSS. For patients with nasobiliary tubes, the drainage time was defined as the duration from tube placement to tube extraction.

Postoperative stay was defined as the duration from the ERCP procedure to discharge. For patients who underwent additional ERCP to remove residual debris during the same hospitalization, the postoperative stay was calculated from the initial ERCP to discharge.

### Statistical analysis

SPSS 25.0 was used for statistical analysis. Numerical variables are expressed as the means (standard deviations) or medians (interquartile ranges, IQRs) according to their distribution and were compared using Student's *t* test or Mann-Whitney *U*-test, accordingly. Categorical variables are expressed as the numbers or proportions and were compared using  $\chi^2$  tests or Fisher's exact tests as appropriate. *P* values  $< 0.05$  were considered significant.

## RESULTS

From November 2017 to July 2018, a total of 91 patients with large biliary stones ( $\geq 10$  mm) underwent ML for stone removal (Figure 2), and 49 patients met the criteria for inclusion in this study. Among these 49 patients, 21 underwent endoscopic placement of a BSDSS, while the other 28 patients underwent endoscopic placement of a nasobiliary tube. The baseline characteristics and clinical information in each group were similar (Table 1).

The clinical outcomes in the two groups are shown in Table 2. Insertion of the BSDSS or nasobiliary tube was technically successful with a single attempt in all 49 patients. There was no need to use forceps to adjust the location of the BSDSS. There was no PEC in the two groups, but mild PEP was noted in one patient in the BSDSS group (4.8%, 1/21) and one in the nasobiliary tube group (3.6%, 1/28); which was controlled in both patients with conservative treatment. During a median follow-up of

**Table 1** Baseline characteristics and clinical information of the biliary spontaneous dislodgement spiral stent and nasobiliary groups, *n* (%)

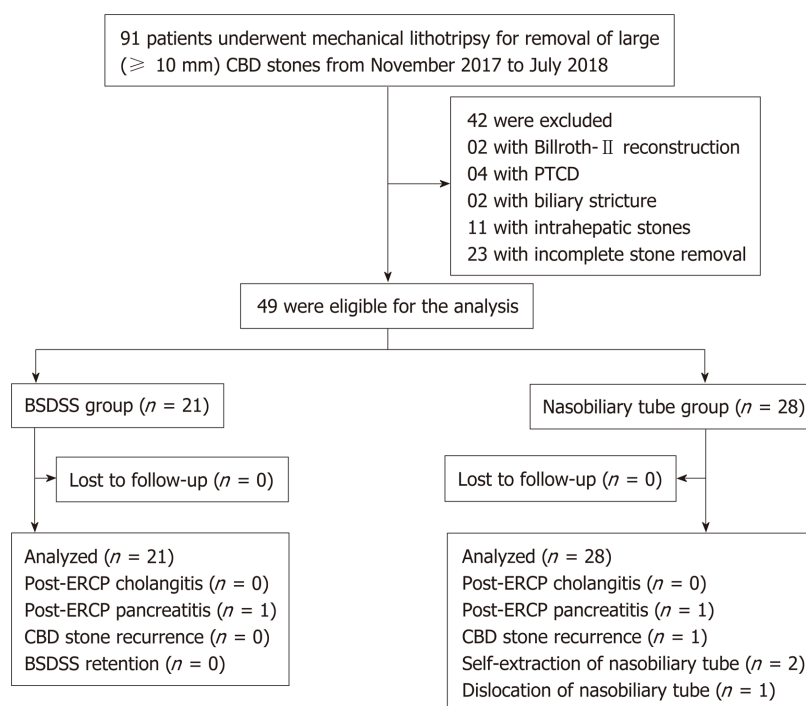
	BSDSS group ( <i>n</i> = 21)	Nasobiliary tube group ( <i>n</i> = 28)	<i>P</i> value
Age, mean ± SD, yr	64 ± 16	67 ± 19	0.572 <sup>5</sup>
Sex, male/female	11/10	13/15	0.680 <sup>6</sup>
Diagnosis			0.951 <sup>7</sup>
Biliary colic	6 (28.6)	10 (35.7)	
Obstructive jaundice	7 (33.3)	8 (28.6)	
Acute cholangitis <sup>1</sup>	6 (28.6)	7 (25.0)	
Acute pancreatitis <sup>1</sup>	2 (9.5)	3 (10.7)	
Comorbidity <sup>2</sup>	10 (47.6)	18 (64.3)	0.243 <sup>6</sup>
Gallbladder status			0.410 <sup>7</sup>
Post cholecystectomy	12 (57.1)	13 (46.4)	
Cholecystectomy after ERCP	2 (9.5)	1 (3.6)	
Gallbladder stones <i>in situ</i>	5 (23.8)	6 (21.4)	
No gallbladder stones	2 (9.5)	8 (28.6)	
Previous EST	2 (9.5)	6 (21.4)	0.438 <sup>7</sup>
Periampullary diverticulum	11 (52.4)	12 (42.9)	0.509 <sup>6</sup>
Maximum CBD diameter, median (IQR), mm	13 (12-16)	15 (13-15)	0.214 <sup>8</sup>
Maximum stone diameter, median (IQR), mm	13 (11-16)	12 (12-15)	0.581 <sup>8</sup>
Minimum stone diameter, median (IQR), mm	10 (9-12)	12 (10-12)	0.761 <sup>8</sup>
Stones number, < 3/≥ 3	14/7	25/3	0.076 <sup>6</sup>
ERCP modalities for stone removal			0.595 <sup>7</sup>
ML <sup>3</sup>	1 (4.8)	4 (14.3)	
EST + ML	3 (14.3)	6 (21.4)	
EPBD + ML <sup>3</sup>	1 (4.8)	2 (7.1)	
EST + EPBD + ML	16 (76.2)	16 (57.1)	
Residual debris <sup>4</sup>	1 (4.8)	5 (17.9)	0.219 <sup>7</sup>

<sup>1</sup>Endoscopic retrograde cholangiopancreatography was performed when acute cholangitis and acute pancreatitis were controlled;<sup>2</sup>Hypertension, coronary artery disease, diabetes mellitus, chronic obstructive pulmonary disease, liver cirrhosis, neoplastic diseases in other systems;<sup>3</sup>These patients underwent endoscopic sphincterotomy for stone removal previously;<sup>4</sup>Residual debris was detected by abdominal ultrasound in the only one patient in the biliary spontaneous dislodgement spiral stent group; Residual debris was detected by postoperative cholangiography in four patients in the nasobiliary tube group, while the remaining one patient was confirmed by abdominal ultrasound owing to dislocation of the nasobiliary tube. All these 6 patients underwent additional endoscopic retrograde cholangiopancreatography for debris removal;<sup>5</sup>Student's *t* test;<sup>6</sup> $\chi^2$  test;<sup>7</sup>Fisher exact test;<sup>8</sup>Mann-Whitney *U*-test. BSDSS: Biliary spontaneous dislodgement spiral stent; ERCP: Endoscopic retrograde cholangiopancreatography; CBD: Common bile duct; IQR: Interquartile range; EST: Endoscopic sphincterotomy; ML: Mechanical lithotripsy; EPBD: Endoscopic papillary balloon dilation.

18 mo (IQR, 15-21; range, 13-23), CBD stone recurrence was detected in one patient in the nasobiliary tube group (3.6%, 1/28), and additional ERCP was performed to remove the recurrent stone. In addition, all BSDSSs were dislodged and evacuated spontaneously after a median duration of 3 d (IQR, 3-5; range, 2-8), without additional injuries to the digestive tract; most patients (76.2%, 16/21) noticed the dislodged BSDSS when they had a bowel movement. Two patients in the nasobiliary tube (7.1%, 2/28) extracted the tube by themselves on postoperative day 1, due to intolerance of the transnasal placement of the tube; dislocation of the nasobiliary tube was also noted in 1 patient in the nasobiliary tube group (3.6%, 1/28). There were no significant differences in the incidence of overall post-ERCP adverse events (4.8% in the BSDSS group *vs* 17.9% in the nasobiliary tube group, *P* = 0.219).

The median drainage time in the BSDSS group was 3 d and that in the nasobiliary tube group was 4 d, without a significant difference between the groups (*P* = 0.934). The median length of postoperative stay was also similar in the two groups (4 d in the BSDSS group *vs* 5 d in the nasobiliary tube group, *P* = 0.223).





**Figure 2 Study flowchart of patient selection.** CBD: Common bile duct; PTC: Percutaneous transhepatic cholangial drainage; BSDSS: Biliary spontaneous dislodgement spiral stent; ERCP: Endoscopic retrograde cholangiopancreatography.

## DISCUSSION

This retrospective cohort study was conducted to evaluate the feasibility of the placement of a BSDSS for patients who underwent ML for large stone ( $\geq 10$  mm) removal. All inserted BSDSSs were dislodged and evacuated spontaneously without additional injuries to the digestive tract, and the incidence of post-ERCP adverse events in the BSDSS group was low and comparable with that in the nasobiliary tube group. Although the duration from BSDSS placement to evacuation was uncontrollable, similar results in terms of the drainage time and postoperative stay were noted in the two groups. Our findings show the feasibility, safety, and effectiveness of BSDSS for patients who underwent ML for large stone removal.

Apart from EST and EPBD, ML is helpful for removing large stones due to its ability to fragment stones, but the rate of PEC after ML can be high (13.3%, 6/45)<sup>[4]</sup>. Residual small fragments or sludge, as well as injuries to the biliary tract and papillary edema caused by repeated manipulations, may be potential causes. The use of a nasobiliary tube in patients who underwent ML ensures the direct evaluation of the drainage characteristics and facilitates postoperative cholangiography to detect residual debris. However, external drainage from the nasobiliary tube could cause significant discomfort due to the transnasal placement and bile loss. Discomfort in the nostril and throat may lead to self-extraction and dislocation of the nasobiliary tube<sup>[14]</sup>, which was noted in 3 patients with nasobiliary tubes in this study (10.7%, 3/28). Tube kinking, compression ulcers, and aspiration pneumonia can also occur<sup>[5,6,15]</sup>. Although external drainage-induced electrolyte imbalance, such as hypokalemia, is uncommon during short-term biliary drainage (0% in this study), it is risky for patients with arrhythmia once developed. In addition, abdominal ultrasound can be applied to detect residual debris as a substitute for postoperative cholangiography. As shown in Table 1, residual debris was detected by abdominal ultrasound in one patient in the BSDSS group and one patient in the nasobiliary tube group who underwent additional ERCP for debris removal. Given the above, the application of a BSDSS avoids the nasobiliary tube-related medical risks and improves the quality of life of patients.

Compared with conventional plastic biliary stents, the main strength of the BSDSS is its ability to dislodge and evacuate spontaneously after a short period of internal biliary drainage, which was noted in all patients in this study (100%, 21/21). We postulate that the BSDSS is dislodged after papillary edema abates, with the help of bowel movements and/or the passage of high-fiber chyme. In contrast, only 5%-10%

**Table 2** Clinical outcomes of the biliary spontaneous dislodgement spiral stent and nasobiliary tube groups, *n* (%)

	BSDSS group ( <i>n</i> = 21)	Nasobiliary tube group ( <i>n</i> = 28)	<i>P</i> value
Technical success	21 (100)	28 (100)	-
Overall post-ERCP adverse events	1 (4.8)	5 (17.9)	0.219 <sup>4</sup>
Cholangitis	0 (0)	0 (0)	-
Pancreatitis <sup>1</sup>	1 (4.8)	1 (3.6)	1.000 <sup>4</sup>
CBD stone recurrence	0 (0)	1 (3.6)	1.000 <sup>4</sup>
Other events <sup>2</sup>	0 (0)	3 (10.7)	0.250 <sup>4</sup>
Follow-up duration, median (IQR), mo	19 (17-22)	18 (15-21)	0.365 <sup>5</sup>
Drainage time <sup>3</sup> , median (IQR), d	3 (3-5)	4 (2-5)	0.934 <sup>5</sup>
Postoperative stay, median (IQR), d	4 (3-6)	5 (3-7)	0.223 <sup>5</sup>

<sup>1</sup>Pancreatitis was graded as mild in both groups;

<sup>2</sup>There was no biliary spontaneous dislodgement spiral stent (BSDSS) retention in the BSDSS group, while self-extraction (*n* = 2) and dislocation (*n* = 1) of the nasobiliary tube was noted in three patients in the nasobiliary tube group;

<sup>3</sup>Drainage time was defined as the duration from insertion to evacuation in the BSDSS group and the duration from insertion to extraction in the nasobiliary tube group;

<sup>4</sup>Fisher exact test;

<sup>5</sup>Mann-Whitney *U*-test. BSDSS: Biliary spontaneous dislodgement spiral stent; ERCP: Endoscopic retrograde cholangiopancreatography; CBD: Common bile duct; IQR: Interquartile range.

of conventional plastic biliary stents can migrate distally<sup>[16]</sup>; thus, additional endoscopy is frequently required for stent removal. In addition, the BSDSS is soft and has several spirals on the duodenal side, which makes it less likely to lead to stent-related bowel perforation or fistula that have been reported previously in patients with conventional plastic biliary stents<sup>[17-21]</sup>.

The main disadvantage of BSDSS is the lack of control over the timing of dislodgement and evacuation. The length of EST, as well as the size of EPBD, may seriously affect BSDSS dislodgement. For patients who underwent complete EST (and/or large EPBD), the BSDSS may be dislodged within a couple of hours because of the large opening of the papilla; thus, the application of a BSDSS in these patients seems unadvisable. However, as reported by previous studies<sup>[22-24]</sup>, complete EST and large EPBD (12-20 mm) have been regarded to be associated with a higher rate of late adverse events; thus, our routines of performing limited (3-5 mm) EST, small (8-10 mm) EPBD and ML for large stone removal seem reasonable. In addition, we used daily radiography to identify the BSDSS location in this study, but BSDSS dislodgement still could not be detected accurately, and there may be a significant difference in the duration from BSDSS dislodgment to evacuation among patients. Because all BSDSSs were evacuated spontaneously after a median duration of 3 d (IQR, 3-5), daily radiography may not be necessary due to increased radiation exposure. We suggest that single radiography on postoperative day 5 may be preferable for patients with BSDSS if they ignore the evacuated BSDSS when they have a bowel movement. Further methods may be proposed for determining the real-time positioning of BSDSS and to clarify the real drainage time with the BSDSS.

The biodegradable stent reported by Anderloni *et al*<sup>[25]</sup> ensures different degradation times for distinct clinical demands using various polymeric mixtures, making it a promising stent for patients who underwent ML; however, the use of such biodegradable stents should be approached cautiously because partially degraded stents may impair normal drainage and affect the findings of follow-up abdominal imaging.

The present study had several limitations. First, it was a single-center, retrospective study with a small sample size, but consecutive patients who underwent ML for large stone removal were included, which helps reduce the selection bias. Prospective, multicenter, and large-scale studies are needed to further evaluate the role of BSDSSs in such patients. Second, a comparison with the conventional plastic biliary stent was absent. This is mainly due to the rare use of conventional plastic stents in patients who underwent successful stone extraction after ML in our endoscopy center; these patients routinely received nasobiliary tube before the introduction of BSDSS. Third, there was no comparative group without drainage, and thus, the necessity of placing a BSDSS needs to be further investigated. Although the three patients with tube self-extraction or dislocation in the nasobiliary tube group did not develop PEC, considering the reported high incidence of PEC in patients who underwent ML for stone removal (13.3%, 6/45)<sup>[4]</sup>, a comparative study regarding the placement of BSDSS *vs* no BSDSS should be carefully conducted.

In conclusion, endoscopic placement of a BSDSS in patients who underwent ML for large stone removal appears to be feasible, safe and effective.

## ARTICLE HIGHLIGHTS

### Research background

The incidence of post-endoscopic retrograde cholangiopancreatography (ERCP) cholangitis (PEC) in patients who underwent mechanical lithotripsy (ML) for large stone removal is high (up to 13.3%). One of the main causes is remaining small fragments or sludge that can impair normal biliary drainage. Endoscopic placement of a nasobiliary tube or a conventional plastic biliary stent was commonly used under such conditions, but the patient may suffer from significant discomfort after the placement of a nasobiliary tube, while additional endoscopy is required for stent removal.

### Research motivation

We developed a biliary spontaneous dislodgement spiral stent (BSDSS) to overcome nasobiliary tube-related and conventional plastic biliary stent-related shortcomings. The duodenal end of the BSDSS is with several spirals, and its bile duct end has two short and thin flanges. We postulate that the BSDSS is dislodged after papillary edema abates, with the help of bowel movements and/or the passage of high-fiber chyme.

### Research objectives

In this retrospective cohort study, we evaluated the feasibility, safety, and effectiveness of inserting a BSDSS for patients who underwent ML for large stone removal by comparing the clinical outcomes of BSDSS patients with those of nasobiliary tube patients.

### Research methods

From November 2017 to July 2018, a total of 91 consecutive patients underwent ML for large ( $\geq 10$  mm) stone removal. Of these, 49 patients were eligible for this study, and they were divided into the BSDSS group and the nasobiliary tube group. Technical success, post-ERCP adverse events (including PEC, post-ERCP pancreatitis, stone recurrence, BSDSS retention, self-extraction and dislocation of the nasobiliary tube), drainage time, and postoperative stay were measured and compared.

### Research results

Twenty-one patients in the BSDSS group and 28 patients in the nasobiliary tube group were included in the analyses. The baseline characteristics and clinical information were similar in the two groups. Insertions of BSDSS and nasobiliary tube were technically successful in all 49 patients. There was no significant difference in the incidence of overall post-ERCP adverse events between the two groups (4.8% in the BSDSS group *vs* 17.9% in the nasobiliary tube group,  $P = 0.219$ ), as well as the median duration of drainage time (3 d in the BSDSS group *vs* 4 d in the nasobiliary tube group,  $P = 0.934$ ) and the median length of postoperative stay (4 d in the BSDSS group *vs* 5 d in the nasobiliary tube group,  $P = 0.223$ ).

### Research conclusions

Endoscopic placement of a BSDSS appears to be feasible, safe and effective for patients who underwent ML for large stone removal.

### Research perspectives

Multi-center studies with a large sample size are warranted to further confirm the safety and effectiveness of BSDSS. Comparative study regarding the placement of BSDSS *vs* no BSDSS is expected to clarify the necessity of routine application of BSDSS in patients who undergo ML for large stone removal.

## REFERENCES

- 1 Williams E, Beckingham I, El Sayed G, Gurusamy K, Sturgess R, Webster G, Young T. Updated guideline on the management of common bile duct stones (CBDS). *Gut* 2017; **66**: 765-782 [PMID: 28122906 DOI: 10.1136/gutjnl-2016-312317]
- 2 Manes G, Paspatis G, Aabakken L, Anderloni A, Arvanitakis M, Ah-Soune P, Barthet M, Domagk D, Dumonceau JM, Gigot JF, Hritz I, Karamanolis G, Laghi A, Mariani A, Paraskeva K, Pohl J, Ponchon T, Swahn F, Ter Steege RWF, Tringali A, Vezakis A, Williams EJ, van Hooft JE. Endoscopic management of common bile duct stones: European Society of Gastrointestinal Endoscopy (ESGE) guideline. *Endoscopy* 2019; **51**: 472-491 [PMID: 30943551 DOI: 10.1055/a-0862-0346]
- 3 ASGE Standards of Practice Committee; Buxbaum JL, Abbas Fehmi SM, Sultan S, Fishman DS, Qumseya BJ, Cortessis VK, Schilperoort H, Kysh L, Matsuoka L, Yachimski P, Agrawal D, Gurudu SR, Jamil LH, Jue TL, Khashab MA, Law JK, Lee JK, Naveed M, Sawhney MS, Thosani N, Yang J, Wani SB. ASGE guideline on the role of endoscopy in the evaluation and management of choledocholithiasis. *Gastrointest Endosc* 2019; **89**: 1075-1105.e15 [PMID: 30979521 DOI: 10.1016/j.gie.2018.10.001]
- 4 Stefanidis G, Viazis N, Pleskow D, Manolakopoulos S, Theocharis L, Christodoulou C, Kotsikoros N, Giannousis J, Sgouros S, Rodias M, Katsikani A, Chuttani R. Large balloon dilation *vs*. mechanical lithotripsy for the management of large bile duct stones: a prospective randomized study. *Am J*

- Gastroenterol* 2011; **106**: 278-285 [PMID: [21045816](#) DOI: [10.1038/ajg.2010.421](#)]
- 5 **Tsuyuguchi T**, Takada T, Kawarada Y, Nimura Y, Wada K, Nagino M, Mayumi T, Yoshida M, Miura F, Tanaka A, Yamashita Y, Hirota M, Hirata K, Yasuda H, Kimura Y, Strasberg S, Pitt H, Büchler MW, Neuhaus H, Belghiti J, de Santibanes E, Fan ST, Liao KH, Sachakul V. Techniques of biliary drainage for acute cholangitis: Tokyo Guidelines. *J Hepatobiliary Pancreat Surg* 2007; **14**: 35-45 [PMID: [17252295](#) DOI: [10.1007/s00534-006-1154-9](#)]
- 6 **Lee JK**, Lee SH, Kang BK, Kim JH, Koh MS, Yang CH, Lee JH. Is it necessary to insert a nasobiliary drainage tube routinely after endoscopic clearance of the common bile duct in patients with choledocholithiasis-induced cholangitis? A prospective, randomized trial. *Gastrointest Endosc* 2010; **71**: 105-110 [PMID: [19913785](#) DOI: [10.1016/j.gie.2009.08.009](#)]
- 7 **Ye L**, Hu B. Sa1366 Endoscopic Placement of A Plastic Spiral Stent for Short-Term Biliary Drainage in Patients with Cholelithiasis. *Gastrointest Endosc* 2018; **87**: Ab232-Ab232 [DOI: [10.1016/j.gie.2018.04.1516](#)]
- 8 **Ye L**, Yuan X, Zeng X, Guo L, Yang W, Hu B. 1114 Placement of a Biliary Spontaneous Dislodgement Spiral Stent for Short-Term Biliary Drainage after Endoscopic Clearance of Common Bile Duct Stones: A Prospective Pilot Study. *Gastrointest Endosc* 2019; **89**: AB137-AB138 [DOI: [10.1016/j.gie.2019.04.183](#)]
- 9 **Cotton PB**, Eisen GM, Aabakken L, Baron TH, Hutter MM, Jacobson BC, Mergener K, Nemcek A, Petersen BT, Petrini JL, Pike IM, Rabeneck L, Romagnuolo J, Vargo JJ. A lexicon for endoscopic adverse events: report of an ASGE workshop. *Gastrointest Endosc* 2010; **71**: 446-454 [PMID: [20189503](#) DOI: [10.1016/j.gie.2009.10.027](#)]
- 10 **Smeets X**, Bouhouch N, Buxbaum J, Zhang H, Cho J, Verdonk RC, Römkens T, Venneman NG, Kats I, Vrolijk JM, Hemmink G, Otten A, Tan A, Elmunzer BJ, Cotton PB, Drenth J, van Geenen E. The revised Atlanta criteria more accurately reflect severity of post-ERCP pancreatitis compared to the consensus criteria. *United European Gastroenterol J* 2019; **7**: 557-564 [PMID: [31065373](#) DOI: [10.1177/2050640619834839](#)]
- 11 **Banks PA**, Bollen TL, Dervenis C, Gooszen HG, Johnson CD, Sarr MG, Tsiotos GG, Vege SS; Acute Pancreatitis Classification Working Group. Classification of acute pancreatitis--2012: revision of the Atlanta classification and definitions by international consensus. *Gut* 2013; **62**: 102-111 [PMID: [23100216](#) DOI: [10.1136/gutjnl-2012-302779](#)]
- 12 **Cotton PB**, Lehman G, Vennes J, Geenen JE, Russell RC, Meyers WC, Liguory C, Nickl N. Endoscopic sphincterotomy complications and their management: an attempt at consensus. *Gastrointest Endosc* 1991; **37**: 383-393 [PMID: [2070995](#) DOI: [10.1016/S0016-5107\(91\)70740-2](#)]
- 13 **Keizman D**, Ish-Shalom M, Konikoff FM. The clinical significance of bile duct sludge: is it different from bile duct stones? *Surg Endosc* 2007; **21**: 769-773 [PMID: [17342562](#) DOI: [10.1007/s00464-006-9153-0](#)]
- 14 **Xu XD**, Dai JJ, Qian JQ, Wang WJ. Prevention of pancreatitis after papillary balloon dilatation by nasobiliary drainage: a randomized controlled trial. *Dig Dis Sci* 2015; **60**: 1087-1091 [PMID: [25322952](#) DOI: [10.1007/s10620-014-3400-3](#)]
- 15 **Isayama H**, Nakai Y, Tsujino T, Kawabe T, Omata M. Which types of drainage tube should we select for endoscopic biliary drainage? Current status. *Dig Endosc* 2006; **18**: S110-S111 [DOI: [10.1111/j.1443-1661.2006.00646.x](#)]
- 16 **ASGE Technology Assessment Committee**; Pfau PR, Pleskow DK, Banerjee S, Barth BA, Bhat YM, Desilets DJ, Gottlieb KT, Maple JT, Siddiqui UD, Tokar JL, Wang A, Song LM, Rodríguez SA. Pancreatic and biliary stents. *Gastrointest Endosc* 2013; **77**: 319-327 [PMID: [23410693](#) DOI: [10.1016/j.gie.2012.09.026](#)]
- 17 **Malhotra NR**, Esparza Monzavi CA, Trepanier JS, Nordenstam J, Abern MR. Biliary Stent Migration: A Rare Cause of a Bladder Stone. *Urology* 2017; **104**: e1-e2 [PMID: [28322898](#) DOI: [10.1016/j.urology.2017.03.007](#)]
- 18 **Kusters PJ**, Keulen ET, Peters FP. Duodenal perforation following bile duct endoprosthesis placement. *Endoscopy* 2014; **46** Suppl 1 UCTN: E646-E647 [PMID: [25526406](#) DOI: [10.1055/s-0034-1390849](#)]
- 19 **Alcaide N**, Lorenzo-Pelayo S, Herranz-Bachiller MT, de la Serna-Higuera C, Barrio J, Perez-Miranda M. Sigmoid perforation caused by a migrated biliary stent and closed with clips. *Endoscopy* 2012; **44** Suppl 2 UCTN: E274 [PMID: [22814918](#) DOI: [10.1055/s-0032-1309719](#)]
- 20 **Wilhelm A**, Langer C, Zoeller G, Nustede R, Becker H. Complex colovesicular fistula: A severe complication caused by biliary stent migration. *Gastrointest Endosc* 2003; **57**: 124-126 [PMID: [12518151](#) DOI: [10.1067/mge.2003.71](#)]
- 21 **Storkson RH**, Edwin B, Reiertsen O, Faerden AE, Sortland O, Rosseland AR. Gut perforation caused by biliary endoprosthesis. *Endoscopy* 2000; **32**: 87-89 [PMID: [10691280](#) DOI: [10.1055/s-2000-87](#)]
- 22 **Yasuda I**, Tomita E, Enya M, Kato T, Moriwaki H. Can endoscopic papillary balloon dilation really preserve sphincter of Oddi function? *Gut* 2001; **49**: 686 [PMID: [11600473](#) DOI: [10.1136/gut.49.5.686](#)]
- 23 **Yasuda I**, Fujita N, Maguchi H, Hasebe O, Igarashi Y, Murakami A, Mukai H, Fujii T, Yamao K, Maeshiro K, Tada T, Tsujino T, Komatsu Y. Long-term outcomes after endoscopic sphincterotomy versus endoscopic papillary balloon dilation for bile duct stones. *Gastrointest Endosc* 2010; **72**: 1185-1191 [PMID: [20869711](#) DOI: [10.1016/j.gie.2010.07.006](#)]
- 24 **Hakuta R**, Kawahata S, Kogure H, Nakai Y, Saito K, Saito T, Hamada T, Takahara N, Uchino R, Mizuno S, Tsujino T, Tada M, Sakamoto N, Isayama H, Koike K. Endoscopic papillary large balloon dilation and endoscopic papillary balloon dilation both without sphincterotomy for removal of large bile duct stones: A propensity-matched analysis. *Dig Endosc* 2019; **31**: 59-68 [PMID: [29943385](#) DOI: [10.1111/den.13220](#)]
- 25 **Anderloni AA**, Fugazza A, luca m, Maselli R, Ormando VM, D'Amico F, Carrara S, Mangiavillano B, Omodei PD, Preatoni P, Lamonaca L, Cappello A, Pellegatta G, Repici A. 1111 Feasibility of New Biliary and Pancreatic Biodegradable Stent Placement: Interim Analysis of an Ongoing Single-Center, Prospective, Pilot Study. *Gastrointest Endosc* 2019; **89**: Ab136-Ab136 [DOI: [10.1016/j.gie.2019.04.180](#)]





Published By Baishideng Publishing Group Inc  
7041 Koll Center Parkway, Suite 160, Pleasanton, CA 94566, USA  
Telephone: +1-925-3991568  
E-mail: [bpgoffice@wjgnet.com](mailto:bpgoffice@wjgnet.com)  
Help Desk: <http://www.f6publishing.com/helpdesk>  
<http://www.wjgnet.com>

