

World Journal of *Clinical Cases*

World J Clin Cases 2020 March 26; 8(6): 1002-1187



**REVIEW**

- 1002** Gut microbiota and nutrient interactions with skin in psoriasis: A comprehensive review of animal and human studies
Damiani G, Bragazzi NL, McCormick TS, Pigatto PDM, Leone S, Pacifico A, Todorovic D, Di Franco S, Alfieri A, Fiore M
- 1013** Microbiota-gut-brain axis and its affect inflammatory bowel disease: Pathophysiological concepts and insights for clinicians
Sinagra E, Utzeri E, Morreale GC, Fabbri C, Pace F, Anderloni A

MINIREVIEWS

- 1026** Distal esophageal spasm: Update on diagnosis and management in the era of high-resolution manometry
Gorti H, Samo S, Shahnava N, Qayed E

ORIGINAL ARTICLE**Retrospective Study**

- 1033** Clinical course of percutaneous cholecystostomies: A cross-sectional study
Er S, Berkem H, Özden S, Birben B, Çetinkaya E, Tez M, Yüksel BC
- 1042** Clinical characteristics and 28-d outcomes of bacterial infections in patients with hepatitis B virus-related acute-on-chronic liver failure
Li C, Su HB, Liu XY, Hu JH
- 1056** Application of hybrid operating rooms for treating spinal dural arteriovenous fistula
Zhang N, Xin WQ
- 1065** Ruxolitinib add-on in corticosteroid-refractory graft-*vs*-host disease after allogeneic stem cell transplantation: Results from a retrospective study on 38 Chinese patients
Dang SH, Liu Q, Xie R, Shen N, Zhou S, Shi W, Liu W, Zou P, You Y, Zhong ZD

META-ANALYSIS

- 1074** Laparoscopic surgery for early gallbladder carcinoma: A systematic review and meta-analysis
Feng X, Cao JS, Chen MY, Zhang B, Juengpanich S, Hu JH, Topatana W, Li SJ, Shen JL, Xiao GY, Cai XJ, Yu H
- 1087** Long-term clinical performance of flapless implant surgery compared to the conventional approach with flap elevation: A systematic review and meta-analysis
Cai H, Liang X, Sun DY, Chen JY

CASE REPORT

- 1104** Diagnosis and management of glandular papilloma of lung: A case report
Wu CW, Chen A, Huang TW
- 1108** Abnormal serum carbohydrate antigen 19-9 levels in a patient with splenic retiform haemangioendothelioma concomitant with hepatic amyloidosis: A case report
Sun KD, Zhang YJ, Zhu LP, Yang B, Wang SY, Yu ZH, Zhang HC, Chen X
- 1116** Hepatoid carcinoma of the pancreas: A case report and review of the literature
Zeng SX, Tan SW, Fong CJTH, Liang Q, Zhao BL, Liu K, Guo JX, Tao J
- 1129** Successful treatment of systemic sclerosis complicated by ventricular tachycardia with a cardiac resynchronization therapy-defibrillator: A case report
Chen YY, Yan H, Zhu JH
- 1137** Metabolic and genetic assessments interpret unexplained aggressive pulmonary hypertension induced by methylmalonic acidemia: A case report
Liao HY, Shi XQ, Li YF
- 1142** Hyoid-complex elevation and stimulation technique restores swallowing function in patients with lateral medullary syndrome: Two case reports
Jiang YE, Lyu QQ, Lin F, You XT, Jiang ZL
- 1150** Microscopic removal of type III dens invaginatus and preparation of apical barrier with mineral trioxide aggregate in a maxillary lateral incisor: A case report and review of literature
Liu J, Zhang YR, Zhang FY, Zhang GD, Xu H
- 1158** Cerebral venous sinus thrombosis following transsphenoidal surgery for craniopharyngioma: A case report
Chang T, Yang YL, Gao L, Li LH
- 1164** Hepatoid adenocarcinoma of the stomach: Thirteen case reports and review of literature
Zhang ZR, Wu J, Li HW, Wang T
- 1172** Growth hormone therapy for children with KBG syndrome: A case report and review of literature
Ge XY, Ge L, Hu WW, Li XL, Hu YY
- 1180** Laparoscopic repair of complete intrathoracic stomach with iron deficiency anemia: A case report
Yasheng D, Wulamu W, Li YL, Tuhongjiang A, Abudureyimu K

ABOUT COVER

Editorial Board Member of *World Journal of Clinical Cases*, Woon-Man Kung, MD, MSc, Assistant Professor, Surgeon, Department of Exercise and Health Promotion, College of Education, Chinese Culture University, Taipei 11114, Taiwan

AIMS AND SCOPE

The primary aim of *World Journal of Clinical Cases* (WJCC, *World J Clin Cases*) is to provide scholars and readers from various fields of clinical medicine with a platform to publish high-quality clinical research articles and communicate their research findings online.

WJCC mainly publishes articles reporting research results and findings obtained in the field of clinical medicine and covering a wide range of topics, including case control studies, retrospective cohort studies, retrospective studies, clinical trials studies, observational studies, prospective studies, randomized controlled trials, randomized clinical trials, systematic reviews, meta-analysis, and case reports.

INDEXING/ABSTRACTING

The WJCC is now indexed in PubMed, PubMed Central, Science Citation Index Expanded (also known as SciSearch®), and Journal Citation Reports/Science Edition. The 2019 Edition of Journal Citation Reports cites the 2018 impact factor for WJCC as 1.153 (5-year impact factor: N/A), ranking WJCC as 99 among 160 journals in Medicine, General and Internal (quartile in category Q3).

RESPONSIBLE EDITORS FOR THIS ISSUE

Responsible Electronic Editor: Ji-Hong Liu

Proofing Production Department Director: Xiang Li

NAME OF JOURNAL

World Journal of Clinical Cases

ISSN

ISSN 2307-8960 (online)

LAUNCH DATE

April 16, 2013

FREQUENCY

Semimonthly

EDITORS-IN-CHIEF

Dennis A Bloomfield, Bao-Gan Peng, Sandro Vento

EDITORIAL BOARD MEMBERS

<https://www.wjgnet.com/2307-8960/editorialboard.htm>

EDITORIAL OFFICE

Jin-Lei Wang, Director

PUBLICATION DATE

March 26, 2020

COPYRIGHT

© 2020 Baishideng Publishing Group Inc

INSTRUCTIONS TO AUTHORS

<https://www.wjgnet.com/bpg/gerinfo/204>

GUIDELINES FOR ETHICS DOCUMENTS

<https://www.wjgnet.com/bpg/GerInfo/287>

GUIDELINES FOR NON-NATIVE SPEAKERS OF ENGLISH

<https://www.wjgnet.com/bpg/gerinfo/240>

PUBLICATION MISCONDUCT

<https://www.wjgnet.com/bpg/gerinfo/208>

ARTICLE PROCESSING CHARGE

<https://www.wjgnet.com/bpg/gerinfo/242>

STEPS FOR SUBMITTING MANUSCRIPTS

<https://www.wjgnet.com/bpg/GerInfo/239>

ONLINE SUBMISSION

<https://www.f6publishing.com>

Microscopic removal of type III dens invaginatus and preparation of apical barrier with mineral trioxide aggregate in a maxillary lateral incisor: A case report and review of literature

Jie Liu, Yue-Rong Zhang, Fu-Yu Zhang, Guang-Dong Zhang, Hai Xu

ORCID number: Jie Liu (0000-0003-1950-5239); Yue-Rong Zhang (0000-0001-6481-8643); Fu-Yu Zhang (0000-0002-1864-6809); Guang-Dong Zhang (0000-0002-3482-4724); Hai Xu (0000-0003-4483-3891).

Author contributions: Xu H designed the treatment plan and treated the patient; Liu J, Zhang YR, Zhang FY, and Zhang GD reviewed the literature and drafted the manuscript.

Supported by the Priority Academic Program Development of Jiangsu Higher Education Institutions, No. PAPD2018-87.

Informed consent statement: Informed written consent was obtained from the patient for publication of this report and any accompanying images.

Conflict-of-interest statement: The author denies any conflict of interest related to this article.

CARE Checklist (2016) statement: The authors have read the CARE Checklist (2016), and the manuscript was prepared and revised according to the CARE Checklist (2016).

Open-Access: This article is an open-access article that was selected by an in-house editor and fully peer-reviewed by external reviewers. It is distributed in accordance with the Creative Commons Attribution NonCommercial (CC BY-NC 4.0) license, which permits others to

Jie Liu, Yue-Rong Zhang, Fu-Yu Zhang, Guang-Dong Zhang, Department of General Dentistry, Affiliated Hospital of Stomatology, Nanjing Medical University, Nanjing 210029, Jiangsu Province, China

Jie Liu, Yue-Rong Zhang, Fu-Yu Zhang, Guang-Dong Zhang, Hai Xu, Jiangsu Key Laboratory of Oral Diseases, Nanjing Medical University, Nanjing 210029, Jiangsu Province, China

Hai Xu, Department of Conservative Dentistry and Endodontics, Affiliated Hospital of Stomatology, Nanjing Medical University, Nanjing 210029, Jiangsu Province, China

Corresponding author: Hai Xu, PhD, Associate Chief Physician, Department of Conservative Dentistry and Endodontics, Affiliated Hospital of Stomatology, Nanjing Medical University, Han-Zhong Road 136th, Nanjing 210029, Jiangsu Province, China. xh1982@njmu.edu.cn

Abstract

BACKGROUND

Invaginated teeth pose greater challenges in clinical management because of their complex configuration. With advancements in equipment and materials, such as the dental operation microscope, cone-beam computed tomography and mineral trioxide aggregate, the preservation rate of type III dens invaginatus could be greatly increased.

CASE SUMMARY

This case report presented a 31-year-old woman with complaints of spontaneous swelling and pain in the right maxillary lateral tooth. With the aid of cone-beam computed tomography, type III dens invaginatus with apical periodontitis was diagnosed and confirmed. Three-visit endodontic treatment was performed. In the first visit, the invagination was carefully removed under the dental operation microscope, and chemomechanical preparation was done. In the second visit, mineral trioxide aggregate apical barrier surgery was performed in this tooth. In the third visit, the canal was finally obturated with thermoplastic gutta-percha to recover the crown morphology. A 26-mo follow-up revealed a satisfied outcome both in the radiographic and oral examinations.

CONCLUSION

In this case, removal of the entire abnormal structure provided great convenience for the follow-up treatment. When confronted with the same clinical case in the future, we can take a similar approach to address it.

distribute, remix, adapt, build upon this work non-commercially, and license their derivative works on different terms, provided the original work is properly cited and the use is non-commercial. See: <http://creativecommons.org/licenses/by-nc/4.0/>

Manuscript source: Unsolicited manuscript

Received: November 26, 2019

Peer-review started: November 26, 2019

First decision: January 19, 2020

Revised: February 1, 2020

Accepted: February 28, 2020

Article in press: February 28, 2020

Published online: March 26, 2020

P-Reviewer: Dereci O, Muhvić-Urek M

S-Editor: Dou Y

L-Editor: Filipodia

E-Editor: Zhang YL



Key words: Type III dens invaginatus; Mineral trioxide aggregate; Apical barrier; Cone-beam computed tomography; Dental operation microscope; Case report

©The Author(s) 2020. Published by Baishideng Publishing Group Inc. All rights reserved.

Core tip: Type III dens invaginatus poses great challenges when conducting clinical operations. This article reported an upper right lateral incisor with type III dens invaginatus using the method that removed the invagination under the dental operation microscope, and then mineral trioxide aggregate apical barrier was made for the convenience of next treatment. The 26-mo follow-up revealed a satisfactory therapeutic effect.

Citation: Liu J, Zhang YR, Zhang FY, Zhang GD, Xu H. Microscopic removal of type III dens invaginatus and preparation of apical barrier with mineral trioxide aggregate in a maxillary lateral incisor: A case report and review of literature. *World J Clin Cases* 2020; 8(6): 1150-1157

URL: <https://www.wjgnet.com/2307-8960/full/v8/i6/1150.htm>

DOI: <https://dx.doi.org/10.12998/wjcc.v8.i6.1150>

INTRODUCTION

Dens invaginatus (DI) is a developmental variation resulting from an infolding of the outer enamel surface of a tooth into the interior^[1]. It is caused by deepening or invagination of the enamel organ into the dental papilla before biological mineralization takes place^[2]. After the tooth erupts, a cystic deep cavity can appear on the tooth surface. It usually occurs in maxillary lateral incisors and occasionally in maxillary central incisors or canines^[1,3]. According to the depth of the invagination and anatomic variation, it can be divided into the deformed lingual sulcus, deformed root sulcus, malformed lingual tip, and dens in dente. Dens in dente is rare but the most severe condition in clinical practice^[1]. The classification advised by Oehlers is the most commonly used, which classifies DI into three types on the basis of penetration depth and communication with periapical tissue^[4]. Type I: Invagination confined inside the crown and not extending beyond the cemento-enamel junction. Type II: Invagination extending beyond the cemento-enamel junction but does not reach periapical tissue and remains as a blind sac. It may or may not communicate with the pulp. Type III: Invagination penetrates through the entire root, perforating the apical area and having a second foramen in the apical or periodontal area; there is no immediate connection with the pulp. A study on the proportion of various Oehlers types found that type I accounted for 81.25%, type II accounted for 6.25% and type III accounted for 12.5%^[5]. This article reports and discusses a case of non-surgical treatment of a maxillary lateral incisor diagnosed as type III DI with apical periodontitis. Treatment was performed with the guidance of cone-beam computed tomography (CBCT) imaging by removing the invagination with ultrasonic equipment and preparing an apical barrier with mineral trioxide aggregate (MTA) under a dental operation microscope (DOM).

CASE PRESENTATION

Chief complaint

A 31-year-old woman presented to the Department of Conservative Dentistry and Endodontics with complaints of spontaneous swelling and pain in an upper right anterior tooth for several days.

History of present illness

The patient felt spontaneous swelling and pain in an upper right anterior tooth for several days. The tooth was insensitive to cold and heat, but the patient felt uncomfortable when chewing. The tooth and its periodontal tissue had swollen before.

History of past illness

The patient recalled that the tooth had swelled before, and it was relieved after oral anti-inflammatory drugs.

Physical examination upon admission

Intra-oral examination disclosed the upper right lateral incisor with unusual morphological features, in which a deep sulcus of the palatal aspect was presented (Figure 1A). The crown also had a little change in color when compared to the adjacent tooth (Figure 1B). The tooth did not respond to thermal and cold tests, but it was sensitive to percussion. There was a swelling in the apical mucosa area, and no obvious fluctuation was detected. The electric pulp vitality test indicated pulp necrosis.

Imaging examinations

A preoperative radiographic examination (Figure 1C) showed the presence of dens invagination in the upper right lateral incisor and a large periapical radiolucency appearing around the apex. Because there was an aberrant anatomic structure and a periapical radiolucency of the tooth, a CBCT scan was taken as a complementary examination (Figure 2). The CBCT showed that the distal, mesial and palatal portions of the upper-middle section of the invagination was connected to the external teeth, and the lower section was separated from the external teeth.

FINAL DIAGNOSIS

Based on the subjective, objective and radiographic finding, a diagnosis of DI with apical periodontitis was made in the right maxillary lateral incisor.

TREATMENT

The proposed treatment protocol was as follows: The first protocol was extracting the tooth and planting; the second protocol was doing apical surgery after inflammatory control; and the third protocol was trying to remove the invaginated tooth and making an apical barrier under the DOM and deciding whether to perform apical surgery, depending on the apical healing situation.

After consideration of the advantages, disadvantages, prognosis, and cost of every treatment protocol, the patient chose the third protocol, which tried to remove the invaginated tooth and prepare an MTA apical barrier under the DOM. The difficulty of the operation was evaluated preoperatively and the possibility of extracting the invagination was assessed by CBCT images. The informed consent of treatment was provided for the patient.

At the first appointment, local anesthesia consisting of articaine with 1:100000 epinephrine was administered, and access to the cavity was gained under rubber dam isolation. Using the DOM (OPMI PROergo, Carl Zeiss Meditec AG, Jena, Germany), the root canal of the invagination was visualized, just as shown by CBCT, and the labial side was separated from the external tooth. The abnormally invaginated tissue was carefully removed from the root trunk using ET20 and ET40 ultrasonic tips until completely separated (Figure 3A) and removed by medical forceps (Figure 3B). Afterwards, an intraoperative film was taken to confirm that the invagination had been completely removed (Figure 3C and 3D). Then, an ultrasonic tip was used to activate the canal soaked with sodium hypochlorite (Figure 3E). After drying with a sterile absorbent paper point, the canal was filled with calcium hydroxide paste and sealed temporarily. The patient was given a prescription for anti-inflammatory drugs with instructions to take for pain only if needed and to inform the doctor immediately if there was any discomfort. The patient was scheduled for MTA apical barrier surgery 1 wk later.

At the second appointment, the pain of the upper right lateral tooth had been significantly relieved. The examination found that the tooth was not sensitive to percussion, and no tenderness but slight bulging was present in the labial apical mucosa. Under rubber dam isolation, the calcium hydroxide in the root canal was removed by ultrasound. Then, 1% sodium hypochlorite was flushed into the canal and activated with ultrasonic tips, saline was used in the final irrigation (Figure 3F), and the canal was dried with absorbent paper points (Figure 3G). The working length was determined by an electronic apex locator and confirmed radiographically (Figure 3H). An apical barrier of 4 mm in thickness was created with MTA (Figure 3I and 3J), where a wet cotton pellet was placed above. Then the tooth was sealed with Ceivitron (GC Corporation, Tokyo, Japan).

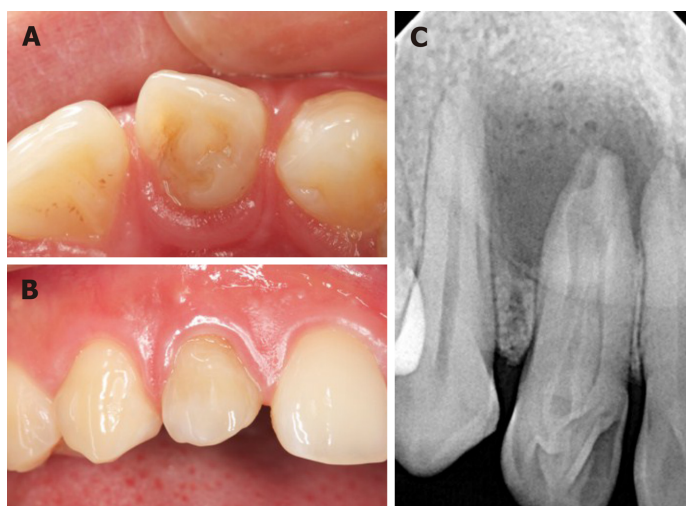


Figure 1 The intraoral examination before treatment. A: The lingual view: the tooth has unusual morphologic features; B: The labial view: the upper right lateral tooth is slightly discolored; C: A preoperative radiograph of the tooth showed a type III dens invaginatus and an associated large apical radiolucency.

At the third appointment, which was set for 1 wk after the second appointment, the patient felt better. There was no obvious discomfort in the upper right lateral tooth, and the apical bulging in the labial mucosa was reduced. Rubber dam isolation was carried out to remove the temporary materials and cotton pellet of the root canal. Under the DOM, the barrier was probed firmly with a DG-16 probe (Hu-Friedy, Chicago, IL, United States) to confirm that the MTA was completely coagulated. The remaining space was then obturated with thermoplastic gutta-percha (SybronEndo, Orange, CA, United States) and AH-Plus (Dentsply Sirona, York, PA, United States) sealer, using a vertical condensation technique (Figure 3K). Thereafter, the access cavity was sealed with composite resin (ESPE Z350; 3M Science, Maplewood, MN, United States) (Figure 3L).

OUTCOME AND FOLLOW-UP

At the 9-, 15- and 26-mo follow-up appointments, the tooth remained asymptomatic. Chewing function could be exercised normally. However, the color of the crown did not significantly change until 26 mo (Figure 4A-C). There was no tenderness or obvious bulging in the labial apical mucosa. Radiographic examination at 9-, 15- and 26-mo postoperatively (Figure 4D-F) showed ongoing periapical repair, in which the apical radiolucency had been reduced and the bone trabecular structure was visible.

DISCUSSION

Dens in dente is the most serious type of dens invagination^[1]. It has been reported that the incidence of DI ranges from 0.04% to 10%, with the maxillary lateral incisors most susceptible to involvement^[6-8]. Depending on the severity of the infection and the complexity of its anatomy, several treatment methods for the invagination have been described. They included filling treatment, endodontic treatment^[9], apical surgery^[10,11], intentional reimplantation^[12], and finally extraction. A case of invagination removal had also been reported in other literature^[13].

In this case, after careful preoperative CBCT analysis, it was decided to use the method of removing the invagination and preparing the MTA apical barrier under a DOM to preserve the tooth. According to American Association of Endodontists commendations, CBCT should be considered the preferred treatment of teeth with the potential of suspected complex canal morphology or dental anomalies^[14]. As a non-invasive diagnostic tool, CBCT has the advantages of increased accuracy and higher resolution. Moreover, CBCT offers significant scan-time reduction, radiation dose reduction, and reduced cost for the patient^[15-17]. Compared with traditional 2-dimensional radiographs, CBCT produces undistorted three-dimensional information, which clearly displays images of the facial skeleton and the teeth and their surrounding tissues^[18]. The induction and widespread adoption of the DOM is the

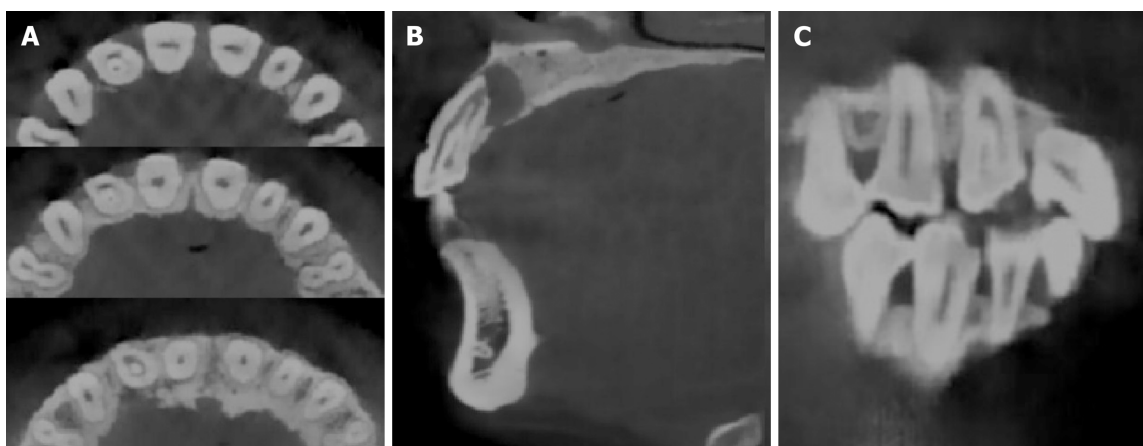


Figure 2 Cone-beam computed tomography images of dens invaginatus. A: The axial image; B: The sagittal image; C: The coronal sections image. A type III dens invaginatus tooth with apical periodontitis based on Oehlers classification can easily be seen in the images.

most revolutionary in non-surgical and surgical endodontic treatment, which offers various high- and low-power magnifications. DOM offers homogeneous illumination without shadows and a 3-dimensional view, which combine to make the examination site clearer^[19,20].

Despite the help of CBCT and the DOM, there were still some challenges in this case. One of the difficulties was how to successfully remove the invagination and reduce the damage to the main root canal wall. We were inspired by orthognathic surgery to place the ultrasound tip in the root canal of the invaginated tooth. It was expected that the force of ultrasonic vibration would be conducted to the joint between the invagination and external tooth so that the invagination could be removed. Finally, the invagination was taken out in two steps, which basically conformed to the preoperative plan.

Another difficulty was the preparation of the MTA apical barrier. The tooth was characterized by absorption of the apex and destruction of the apical foramen. An apical barrier is used in teeth with necrotic pulps, open apices, periapical radiolucencies and root resorption^[21]. Materials including collagen, calcium-enriched mixture cement, Biodentine and Portland cement have been reportedly used to make apical barriers^[21]. However, several studies with varying follow-up periods revealed that MTA as an apical barrier has a high success rate in teeth with necrotic pulps, open apices, and apical lesions^[22-26]. MTA is characterized by hard tissue conductivity^[27] and biocompatibility^[28] and has been recognized as a bioactive material. The main components of MTA are tricalcium silicate, tricalcium aluminate, calcium silicate, and tetracalcium aluminoferrite^[29]. MTA is a type of hydraulic cement. Its powder contains small hydrophilic particles, which can interact with the natural fluids present in tissues^[30]. The MTA barrier also has the advantages of reducing clinical time cost and early safe tooth restoration^[21]. In this case, we chose MTA as the apical barrier material. The pulsatile exudation of the apex could be seen under the DOM, which made placement of the MTA apical barrier difficult. During the apical barrier operation, the exudation liquid was aspirated with a syringe while filling the MTA. Finally, the material was compacted by ultrasonic vibration to improve the sealing performance. At the same time, the depth of the thermoplastic gutta-percha was controlled at the level of the alveolar ridge, to leave enough depth and space for the resin to make up for the loss of dentin. Therefore, the resistance of the tooth could be improved. The follow-up examinations demonstrated that the treatment of the invagination was successful because radiographs showed that the apical radiolucency had been reduced and the bone trabecular structure was visible.

CONCLUSION

The article reported a type III DI treated by removing the invagination combined with an MTA apical barrier. A follow-up of 26 mo revealed satisfactory healing of the soft tissue and bone of the periapical lesion, but the long-term efficacy still should be observed.

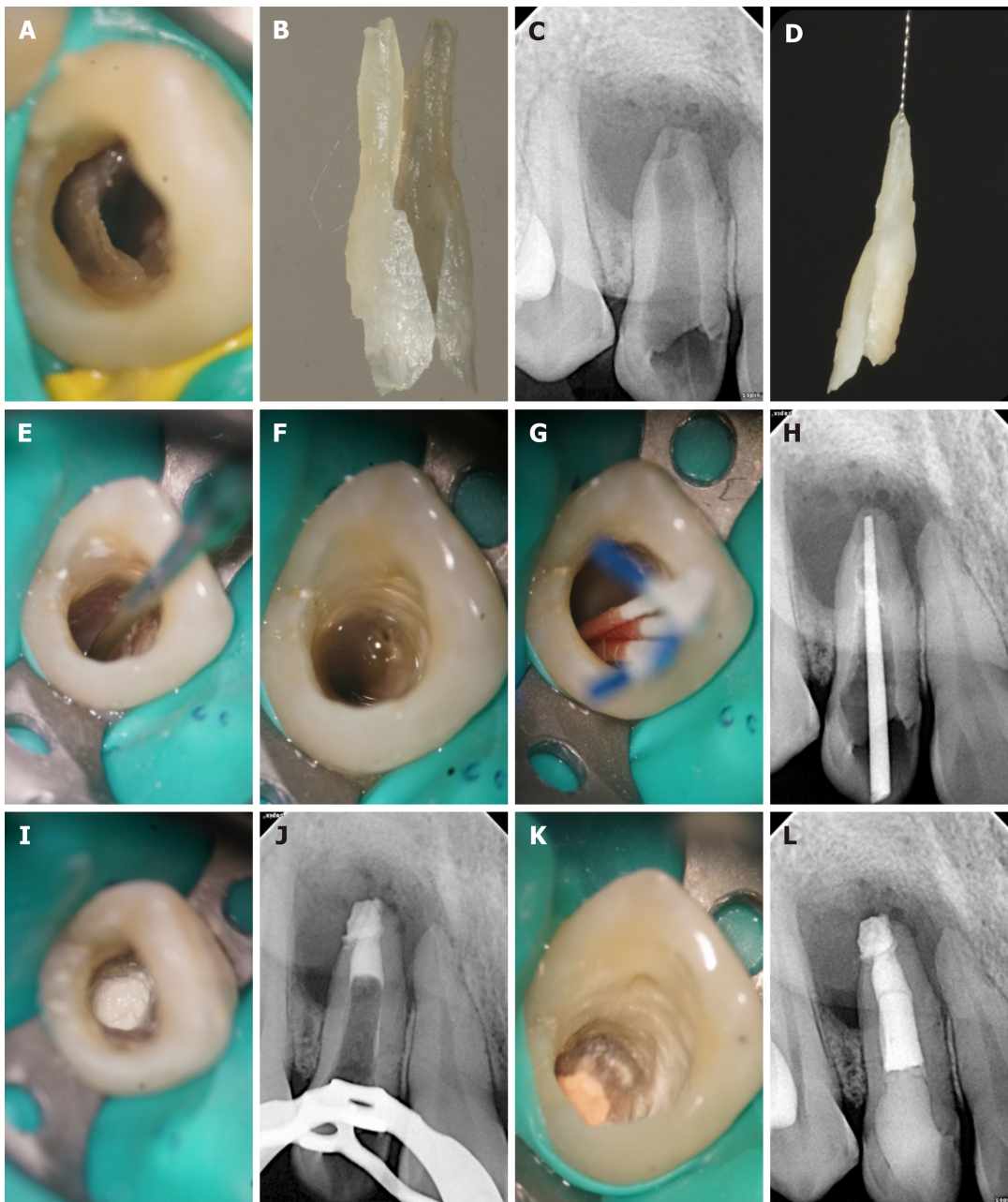


Figure 3 Non-surgical treatment process. A: Invaginated tooth seen under the dental operation microscope; B: Partially invaginated tooth taken out for the first step; C: Intraoperative film confirmed that the invaginated tooth was completely removed; D: *In vitro* photo of a complete invaginated tooth; E: The canal was prepared with ultrasonic tip; F: The canal was irrigated with 1% sodium hypochlorite and saline; G: The canal was dried with absorbent paper points; H: Working length was confirmed with the X-ray dental pictures; I: Mineral trioxide aggregate was seen under the dental operation microscope; J: A radiographic image showed the apical third root was obturated with 4 mm mineral trioxide aggregate; K: The remaining pulp space was obturated with thermoplastic gutta-percha, and the access cavity was sealed with a composite resin; L: Radiograph taken immediately after the treatment.

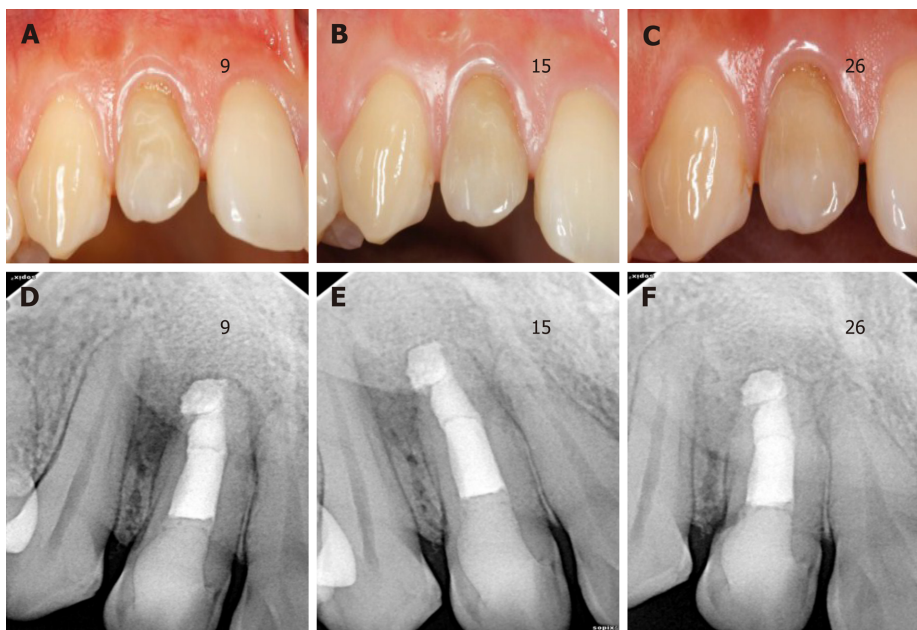


Figure 4 Follow-up images at different periods. A-C: The labial view of the invaginated tooth during 9-, 15- and 26-mo follow-up examinations; D-F: Periapical radiographs taken at the 9-, 15- and 26-mo follow-up examinations. The apical radiolucency was significantly reduced.

REFERENCES

- 1 Shafer WG, Hine MK, Levy BM. A Text-Book of Oral Pathology. 4th ed. Philadelphia: W.B. Saunders Company, 1983: 2
- 2 Hülsmann M. Dens invaginatus: aetiology, classification, prevalence, diagnosis, and treatment considerations. *Int Endod J* 1997; **30**: 79-90 [PMID: 10332241 DOI: 10.1046/j.1365-2591.1997.00065.x]
- 3 Alani A, Bishop K. Dens invaginatus. Part 1: classification, prevalence and aetiology. *Int Endod J* 2008; **41**: 1123-1136 [PMID: 19133103 DOI: 10.1111/j.1365-2591.2008.01468.x]
- 4 OEHLERS FA. Dens invaginatus (dilated composite odontome). I. Variations of the invagination process and associated anterior crown forms. *Oral Surg Oral Med Oral Pathol* 1957; **10**: 1204-18 contd [PMID: 13477660 DOI: 10.1016/0030-4220(57)90077-4]
- 5 Cakici F, Celikoglu M, Arslan H, Topcuoglu HS, Erdogan AS. Assessment of the prevalence and characteristics of dens invaginatus in a sample of Turkish Anatolian population. *Med Oral Patol Oral Cir Bucal* 2010; **15**: e855-e858 [PMID: 20526277 DOI: 10.4317/medoral.15.e855]
- 6 Rotstein I, Stabholz A, Heling I, Friedman S. Clinical considerations in the treatment of dens invaginatus. *Endod Dent Traumatol* 1987; **3**: 249-254 [PMID: 3479324 DOI: 10.1111/j.1600-9657.1987.tb00632.x]
- 7 Jaramillo A, Fernández R, Villa P. Endodontic treatment of dens invaginatus: a 5-year follow-up. *Oral Surg Oral Med Oral Pathol Oral Radiol Endod* 2006; **101**: e15-e21 [PMID: 16360600 DOI: 10.1016/j.tripleo.2005.08.008]
- 8 Hovland EJ, Block RM. Nonrecognition and subsequent endodontic treatment of dens invaginatus. *J Endod* 1977; **3**: 360-362 [PMID: 269901 DOI: 10.1016/S0099-2399(77)80067-8]
- 9 Tsurumachi T, Hayashi M, Takeichi O. Non-surgical root canal treatment of dens invaginatus type 2 in a maxillary lateral incisor. *Int Endod J* 2002; **35**: 310-314 [PMID: 11993441 DOI: 10.1046/j.1365-2591.2002.00450.x]
- 10 Nallapati S. Clinical management of a maxillary lateral incisor with vital pulp and type 3 dens invaginatus: a case report. *J Endod* 2004; **30**: 726-731 [PMID: 15448469 DOI: 10.1097/01.don.0000125879.11248.12]
- 11 Ortiz P, Weisleder R, Villareal de Justus Y. Combined therapy in the treatment of dens invaginatus: case report. *J Endod* 2004; **30**: 672-674 [PMID: 15329576 DOI: 10.1097/01.don.0000121611.19808.ad]
- 12 Nedley MP, Powers GK. Intentional extraction and reimplantation of an immature invaginated central incisor. *ASDC J Dent Child* 1997; **64**: 417-420 [PMID: 9466013]
- 13 Girsch WJ, McClammy TV. Microscopic removal of dens invaginatus. *J Endod* 2002; **28**: 336-339 [PMID: 12043878 DOI: 10.1097/00004770-200204000-00020]
- 14 Special Committee to Revise the Joint AAE/AAOMR Position Statement on use of CBCT in Endodontics. AAE and AAOMR Joint Position Statement: Use of Cone Beam Computed Tomography in Endodontics 2015 Update. *Oral Surg Oral Med Oral Pathol Oral Radiol* 2015; **120**: 508-512 [PMID: 26346911 DOI: 10.1016/j.oooo.2015.07.033]
- 15 Scarfe WC, Farman AG, Sukovic P. Clinical applications of cone-beam computed tomography in dental practice. *J Can Dent Assoc* 2006; **72**: 75-80 [PMID: 16480609]
- 16 Yajima A, Otonari-Yamamoto M, Sano T, Hayakawa Y, Otonari T, Tanabe K, Wakoh M, Mizuta S, Yonezu H, Nakagawa K, Yajima Y. Cone-beam CT (CB Throne) applied to dentomaxillofacial region. *Bull Tokyo Dent Coll* 2006; **47**: 133-141 [PMID: 17344621 DOI: 10.2209/tdcpublication.47.133]
- 17 Ziegler CM, Woertche R, Brief J, Hassfeld S. Clinical indications for digital volume tomography in oral and maxillofacial surgery. *Dentomaxillofac Radiol* 2002; **31**: 126-130 [PMID: 12076053 DOI: 10.1038/sj/dmfr.4600680]
- 18 Baratto Filho F, Zaitter S, Haragushiku GA, de Campos EA, Abuabara A, Correr GM. Analysis of the internal anatomy of maxillary first molars by using different methods. *J Endod* 2009; **35**: 337-342 [PMID: 19133103 DOI: 10.1111/j.1365-2591.2008.01468.x]

- 19249591 DOI: [10.1016/j.joen.2008.11.022](https://doi.org/10.1016/j.joen.2008.11.022)
- 19 **Zafersoy-Akarslan Z**, Erten H, Uzun O, Semiz M. Reproducibility and agreement of clinical diagnosis of occlusal caries using unaided visual examination and operating microscope. *J Can Dent Assoc* 2009; **75**: 455 [PMID: [19627655](https://pubmed.ncbi.nlm.nih.gov/19627655/)]
- 20 **Carr GB**, Murgel CA. The use of the operating microscope in endodontics. *Dent Clin North Am* 2010; **54**: 191-214 [PMID: [20433974](https://pubmed.ncbi.nlm.nih.gov/20433974/) DOI: [10.1016/j.cden.2010.01.002](https://doi.org/10.1016/j.cden.2010.01.002)]
- 21 **Torabinejad M**, Parirokh M, Dummer PMH. Mineral trioxide aggregate and other bioactive endodontic cements: an updated overview - part II: other clinical applications and complications. *Int Endod J* 2018; **51**: 284-317 [PMID: [28846134](https://pubmed.ncbi.nlm.nih.gov/28846134/) DOI: [10.1111/iej.12843](https://doi.org/10.1111/iej.12843)]
- 22 **Mente J**, Leo M, Panagidis D, Ohle M, Schneider S, Lorenzo Bermejo J, Pfefferle T. Treatment outcome of mineral trioxide aggregate in open apex teeth. *J Endod* 2013; **39**: 20-26 [PMID: [23228252](https://pubmed.ncbi.nlm.nih.gov/23228252/) DOI: [10.1016/j.joen.2012.10.007](https://doi.org/10.1016/j.joen.2012.10.007)]
- 23 **Pace R**, Giuliani V, Nieri M, Di Nasso L, Pagavino G. Mineral trioxide aggregate as apical plug in teeth with necrotic pulp and immature apices: a 10-year case series. *J Endod* 2014; **40**: 1250-1254 [PMID: [25069943](https://pubmed.ncbi.nlm.nih.gov/25069943/) DOI: [10.1016/j.joen.2013.12.007](https://doi.org/10.1016/j.joen.2013.12.007)]
- 24 **Bonte E**, Beslot A, Boukpepsi T, Lasfargues JJ. MTA versus Ca(OH)₂ in apexification of non-vital immature permanent teeth: a randomized clinical trial comparison. *Clin Oral Investig* 2015; **19**: 1381-1388 [PMID: [25467231](https://pubmed.ncbi.nlm.nih.gov/25467231/) DOI: [10.1007/s00784-014-1348-5](https://doi.org/10.1007/s00784-014-1348-5)]
- 25 **Moore A**, Howley MF, O'Connell AC. Treatment of open apex teeth using two types of white mineral trioxide aggregate after initial dressing with calcium hydroxide in children. *Dent Traumatol* 2011; **27**: 166-173 [PMID: [21564517](https://pubmed.ncbi.nlm.nih.gov/21564517/) DOI: [10.1111/j.1600-9657.2011.00984.x](https://doi.org/10.1111/j.1600-9657.2011.00984.x)]
- 26 **Annamalai S**, Mungara J. Efficacy of mineral trioxide aggregate as an apical plug in non-vital young permanent teeth: preliminary results. *J Clin Pediatr Dent* 2010; **35**: 149-155 [PMID: [21417116](https://pubmed.ncbi.nlm.nih.gov/21417116/) DOI: [10.17796/jcpd.35.2.9061h7g718834017](https://doi.org/10.17796/jcpd.35.2.9061h7g718834017)]
- 27 **Moretton TR**, Brown CE, Legan JJ, Kafrawy AH. Tissue reactions after subcutaneous and intraosseous implantation of mineral trioxide aggregate and ethoxybenzoic acid cement. *J Biomed Mater Res* 2000; **52**: 528-533 [PMID: [11007621](https://pubmed.ncbi.nlm.nih.gov/11007621/) DOI: [10.1002/1097-4636\(20001205\)52:3<528::aid-jbm11>3.0.co;2-9](https://doi.org/10.1002/1097-4636(20001205)52:3<528::aid-jbm11>3.0.co;2-9)]
- 28 **Enkel B**, Dupas C, Armengol V, Akpe Adou J, Bosco J, Daculsi G, Jean A, Laboux O, LeGeros RZ, Weiss P. Bioactive materials in endodontics. *Expert Rev Med Devices* 2008; **5**: 475-494 [PMID: [18573047](https://pubmed.ncbi.nlm.nih.gov/18573047/) DOI: [10.1586/17434440.5.4.475](https://doi.org/10.1586/17434440.5.4.475)]
- 29 **Islam I**, Chng HK, Yap AU. X-ray diffraction analysis of mineral trioxide aggregate and Portland cement. *Int Endod J* 2006; **39**: 220-225 [PMID: [16507076](https://pubmed.ncbi.nlm.nih.gov/16507076/) DOI: [10.1111/j.1365-2591.2006.01077.x](https://doi.org/10.1111/j.1365-2591.2006.01077.x)]
- 30 **Gancedo-Caravia L**, Garcia-Barbero E. Influence of humidity and setting time on the push-out strength of mineral trioxide aggregate obturations. *J Endod* 2006; **32**: 894-896 [PMID: [16934637](https://pubmed.ncbi.nlm.nih.gov/16934637/) DOI: [10.1016/j.joen.2006.03.004](https://doi.org/10.1016/j.joen.2006.03.004)]



Published By Baishideng Publishing Group Inc
7041 Koll Center Parkway, Suite 160, Pleasanton, CA 94566, USA
Telephone: +1-925-3991568
E-mail: bpgoffice@wjgnet.com
Help Desk: <https://www.f6publishing.com/helpdesk>
<https://www.wjgnet.com>

