

World Journal of *Gastroenterology*

World J Gastroenterol 2020 May 7; 26(17): 1987-2125



**OPINION REVIEW**

- 1987** Significance of progressive liver fibrosis in pediatric liver transplants: A review of current evidence
George M, Paci P, Taner T

REVIEW

- 1993** Metabolic inflammation as an instigator of fibrosis during non-alcoholic fatty liver disease
Katsarou A, Moustakas II, Pyrina I, Lembessis P, Koutsilieris M, Chatzigeorgiou A
- 2012** Pearls and pitfalls in magnetic resonance imaging of hepatocellular carcinoma
Kovac JD, Milovanovic T, Dugalic V, Domic I

MINIREVIEWS

- 2030** Management of Barrett's esophagus with dysplasia refractory to radiofrequency ablation
Raphael KL, Trindade AJ
- 2040** Radiofrequency combined with immunomodulation for hepatocellular carcinoma: State of the art and innovations
da Costa AC, Sodergren M, Jayant K, Santa Cruz F, Spalding D, Pai M, Habib N
- 2049** Ethnic differences in genetic polymorphism associated with irritable bowel syndrome
Xiao QY, Fang XC, Li XQ, Fei GJ

ORIGINAL ARTICLE**Basic Study**

- 2064** Epigallocatechin gallate inhibits dimethylhydrazine-induced colorectal cancer in rats
Wang Y, Jin HY, Fang MZ, Wang XF, Chen H, Huang SL, Kong DS, Li M, Zhang X, Sun Y, Wang SM

Retrospective Study

- 2082** Prediction of different stages of rectal cancer: Texture analysis based on diffusion-weighted images and apparent diffusion coefficient maps
Yin JD, Song LR, Lu HC, Zheng X

Clinical Trials Study

- 2097** Assessment of hemostatic profile in patients with mild to advanced liver cirrhosis
Adam EH, Möhlmann M, Herrmann E, Schneider S, Zacharowski K, Zeuzem S, Weber CF, Weiler N

CASE REPORT

- 2111** Multiple carcinosarcomas of the esophagus with adeno-carcinomatous components: A case report
Okamoto H, Kikuchi H, Naganuma H, Kamei T
- 2119** Gastrocolic fistula in Crohn's disease detected by oral agent contrast-enhanced ultrasound: A case report of a novel ultrasound modality
Wu S, Zhuang H, Zhao JY, Wang YF

ABOUT COVER

Associate Editor of *World Journal of Gastroenterology*, Jürgen Stein, MD, PhD, Doctor, Professor, Department of Gastroenterology and Clinical Nutrition, DGD Clinics Frankfurt-Sachsenhausen, Teaching Hospital of the University of Frankfurt, Frankfurt/Main 60594, Germany

AIMS AND SCOPE

The primary aim of *World Journal of Gastroenterology* (WJG, *World J Gastroenterol*) is to provide scholars and readers from various fields of gastroenterology and hepatology with a platform to publish high-quality basic and clinical research articles and communicate their research findings online.

WJG mainly publishes articles reporting research results and findings obtained in the field of gastroenterology and hepatology and covering a wide range of topics including gastroenterology, hepatology, gastrointestinal endoscopy, gastrointestinal surgery, gastrointestinal oncology, and pediatric gastroenterology.

INDEXING/ABSTRACTING

The WJG is now indexed in Current Contents®/Clinical Medicine, Science Citation Index Expanded (also known as SciSearch®), Journal Citation Reports®, Index Medicus, MEDLINE, PubMed, PubMed Central, and Scopus. The 2019 edition of Journal Citation Report® cites the 2018 impact factor for WJG as 3.411 (5-year impact factor: 3.579), ranking WJG as 35th among 84 journals in gastroenterology and hepatology (quartile in category Q2). CiteScore (2018): 3.43.

RESPONSIBLE EDITORS FOR THIS ISSUE

Responsible Electronic Editor: *Yu-Jie Ma*

Proofing Production Department Director: *Xiang Li*

Responsible Editorial Office Director: *Ze-Mao Gong*

NAME OF JOURNAL

World Journal of Gastroenterology

ISSN

ISSN 1007-9327 (print) ISSN 2219-2840 (online)

LAUNCH DATE

October 1, 1995

FREQUENCY

Weekly

EDITORS-IN-CHIEF

Subrata Ghosh, Andrzej S Tarnawski

EDITORIAL BOARD MEMBERS

<http://www.wjgnet.com/1007-9327/editorialboard.htm>

PUBLICATION DATE

May 7, 2020

COPYRIGHT

© 2020 Baishideng Publishing Group Inc

INSTRUCTIONS TO AUTHORS

<https://www.wjgnet.com/bpg/gerinfo/204>

GUIDELINES FOR ETHICS DOCUMENTS

<https://www.wjgnet.com/bpg/GerInfo/287>

GUIDELINES FOR NON-NATIVE SPEAKERS OF ENGLISH

<https://www.wjgnet.com/bpg/gerinfo/240>

PUBLICATION ETHICS

<https://www.wjgnet.com/bpg/GerInfo/288>

PUBLICATION MISCONDUCT

<https://www.wjgnet.com/bpg/gerinfo/208>

ARTICLE PROCESSING CHARGE

<https://www.wjgnet.com/bpg/gerinfo/242>

STEPS FOR SUBMITTING MANUSCRIPTS

<https://www.wjgnet.com/bpg/GerInfo/239>

ONLINE SUBMISSION

<https://www.f6publishing.com>



Significance of progressive liver fibrosis in pediatric liver transplants: A review of current evidence

Mathew George, Philippe Paci, Timucin Taner

ORCID number: Mathew George (0000-0001-7489-4711); Philippe Paci (0000-0002-1834-3541); Timucin Taner (0000-0003-0641-2930).

Author contributions: George M, Paci P and Taner T conceived and outlined the review; George M and Paci P performed literature review and wrote the manuscript; Taner T made critical revisions and approved the final version of the manuscript.

Conflict-of-interest statement: The authors declare no conflict of interests.

Open-Access: This article is an open-access article that was selected by an in-house editor and fully peer-reviewed by external reviewers. It is distributed in accordance with the Creative Commons Attribution NonCommercial (CC BY-NC 4.0) license, which permits others to distribute, remix, adapt, build upon this work non-commercially, and license their derivative works on different terms, provided the original work is properly cited and the use is non-commercial. See: <http://creativecommons.org/licenses/by-nc/4.0/>

Manuscript source: Invited manuscript

Received: December 31, 2019

Peer-review started: December 31, 2019

First decision: February 19, 2020

Revised: March 31, 2020

Accepted: April 21, 2020

Article in press: April 21, 2020

Published online: May 7, 2020

Mathew George, Philippe Paci, Timucin Taner, Departments of Surgery, Mayo Clinic, Rochester, MN 55905, United States

Timucin Taner, Departments of Immunology, Mayo Clinic, Rochester, MN 55905, United States

Corresponding author: Timucin Taner, FACS, MD, PhD, Associate Professor, Surgeon, Departments of Surgery, Mayo Clinic, 200 First Street Southwest, Rochester, MN 55905, United States. taner.timucin@mayo.edu

Abstract

This article reviews the current evidence and knowledge of progressive liver fibrosis after pediatric liver transplantation. This often-silent histologic finding is common in long-term survivors and may lead to allograft dysfunction in advanced stages. Surveillance through protocolized liver allograft biopsy remains the gold standard for diagnosis, and recent evidence suggests that chronic inflammation precedes fibrosis.

Key words: Allograft fibrosis; Pediatric liver transplant; Chronic rejection; Immunosuppression; Portal inflammation; Liver allograft

©The Author(s) 2020. Published by Baishideng Publishing Group Inc. All rights reserved.

Core tip: Progressive liver allograft fibrosis is a common finding after liver transplantation in children and may lead to allograft failure in the long-term. Recent data from centers performing sequential protocol biopsies after pediatric liver transplantation demonstrate that chronic inflammation precedes fibrosis. In this review, we provide an update on pathogenesis, diagnosis and management of progressive liver fibrosis in pediatric liver transplant recipients.

Citation: George M, Paci P, Taner T. Significance of progressive liver fibrosis in pediatric liver transplants: A review of current evidence. *World J Gastroenterol* 2020; 26(17): 1987-1992

URL: <https://www.wjgnet.com/1007-9327/full/v26/i17/1987.htm>

DOI: <https://dx.doi.org/10.3748/wjg.v26.i17.1987>

P-Reviewer: Mandorfer M

S-Editor: Dou Y

L-Editor: A

E-Editor: Liu MY



INTRODUCTION

Improvements in organ preservation, perioperative care and immunosuppression have increased patient and graft survival after pediatric liver transplantation over the past three decades. As such, currently, the 10-year patient and graft survival are 83% and 73%, respectively^[1]. Despite these good early outcomes, most pediatric liver transplant recipients fail to meet the goal of “one graft for lifetime”. Progressive liver fibrosis, a common cause of liver allograft failure in pediatric liver transplant recipients, remains highly prevalent in late post-transplant liver biopsies; reported in 69% to 97% of all cases^[2-7] (Table 1). Here, we review the current evidence on pathogenesis, etiology, diagnosis and management of progressive liver fibrosis in pediatric liver transplant recipients.

ETIOPATHOGENESIS OF PROGRESSIVE LIVER FIBROSIS

While a detailed overview of the liver fibrosis is beyond the scope of this review, understanding the main instigators of this process is of paramount importance in the context of progressive liver fibrosis. Fibrosis in the liver is a wound healing response to chronic injury, secondary to infections (*e.g.*, viral hepatitis), immune-mediated mechanisms (*e.g.*, auto-immune hepatitis) or chemicals (*e.g.*, alcoholic hepatitis). Fibrosis can occur both in the native and transplanted liver. Studies have shown that the central event in liver fibrosis is activation of hepatic stellate cells (HSC) in response to chronic injury. HSC are located in the subendothelial space of Disse, between sinusoidal epithelium and hepatocytes. Activated HSC increase expression of cytoplasmic alpha-smooth muscle actin. This differentiation is followed by secretion of collagen Type 1 and 3^[8,9]. In addition, HSC activate other fibrogenic mechanisms through paracrine stimuli.

Two additional mechanisms of chronic injury can occur in transplanted livers; alloimmune inflammation (Figure 1A and B) and biliary outflow obstruction (Figure 1C). The association between allograft inflammation and progressive fibrosis has been demonstrated in multiple studies. Based on 1-, 5- and 10-year protocol liver allograft biopsies in pediatric liver transplant recipients, Evans *et al*^[3] showed that the incidence of chronic, silent inflammation exceeds 40% at 5 years, and 60% at 10 years. The group from Belgium, Varma *et al*^[10] subsequently investigated the temporal relationship of inflammation and fibrosis, using sequential allograft biopsies (a total of 5 biopsies in 10 years). Their analysis demonstrated that the biggest predictor of graft fibrosis is portal inflammation (Figure 1A) seen in the preceding biopsy. Furthermore, the severity of the inflammation correlated with the risk of fibrosis (Figure 1C and D) in the consecutive biopsy.

The role of donor-specific HLA antibodies (DSA) in development of allograft fibrosis after pediatric liver transplantation has been investigated in Kyoto, Japan^[11]. Based on 5-20-year protocol liver biopsies, the investigators found a significant correlation with circulating DSA and stage 3 and 4 fibrosis. More in-depth evaluation of the biopsies, however, demonstrated that the incidence of inflammation in the preceding liver biopsy of the recipients with DSA was significantly higher, raising the question of whether the DSA is a consequence of inflammation, rather than the cause of fibrosis. Previous studies from our group at the Mayo Clinic have shown that the inflammation in patients with DSA is not different than that of patients without DSA^[12], and the alloreactivity of T cells in liver patients, regardless of the DSA status, is reduced^[13].

One of the theories that explain immune mediated injury and subsequent fibrosis is “antigenic mimicry”. HLA-DRB1*03/04 allele in liver recipients predisposes to such injury. The mechanism of injury is similar to autoimmune hepatitis as explained by Montano-Loza *et al*^[14] and Liberal *et al*^[15]. This allele favors faulty antigen processing causing immune mediated hepatocyte injury. Varma *et al*^[10] in their observational study of 89 stable liver recipients noted that HLA-DRB1*03/04 is a risk factor for high grade fibrosis and these recipients need to be monitored closely.

DIAGNOSIS

Protocol liver biopsy

Liver function tests are usually normal at early stages of liver allograft fibrosis after pediatric liver transplantation. Therefore, liver biopsy remains the current gold standard for diagnosis of fibrosis though with some limitations which include sampling errors. Although it is an invasive diagnostic tool, liver biopsy in pediatric

Table 1 Incidence of liver allograft fibrosis in protocol liver biopsies in various studies

Ref.	1-2 yr (%)	3-5 yr (%)	10 yr (%)
Fouquet <i>et al</i> ^[4] , 2005			73
Evans <i>et al</i> ^[3] , 2006	32	55	69
Ekong <i>et al</i> ^[2] , 2008		97	
Scheenstra <i>et al</i> ^[6] , 2009	34	65	69
Miyagawa-Hayashino <i>et al</i> ^[11] , 2012		84	
Sanada <i>et al</i> ^[5] , 2014	24.7	34.5	
Sheikh <i>et al</i> ^[23] , 2018		2	

liver transplant recipients has a low complication rate and provides invaluable information regarding the health of the allograft. Thus, most pediatric liver transplant programs have adapted protocolized liver biopsy at various time points. These biopsies are evaluated for fibrosis by using either the METAVIR or the Liver Allograft Fibrosis Score systems (Table 2). As the more commonly used METAVIR score was not designed for evaluating allograft biopsies, the latter may be better suited for transplant patients. Regardless, both score systems have advantages and disadvantages, detailed in Table 2. In order to decrease the odds of sampling error and observer variability, it is recommended that the biopsy specimen to be at least 20-25 mm^[16,17].

In addition to the routine histological evaluation, recently the utility of the assessment of alpha smooth muscle actin in biopsies was tested. As discussed above, HSC express cytoplasmic alpha smooth muscle actin prior to secreting collagen. Therefore, theoretically, quantification of alpha smooth muscle actin could predict severity of future fibrosis in the allograft. In fact, in a recent study, alpha smooth muscle actin -positive area percentage > 1.05 predicted increased fibrosis in the subsequent biopsy with a 90% specificity^[18].

Serological tests for fibrosis

Fibro test: Fibro test in pediatric liver transplant patients is calculated from six biochemical markers (gamma glutamyl transpeptidase, alanine aminotransferase, haptoglobin, alpha-2-macroglobulin, apolipoprotein-A1, and total bilirubin) as well as age and sex of the patient. The test was devised by Bio Predictive, France. The score lies between 0 and 1. There was, however, no correlation of FT with the degree of fibrosis^[19].

Enhanced liver fibrosis test: The enhanced liver fibrosis test (ELF test, Siemens) combines Hyaluronic Acid, amino-terminal propeptide of type III collagen, and tissue inhibitor of metalloproteinase 1 in an algorithm. ELF values were significantly higher in healthy transplant children compared with healthy controls. Values < 7.7 mild or no fibrosis, 7.7-9.8 moderate fibrosis, and > 9.8 severe fibrosis. There was however no correlation of ELF with the degree of fibrosis^[19].

Imaging studies

Transient elastography: Uses the propagation velocity of an ultrasound wave to calculate liver stiffness. It is useful to detect advanced fibrosis rather than milder forms. The technique is generally applicable in children and has been shown to be of some diagnostic value. However, it is not a test for screening fibrosis; although it can be used for follow up after establishing a base line for the patient^[19]. Limitations of the elastography in children include the requirement of pediatric probes and distorted signals secondary to the midline position of the grafts. In addition, elastography in pediatric transplant recipients with no fibrosis (based on biopsy) reveals higher scores than that in children who have not had a transplant^[19].

Acoustic radiation force impulse: This is another ultrasound based elastography method. The region of interest in the liver is located using a real time B mode ultrasound. Tissue in the region of interest is mechanically excited with an impulsive acoustic radiation force, which results in the generation of shear waves within the tissue; the velocity of these shear waves in meters per second indirectly measures the elasticity of the liver. Tomita *et al*^[20] showed that acoustic radiation force impulse had good accuracy in detecting graft fibrosis after living donor liver transplantation.

Magnetic resonance imaging: Serai *et al*^[21] in 2018 had used magnetic resonance imaging (MRI) derived liver stiffness in pediatric and young population for a wide

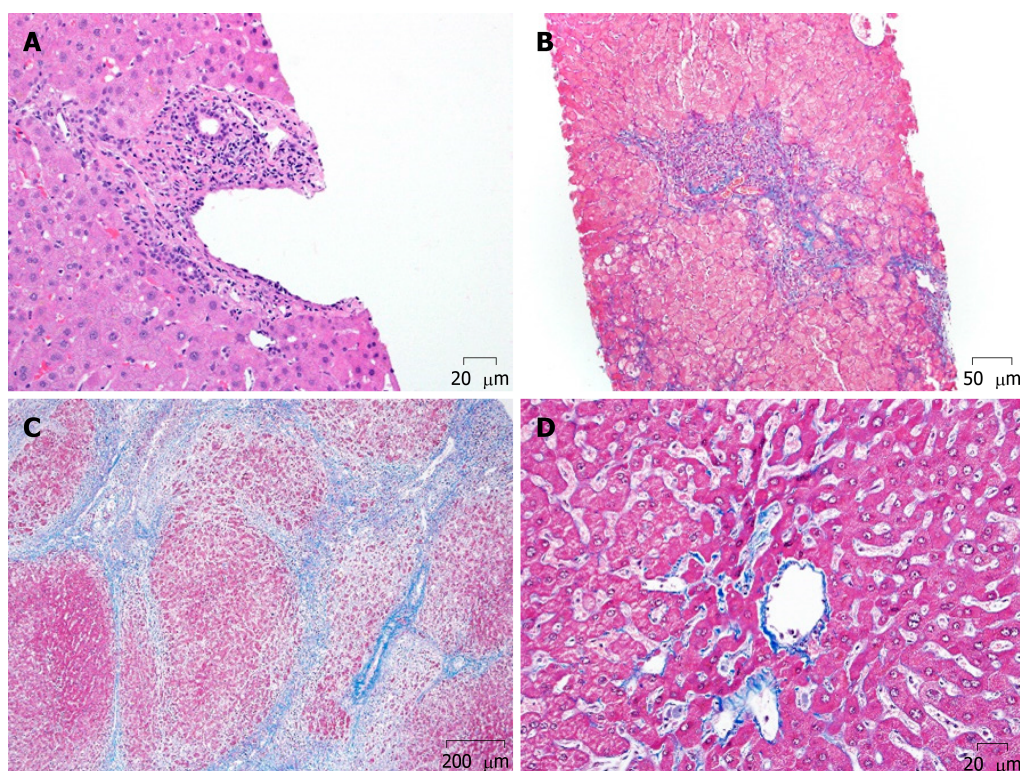


Figure 1 Hematoxylin-eosin staining results. A and B: Portal inflammation, noted for infiltration of the portal fields with inflammatory cells (A, 40 ×) can give rise to fibrosis in the same field (periportal fibrosis) (B, 10 ×); C: When the fibrosis extends from portal fields to adjacent portal fields, biliary type fibrosis ensues (20 ×); D: Conversely, fibrosis can also occur in perisinusoidal or perivenular compartments (40 ×).

variety of liver diseases. MRI was found to have moderate test performance for distinguishing stage 0-1 fibrosis from stage 2 or higher fibrosis in pediatric patients with liver disease. MRI has still not been used for detecting fibrosis in pediatric liver allografts but seems to be a modality for the future.

MANAGEMENT OF PATIENTS WITH LIVER FIBROSIS

Because of the correlation between alloimmune injury and subsequent development of progressive allograft fibrosis after pediatric liver transplantation, intensifying immunosuppression has been the most common approach in management of patients with fibrosis. In a cross-sectional study of 60 pediatric liver transplant recipients from Hamburg, Germany, 14 patients were found to have inflammation and early fibrosis in protocol biopsies, despite normal laboratory findings^[22]. Accordingly, immunosuppression was intensified by increasing the goal trough levels of Cyclosporin A and Tacrolimus. Five of the 14 patients were then biopsied, 12 to 18 mo later. Histologic evaluation demonstrated resolution of inflammation and improvement in the fibrosis score in 4 patients in whom the higher drug trough levels could be achieved. Similarly, Sanada *et al*^[5] reported that in 11 pediatric liver transplant patients with 5 year protocol liver allograft biopsies demonstrating moderate inflammation and fibrosis, improvement in both the inflammation and fibrosis scores was achieved in all patients after intensifying the immunosuppression. In the most recent report from Sheikh *et al*^[23], 44 liver transplant recipients in New Zealand were maintained on stable, Tacrolimus-based immunosuppression for the first 5 years, with a median trough level of 5.8 µg/L. With that, the incidence of fibrosis in liver allografts was as low as 2% at 5 years, notable for the lowest such incidences in the literature.

The role of steroids in preventing fibrosis was investigated by Venturi *et al*^[17] in 2014. In a cohort of 38 pediatric liver transplant recipients, the authors found that the incidence of allograft fibrosis within the first year was higher among the group that was maintained on a steroid-free immunosuppression regimen. However, long term progression of the fibrosis was similar in the steroid-free and steroid-inclusive immunosuppression groups, indicating that the potentially protective impact of steroids on liver allograft fibrosis may not be sustained in the long-term.

Table 2 Comparison of METAVIR and Liver Allograft Fibrosis scores for fibrosis assessment

METAVIR score ^[25]	Liver allograft fibrosis score – LAFSc ^[26]
Portal and periportal (Figure 1B) tract-based fibrosis scoring systems	Periportal (Figure 1B), Perisinusoidal and perivenular (Figure 1C) fibrosis-based staging
Used for assessing fibrosis in post viral hepatitis, may not accurately quantify LAF in pediatric population. Assesses fibrosis located in portal tracts, underestimating LAF in the other areas	LAFSc system stages fibrosis adding portal tracts, sinusoids and centrilobular areas. Advantage of LAFSc is the individual assessment of fibrosis in portal tracts, sinusoids and centrilobular veins providing good representation of the whole hepatic acinus
The stage of fibrosis was assessed on a five-point scale: F0 = no fibrosis, F1 = portal fibrosis without septa, F2 = few septa, F3 = numerous septa without cirrhosis, F4 = cirrhosis; Activity was graded according to the intensity of necro inflammatory lesions: A0 = no histological activity, A1 = mild activity, A2 = moderate activity, A3 = severe activity	Fibrosis deposition was classified in three main areas of the liver parenchyma: Portal tracts, sinusoids (zones 1 and 2) and centrilobular veins (zone 3); in each area, fibrosis was staged from 0 to 3 (0 = absent, 1 = mild, 2 = moderate and 3 = severe fibrosis), with a total score of 9. Equal score weight was assigned to each area to accurately reflect fibrosis distribution in liver allograft specimens
A histopathological abnormality is a Metavir score of \geq A1 or \geq F1 and such scores indicate the need for treatment because liver fibrosis is reversible if early treatment is initiated	LAFSc: \leq 3 – mild fibrosis; 4-5 – moderate fibrosis; \geq 6 – severe fibrosis
In a sample of PLB specimens METAVIR detected LAF in 81.6% specimens ^[26]	LAFSc showed fibrosis in 93.5% of specimens ^[26]

LAFSc: Liver Allograft Fibrosis Score; LAF: Liver allograft fibrosis.

Given these findings, it is reasonable to suggest that detection of early reversible graft fibrosis warrants increasing immunosuppression. It should be noted, however, that none of the above-mentioned studies are randomized.

THE FUTURE

As outlined above, much remains to be investigated to elucidate the mechanisms that trigger graft fibrosis in pediatric liver transplant recipients. A promising development is the establishment of the Graft Injury Group Observing Long-term Outcome group in early 2015^[24]. This international multicenter, multidisciplinary collaboration aims to follow a population of children post liver transplant in order to identify mechanisms of allograft injury, and to determine predictive factors for progression of disease and treatment response, with the ultimate goal of improving long-term graft survival.

Preliminary data from 6 European transplant centers shows increasing incidence of chronic graft hepatitis (43% at 5 years, 53% at 10 years) and fibrosis (54% at 5 years, 79% at 10 years) over time. It appears that children treated with long-term low dose steroids are significantly less likely to have graft hepatitis compared to those not on steroids both at 5 years and 10 years. This improvement, however, was not associated with decreased graft fibrosis at 10 years.

CONCLUSION

As long-term survivors of pediatric liver transplantation continue to increase, so does the incidence of progressive graft fibrosis. The definitive way of diagnosis of graft fibrosis is still through a liver biopsy. Even though studies show early post-transplant biopsies are not needed (1 and 2 year) most of the centers do regular protocol biopsies at 1, 5, 10, 15 and 20 years. There is also evidence that some of the fibrosis could be driven by genetic predisposition, allo-immunity and inflammation. There has been evidence to suggest that preceding inflammation and its intensity correlated with subsequent fibrosis. Portal inflammation has been the strongest predictor of portal fibrosis in subsequent protocol biopsies and this is not seen in other areas^[10]. The current understanding is early fibrosis is reversible with increasing immunosuppression emphasizing the need for constant surveillance of pediatric liver allograft recipients.

REFERENCES

- 1 **Martinelli J**, Habes D, Majed L, Guettier C, Gonzalès E, Linglart A, Larue C, Furlan V, Pariente D, Baujard C, Branchereau S, Gauthier F, Jacquemin E, Bernard O. Long-term outcome of liver transplantation in childhood: A study of 20-year survivors. *Am J Transplant* 2018; **18**: 1680-1689 [PMID: 30111111]

- 29247469 DOI: [10.1111/ajt.14626](https://doi.org/10.1111/ajt.14626)
- 2 **Ekong UD**, Melin-Aldana H, Seshadri R, Lokar J, Harris D, Whittington PF, Alonso EM. Graft histology characteristics in long-term survivors of pediatric liver transplantation. *Liver Transpl* 2008; **14**: 1582-1587 [PMID: [18975292](https://pubmed.ncbi.nlm.nih.gov/18975292/) DOI: [10.1002/lt.21549](https://doi.org/10.1002/lt.21549)]
- 3 **Evans HM**, Kelly DA, McKiernan PJ, Hübscher S. Progressive histological damage in liver allografts following pediatric liver transplantation. *Hepatology* 2006; **43**: 1109-1117 [PMID: [16628633](https://pubmed.ncbi.nlm.nih.gov/16628633/) DOI: [10.1002/hep.21152](https://doi.org/10.1002/hep.21152)]
- 4 **Fouquet V**, Alves A, Branchereau S, Grabar S, Debray D, Jacquemin E, Devictor D, Durand P, Baujard C, Fabre M, Pariente D, Chardot C, Dousset B, Massault PP, Bernard D, Houssin D, Bernard O, Gauthier F, Soubrane O. Long-term outcome of pediatric liver transplantation for biliary atresia: a 10-year follow-up in a single center. *Liver Transpl* 2005; **11**: 152-160 [PMID: [15666395](https://pubmed.ncbi.nlm.nih.gov/15666395/) DOI: [10.1002/lt.20358](https://doi.org/10.1002/lt.20358)]
- 5 **Sanada Y**, Matsumoto K, Urahashi T, Ihara Y, Wakiya T, Okada N, Yamada N, Hirata Y, Mizuta K. Protocol liver biopsy is the only examination that can detect mid-term graft fibrosis after pediatric liver transplantation. *World J Gastroenterol* 2014; **20**: 6638-6650 [PMID: [24914389](https://pubmed.ncbi.nlm.nih.gov/24914389/) DOI: [10.3748/wjg.v20.i21.6638](https://doi.org/10.3748/wjg.v20.i21.6638)]
- 6 **Scheenstra R**, Peeters PM, Verkade HJ, Gouw AS. Graft fibrosis after pediatric liver transplantation: ten years of follow-up. *Hepatology* 2009; **49**: 880-886 [PMID: [19101912](https://pubmed.ncbi.nlm.nih.gov/19101912/) DOI: [10.1002/hep.22686](https://doi.org/10.1002/hep.22686)]
- 7 **Ueno T**, Tanaka N, Ihara Y, Takama Y, Yamada H, Mushiaki S, Fukuzawa M. Graft fibrosis in patients with biliary atresia after pediatric living-related liver transplantation. *Pediatr Transplant* 2011; **15**: 470-475 [PMID: [21771230](https://pubmed.ncbi.nlm.nih.gov/21771230/) DOI: [10.1111/j.1399-3046.2011.01483.x](https://doi.org/10.1111/j.1399-3046.2011.01483.x)]
- 8 **Lee UE**, Friedman SL. Mechanisms of hepatic fibrogenesis. *Best Pract Res Clin Gastroenterol* 2011; **25**: 195-206 [PMID: [21497738](https://pubmed.ncbi.nlm.nih.gov/21497738/) DOI: [10.1016/j.bpg.2011.02.005](https://doi.org/10.1016/j.bpg.2011.02.005)]
- 9 **Lee YA**, Wallace MC, Friedman SL. Pathobiology of liver fibrosis: a translational success story. *Gut* 2015; **64**: 830-841 [PMID: [25681399](https://pubmed.ncbi.nlm.nih.gov/25681399/) DOI: [10.1136/gutjnl-2014-306842](https://doi.org/10.1136/gutjnl-2014-306842)]
- 10 **Varma S**, Ambrose J, Komuta M, Latinne D, Baldin P, Reding R, Smets F, Stephenne X, Sokal EM. Progressive Fibrosis Is Driven by Genetic Predisposition, Allo-immunity, and Inflammation in Pediatric Liver Transplant Recipients. *EBioMedicine* 2016; **9**: 346-355 [PMID: [27333038](https://pubmed.ncbi.nlm.nih.gov/27333038/) DOI: [10.1016/j.ebiom.2016.05.040](https://doi.org/10.1016/j.ebiom.2016.05.040)]
- 11 **Miyagawa-Hayashino A**, Yoshizawa A, Uchida Y, Egawa H, Yurugi K, Masuda S, Minamiguchi S, Maekawa T, Uemoto S, Haga H. Progressive graft fibrosis and donor-specific human leukocyte antigen antibodies in pediatric late liver allografts. *Liver Transpl* 2012; **18**: 1333-1342 [PMID: [22888064](https://pubmed.ncbi.nlm.nih.gov/22888064/) DOI: [10.1002/lt.23534](https://doi.org/10.1002/lt.23534)]
- 12 **Taner T**, Heimbach JK, Rosen CB, Nyberg SL, Park WD, Stegall MD. Decreased chronic cellular and antibody-mediated injury in the kidney following simultaneous liver-kidney transplantation. *Kidney Int* 2016; **89**: 909-917 [PMID: [26924059](https://pubmed.ncbi.nlm.nih.gov/26924059/) DOI: [10.1016/j.kint.2015.10.016](https://doi.org/10.1016/j.kint.2015.10.016)]
- 13 **Taner T**, Gustafson MP, Hansen MJ, Park WD, Bornschlegl S, Dietz AB, Stegall MD. Donor-specific hypo-responsiveness occurs in simultaneous liver-kidney transplant recipients after the first year. *Kidney Int* 2018; **93**: 1465-1474 [PMID: [29656904](https://pubmed.ncbi.nlm.nih.gov/29656904/) DOI: [10.1016/j.kint.2018.01.022](https://doi.org/10.1016/j.kint.2018.01.022)]
- 14 **Montano-Loza AJ**, Carpenter HA, Czaja AJ. Clinical significance of HLA DRB103-DRB104 in type 1 autoimmune hepatitis. *Liver Int* 2006; **26**: 1201-1208 [PMID: [17105585](https://pubmed.ncbi.nlm.nih.gov/17105585/) DOI: [10.1111/j.1478-3231.2006.01387.x](https://doi.org/10.1111/j.1478-3231.2006.01387.x)]
- 15 **Liberal R**, Vergani D, Mieli-Vergani G. Update on Autoimmune Hepatitis. *J Clin Transl Hepatol* 2015; **3**: 42-52 [PMID: [26357634](https://pubmed.ncbi.nlm.nih.gov/26357634/) DOI: [10.14218/JCTH.2014.00032](https://doi.org/10.14218/JCTH.2014.00032)]
- 16 Intraobserver and interobserver variations in liver biopsy interpretation in patients with chronic hepatitis C. The French METAVIR Cooperative Study Group. *Hepatology* 1994; **20**: 15-20 [PMID: [26052460](https://pubmed.ncbi.nlm.nih.gov/26052460/)]
- 17 **Venturi C**, Sempoux C, Quinones JA, Bourdeaux C, Hoyos SP, Sokal E, Reding R. Dynamics of allograft fibrosis in pediatric liver transplantation. *Am J Transplant* 2014; **14**: 1648-1656 [PMID: [24934832](https://pubmed.ncbi.nlm.nih.gov/24934832/) DOI: [10.1111/ajt.12740](https://doi.org/10.1111/ajt.12740)]
- 18 **Varma S**, Stéphenne X, Komuta M, Bouzin C, Ambrose J, Smets F, Reding R, Sokal EM. The histological quantification of alpha-smooth muscle actin predicts future graft fibrosis in pediatric liver transplant recipients. *Pediatr Transplant* 2017; **21** [PMID: [27774712](https://pubmed.ncbi.nlm.nih.gov/27774712/) DOI: [10.1111/ptr.12834](https://doi.org/10.1111/ptr.12834)]
- 19 **Goldschmidt I**, Stieghorst H, Munteanu M, Poynard T, Schlue J, Streckenbach C, Baumann U. The use of transient elastography and non-invasive serum markers of fibrosis in pediatric liver transplant recipients. *Pediatr Transplant* 2013; **17**: 525-534 [PMID: [23802661](https://pubmed.ncbi.nlm.nih.gov/23802661/) DOI: [10.1111/ptr.12116](https://doi.org/10.1111/ptr.12116)]
- 20 **Tomita H**, Hoshino K, Fuchimoto Y, Ebinuma H, Ohkuma K, Tanami Y, Du W, Masugi Y, Shimojima N, Fujino A, Kano M, Fujimura T, Ishihama H, Shimizu T, Tanabe M, Saito H, Sakamoto M, Hibi T, Kitagawa Y, Kuroda T. Acoustic radiation force impulse imaging for assessing graft fibrosis after pediatric living donor liver transplantation: a pilot study. *Liver Transpl* 2013; **19**: 1202-1213 [PMID: [23894066](https://pubmed.ncbi.nlm.nih.gov/23894066/) DOI: [10.1002/lt.23708](https://doi.org/10.1002/lt.23708)]
- 21 **Serai SD**, Trout AT, Sirlin CB. Elastography to assess the stage of liver fibrosis in children: Concepts, opportunities, and challenges. *Clin Liver Dis (Hoboken)* 2017; **9**: 5-10 [PMID: [30992948](https://pubmed.ncbi.nlm.nih.gov/30992948/) DOI: [10.1002/cld.607](https://doi.org/10.1002/cld.607)]
- 22 **Briem-Richter A**, Ganschow R, Sornsakrin M, Brinkert F, Schirmer J, Schaefer H, Grabhorn E. Liver allograft pathology in healthy pediatric liver transplant recipients. *Pediatr Transplant* 2013; **17**: 543-549 [PMID: [23834615](https://pubmed.ncbi.nlm.nih.gov/23834615/) DOI: [10.1111/ptr.12119](https://doi.org/10.1111/ptr.12119)]
- 23 **Sheikh A**, Chau KY, Evans HM. Histological findings in protocol biopsies following pediatric liver transplant: Low incidence of abnormalities at 5 years. *Pediatr Transplant* 2018; **22**: e13212 [PMID: [29749699](https://pubmed.ncbi.nlm.nih.gov/29749699/) DOI: [10.1111/ptr.13212](https://doi.org/10.1111/ptr.13212)]
- 24 **Group GI**. Graft Injury Group Observing Long-term Outcome. 2015. [accessed 2019 December 1] Available from: <http://www.graftinjurygroup.org/>
- 25 **Poynard T**, Bedossa P, Opolon P. Natural history of liver fibrosis progression in patients with chronic hepatitis C. The OBSVIRC, METAVIR, CLINIVIR, and DOSVIRC groups. *Lancet* 1997; **349**: 825-832 [PMID: [9121257](https://pubmed.ncbi.nlm.nih.gov/9121257/) DOI: [10.1016/s0140-6736\(96\)07642-8](https://doi.org/10.1016/s0140-6736(96)07642-8)]
- 26 **Venturi C**, Sempoux C, Bueno J, Ferreres Pinas JC, Bourdeaux C, Abarca-Quinones J, Rahier J, Reding R. Novel histologic scoring system for long-term allograft fibrosis after liver transplantation in children. *Am J Transplant* 2012; **12**: 2986-2996 [PMID: [22882699](https://pubmed.ncbi.nlm.nih.gov/22882699/) DOI: [10.1111/j.1600-6143.2012.04210.x](https://doi.org/10.1111/j.1600-6143.2012.04210.x)]



Published By Baishideng Publishing Group Inc
7041 Koll Center Parkway, Suite 160, Pleasanton, CA 94566, USA
Telephone: +1-925-3991568
E-mail: bpgoffice@wjgnet.com
Help Desk: <http://www.f6publishing.com/helpdesk>
<http://www.wjgnet.com>

