

World Journal of *Hepatology*

World J Hepatol 2020 July 27; 12(7): 332-412



REVIEW

- 332** Oxidative stress in alcohol-related liver disease
Tan HK, Yates E, Lilly K, Dhanda AD

ORIGINAL ARTICLE

Basic Study

- 350** Ipragliflozin-induced improvement of liver steatosis in obese mice may involve sirtuin signaling
Suga T, Sato K, Ohyama T, Matsui S, Kobayashi T, Tojima H, Horiguchi N, Yamazaki Y, Kakizaki S, Nishikido A, Okamura T, Yamada M, Kitamura T, Uraoka T
- 363** Anti-inflammatory and anti-oxidant effects of aloe vera in rats with non-alcoholic steatohepatitis
Klaikaw N, Wongphoom J, Werawatganon D, Chayanupatkul M, Siriviriyakul P

Observational Study

- 378** Non-alcoholic steatohepatitis and the risk of myocardial infarction: A population-based national study
Ghoneim S, Dhorepatil A, Shah AR, Ram G, Ahmad S, Kim C, Asaad I

META-ANALYSIS

- 389** Effect of zinc treatment on clinical outcomes in patients with liver cirrhosis: A systematic review and meta-analysis
Tan HK, Streeter A, Cramp ME, Dhanda AD

CASE REPORT

- 399** Diagnosis and management of hepatic artery in-stent restenosis after liver transplantation by optical coherence tomography: A case report
Galastrri FL, Gilberto GM, Affonso BB, Valle LGM, Falsarella PM, Caixeta AM, Lima CA, Silva MJ, Pinheiro LL, Baptistella CDPA, Almeida MDD, Garcia RG, Wolosker N, Nasser F
- 406** Is right lobe liver graft without main right hepatic vein suitable for living donor liver transplantation?
Demyati K, Akbulut S, Cicek E, Dirican A, Koc C, Yilmaz S

ABOUT COVER

Editorial board member of *World Journal of Hepatology*. Koo Jeong Kang, MD, PhD, Professor, Division of HBP Surgery, Department of Surgery, Keimyung University Dong-San Hospital, Daegu, South Korea. As a hepatobiliary surgeon, he has been dedicated in hepatobiliary and pancreatic surgery including HCC, intrahepatic cholangiocarcinoma, hilar cholangiocarcinoma, cancer of gallbladder, pancreatic cancer and liver transplantation including LDLT, laparoscopic as well as open. Initially as a HBP surgeon, his research interests was hepatic ischemia/reperfusion injury to prevent hepatic injury both clinical but experimental research to establish safe liver surgeries. And he interested in the clinical significance of anatomical resection of the liver cancer, systematic segmentectomy or Glissonean pedicle approach according to the size and location of the tumor.

AIMS AND SCOPE

The primary aim of *World Journal of Hepatology* (WJH, *World J Hepatol*) is to provide scholars and readers from various fields of hepatology with a platform to publish high-quality basic and clinical research articles and communicate their research findings online.

WJH mainly publishes articles reporting research results and findings obtained in the field of hepatology and covering a wide range of topics including chronic cholestatic liver diseases, cirrhosis and its complications, clinical alcoholic liver disease, drug induced liver disease autoimmune, fatty liver disease, genetic and pediatric liver diseases, hepatocellular carcinoma, hepatic stellate cells and fibrosis, liver immunology, liver regeneration, hepatic surgery, liver transplantation, biliary tract pathophysiology, non-invasive markers of liver fibrosis, viral hepatitis.

INDEXING/ABSTRACTING

The WJH is now abstracted and indexed in PubMed, PubMed Central, Emerging Sources Citation Index (Web of Science), Scopus, China National Knowledge Infrastructure (CNKI), China Science and Technology Journal Database (CSTJ), and Superstar Journals Database.

RESPONSIBLE EDITORS FOR THIS ISSUE

Electronic Editor: *Li-Li Wang*, Production Department Director: *Yun-Xiaojuan Wu*, Editorial Office Director: *Jiu-Ping Yan*.

NAME OF JOURNAL

World Journal of Hepatology

ISSN

ISSN 1948-5182 (online)

LAUNCH DATE

October 31, 2009

FREQUENCY

Monthly

EDITORS-IN-CHIEF

Nikolaos Pylsopoulos, Ke-Qin Hu, Koo Jeong Kang

EDITORIAL BOARD MEMBERS

<https://www.wjgnet.com/1948-5182/editorialboard.htm>

PUBLICATION DATE

July 27, 2020

COPYRIGHT

© 2020 Baishideng Publishing Group Inc

INSTRUCTIONS TO AUTHORS

<https://www.wjgnet.com/bpg/gerinfo/204>

GUIDELINES FOR ETHICS DOCUMENTS

<https://www.wjgnet.com/bpg/GerInfo/287>

GUIDELINES FOR NON-NATIVE SPEAKERS OF ENGLISH

<https://www.wjgnet.com/bpg/gerinfo/240>

PUBLICATION ETHICS

<https://www.wjgnet.com/bpg/GerInfo/288>

PUBLICATION MISCONDUCT

<https://www.wjgnet.com/bpg/gerinfo/208>

ARTICLE PROCESSING CHARGE

<https://www.wjgnet.com/bpg/gerinfo/242>

STEPS FOR SUBMITTING MANUSCRIPTS

<https://www.wjgnet.com/bpg/GerInfo/239>

ONLINE SUBMISSION

<https://www.f6publishing.com>

Diagnosis and management of hepatic artery in-stent restenosis after liver transplantation by optical coherence tomography: A case report

Francisco Leonardo Galastri, Guilherme Moratti Gilberto, Breno Boueri Affonso, Leonardo Guedes Moreira Valle, Priscila Mina Falsarella, Adriano Mendes Caixeta, Camila Antunes Lima, Marcela Juliano Silva, Lucas Lembrança Pinheiro, Conrado Dias Pacheco Annicchino Baptistella, Márcio Dias de Almeida, Rodrigo Gobbo Garcia, Nelson Wolosker, Felipe Nasser

ORCID number: Francisco Leonardo Galastri 0000-0001-9599-3778; Guilherme Moratti Gilberto 0000-0002-8923-2996; Breno Boueri Affonso 0000-0002-2940-9016; Leonardo Guedes Moreira Valle 0000-0001-6255-340X; Priscila Mina Falsarella 0000-0003-3063-9174; Adriano Mendes Caixeta 0000-0002-6287-5414; Camila Antunes Lima 0000-0001-7821-6408; Marcela Juliano Silva 0000-0002-0886-8184; Lucas Lembrança Pinheiro 0000-0001-5203-9896; Conrado Dias Pacheco Annicchino Baptistella 0000-0002-1311-8492; Márcio Dias de Almeida 0000-0003-4571-961X; Rodrigo Gobbo Garcia 0000-0002-1968-9595; Nelson Wolosker 0000-0003-1991-3507; Felipe Nasser 0000-0002-3259-7142.

Author contributions: Galastri FL, Nasser F and Affonso BB were the patient's interventionists, reviewed the literature and revised the manuscript, Valle LGM and Falsarella PM reviewed the literature; Caixeta AM was the interventional cardiologist who helped perform the OCT procedure; Gilberto GM, Lima CA, Silva MJ, Pinheiro LL and Baptistella CDPA reviewed the literature, contributed to the

Francisco Leonardo Galastri, Guilherme Moratti Gilberto, Breno Boueri Affonso, Leonardo Guedes Moreira Valle, Priscila Mina Falsarella, Camila Antunes Lima, Marcela Juliano Silva, Lucas Lembrança Pinheiro, Conrado Dias Pacheco Annicchino Baptistella, Rodrigo Gobbo Garcia, Felipe Nasser, Hospital Israelita Albert Einstein, Department of Interventional Radiology, São Paulo 05652900, Brazil

Adriano Mendes Caixeta, Hospital Israelita Albert Einstein, Department of Interventional Cardiology, São Paulo 0562900, Brazil

Márcio Dias de Almeida, Hospital Israelita Albert Einstein, Department of Liver Transplant, São Paulo 05652900, Brazil

Nelson Wolosker, Hospital Israelita Albert Einstein, Department of Vascular Surgery, São Paulo 05652-000, Brazil

Corresponding author: Francisco Leonardo Galastri, MD, PhD, Doctor, Staff Physician, Department of Interventional Radiology, Hospital Israelita Albert Einstein, Avenida Albert Einstein, 627, São Paulo 05652900, Brazil. francisco.galastri2@einstein.br

Abstract

BACKGROUND

Percutaneous transluminal angioplasty and stenting represent an effective treatment for hepatic artery stenosis after liver transplantation. In the first year after stenting, approximately 22% of patients experience in-stent restenosis, increasing the risk of artery thrombosis and related complications, and 50% experience liver failure. Although angiography is an important tool for diagnosis and the planning of therapeutic interventions, it may raise doubts, especially in small-diameter arteries, and it provides low resolution rates compared with newer intravascular imaging methods, such as optical coherence tomography (OCT).

CASE SUMMARY

A 64-year-old male developed hepatic artery stenosis one year after orthotopic

manuscript, interpreted the imaging findings; Almeida MD, Garcia RG and Wolosker N were responsible for revision of the manuscript for important intellectual content; All authors issued final approval for the version to be submitted.

Informed consent statement:

Consent for publication was obtained for every individual person's data included in the study.

Conflict-of-interest statement: The authors have no conflict of interest.

CARE Checklist (2016) statement:

The authors have read the CARE Checklist (2016), and the manuscript was prepared and revised according to the CARE Checklist (2016).

Open-Access: This article is an open-access article that was selected by an in-house editor and fully peer-reviewed by external reviewers. It is distributed in accordance with the Creative Commons Attribution NonCommercial (CC BY-NC 4.0) license, which permits others to distribute, remix, adapt, build upon this work non-commercially, and license their derivative works on different terms, provided the original work is properly cited and the use is non-commercial. See: <http://creativecommons.org/licenses/by-nc/4.0/>

Manuscript source: Unsolicited manuscript

Received: January 15, 2020

Peer-review started: January 15, 2020

First decision: March 5, 2020

Revised: April 2, 2020

Accepted: May 19, 2020

Article in press: May 19, 2020

Published online: July 27, 2020

P-Reviewer: Gerber DA, Govindarajan GK, Pan GD

S-Editor: Dou Y

L-Editor: Webster JR

E-Editor: Wang LL

liver transplantation and was successfully treated with percutaneous transluminal angioplasty with stenting. Five months later, the Doppler ultrasound results indicated restenosis. Visceral arteriography confirmed hepatic artery tortuosity but was doubtful for significant in-stent restenosis (ISR) and intrahepatic flow reduction. To confirm ISR, identify the etiology and guide treatment, OCT was performed. OCT showed severe stenosis due to four mechanisms: Focal and partial stent fracture, late stent malapposition, in-stent neointimal hyperplasia, and neoatherosclerosis.

CONCLUSION

Intravascular diagnostic methods can be useful in evaluating cases in which initial angiography results are not sufficient to provide a proper diagnosis of significant stenosis, especially with regard to ISR. A wide range of diagnoses are provided by OCT, resulting in different treatment options. Interventional radiologists should consider intravascular diagnostic methods as additional tools for evaluating patients when visceral angiography results are unclear.

Key words: Liver transplantation; Hepatic artery restenosis; Tomography; Optical coherence; Case report; Endovascular procedures; Angiography

©The Author(s) 2020. Published by Baishideng Publishing Group Inc. All rights reserved.

Core tip: This is the first case report of optical coherence tomography in the evaluation of in-stent restenosis in a transplant hepatic artery. In this case, optical coherence tomography proved to be valuable in grading the significance of stenosis, identifying its possible causes, and providing measures for choosing appropriate devices for re-treatment. In this case, this additional and modern tool helped in the diagnosis and the therapeutic planning after a doubtful angiography result.

Citation: Galastrri FL, Gilberto GM, Affonso BB, Valle LGM, Falsarella PM, Caixeta AM, Lima CA, Silva MJ, Pinheiro LL, Baptistella CDPA, Almeida MD, Garcia RG, Wolosker N, Nasser F. Diagnosis and management of hepatic artery in-stent restenosis after liver transplantation by optical coherence tomography: A case report. *World J Hepatol* 2020; 12(7): 399-405

URL: <https://www.wjgnet.com/1948-5182/full/v12/i7/399.htm>

DOI: <https://dx.doi.org/10.4254/wjh.v12.i7.399>

INTRODUCTION

Hepatic artery stenosis (HAS) is one of the most common vascular complications of liver transplantation and is a leading cause of hepatic artery thrombosis and allograft dysfunction^[1]. HAS treatment consisting of percutaneous transluminal angioplasty with stenting (PTAS) has been largely adopted and proven to be effective, although it carries a risk of up to 22% for in-stent restenosis (ISR) in the first year and poses a therapeutic challenge related to the fact that up to 50% of cases result in liver failure^[2].

ISR after liver transplantation is frequently attributed to neointimal proliferation. Doppler ultrasound (DUS) is the standard method for screening diagnosis combined with laboratory abnormalities^[3]. Angiography is an important tool for confirming the diagnosis and planning optimum therapeutic intervention. However, because angiography only provides a two-dimensional view of a three-dimensional structure, it poorly estimates plaque volume, morphology and lesion severity. Moreover, angiography sometimes overestimates lumen dimensions and provides low resolution rates compared with newer intravascular imaging methods, such as intravascular ultrasound (IVUS) and optical coherence tomography (OCT), especially in small-diameter arteries^[4]. Additionally, considerable intra- and interobserver variability in the interpretation of stenosis severity has been observed with arteriography^[5].

Several factors contribute to stent failures, and OCT can assess them with great imaging quality. One of these factors is neoatherosclerosis, which is observed by OCT as the presence of clusters of lipid-laden foamy macrophages with or without necrotic core formation and/or calcification within the neointimal tissue of stented segments^[6]. Other possible findings are: Stent malapposition which is defined by the separation of



at least one stent strut from the intimal surface of the arterial wall with evidence of blood behind the strut^[7] and stent fracture which is complete separation of stent segments or separated stent struts without displacement^[8].

OCT provides the highest resolution of all invasive imaging modalities, resulting in high-quality cross-sectional tomographic images of vessel architecture, and it demonstrates superiority compared with IVUS or angiography in terms of assessing lesions, particularly identifying thrombus, plaque erosion and rupture^[9].

To our knowledge, this is the first case report of OCT used to evaluate ISR in a transplant hepatic artery. In this case, OCT proved to be valuable for grading the significance of stenosis, identifying its possible causes, and providing measures for choosing appropriate devices for retreatment.

CASE PRESENTATION

Chief complaints

A 64-year-old man developed, during clinical and ultrasound follow up, hepatic artery intra-stent restenosis.

History of present illness

The patient had a history of orthotopic liver transplantation and was successfully treated with PTAS. Five months later, the patient presented with increased alkaline phosphatase and alanine aminotransferase levels and DUS indicated restenosis.

History of past illness

The patient had alcoholic liver cirrhosis previous to liver transplantation.

Physical examination

The patient was conscious, with good general health and normal vital signs, anicteric, eupneic and without fever. The abdomen was distended without signs of ascites.

Laboratory examinations

Alkaline phosphatase level was 186 U/L and alanine aminotransferase level was 390 U/L.

Imaging examinations

DUS of the intrahepatic arteries showed a low resistance index, ranging from 0.4 to 0.5, indicating restenosis (Figure 1).

Further diagnostic work-up

Visceral arteriography confirmed the tortuosity of the hepatic artery but showed doubtful significant intrastent diameter reduction and intrahepatic flow reduction (Figure 2). Two experienced interventional radiologists disagreed on the angiography results. To confirm ISR, identify the etiology and guide treatment, OCT was performed.

OCT showed severe stenosis (vessel luminal area: 9.8 mm²/minimal luminal area: 1.7 mm²/82% of area reduction) due to four mechanisms: Focal and partial stent fracture, late stent malapposition, in-stent neointimal hyperplasia, and neoatherosclerosis (Figure 2).

FINAL DIAGNOSIS

Hepatic artery intra-stent restenosis.

TREATMENT

PTAS with a new drug-eluting stent (Sirolimus) Orsiro 3 mm × 30 mm (Biotronik) resulted in complete resolution of restenosis with improvements in intrahepatic perfusion (Figure 3).

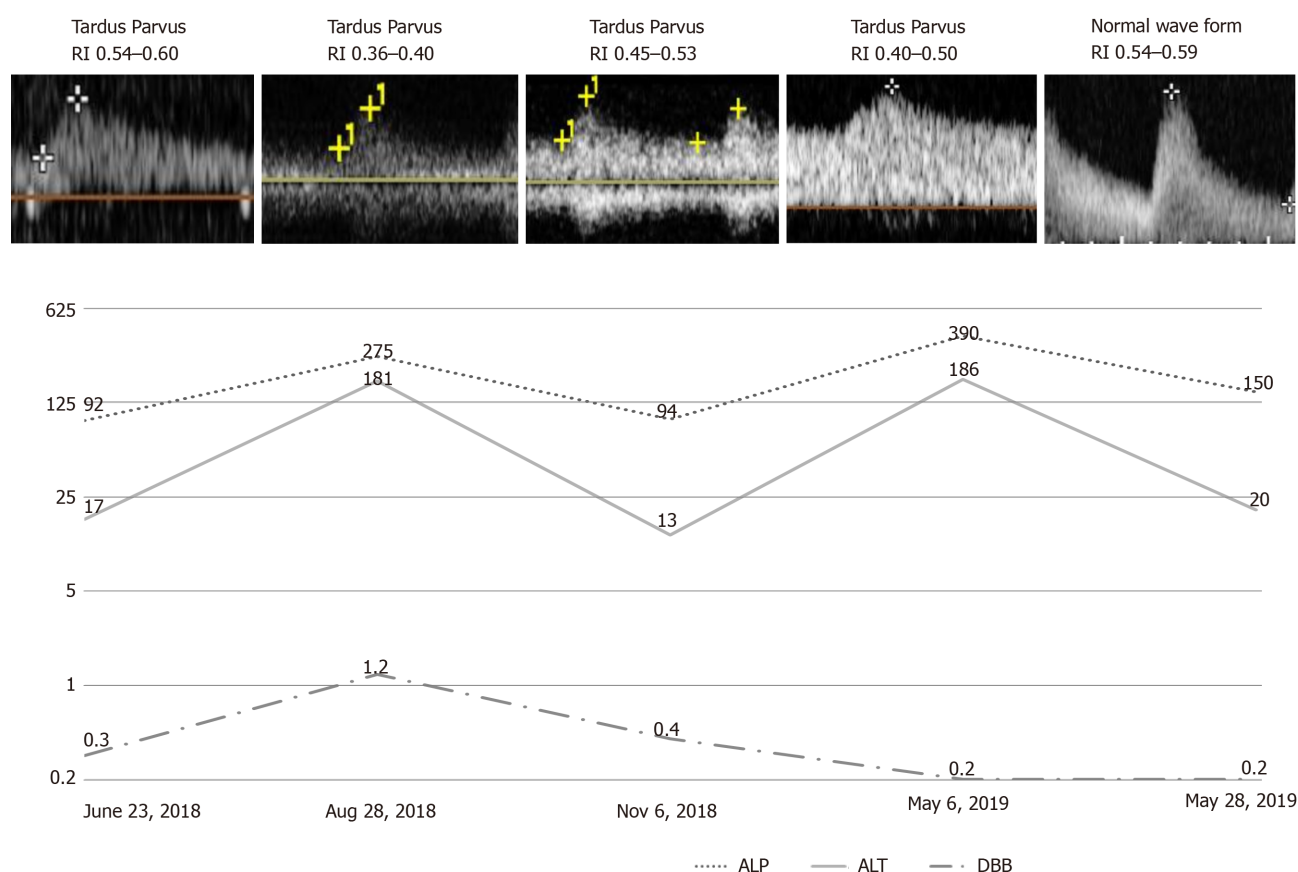


Figure 1 Graphic showing patient's serum levels of direct bilirubin (mg/dL), alkaline phosphatase (U/L) and alanine aminotransferase (U/L); Doppler wave forms and resistive index along time. DBB: Direct bilirubin; ALP: Alkaline phosphatase; ALT: Alanine aminotransferase; RI: Resistance index.

OUTCOME AND FOLLOW-UP

Twenty days later, liver enzymes were normalized, and DUS waveforms were normal for the first time after liver transplantation. The resistance index ranged from 0.54 to 0.59 (Figure 1). In a 10-mo outpatient follow-up, the patient was free from symptoms, with normal liver enzymes.

DISCUSSION

The endovascular approach has become an alternative for the treatment of HAS due to its low morbidity, high patency rates similar to those of open surgery^[10], low graft loss, and low mortality rates. Recent retrospective studies have shown that primary stenting may be the first option, with primary assisted patency rates up to 97% within 12 mo and 93% within 24 mo as well as a decrease in the need for reintervention^[3,11].

ISR and occlusion are known complications of endovascular procedures that justify clinical follow-up and DUS in these patients. The development of intravascular diagnostic methods has shown that restenosis etiologies are not as simple as they were believed to be. IVUS and OCT enable better evaluation of ISR, and they should be considered for the detection of stent-related mechanical problems leading to restenosis in patients with coronary revascularization, therefore leading to class IIA and level C recommendations^[12,13]. The wide range of differential diagnoses for ISR are due to endovascular diagnostic methods, including stent fracture, neoatherosclerosis, neointimal hyperplasia, late acquired stent malapposition, stent underexpansion, evagination, stent crush and edge dissection. Treatment options differ according to the diagnosis of ISR^[13].

In our case, the patient presented with biochemical alterations and DUS parameters that suggested new arterial stenosis and probable ISR. Angiography showed tortuosity of the treated vessel, but this tool was limited in terms of measuring intrastent luminal reduction and intrahepatic contrast enhancement. Furthermore, angiography could

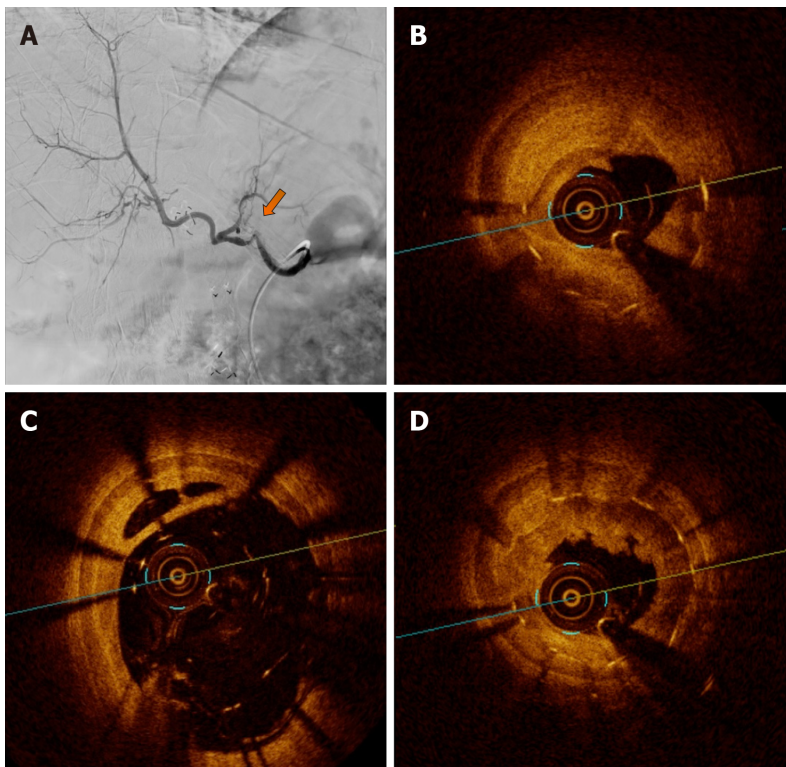


Figure 2 Visceral arteriography and optical coherence tomography. A: Visceral arteriography diagnosis with hepatic artery tortuosity and doubtful significant intra-stent diameter reduction and intrahepatic flow reduction. The yellow arrow indicates the possible stenosis area, to be confirmed further with an intravascular method; B: OCT diagnosis of severe stenosis due neointimal hyperplasia and focal and partial stent fracture; C: OCT diagnosis of stent late malapposition; D: OCT diagnosis of in-stent neointimal hyperplasia and neoatherosclerosis. OCT: Optical coherence tomography.

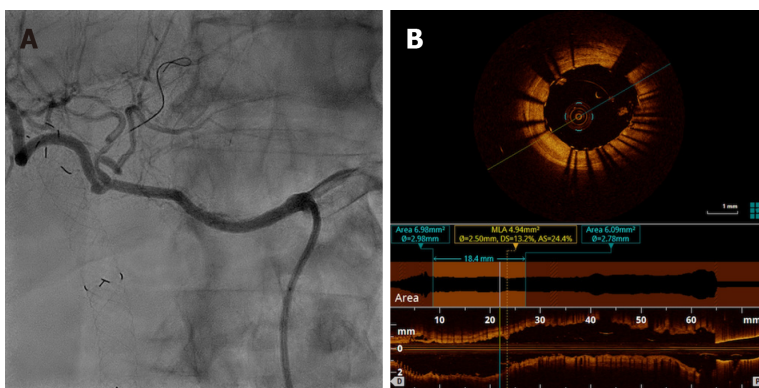


Figure 3 Visceral arteriography after percutaneous transluminal angioplasty and optical coherence tomography posttreatment. A: Visceral arteriography after percutaneous transluminal angioplasty with drug-eluting stent (Sirolimus) Orsiro 3 mm × 30 mm (Biotronik) showing complete resolution of restenosis and improvement in intrahepatic perfusion; B: Optical coherence tomography posttreatment showing acute gain in luminal area due to complete stent expansion.

not categorize the severity of the lesion, the presence of hemodynamic repercussion or the etiology of restenosis. OCT showed severe stenosis caused by stent fracture, late stent malapposition, neointimal hyperplasia and probable neoatherosclerosis tissue. These diagnoses and OCT measurements guided the treatment and stent choice.

Posttreatment angiography undoubtedly showed ISR resolution and improvements in hepatic perfusion with faster parenchymal enhancement and washout. Both interventional radiologists agreed with these findings. Similar to angiography, OCT confirmed an increased vessel area without residual stenosis and provided the finding of adequate stent apposition. DUS performed immediately postprocedure demonstrated normal intrahepatic wave forms and resistance index, and it was used as a basic follow-up test. Consistent with the results of the imaging exams, the patient progressed and demonstrated clinical and laboratory improvements.

The disagreement on the angiography evaluation by two experienced interventional radiologists and the urge to identify stent-related mechanical problems motivated the use of additional intravascular diagnostic methods. In our case, for the first time in the published medical literature, OCT has proven to be an effective additional method for elucidating doubtful lesions on visceral arteries after transplantation. Moreover, posttreatment OCT evaluation confirmed that the interventional radiologists were in agreement regarding the adequate results. Although OCT provides outstanding new information to the vascular territory, we understand that it has some limitations, such as the additional volume of contrast that is unavoidable, the imaging is not free from artifacts and it depends on the observer's experience. In addition, it has a high cost and poor availability^[14].

CONCLUSION

Angiography is the gold standard for evaluating patients with suspected restenosis; however, in some cases, this procedure can cast doubt. Intravascular diagnostic methods can be useful when evaluating such cases, especially with regard to in-stent restenosis. A wide range of diagnoses are provided by OCT, which results in different treatment options. Interventional radiologists should consider intravascular diagnostic methods as additional tools for evaluating patients when visceral angiography results are unclear.

ACKNOWLEDGEMENTS

OCT analysis assistance was by Eduardo Ufeni Sandes, BIOMED.

REFERENCES

- 1 **Rostambeigi N**, Hunter D, Duval S, Chinnakotla S, Golzarian J. Stent placement versus angioplasty for hepatic artery stenosis after liver transplant: a meta-analysis of case series. *Eur Radiol* 2013; **23**: 1323-1334 [PMID: 23239061 DOI: 10.1007/s00330-012-2730-9]
- 2 **Sugi MD**, Albadawi H, Knuttinen G, Naidu SG, Mathur AK, Moss AA, Oklu R. Transplant artery thrombosis and outcomes. *Cardiovasc Diagn Ther* 2017; **7**: S219-S227 [PMID: 29399525 DOI: 10.21037/cdt.2017.10.13]
- 3 **Pulitano C**, Joseph D, Sandroussi C, Verran D, Strasser SI, Shackel NA, McCaughan GW, Crawford M. Hepatic artery stenosis after liver transplantation: is endovascular treatment always necessary? *Liver Transpl* 2015; **21**: 162-168 [PMID: 25378262 DOI: 10.1002/lt.24043]
- 4 **Nakamura S**, Mahon DJ, Maheswaran B, Gutfinger DE, Colombo A, Tobis JM. An explanation for discrepancy between angiographic and intravascular ultrasound measurements after percutaneous transluminal coronary angioplasty. *J Am Coll Cardiol* 1995; **25**: 633-639 [PMID: 7860907 DOI: 10.1016/0735-1097(94)00453-W]
- 5 **Thomas AC**, Davies MJ, Dilly S, Dilly N, Franc F. Potential errors in the estimation of coronary arterial stenosis from clinical arteriography with reference to the shape of the coronary arterial lumen. *Br Heart J* 1986; **55**: 129-139 [PMID: 3942647 DOI: 10.1136/hrt.55.2.129]
- 6 **Hong SJ**, Lee SY, Hong MK. Clinical Implication of Optical Coherence Tomography-Based Neointimal Sclerosis. *J Korean Med Sci* 2017; **32**: 1056-1061 [PMID: 28581259 DOI: 10.3346/jkms.2017.32.7.1056]
- 7 **Karalis I**, Ahmed TA, Jukema JW. Late acquired stent malapposition: why, when and how to handle? *Heart* 2012; **98**: 1529-1536 [PMID: 23001063 DOI: 10.1136/heartjnl-2011-301220]
- 8 **Mohsen MK**, Alqahtani A, Al Suwaidi J. Stent fracture: how frequently is it recognized? *Heart Views* 2013; **14**: 72-81 [PMID: 23983912 DOI: 10.4103/1995-705X.115501]
- 9 **Hamby BA**, Ramirez DE, Loss GE, Bazan HA, Smith TA, Bluth E, Sternbergh WC 3rd. Endovascular treatment of hepatic artery stenosis after liver transplantation. *J Vasc Surg* 2013; **57**: 1067-1072 [PMID: 23332988 DOI: 10.1016/j.jvs.2012.10.086]
- 10 **Le L**, Terral W, Zea N, Bazan HA, Smith TA, Loss GE, Bluth E, Sternbergh WC 3rd. Primary stent placement for hepatic artery stenosis after liver transplantation. *J Vasc Surg* 2015; **62**: 704-709 [PMID: 26054583 DOI: 10.1016/j.jvs.2015.04.400]
- 11 **Vidjak V**, Novačić K, Matijević F, Kavur L, Slavica M, Mrzljak A, Filipec-Kanižaj T, Leder NI, Škegro D. Percutaneous Endovascular Treatment for Hepatic Artery Stenosis after Liver Transplantation: The Role of Percutaneous Endovascular Treatment. *Pol J Radiol* 2015; **80**: 309-316 [PMID: 26150902 DOI: 10.12659/PJR.893831]
- 12 **Secco GG**, Grattoni C, Parisi R, Oshoala K, Cremonesi A, Fattori R, Castriota F. Optical Coherence Tomography Guidance during Peripheral Vascular Intervention. *Cardiovasc Intervent Radiol* 2015; **38**: 768-772 [PMID: 24595662 DOI: 10.1007/s00270-014-0868-3]
- 13 **Neumann FJ**, Sousa-Uva M, Ahlsson A, Alfonso F, Banning AP, Benedetto U, Byrne RA, Collet JP, Falk V, Head SJ, Juni P, Kastrati A, Koller A, Kristensen SD, Niebauer J, Richter DJ, Seferović PM, Sibbing D,

- Stefanini GG, Windecker S, Yadav R, Zembala MO. [2018 ESC/EACTS Guidelines on myocardial revascularization]. *Kardiol Pol* 2018; **76**: 1585-1664 [PMID: [30566213](#) DOI: [10.5603/KP.2018.0228](#)]
- 14 **Roleder T**, Jąkała J, Kałuża GL, Partyka Ł, Proniewska K, Pociask E, Zasada W, Wojakowski W, Gąsior Z, Dudek D. The basics of intravascular optical coherence tomography. *Postępy Kardiol Interwencyjnej* 2015; **11**: 74-83 [PMID: [26161097](#) DOI: [10.5114/pwki.2015.52278](#)]



Published by **Baishideng Publishing Group Inc**
7041 Koll Center Parkway, Suite 160, Pleasanton, CA 94566, USA

Telephone: +1-925-3991568

E-mail: bpgoffice@wjgnet.com

Help Desk: <https://www.f6publishing.com/helpdesk>

<https://www.wjgnet.com>

