

Name of Journal: *World Journal of Gastroenterology*

Manuscript NO: 54174

Manuscript Type: MINIREVIEWS

Endoscopic ultrasound-guided injective ablative treatment of pancreatic cystic neoplasms

Du C *et al.* EUS-guided ablative treatment of pancreatic cyst

Chen Du, Ning-Li Chai, En-Qiang Linghu, Hui-Kai Li, Xiu-Xue Feng

Chen Du, Ning-Li Chai, En-Qiang Linghu, Hui-Kai Li, Xiu-Xue Feng,
Department of Gastroenterology and Hepatology, Chinese PLA General Hospital, Beijing 100853, China

Abstract

With the development of cross-sectional imaging modalities and the increasing attention being paid to physical examinations, the prevalence of pancreatic cystic neoplasms (PCNs) has increased. PCNs comprise a broad differential spectrum with some PCNs having low or no malignant potential and others have high malignant potential. The morbidity and mortality rates

Match Overview

1	Crossref 75 words Enqiang Linghu, Chen Du, Ningli Chai, Huikai Li et al. "A prospective study on the safety and effectiveness of usin	1%
2	Internet 61 words crawled on 10-Jan-2020 www.thieme-connect.com	1%
3	Crossref 28 words Hyoung-Chul Oh, Dong Wan Seo, Tae Yoon Lee, Ji Youn g Kim, Sang Soo Lee, Sung Koo Lee, Myung-Hwan Kim.	1%
4	Internet 26 words crawled on 13-Apr-2020 journals.lww.com	<1%
5	Internet 26 words crawled on 08-Apr-2018 www.wjgnet.com	<1%
6	Crossref 24 words Matthew T. Moyer, Setareh Sharzehi, Abraham Mathew, J ohn M. Levenick et al. "The Safety and Efficacy of an AI...	<1%
7	Crossref 24 words Xiang-Yao Wang, Ning-Li Chai, En-Qiang Linghu, Hui-Kai Li et al. "Efficacy and safety of hybrid endoscopic submu	<1%
8	Internet 23 words crawled on 23-Feb-2020 thieme-connect.de	<1%

Endoscopic ultrasound-guided injective ablative treati



ALL

IMAGES

VIDEOS

285,000 Results

Any time ▾

Endoscopic ultrasound-guided radiofrequency ablation (EUS-RFA) delivery can be used to **treat** both **pancreatic** cancer and asymptomatic premalignant **pancreatic neoplasms** and may serve as a less invasive alternative to surgical resection. This is an appealing option that may result in less morbidity and mortality.

Endoscopic Ultrasound-Guided Radiofrequency Ablation of ...

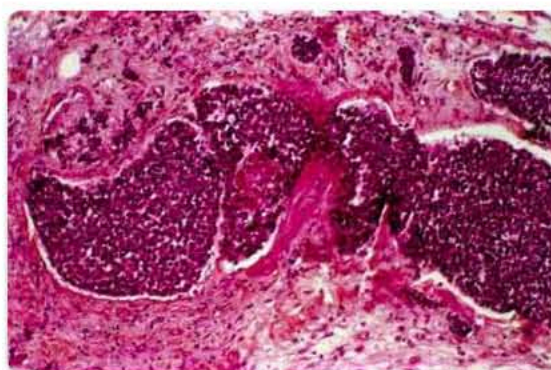
www.hindawi.com/journals/cjgh/2016/4189358/

Was this helpful?



Images of Endoscopic ultrasound-guided Injective Ablative
Treatme...

bing.com/images



Diagnosis	Pre ablation size (mm)	Post ablation size (mm)	Adv
Mucinous cyst	30	10	No
Mucinous cyst	40	Cyst not seen	No
Microcystic adenoma	20	8	No
Mucinous cyst	70	45	Mild
Mucinous cyst	24	Cyst not seen	Mild
IPMN	35	17	No
NET	15	Change in vascularity	No
NET	40	Central area of necrosis 15 mm	No

traductal papillary mucinous neoplasm; NET: Neuroe



See more images of Endoscopic ultrasound-guided Injective Ablative Treatment of Pancreatic cystic neoplasms

Endoscopic ultrasound-guided ablation of pancreatic cystic ...

<https://www.ncbi.nlm.nih.gov/pmc/articles/PMC6302202>

Dec 03, 2018 · In this manuscript we review 4 major endoscopic ultrasound-guided ablative therapies: **radiofrequency ablation**, **ethanol injection**, **chemo ablation**, and **cryoablation**. We also review the efficacy and safety of these techniques and future directions in the management



Endoscopic ultrasound-guided injective ablative treatme



ALL

IMAGES

VIDEOS

MAPS

NEWS

SHOPPING

286,000 Results

Any time ▾

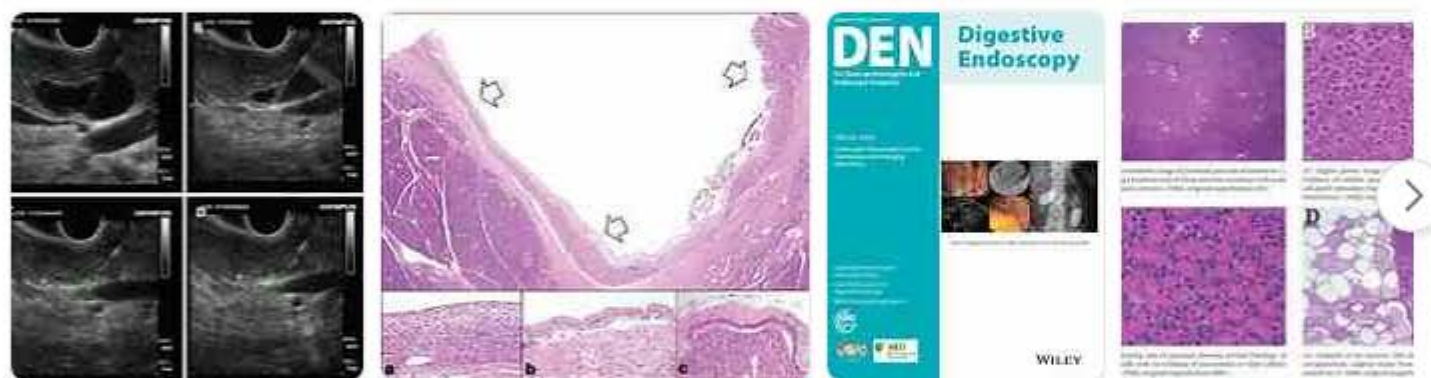Endoscopic ultrasound-guided ablation of pancreatic cystic ...

<https://www.ncbi.nlm.nih.gov/pmc/articles/PMC6302202>

Dec 03, 2018 · In this manuscript we review 4 major endoscopic ultrasound-guided ablative therapies: **radiofrequency ablation**, **ethanol injection**, **chemo ablation**, and **cryoablation**. We also review the efficacy and safety of these techniques and future directions in ...

Images of Endoscopic ultrasound-guided Injective Ablative Treatm...

[bing.com/images](https://www.bing.com/images)



See all images

Endoscopic Ultrasound-Guided Therapies in Pancreatic Neoplasms

<https://www.ncbi.nlm.nih.gov/pmc/articles/PMC4329839>

Pancreatic neuroendocrine **tumors** (pNET) account for only a small percentage (3–5%) of **pancreatic neoplasms** and, in general, carry a better prognosis than **pancreatic** adenocarcinoma . While surgical resection is the mainstay therapy, this may not be suitable for patients with metastatic disease or those with prohibitive medical comorbidities.

Cited by: 2

Author: Dennis Yang, Christopher J. DiMaio

Publish Year: 2015

Endoscopic Ultrasound–Guided Ablation of Pancreatic Cysts ...

[https://www.gastroenterologyandhepatology.net/...](https://www.gastroenterologyandhepatology.net/)

Pancreas. 2011;40(5):664–668. Oh HC, Brugge WR. **EUS**-guided **pancreatic** cyst ablation: a critical