

World Journal of *Clinical Cases*

World J Clin Cases 2020 May 26; 8(10): 1756-2065



**GUIDELINES**

- 1756** French Spine Surgery Society guidelines for management of spinal surgeries during COVID-19 pandemic
Prost S, Charles YP, Allain J, Barat JL, d'Astorg H, Delhaye M, Eap C, Zairi F, Guigui P, Ilharreborde B, Meyblum J, Le Huec JC, Lonjon N, Lot G, Hamel O, Riouallon G, Litrico S, Tropiano P, Blondel B, the French Spine Surgery Society

OPINION REVIEW

- 1763** Needs and concerns of patients in isolation care units - learnings from COVID-19: A reflection
Fan PEM, Aloweni F, Lim SH, Ang SY, Perera K, Quek AH, Quek HKS, Ayre TC

REVIEW

- 1767** Prophylactic and therapeutic roles of oleanolic acid and its derivatives in several diseases
Sen A
- 1793** Macrophage regulation of graft-vs-host disease
Hong YQ, Wan B, Li XF

MINIREVIEWS

- 1806** Antiphospholipid syndrome and its role in pediatric cerebrovascular diseases: A literature review
Sarecka-Hujar B, Kopyta I
- 1818** Remotely monitored telerehabilitation for cardiac patients: A review of the current situation
Batalik L, Filakova K, Batalikova K, Dosbaba F
- 1832** Keystone design perforator island flap in facial defect reconstruction
Lim SY, Yoon CS, Lee HG, Kim KN

ORIGINAL ARTICLE**Clinical and Translational Research**

- 1848** Cross electro-nape-acupuncture ameliorates cerebral hemorrhage-induced brain damage by inhibiting necroptosis
Cai GF, Sun ZR, Zhuang Z, Zhou HC, Gao S, Liu K, Shang LL, Jia KP, Wang XZ, Zhao H, Cai GL, Song WL, Xu SN

Retrospective Study

- 1859** Evaluation of ischemic lesions after carotid artery stenting with diffusion-weighted imaging
Beyhan M, Acu B, Gökçe E, Fırat MM
- 1871** Transjugular intrahepatic portosystemic shunt and splenectomy are more effective than endoscopic therapy for recurrent variceal bleeding in patients with idiopathic noncirrhotic portal hypertension
He FL, Qi RZ, Zhang YN, Zhang K, Zhu-Ge YZ, Wang M, Wang Y, Jia JD, Liu FQ

- 1878** Liglipatin for treatment of type 2 diabetes mellitus with early renal injury: Efficacy and impact on endogenous hydrogen sulfide and endothelial function
Zhang J, Du YL, Zhang H, Sui H, Hou WK
- 1887** Outcomes of patients with pelvic leiomyosarcoma treated by surgery and relevant auxiliary diagnosis
Sun Q, Yang X, Zeng Z, Wei X, Li KZ, Xu XY
- 1897** Defecation function and quality of life in patients with slow-transit constipation after colectomy
Tian Y, Wang L, Ye JW, Zhang Y, Zheng HC, Shen HD, Li F, Liu BH, Tong WD
- 1908** Risk factors, incidence, and morbidity associated with antibiotic-associated diarrhea in intensive care unit patients receiving antibiotic monotherapy
Zhou H, Xu Q, Liu Y, Guo LT
- Observational Study**
- 1916** Serum von Willebrand factor for early diagnosis of lung adenocarcinoma in patients with type 2 diabetes mellitus
Zhou YY, Du X, Tang JL, Wang QP, Chen K, Shi BM
- 1923** Four-microRNA signature for detection of type 2 diabetes
Yan LN, Zhang X, Xu F, Fan YY, Ge B, Guo H, Li ZL

CASE REPORT

- 1932** Isolated colonic neurofibroma, a rare tumor: A case report and review of literature
Ghoneim S, Sandhu S, Sandhu D
- 1939** Helmet-based noninvasive ventilation for acute exacerbation of chronic obstructive pulmonary disease: A case report
Park MH, Kim MJ, Kim AJ, Lee MJ, Kim JS
- 1944** Appendectomy in patient with suspected COVID-19 with negative COVID-19 results: A case report
Kim C, Kim JK, Yeo IH, Choe JY, Lee JE, Kang SJ, Park CS, Kwon KT, Hwang S
- 1950** T4 cervical esophageal cancer cured with modern chemoradiotherapy: A case report
Lee CC, Yeo CM, Ng WK, Verma A, Tey JC
- 1958** Lumbar disc rehydration in the bridged segment using the BioFlex dynamic stabilization system: A case report and literature review
Li YC, Feng XF, Pang XD, Tan J, Peng BG
- 1966** Traditional investigation and management for recurrent hemarthrosis after total knee arthroplasty: A case report
Geng X, Li Y, He X, Tian H

- 1973** Positron emission tomography/computed tomography findings of multiple cystic lymphangiomas in an adult: A case report
Sun MM, Shen J
- 1979** Heterotopic pancreas adenocarcinoma in the stomach: A case report and literature review
Xiong Y, Yue X, Jin DD, Wang XY
- 1988** Early-onset refractory diarrhea due to immune dysregulation, polyendocrinopathy, enteropathy, X-linked syndrome associated with a novel mutation in the *FOXP3* gene: A case report
Su N, Chen C, Zhou X, Ma GD, Chen RL, Tian C
- 1995** Tuberous sclerosis complex presenting as primary intestinal lymphangiectasia: A case report
Lin WH, Zhang ZH, Wang HL, Ren L, Geng LL
- 2001** Gilbert's syndrome coexisting with hereditary spherocytosis might not be rare: Six case reports
Kang LL, Liu ZL, Zhang HD
- 2009** Effective combined therapy for pulmonary epithelioid hemangioendothelioma: A case report
Zhang XQ, Chen H, Song S, Qin Y, Cai LM, Zhang F
- 2016** Unexplained huge liver infarction presenting as a tumor with bleeding: A case report
Wang FH, Yang NN, Liu F, Tian H
- 2023** Rare recurrent gallstone ileus: A case report
Jiang H, Jin C, Mo JG, Wang LZ, Ma L, Wang KP
- 2028** Treating severe periodontitis with staged load applied implant restoration: A case report
Wang SH, Ni WC, Wang RF
- 2038** Cryptococcal pneumonia in a human immunodeficiency virus-negative patient: A case report
Jiang XQ, Zhang YB
- 2044** Ileocecal intussusception caused by two different tumors - which is the culprit lesion? A case report
Fan WF, Ma G, Li GC, Long J, Xu YH, Guo KJ, Liu Z
- 2050** Robot-assisted retroperitoneal laparoscopic excision of perirenal vascular tumor: A case report
Zhang C, Fu B, Xu S, Zhou XC, Cheng XF, Fu WQ, Wang GX
- 2056** Successful use of plasma exchange in fulminant lupus myocarditis coexisting with pneumonia: A case report
Xing ZX, Yu K, Yang H, Liu GY, Chen N, Wang Y, Chen M

ABOUT COVER

Editorial Board Member of *World Journal of Clinical Cases*, Preet M Chaudhary, MD, PhD, Professor, Department of Medicine, Jane Anne Nohl Division of Hematology and Center for the Study of Blood Diseases, University of Southern California, Los Angeles, CA 90033, United States

AIMS AND SCOPE

The primary aim of *World Journal of Clinical Cases* (WJCC, *World J Clin Cases*) is to provide scholars and readers from various fields of clinical medicine with a platform to publish high-quality clinical research articles and communicate their research findings online.

WJCC mainly publishes articles reporting research results and findings obtained in the field of clinical medicine and covering a wide range of topics, including case control studies, retrospective cohort studies, retrospective studies, clinical trials studies, observational studies, prospective studies, randomized controlled trials, randomized clinical trials, systematic reviews, meta-analysis, and case reports.

INDEXING/ABSTRACTING

The WJCC is now indexed in PubMed, PubMed Central, Science Citation Index Expanded (also known as SciSearch®), and Journal Citation Reports/Science Edition. The 2019 Edition of Journal Citation Reports cites the 2018 impact factor for WJCC as 1.153 (5-year impact factor: N/A), ranking WJCC as 99 among 160 journals in Medicine, General and Internal (quartile in category Q3).

RESPONSIBLE EDITORS FOR THIS ISSUE

Responsible Electronic Editor: Ji-Hong Liu

Proofing Production Department Director: Xiang Li

Responsible Editorial Office Director: Jin-Lai Wang

NAME OF JOURNAL

World Journal of Clinical Cases

ISSN

ISSN 2307-8960 (online)

LAUNCH DATE

April 16, 2013

FREQUENCY

Semimonthly

EDITORS-IN-CHIEF

Dennis A Bloomfield, Bao-Gan Peng, Sandro Vento

EDITORIAL BOARD MEMBERS

<https://www.wjgnet.com/2307-8960/editorialboard.htm>

PUBLICATION DATE

May 26, 2020

COPYRIGHT

© 2020 Baishideng Publishing Group Inc

INSTRUCTIONS TO AUTHORS

<https://www.wjgnet.com/bpg/gerinfo/204>

GUIDELINES FOR ETHICS DOCUMENTS

<https://www.wjgnet.com/bpg/GerInfo/287>

GUIDELINES FOR NON-NATIVE SPEAKERS OF ENGLISH

<https://www.wjgnet.com/bpg/gerinfo/240>

PUBLICATION ETHICS

<https://www.wjgnet.com/bpg/GerInfo/288>

PUBLICATION MISCONDUCT

<https://www.wjgnet.com/bpg/gerinfo/208>

ARTICLE PROCESSING CHARGE

<https://www.wjgnet.com/bpg/gerinfo/242>

STEPS FOR SUBMITTING MANUSCRIPTS

<https://www.wjgnet.com/bpg/GerInfo/239>

ONLINE SUBMISSION

<https://www.f6publishing.com>

Isolated colonic neurofibroma, a rare tumor: A case report and review of literature

Sara Ghoneim, Sonia Sandhu, Dalbir Sandhu

ORCID number: Sara Ghoneim (0000-0003-4548-6318); Sonia Sandhu (0000-0001-8077-2657); Dalbir Sandhu (0000-0002-8473-5148).

Author contributions: Ghoneim S, Sandhu S and Dalbir S wrote the manuscript and reviewed the literature; Ghoneim S is the article guarantor; all authors edited and revised the manuscript.

Informed consent statement: The patient provided informed consent for the publication of his case.

Conflict-of-interest statement: All authors have no conflict of interest.

CARE Checklist (2016) statement: The authors have read the CARE checklist (2016), and the manuscript was prepared and revised according to the CARE checklist (2016).

Open-Access: This article is an open-access article that was selected by an in-house editor and fully peer-reviewed by external reviewers. It is distributed in accordance with the Creative Commons Attribution NonCommercial (CC BY-NC 4.0) license, which permits others to distribute, remix, adapt, build upon this work non-commercially, and license their derivative works on different terms, provided the original work is properly cited and the use is non-commercial. See: <http://creativecommons.org/licenses/by-nc/4.0/>

Manuscript source: Unsolicited manuscript

Sara Ghoneim, Department of Internal Medicine, Case Western Reserve University at MetroHealth Medical Center, Cleveland, OH 44109, United States

Sonia Sandhu, Department of Hematology and Oncology, Cleveland Clinic Akron General, Cleveland, OH 44307, United States

Dalbir Sandhu, Division of Gastroenterology, Case Western Reserve University at MetroHealth Medical Center, Cleveland, OH 44109, United States

Corresponding author: Sara Ghoneim, MD, Doctor, Department of Internal Medicine, Case Western Reserve University at MetroHealth Medical Center, 2500 MetroHealth Drive, Cleveland, OH 44109, United States. saragho@gmail.com

Abstract

BACKGROUND

Neurofibromas are tumors comprised of peripheral nerve sheath and connective tissue components. They can occur sporadically or as part of familial syndromes such as neurofibromatosis type 1. Isolated colonic neurofibroma without systemic manifestations is a rarely reported clinical entity. Here we present a case of a 51 years old male with an isolated colonic neurofibroma seen on a screening colonoscopy.

CASE SUMMARY

Fifty-one years old male who was otherwise healthy without a significant family history of cancer underwent a screening colonoscopy and was found have a 2.3 cm × 1.4 cm lesion in the colon. Tissue biopsy revealed a spindle cell tumor. Magnetic resonance imaging of the pelvis was negative for adenopathy. He underwent an endoscopic ultrasound that showed an ill-defined avascular lesion of mixed echogenicity measuring 2.8 cm × 15.2 cm in the submucosa with no communication with muscularis mucosa or propria. Immunohistochemistry staining of the tumor was strongly positive for S100, with rare penetrating axons deep within the tumor. Tumor cells were negative for c-kit and desmin and had low Ki-67 index. These findings were consistent with a solitary colonic submucosal neurofibroma. A detailed history and physical examination did not reveal any evidence of extraintestinal neurofibromatosis. He underwent transanal surgical resection of the tumor. The patient tolerated the procedure well without any complications.

CONCLUSION

While neurofibromas have been well described in literature, an isolated colonic neurofibroma is a rare pathological entity. Malignant transformation of

Received: January 31, 2020**Peer-review started:** January 31, 2020**First decision:** April 8, 2020**Revised:** April 24, 2020**Accepted:** April 27, 2020**Article in press:** April 27, 2020**Published online:** May 26, 2020**P-Reviewer:** Cuocolo R, de Melo FF, El-Razek AA**S-Editor:** Tang JZ**L-Editor:** A**E-Editor:** Li X

neurofibromas has been reported in patients with neurofibromatosis syndromes. We report a case of isolated colonic neurofibroma and highlight the importance of resection due to the increased risk of tumorigenesis.

Key words: Neurofibroma; Colonoscopy; Neurofibromatosis type 1; Neurofibromatosis type 2; Spindle cell tumor; Endoscopic ultrasound; Case report

©The Author(s) 2020. Published by Baishideng Publishing Group Inc. All rights reserved.

Core tip: Neurofibromas are composed of neural and connective tissue components. They are associated with hereditary syndromes such as neurofibromatosis type 1 and 2. They have systemic manifestations and may involve multiple organs. Malignant transformation of this tumor has been reported in literature. Isolated colonic neurofibroma is a rarely reported pathological entity. Clinical follow-up after surgical resection is recommended as solitary colonic neurofibromas might be the first sign of neurofibromatosis type 1.

Citation: Ghoneim S, Sandhu S, Sandhu D. Isolated colonic neurofibroma, a rare tumor: A case report and review of literature. *World J Clin Cases* 2020; 8(10): 1932-1938

URL: <https://www.wjnet.com/2307-8960/full/v8/i10/1932.htm>

DOI: <https://dx.doi.org/10.12998/wjcc.v8.i10.1932>

INTRODUCTION

Neurofibromas are peripheral nerve sheath tumors that consist of Schwann cells, perineural cells and myofibroblasts^[1-3]. They occur sporadically or as part of familial syndromes such as neurofibromatosis type 1 (NF1) (von Recklinghausen's disease), NF2 (central or bilateral neurofibromatosis), multiple endocrine neoplasia type IIb, or intestinal neurofibromatosis^[2]. NF1 and 2 are both autosomal dominant syndromes with variable clinical manifestations^[1-3]. The genes for NF1 and NF2 are found on chromosomes 17 and 22, respectively^[3]. Both genes encode tumor suppressor proteins. NF1 has no sex predilection and occurs with a prevalence of 1 in every 3000 individuals^[3,4]. About 50% of patients have a positive family history. In the remaining 50% of patients, the disorder represents a sporadic new mutation^[3,4]. The diagnosis of NF1 is largely based on clinical criteria established by the National Institutes of Health and involves the presence of two or more of the following features: Six or more café au lait patches, two or more neurofibromas, one plexiform neurofibroma, freckling in the axillary or groin region, Lisch nodules, optic glioma, a first degree relative with NF1 and/or the presence of osseous dysplasia^[3].

Gastrointestinal involvement is seen in NF1 but not NF2^[4]. Abdominal neoplasms in NF1 can be divided into five categories: Neurogenic tumors, neuroendocrine tumors, gastrointestinal mesenchymal tumors, embryonal tumors and miscellaneous tumors. Neurogenic neoplasms seen in the abdomen include neurofibroma, plexiform neurofibroma, malignant sheath peripheral nerve sheath tumor, triton tumor and ganglioneuroma^[3-4]. Sporadic intestinal neurofibromas mainly arise in the small or large intestine and affect middle age adults^[5]. In the gastrointestinal tract, neurofibromas have been reported in the following order of decreasing frequency: the jejunum, stomach, ileum, duodenum and colon^[3-7]. Isolated colonic neurofibromas are rare with a few cases reported in literature (Table 1)^[8-23]. Here we present a case of an isolated colonic neurofibroma seen on a routine screening colonoscopy.

CASE PRESENTATION

Chief complaints

A 51-year-old Caucasian male was referred to our gastroenterology clinic for a routine screening colonoscopy. He had no complaints.

History of present illness

He was otherwise healthy and denied having bloody stools, fevers, chills or unintentional weight loss.

Table 1 Case reports of isolated colonic neurofibromas reported in English clinical literature

Ref.	Age	Sex	Location
Keith <i>et al</i> ^[8] , 1937	50	Female	Rectum
Woolf <i>et al</i> ^[9] , 1938	70	Male	Rectum
Butler and Hanna ^[10] , 1959	45	Female	Rectum
Suzuki and Yamashita ^[11] , 1966	NA	NA	Rectum
Geboes <i>et al</i> ^[12] , 1978	NA	NA	Rectum
Abramsone <i>et al</i> ^[13] , 1997	53	Male	Transverse colon
Bononi <i>et al</i> ^[14] , 2000	68	Female	Diffuse involvement
Panteris <i>et al</i> ^[15] , 2005	65	Female	Descending colon
Carter and Laurini ^[16] , 2008	52	Female	Rectum, transverse colon
Hindy <i>et al</i> ^[17] , 2012	59	Male	Transverse colon
Chelimilla <i>et al</i> ^[18] , 2013	70	Female	Ascending colon
Ahn <i>et al</i> ^[19] , 2016	26	Female	Sigmoid colon
Bilal <i>et al</i> ^[20] , 2016	52	Male	Descending colon
Adiou <i>et al</i> ^[21] , 2018	29	Female	Sigmoid colon
Miao <i>et al</i> ^[22] , 2018	24	Female	Ileocecal valve
Sun <i>et al</i> ^[23] , 2020	33	Female	Ascending colon

NA: Not applicable.

History of past illness

He had no significant past medical history or surgical history and was not taking any medications.

Personal and family history

Father had a history of hypertension. No family member had a history of cancer.

Physical examination upon admission

Temperature was 37 °C, heart rate was 75 beats per minute, respiratory rate was 18 breaths per minute, blood pressure was 129/72 mmHg and body mass index was 23.4 kg/m². Physical examination was normal. His abdomen was soft with no tenderness or palpable masses. He had no skin lesions, pigmented or hypopigmented spots.

Laboratory examinations

Laboratory testing including complete blood count, basic metabolic panel, liver function tests and coagulation profile were all within normal limits. Hepatic serology was also negative.

Imaging examinations

He underwent a screening colonoscopy and was found to have a 3-cm submucosal pedunculated polyp about 15 cm from anal verge adjacent to the second rectal fold (Figure 1). Mucosal biopsies were obtained during the procedure. The specimen included fragments of colonic mucosa and a spindle cell tumor. As the mucosal specimens were unrevealing, the patient underwent magnetic resonance imaging of the pelvis which showed a 2.3 cm × 1.4 cm lesion in the submucosa with no adenopathy. A subsequent endoscopic ultrasound revealed an ill-defined avascular lesion of mixed echogenicity measuring 2.8 cm × 15.2 cm in the submucosa with no communication with muscularis mucosa or propria (Figure 2). Fine needle biopsy, with 19G SharkCore™ needle (Covidien), was obtained for pathology assessment (Figures 2 and 3). The tumor showed bland spindle cell proliferation in a uniform fascicular pattern with edematous stroma (Figure 3). The cells were elongated, with oval/wavy nuclei. No mitotic figures, necrosis, or tumoral hemorrhage were seen. The tumor showed strong and diffuse S100 staining, with rare penetrating axons deep within the tumor (Figure 4). Tumor cells were negative for c-kit, desmin and had low Ki-67 index.

FINAL DIAGNOSIS

These findings were consistent with a colonic submucosal neurofibroma. A detailed

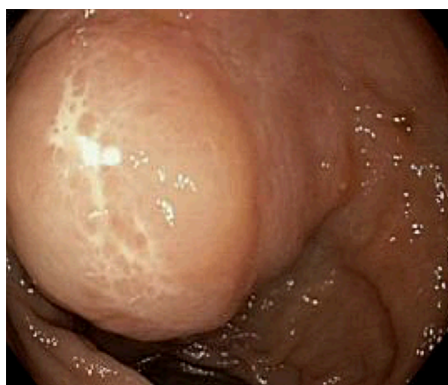

Figure 1 Findings at colonoscopy. A 3 cm submucosal pedunculated polyp is seen about 15 cm from anal verge.

history and physical examination did not reveal any evidence of extraintestinal manifestations.

TREATMENT

Our patient opted for transanal surgical resection.

OUTCOME AND FOLLOW-UP

The patient tolerated the procedure well without any complications. He will undergo a repeat colonoscopy in one year to evaluate for recurrence.

DISCUSSION

Our patient was diagnosed with a localized colonic neurofibroma without any clinical signs of NF1. The presence of such lesions in the intestinal tract without associated systemic manifestations is a rare finding.

Gastrointestinal involvement in NF1 has been reported in up to 25% of cases, with most lesions localizing to the upper gastrointestinal tract and rarely to the lower intestinal tract^[24,25]. The pathological forms seen in the gastrointestinal tract of patients with NF1 are characterized by hyperplasia and hypertrophy of the nerve plexus and ganglionic cells in the mucosa, submucosa, muscularis propria or even serosa^[20,26]. In addition to neurogenic tumors, patients may develop neuroendocrine and mesenchymal tumors such as gangliocytic paragangliomas, pheochromocytomas and gastrointestinal stromal tumors (GIST)^[2-4]. Intestinal neurofibromas predominately originate from the plexus of Meissner in the submucosa or the plexus of Auerbach^[9]. Dense growths known as plexiform neurofibromatosis may infiltrate the mesentery and lead to arterial compression or nerve injury^[25]. Endoscopically, neurofibromas are often sessile and wide-based or, as seen in this patient, pedunculated polyps^[23]. Clinically patients may present with abdominal pain, palpable masses, rectal bleeding, or obstruction due to intussusception or extra-luminal pressure, although most cases are found incidentally in asymptomatic patients.

Since there is no recommendation about modalities to explore these patients and because of the nonspecific clinical presentation of gastrointestinal lesion manifestations and limitations of endoscopic techniques, cross-sectional imaging may be used to aid in diagnosis. MR enterography is a non-invasive technique that has high sensitivity for detecting small bowel lesions and is more preferable than computed topography (CT) enterography for follow up of these patients because of concerns over exposure to ionizing radiation^[24]. CT colonography (virtual colonoscopy) is a potential alternative to conventional colonoscopy for the detection of colorectal tumors especially in poor risk patients^[27]. It is a non-invasive technique that requires no sedation and is well tolerated by most patients. CT colonography allows for complete visualization of the entire large bowel in almost all patients even following incomplete endoscopy and for colorectal examination proximal to an obstructing lesion. The use of multidetector technology improves the detection of many colorectal lesions^[27]. Potential limitations of this modality include the inability to

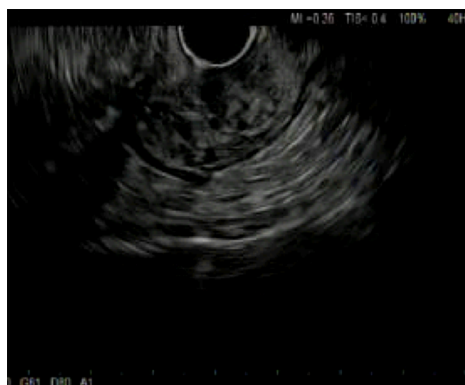

Figure 2 Findings with endoscopic ultrasound. A 2.8 cm × 15.2 cm avascular lesion of mixed echogenicity seen in the submucosa with no communication with muscularis mucosa or propria.

obtain tissue biopsy and exposure to ionizing radiation^[27,28].

Tissue biopsy remains the gold standard for diagnosis^[26]. The differential diagnosis for neurofibroma of the abdomen includes schwannoma, myxoma, inflammatory fibroid polyp and GIST^[2,25]. Unlike myxomas, neurofibromas are diffusely positive for S-100^[2]. The absence of calretinin and a peripheral lymphoid cuff help distinguish these tumors from schwannomas and inflammatory fibroid polyps, respectively. In contrast to schwannomas, neurofibromas stain positively for CD34 and factor XIIIa^[2]. On the other hand, GIST stain positive for c-kit while neurofibromas do not^[2]. In our patient, histopathology revealed bland spindle cell proliferation in a fascicular pattern. Immunohistochemical staining was positive for S100, negative for c-kit and desmin. These features are consistent with a diagnosis of neurofibroma.

Malignant transformation of neurofibromas has been reported in patients with NF1^[3,27]. Malignant peripheral nerve sheath tumors are highly aggressive tumors associated with low survival rates (34%-52%)^[29-31]. The lifetime risk of these tumors in patients with NF1 is 8%-13%^[3]. Plexiform and larger neurofibromas are more likely to undergo malignant transformation^[30-32]. Malignant sheath peripheral nerve sheath tumors are often clinically silent when they arise in the abdomen and are often diagnosed at advanced stage. The prognosis remains poor and depends on the tumor size and location, resection margins, adjuvant chemotherapy, distant metastasis, stage and site^[29-32].

The clinical significance of solitary neurofibromas is currently unknown, hence a thorough search should be made to exclude the possibility of colonic neurofibromas presenting as initial sign of NF1. Unfortunately, due to the rarity of this condition there is no consensus regarding management of these patients. Given the low incidence, and very few cases reported, long term follow up and screening goals are also unknown but close follow up is recommended to exclude neurofibromatosis and the associated risk of malignant transformation^[29-32].

CONCLUSION

An isolated colonic neurofibroma without associated signs of neurofibromatosis or systemic disease is a rare pathological finding. The clinical significance lies in the need to follow these patients as bowel involvement might be the first systemic manifestation of syndromic diseases such as NF1.

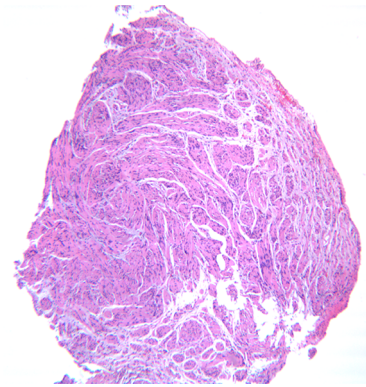


Figure 3 Histopathology of the tumor at low power $\times 10$ magnification. Bland spindle cell tumor is seen in a fascicular growth pattern.

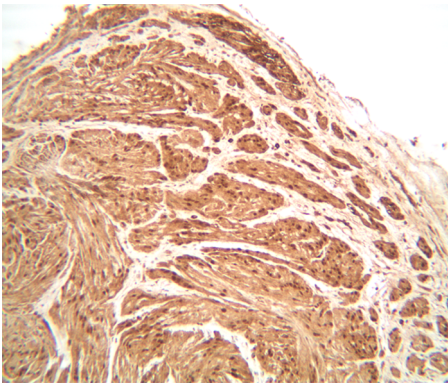


Figure 4 Immunohistochemistry of the lesion at $\times 50$ magnification. Tumor is diffusely positive for S100. Note the penetrating axons with neurofilament stain.

ACKNOWLEDGEMENTS

We would like to thank Dr. Dan X Cai for providing the pathology slides.

REFERENCES

- 1 Jett K, Friedman JM. Clinical and genetic aspects of neurofibromatosis 1. *Genet Med* 2010; **12**: 1-11 [PMID: 20027112 DOI: 10.1097/GIM.0b013e3181bf15e3]
- 2 Hechtman JF, Harpaz N. Neurogenic polyps of the gastrointestinal tract: a clinicopathologic review with emphasis on differential diagnosis and syndromic associations. *Arch Pathol Lab Med* 2015; **139**: 133-139 [PMID: 25549149 DOI: 10.5858/arpa.2013-0431-RS]
- 3 Razeq AAKA. MR imaging of neoplastic and non-neoplastic lesions of the brain and spine in neurofibromatosis type I. *Neurol Sci* 2018; **39**: 821-827 [PMID: 29455398 DOI: 10.1007/s10072-018-3284-7]
- 4 Levy AD, Patel N, Dow N, Abbott RM, Miettinen M, Sobin LH. From the archives of the AFIP: abdominal neoplasms in patients with neurofibromatosis type 1: radiologic-pathologic correlation. *Radiographics* 2005; **25**: 455-480 [PMID: 15798063 DOI: 10.1148/rq.252045176]
- 5 Mann NS, Mann SK, Alam I. The safety of hot biopsy forceps in the removal of small colonic polyps. *Digestion* 1999; **60**: 74-76 [PMID: 9892802 DOI: 10.1159/000007592]
- 6 Pinski I, Dukhno O, Ovnat A, Levy I. Gastrointestinal complications of von Recklinghausen's disease: two case reports and a review of the literature. *Scand J Gastroenterol* 2003; **38**: 1275-1278 [PMID: 14750649 DOI: 10.1080/00365520310005712]
- 7 Parmar ZB, Chudasama B, Rajpura H, Desai S, Nilkanth R, Jetly D. The isolated rectal neurofibroma: a rare case report. *OMCIS J Radiol* 2016; **5**: 3 [DOI: 10.4172/2167-7964.1000238]
- 8 Keith AR. A case of neurofibromatosis of the rectal wall. *Trans Am Protoc Soc* 1937; **38**: 68
- 9 Woolf MS. Neurofibroma of the Rectum. *Cal West Med* 1938; **49**: 463-464 [PMID: 18744831]
- 10 Butler DB, Hanna E. Neurogenic tumor of the rectum. *Dis Colon Rectum* 1959; **2**: 291-293 [PMID: 13663747 DOI: 10.1007/bf02616893]
- 11 Suzuki H, Yamashita E. A case report of intestinal neurofibroma. *Nihon Geka Hokan* 1966; **35**: 948-950 [PMID: 4962547]
- 12 Geboes K, De Wolf-Peeters C, Rutgeerts P, Vantrappen G, Desmet V. Submucosal tumors of the colon: experience with twenty-five cases. *Dis Colon Rectum* 1978; **21**: 420-425 [PMID: 212258 DOI: 10.1007/bf02586719]
- 13 Abramson LP, Orkin BA, Schwartz AM. Isolated colonic neurofibroma manifested by massive lower

- gastrointestinal bleeding and intussusception. *South Med J* 1997; **90**: 952-954 [PMID: [9305312](#) DOI: [10.1097/00007611-199709000-00020](#)]
- 14 **Bononi M**, De Cesare A, Stella MC, Fiori E, Galati G, Atella F, Angelini M, Cimitan A, Lemos A, Cangemi V. Isolated intestinal neurofibromatosis of colon. Single case report and review of the literature. *Dig Liver Dis* 2000; **32**: 737-742 [PMID: [11142587](#) DOI: [10.1016/s1590-8658\(00\)80340-0](#)]
- 15 **Panteris V**, Vassilakaki T, Vaitis N, Elemenoglou I, Mylonakou I, Karamanolis DG. Solitary colonic neurofibroma in a patient with transient segmental colitis: case report. *World J Gastroenterol* 2005; **11**: 5573-5576 [PMID: [16222760](#) DOI: [10.3748/wjg.v11.i35.5573](#)]
- 16 **Carter JE**, Laurini JA. Isolated intestinal neurofibromatous proliferations in the absence of associated systemic syndromes. *World J Gastroenterol* 2008; **14**: 6569-6571 [PMID: [19030214](#) DOI: [10.3748/wjg.14.6569](#)]
- 17 **Hindy P**, Parvin R, Hanna K, Andrawes S, Gress F, Goodman A. An isolated neurofibromal polyp of the colon. *Case Rep Gastroenterol* 2012; **6**: 58-62 [PMID: [22423240](#) DOI: [10.1159/000336214](#)]
- 18 **Chelimilla H**, Chandrala CK, Niazi M, Kumbum K. Incidental finding of isolated colonic neurofibroma. *Case Rep Gastroenterol* 2013; **7**: 369-375 [PMID: [24163647](#) DOI: [10.1159/000355163](#)]
- 19 **Ahn S**, Chung CS, Kim KM. Neurofibroma of the Colon: A Diagnostic Mimicker of Gastrointestinal Stromal Tumor. *Case Rep Gastroenterol* 2016; **10**: 674-678 [PMID: [27920660](#) DOI: [10.1159/000452202](#)]
- 20 **Bilal M**, Bilimoria F, Clarke K. An isolated colonic neurofibroma. *Ann Gastroenterol* 2016; **29**: 381 [PMID: [27366045](#) DOI: [10.20524/aog.2016.0029](#)]
- 21 **Adioui T**, Tamzaourte M, Nejari F, Chakkor A, Elkaoui H, Boudhas A, Oukabli M, Rouibaa F, Aourarh A, Zentar A. Isolated Neurofibroma of the Sigmoid Colon: a Case Report and Review of the Literature. *J Gastrointest Cancer* 2018; **49**: 195-199 [PMID: [27577727](#) DOI: [10.1007/s12029-016-9864-y](#)]
- 22 **Miao Y**, Wang JJ, Chen ZM, Zhu JL, Wang MB, Cai SQ. Neurofibroma discharged from the anus with stool: A case report and review of literature. *World J Clin Cases* 2018; **6**: 455-458 [PMID: [30294610](#) DOI: [10.12998/wjcc.v6.i11.455](#)]
- 23 **Sun WY**, Pandey A, Lee M, Wasilenko S, Karmali S. Isolated colonic neurofibroma in the setting of Lynch syndrome: A case report and review of literature. *World J Gastrointest Surg* 2020; **12**: 28-33 [PMID: [31984122](#) DOI: [10.4240/wjgs.v12.i1.28](#)]
- 24 **Murphy MD**, Smith WS, Smith SE, Kransdorf MJ, Temple HT. From the archives of the AFIP. Imaging of musculoskeletal neurogenic tumors: radiologic-pathologic correlation. *Radiographics* 1999; **19**: 1253-1280 [PMID: [10489179](#) DOI: [10.1148/radiographics.19.5.g99se101253](#)]
- 25 **Kumar BS**, Gopal M, Talwar A, Ramesh M. Diffuse neurofibroma of the scalp presenting as circumscribed alopecic patch. *Int J Trichology* 2010; **2**: 60-62 [PMID: [21188030](#) DOI: [10.4103/0974-7753.66919](#)]
- 26 **Lefere I**, Dalle I, Thieren H, Decock S, Ramboer K. Diffuse intestinal ganglioneuromatosis of the ileum. *JBR-BTR* 2012; **95**: 152-153 [PMID: [22880516](#) DOI: [10.5334/jbr-btr.596](#)]
- 27 **Abd-El Khalek Abd-ALRazek A**, Fahmy DM. Diagnostic Value of Diffusion-Weighted Imaging and Apparent Diffusion Coefficient in Assessment of the Activity of Crohn Disease: 1.5 or 3 T. *J Comput Assist Tomogr* 2018; **42**: 688-696 [PMID: [29958199](#) DOI: [10.1097/RCT.0000000000000754](#)]
- 28 **Abdel Razek AA**, Abu Zeid MM, Bilal M, Abdel Wahab NM. Virtual CT colonoscopy versus conventional colonoscopy: a prospective study. *Hepatogastroenterology* 2005; **52**: 1698-1702 [PMID: [16334760](#)]
- 29 **Boldorini R**, Tosoni A, Leutner M, Ribaldone R, Surico N, Comello E, Min KW. Multiple small intestinal stromal tumours in a patient with previously unrecognised neurofibromatosis type 1: immunohistochemical and ultrastructural evaluation. *Pathology* 2001; **33**: 390-395 [PMID: [11523947](#) DOI: [10.1080/00313020126313](#)]
- 30 **Hirbe AC**, Gutmann DH. Neurofibromatosis type 1: a multidisciplinary approach to care. *Lancet Neurol* 2014; **13**: 834-843 [PMID: [25030515](#) DOI: [10.1016/S1474-4422\(14\)70063-8](#)]
- 31 **Basile U**, Cavallaro G, Polistena A, Giustini S, Orlando G, Cotesta D, Petramala L, Letizia C, Calvieri S, De Toma G. Gastrointestinal and retroperitoneal manifestations of type 1 neurofibromatosis. *J Gastrointest Surg* 2010; **14**: 186-194 [PMID: [19495890](#) DOI: [10.1007/s11605-009-0940-5](#)]
- 32 **Hwang IK**, Hahn SM, Kim HS, Kim SK, Kim HS, Shin KH, Suh CO, Lyu CJ, Han JW. Outcomes of Treatment for Malignant Peripheral Nerve Sheath Tumors: Different Clinical Features Associated with Neurofibromatosis Type 1. *Cancer Res Treat* 2017; **49**: 717-726 [PMID: [28052660](#) DOI: [10.4143/crt.2016.271](#)]



Published by Baishideng Publishing Group Inc
7041 Koll Center Parkway, Suite 160, Pleasanton, CA 94566, USA
Telephone: +1-925-3991568
E-mail: bpgoffice@wjgnet.com
Help Desk: <https://www.f6publishing.com/helpdesk>
<https://www.wjgnet.com>

