

Name of Journal: *World Journal of Clinical Oncology*

Manuscript NO: 54690

Manuscript Type: CASE REPORT

**Mechanisms and anatomical risk factors of pneumothorax after
Bevacizumab use: A case report**

Ozaki Y *et al.* Pneumothorax after Bevacizumab use

Yuri Ozaki¹, Akiyo Yoshimura, ⁴Masataka Sawaki, Masaya Hattori, Naomi
Gondo, Haruru Kotani, Yayoi Adachi, Ayumi Kataoka, Kayoko Sugino, Nanae
Horisawa, Yuka Endo, Kazuki Nozawa, Shoko Sakamoto, Hiroji Iwata

Abstract

BACKGROUND

Bevacizumab is an antiangiogenic agent, and that synergizes with
chemotherapeutic drugs. When used in combination therapies, Bevacizumab is
associated with adverse events such as hemorrhage, gastrointestinal

Match Overview

1	Internet 16 words crawled on 08-Mar-2016 www.dovepress.com	1%
2	Crossref 15 words Tadahiro Nozoe, Emiko Mori, Tomohiro Iguchi, Akinori Egashira, Eisuke Adachi, Akito Matsukuma, Takahiro Ezaki. "Immun..."	1%
3	Crossref 14 words M. Mori, M. Sawaki, M. Hattori, A. Yoshimura, N. Gondo, H. Kotani, Y. Adachi, A. Kataoka, K. Sugino, H. Iwata. "Microdoc..."	1%
4	Internet 14 words crawled on 18-Mar-2019 surgicalcasereports.springeropen.com	1%
5	Internet 12 words crawled on 14-Jan-2020 www.oncotarget.com	1%
6	Internet 12 words ascpt.org	1%

Mechanisms and anatomical risk factors of pneumothorax



ALL

IMAGES

VIDEOS

41,100 Results

Any time ▾

Bilateral pneumothorax after bevacizumab-containing ...

<https://www.ncbi.nlm.nih.gov/pmc/articles/PMC3378222>

Apr 01, 2012 · The **pneumothorax** resolved completely **after chest tube drainage**. The chest tube was removed 3 days later. In the fourth chemotherapy, **bevacizumab** was not **used and pneumothorax** was not occurred. However, in the fifth chemotherapy, we add the **bevacizumab** again, chest radiograph showed right **pneumothorax** a week **later after bevacizumab** (Figure 4). The **pneumothorax** resolved completely **after chest tube drainage**.

Cited by: 7

Author: Yalei Zhang, Haihong Yang, Meiling Zhao,...

Publish Year: 2012

Pneumothorax After Bevacizumab-containing ...

<https://academic.oup.com/jjco/article/41/2/269/873905> ▾

Oct 28, 2010 · Several risk factors predisposing to GI perforation after bevacizumab have been proposed including **peptic ulcer disease**, **acute diverticulitis**, **primary tumor in situ**, **abdominal irradiation**, **abdominal carcinomatosis** and obstruction (10,11). Because of the different anatomic and physiologic characteristics of the lungs and the GI tract, the risk factors for GI perforation would not likely be the ...

Cited by: 21

Author: Sheng-Hsiang Yang, Sheng-Hsiang Yang,...

Publish Year: 2011

Pneumothorax After Bevacizumab-containing



40,000 Results

Any time ▾

Bilateral pneumothorax after bevacizumab-containing ...

<https://www.ncbi.nlm.nih.gov/pmc/articles/PMC3378222>

Apr 01, 2012 · The **pneumothorax** resolved completely **after chest tube drainage**. The chest tube was removed 3 days later. In the fourth chemotherapy, **bevacizumab** was not **used and pneumothorax** was not occurred. However, in the fifth chemotherapy, we add the **bevacizumab** again, chest radiograph showed right **pneumothorax** a week **later after bevacizumab** (Figure 4). The **pneumothorax** resolved completely **after chest tube drainage**.

Cited by: 7

Author: Yalei Zhang, Haihong Yang, Meiling Zhao...

Publish Year: 2012

Pneumothorax After Bevacizumab-containing Chemotherapy: A ...

<https://academic.oup.com/jjco/article/41/2/269/873905>

Oct 28, 2010 · Several risk factors predisposing to GI perforation after bevacizumab have been proposed including **peptic ulcer disease**, **acute diverticulitis**, primary **tumor** in situ, **abdominal irradiation**, **abdominal carcinomatosis** and obstruction (10,11). Because of the different anatomic and physiologic characteristics of the lungs and the GI tract, the risk factors for GI perforation would not likely be the ...

Cited by: 21

Author: Sheng-Hsiang Yang, Sheng-Hsiang Yang...

Publish Year: 2011

Pneumothorax After Bevacizumab-containing Chemotherapy: A ...

<https://www.researchgate.net/publication/47621413...>

Although several **cases of pneumothorax induced by bevacizumab** have been reported, this case is the first documentation that **bevacizumab caused a rupture of the lung metastatic lesion**, leading to ...

PEOPLE ALSO ASK

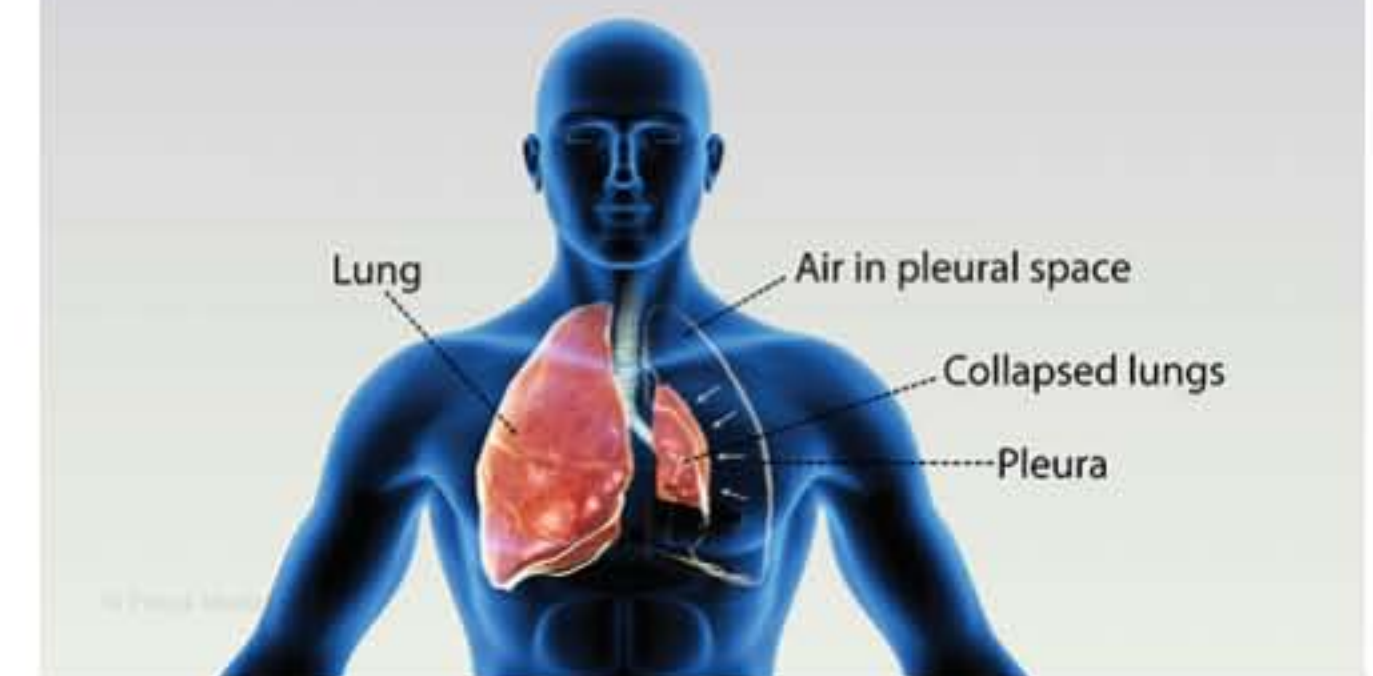
What are the risk factors for a pneumothorax? ▾

Are men more likely to have a pneumothorax? ▾

Pneumothorax

Medical Condition

Chest pain and breathing difficulty



A collapsed lung that occurs when air enters the space around lungs.

🏠 Rare (Fewer than 200,000 cases per year in US)

🧪 Often requires lab test or imaging

👨🏻‍⚕️ Treatment from medical professional advised

🕒 Can last several days or weeks

Injury or existing lung diseases are the main causes. Pain in the chest and breathing difficulty are the common symptoms. Chest tube insertion or surgery is the treatment options.

Symptoms

- A steady ache in the chest
- Shortness of breath, or dyspnea
- Breaking out into cold sweat
- Tightness in the chest



39,900 Results Any time ▾

[Pneumothorax After Bevacizumab-containing Chemotherapy: A ...](https://academic.oup.com/jjco/article/41/2/269/873905)

<https://academic.oup.com/jjco/article/41/2/269/873905>

Oct 28, 2010 · Several risk factors predisposing to GI perforation after bevacizumab have been proposed including **peptic ulcer disease**, **acute diverticulitis**, primary **tumor** in situ, **abdominal irradiation**, **abdominal carcinomatosis** and obstruction (10,11). Because of the different anatomic and physiologic characteristics of the lungs and the GI tract, the risk factors for GI perforation would not likely be the ...

Cited by: 21

Author: Sheng-Hsiang Yang, Sheng-Hsiang Yang...

Publish Year: 2011

[Bilateral pneumothorax after bevacizumab-containing ...](https://www.ncbi.nlm.nih.gov/pmc/articles/PMC3378222)

<https://www.ncbi.nlm.nih.gov/pmc/articles/PMC3378222>

Apr 01, 2012 · The **pneumothorax** resolved completely **after chest tube drainage**. The chest tube was removed 3 days later. In the fourth chemotherapy, **bevacizumab** was not **used** and **pneumothorax** was not occurred. However, in the fifth chemotherapy, we add the **bevacizumab** again, chest radiograph showed right **pneumothorax** a week **later after bevacizumab** (Figure 4). The **pneumothorax** resolved completely **after chest tube drainage**.

Cited by: 7

Author: Yalei Zhang, Haihong Yang, Meiling Zhao...

Publish Year: 2012

[Pneumothorax After Bevacizumab-containing Chemotherapy: A ...](https://www.researchgate.net/publication/47621413...)

<https://www.researchgate.net/publication/47621413...>

Although several **cases of pneumothorax induced by bevacizumab** have been reported, this case is the first documentation that **bevacizumab caused a rupture of the lung metastatic lesion**, leading to ...

[Bilateral pneumothorax after bevacizumab-containing ...](https://jtd.amegroups.com/article/view/328/656)

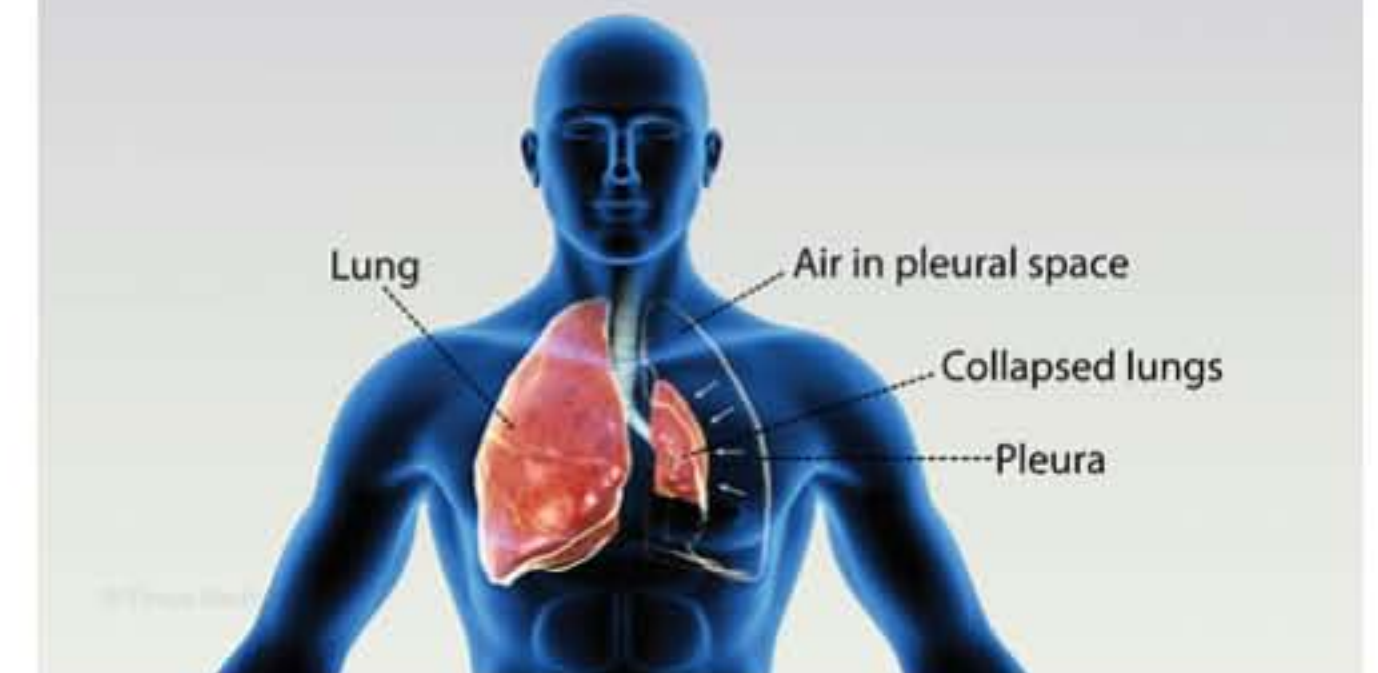
jtd.amegroups.com/article/view/328/656

It can improve outcomes in patients with sarcoma (1). **Bevacizumab** has several notable adverse effects including bleeding, hypertension, heart failure, **proteinuria**, thromboembolism and gastrointestinal (GI) perforation, an uncommon but serious adverse effect (2,4). However, **bilateral SP** occurring **after**

Pneumothorax

Medical Condition

Chest pain and breathing difficulty



A collapsed lung that occurs when air enters the space around lungs.

🏠 Rare (Fewer than 200,000 cases per year in US)

🧪 Often requires lab test or imaging

👨🏻‍⚕️ Treatment from medical professional advised

🕒 Can last several days or weeks

Injury or existing lung diseases are the main causes. Pain in the chest and breathing difficulty are the common symptoms. Chest tube insertion or surgery is the treatment options.

Symptoms

- A steady ache in the chest