

World Journal of *Hepatology*

World J Hepatol 2020 July 27; 12(7): 332-412



REVIEW

- 332** Oxidative stress in alcohol-related liver disease
Tan HK, Yates E, Lilly K, Dhanda AD

ORIGINAL ARTICLE

Basic Study

- 350** Ipragliflozin-induced improvement of liver steatosis in obese mice may involve sirtuin signaling
Suga T, Sato K, Ohyama T, Matsui S, Kobayashi T, Tojima H, Horiguchi N, Yamazaki Y, Kakizaki S, Nishikido A, Okamura T, Yamada M, Kitamura T, Uraoka T
- 363** Anti-inflammatory and anti-oxidant effects of aloe vera in rats with non-alcoholic steatohepatitis
Klaikaw N, Wongphoom J, Werawatganon D, Chayanupatkul M, Siriviriyakul P

Observational Study

- 378** Non-alcoholic steatohepatitis and the risk of myocardial infarction: A population-based national study
Ghoneim S, Dhorepatil A, Shah AR, Ram G, Ahmad S, Kim C, Asaad I

META-ANALYSIS

- 389** Effect of zinc treatment on clinical outcomes in patients with liver cirrhosis: A systematic review and meta-analysis
Tan HK, Streeter A, Cramp ME, Dhanda AD

CASE REPORT

- 399** Diagnosis and management of hepatic artery in-stent restenosis after liver transplantation by optical coherence tomography: A case report
Galastrri FL, Gilberto GM, Affonso BB, Valle LGM, Falsarella PM, Caixeta AM, Lima CA, Silva MJ, Pinheiro LL, Baptistella CDPA, Almeida MDD, Garcia RG, Wolosker N, Nasser F
- 406** Is right lobe liver graft without main right hepatic vein suitable for living donor liver transplantation?
Demyati K, Akbulut S, Cicek E, Dirican A, Koc C, Yilmaz S

ABOUT COVER

Editorial board member of *World Journal of Hepatology*. Koo Jeong Kang, MD, PhD, Professor, Division of HBP Surgery, Department of Surgery, Keimyung University Dong-San Hospital, Daegu, South Korea. As a hepatobiliary surgeon, he has been dedicated in hepatobiliary and pancreatic surgery including HCC, intrahepatic cholangiocarcinoma, hilar cholangiocarcinoma, cancer of gallbladder, pancreatic cancer and liver transplantation including LDLT, laparoscopic as well as open. Initially as a HBP surgeon, his research interests was hepatic ischemia/reperfusion injury to prevent hepatic injury both clinical but experimental research to establish safe liver surgeries. And he interested in the clinical significance of anatomical resection of the liver cancer, systematic segmentectomy or Glissonean pedicle approach according to the size and location of the tumor.

AIMS AND SCOPE

The primary aim of *World Journal of Hepatology* (WJH, *World J Hepatol*) is to provide scholars and readers from various fields of hepatology with a platform to publish high-quality basic and clinical research articles and communicate their research findings online.

WJH mainly publishes articles reporting research results and findings obtained in the field of hepatology and covering a wide range of topics including chronic cholestatic liver diseases, cirrhosis and its complications, clinical alcoholic liver disease, drug induced liver disease autoimmune, fatty liver disease, genetic and pediatric liver diseases, hepatocellular carcinoma, hepatic stellate cells and fibrosis, liver immunology, liver regeneration, hepatic surgery, liver transplantation, biliary tract pathophysiology, non-invasive markers of liver fibrosis, viral hepatitis.

INDEXING/ABSTRACTING

The WJH is now abstracted and indexed in PubMed, PubMed Central, Emerging Sources Citation Index (Web of Science), Scopus, China National Knowledge Infrastructure (CNKI), China Science and Technology Journal Database (CSTJ), and Superstar Journals Database.

RESPONSIBLE EDITORS FOR THIS ISSUE

Electronic Editor: *Li-Li Wang*, Production Department Director: *Yun-Xiaojuan Wu*, Editorial Office Director: *Jiu-Ping Yan*.

NAME OF JOURNAL

World Journal of Hepatology

ISSN

ISSN 1948-5182 (online)

LAUNCH DATE

October 31, 2009

FREQUENCY

Monthly

EDITORS-IN-CHIEF

Nikolaos Pylsopoulos, Ke-Qin Hu, Koo Jeong Kang

EDITORIAL BOARD MEMBERS

<https://www.wjgnet.com/1948-5182/editorialboard.htm>

PUBLICATION DATE

July 27, 2020

COPYRIGHT

© 2020 Baishideng Publishing Group Inc

INSTRUCTIONS TO AUTHORS

<https://www.wjgnet.com/bpg/gerinfo/204>

GUIDELINES FOR ETHICS DOCUMENTS

<https://www.wjgnet.com/bpg/GerInfo/287>

GUIDELINES FOR NON-NATIVE SPEAKERS OF ENGLISH

<https://www.wjgnet.com/bpg/gerinfo/240>

PUBLICATION ETHICS

<https://www.wjgnet.com/bpg/GerInfo/288>

PUBLICATION MISCONDUCT

<https://www.wjgnet.com/bpg/gerinfo/208>

ARTICLE PROCESSING CHARGE

<https://www.wjgnet.com/bpg/gerinfo/242>

STEPS FOR SUBMITTING MANUSCRIPTS

<https://www.wjgnet.com/bpg/GerInfo/239>

ONLINE SUBMISSION

<https://www.f6publishing.com>

Basic Study

Anti-inflammatory and anti-oxidant effects of aloe vera in rats with non-alcoholic steatohepatitis

Naruemon Klaikeaw, Jutamas Wongphoom, Duangporn Werawatganon, Maneerat Chayanupatkul, Prasong Siriviriyakul

ORCID number: Naruemon Klaikeaw 0000-0001-8847-9692; Jutamas Wongphoom 0000-0001-8847-9691; Duangporn Werawatganon 0000-0001-8847-9690; Maneerat Chayanupatkul 0000-0002-1649-5373; Prasong Siriviriyakul 0000-0001-8847-9693.

Author contributions: Klaikeaw N, Werawatganon D and Siriviriyakul P designed the study; Klaikeaw N, Wongphoom J and Werawatganon D performed the experiments; Klaikeaw N performed pathological examinations; Wongphoom J collected the data; Wongphoom J, Werawatganon D, Chayanupatkul M and Siriviriyakul P analyzed the data; Werawatganon D edited the manuscript; Chayanupatkul M wrote the manuscript; Siriviriyakul P revised the manuscript.

Supported by the Grant of Ratchadaphiseksomphot, Faculty of Medicine, Chulalongkorn University, Bangkok, Thailand, No. RA59/035.

Institutional review board statement: The study was reviewed and approved by the Ethical Committee, Faculty of Medicine, Chulalongkorn University, Thailand (IRB No.12/58).

Naruemon Klaikeaw, Jutamas Wongphoom, Department of Pathology, Faculty of Medicine, Chulalongkorn University, Bangkok 10330, Thailand

Duangporn Werawatganon, Maneerat Chayanupatkul, Prasong Siriviriyakul, Alternative and Complementary Medicine for Gastrointestinal and Liver Diseases Research Unit, Department of Physiology, Faculty of Medicine, Chulalongkorn University, Bangkok 10330, Thailand

Corresponding author: Duangporn Werawatganon, MD, MSc, Professor, Alternative and Complementary Medicine for Gastrointestinal and Liver Diseases Research Unit, Department of Physiology, Faculty of Medicine, Chulalongkorn University, Henri Dunant Road, Pathumwan, Bangkok 10330, Thailand. dr.duangporn@gmail.com

Abstract

BACKGROUND

Aloe vera exerts several biological activities, such as, anti-inflammatory, antioxidant, and antimicrobial effects. It was recently shown to reduce insulin resistance and triglyceride level. We hypothesized that aloe vera would have beneficial effects in alleviating non-alcoholic steatohepatitis (NASH) in rats.

AIM

To examine the therapeutic effects of aloe vera in NASH rats.

METHODS

All rats were randomly divided into 3 groups ($n = 6$ in each group). Rats in the control group were fed ad libitum with a standard diet for 8 wk. Rats in the NASH group were fed ad libitum with a high-fat high-fructose diet (HFHFD) for 8 wk. Rats in the aloe vera group were fed ad libitum with a HFHFD and aloe vera in dimethylsulfoxide (50 mg/kg) by gavage daily for 8 wk. Liver samples were collected at the end of the treatment period.

RESULTS

Hepatic malondialdehyde (MDA) levels increased significantly in the NASH group as compared with the control group (377 ± 77 nmol/mg vs 129 ± 51 nmol/mg protein, respectively, $P < 0.001$). Glutathione (GSH) levels were significantly lower in the NASH group than the control group (9 ± 2 nmol/mg vs 24 ± 8 nmol/mg protein, respectively, $P = 0.001$). The expression of interleukin-18

Institutional animal care and use

committee statement: That *in vivo* experiments were performed only after receiving formal authorization by the Institutional "Animal Care and Use Committee" of the Chulalongkorn University, Bangkok, Thailand. The procedures for the care and handling of the animals used in the study were in accordance with the European Directive 2010/63/EU on the protection of animals used for scientific purposes.

Conflict-of-interest statement: No potential conflicts of interest relevant to this article were reported.

Data sharing statement: The data that support the findings of this study are available from the corresponding author, upon reasonable request.

ARRIVE guidelines statement: The authors have read the ARRIVE guidelines, and the manuscript was prepared and revised according to the ARRIVE guidelines.

Open-Access: This article is an open-access article that was selected by an in-house editor and fully peer-reviewed by external reviewers. It is distributed in accordance with the Creative Commons Attribution NonCommercial (CC BY-NC 4.0) license, which permits others to distribute, remix, adapt, build upon this work non-commercially, and license their derivative works on different terms, provided the original work is properly cited and the use is non-commercial. See: <http://creativecommons.org/licenses/by-nc/4.0/>

Manuscript source: Unsolicited manuscript

Received: February 13, 2020

Peer-review started: February 13, 2020

First decision: April 29, 2020

Revised: May 12, 2020

Accepted: May 29, 2020

Article in press: May 29, 2020

Published online: July 27, 2020

(IL-18), nuclear factor-kappa β , and caspase-3 increased, while peroxisome proliferator-activated receptor gamma decreased in the NASH group compared with the controls. Following aloe vera administration, MDA levels decreased (199 ± 35 nmol/mg protein) and GSH increased (18 ± 4 nmol/mg protein) markedly. Steatosis, hepatocyte ballooning, lobular inflammation and increased hepatocyte apoptosis were observed in the NASH group. Aloe vera treatment attenuated these changes in liver histology.

CONCLUSION

Aloe vera attenuated oxidative stress, hepatic inflammation and hepatocyte apoptosis, thus improving liver pathology in rats with NASH.

Key words: Non-alcoholic steatohepatitis; Aloe vera; Oxidative stress; Hepatic inflammation; Hepatocyte apoptosis; Peroxisome proliferator-activated receptor

©The Author(s) 2020. Published by Baishideng Publishing Group Inc. All rights reserved.

Core tip: To the best of our knowledge, this is the first study to evaluate the therapeutic effects of aloe vera in non-alcoholic steatohepatitis (NASH). In this animal model of NASH, we found that aloe vera decreased oxidative stress markers, replenished natural antioxidants, and reduced hepatic inflammation and hepatocyte apoptosis. Thus, aloe vera can alleviate the pathologic changes seen in NASH.

Citation: Klaikeaw N, Wongphoom J, Werawatganon D, Chayanupatkul M, Siriviriyakul P. Anti-inflammatory and anti-oxidant effects of aloe vera in rats with non-alcoholic steatohepatitis. *World J Hepatol* 2020; 12(7): 363-377

URL: <https://www.wjgnet.com/1948-5182/full/v12/i7/363.htm>

DOI: <https://dx.doi.org/10.4254/wjh.v12.i7.363>

INTRODUCTION

Due to the obesity epidemic, non-alcoholic fatty liver disease (NAFLD) has become the most common liver disease worldwide with an estimated prevalence of 24%^[1]. In the United States, NAFLD has now surpassed alcoholic liver disease as the leading indication for liver transplantation in women^[2]. A subset of patients with NAFLD develop non-alcoholic steatohepatitis (NASH) which can lead to fibrosis progression and cirrhosis^[3,4]. Currently, there are no Food and Drug Administration approved medications for the treatment of NASH. Weight loss, the mainstay of treatment for NASH, is difficult to achieve and hardly sustainable. Alternative therapies that are safe, effective and inexpensive are attractive options for the management of lifelong diseases such as NASH.

Indigenous to Africa, Asia and Mediterranean regions, aloe vera has long been used as a medicinal plant for various conditions^[5,6]. Aloe vera contains at least 75 potentially active constituents such as vitamins, enzymes, minerals, sugars, plant steroids, hormones and amino acids^[7]. Aloe vera and its constituents exert several biological activities, for instance, anti-inflammatory (salicylic acid, campesterol, β -sitosterol and C-glucosyl chromone), antioxidant (vitamin A, C and E), antitumor (anthraquinones and phorbol myristic acetate), and antimicrobial effects (aloin and emodin)^[5,7,8]. Aloe vera has never been directly studied in NASH but it has shown potential benefits in other liver conditions such as amelioration of acetaminophen-induced liver damage^[9]. Moreover, aloe vera has been shown to reduce insulin resistance and hepatic triglyceride levels which are major components of NASH^[10,11]. With the aforementioned evidence, we hypothesized that aloe vera could alleviate NASH *via* its anti-inflammatory and antioxidant properties. To the best of our knowledge, this is the first study to evaluate the effects of aloe vera on NASH development in an animal model.

P-Reviewer: Inoue K, Tajiri K,
Tsukanov V
S-Editor: Yan JP
L-Editor: Webster JR
E-Editor: Wang LL



MATERIALS AND METHODS

Animal preparation

The study protocol was approved by the Institutional Review Board for Animal Research Studies, Faculty of Medicine, Chulalongkorn University, Bangkok, Thailand. Male Sprague-Dawley® rats weighing 220-260 g were obtained from the National Laboratory Animal Center, Mahidol University, Nakorn Pathom, Thailand. The animals were kept in a controlled temperature room at $25 \pm 1^\circ\text{C}$ under standard conditions with a normal 12 h light-12 h dark cycle. All rats had free access to drinking water. The animals were allowed to acclimate to the new environment for 1 wk prior to initiation of the experiment.

Aloe vera preparation

Leaves of 1-year-old aloe vera plants were cut and washed thoroughly with water to cleanse the aloin-containing juice. The spiked edges were sliced off to extract the pulp. The pulp was then mixed in a blender and sieved through fine gauze. Aloe vera gel was turned into powder by freeze drying using a lyophilizer. Before use, the aloe vera powder was reconstituted into gel form and dispensed in distilled water (DW).

Experimental protocol

A total of 18 rats were randomly divided into 3 groups as follows: (1) Group 1 (control group, $n = 6$): Rats were fed ad libitum with standard laboratory chow (National Laboratory Animal Center, Mahidol University, Nakorn Pathom, Thailand) which contained 35% of total energy from fat, 47% from carbohydrate, and 18% from protein for 8 wk; (2) Group 2 (NASH group, $n = 6$): Rats were fed ad libitum with a made-in-house high-fat high-fructose diet (HFHFD) which contained 55% of total energy from fat, 35% from carbohydrate (20% from fructose and 15% from starch), and 10% from protein for 8 wk; and (3) Group 3 (aloe vera group, $n = 6$): Rats were fed ad libitum with the HFHFD plus daily administration of aloe vera (50 mg/kg) dissolved in DW by gavage for 8 wk. Aloe vera powder was supplied by Lipo Chemical Co., United States.

Animals were weighed weekly during the experimental period. At the end of 8 wk, all rats were euthanized with sodium thiopental overdose after a 12-h fast. The liver was surgically removed and cut into several pieces. Three small pieces of liver were immediately frozen in liquid nitrogen and stored at -80°C until malondialdehyde (MDA) and glutathione (GSH) analysis. The remaining liver specimen was fixed in 10% formaldehyde for histopathological examination and the expression of IL-18, PPAR γ , caspase-3, cytochrome-C and NF- $\kappa\beta$ was analyzed using an immunohistochemistry technique.

Hepatic MDA determination

MDA level was measured from homogenized tissue using a commercial assay kit (Cayman Chemical Company, Ann Arbor, MI, United States). The test involved measuring the rate of production of thiobarbituric acid-reactive substances under high-temperature and acidic conditions. The process is described as follows: One gram of liver tissue was homogenized in radioimmunoprecipitation assay buffer (RIPA buffer) containing protease inhibitor and sonicated on ice for 15 s. Supernatants were obtained after centrifugation at $1600 \times g$ for 10 min at 4°C . The absorbance of the supernatant fraction was read at a wavelength of 532 nm. MDA levels were calculated from a standard curve and expressed as nmol/mg protein.

Hepatic GSH measurement

GSH level was quantified using a commercial assay kit (Cayman Chemical Company, Ann Arbor, MI, United States). Liver tissues were washed with phosphate buffered saline (PBS) solution. Tissues were then homogenized with cold MES buffer before being centrifuged at $10000 \times g$ for 15 min at 4°C . The supernatants were collected and deproteinated. The absorbance of the supernatant fraction was read at a wavelength of 405 nm and GSH values were calculated from a standard curve and expressed as nmol/mg protein.

Immunohistochemistry for hepatic IL-18, PPAR- γ , NF- $\kappa\beta$, caspase-3, and cytochrome-C expression

After being fixed in formaldehyde, liver samples were embedded in paraffin and sliced at a thickness of 3 μm . The tissue sections were then deparaffinized with xylene

and ethanol for 10 min. Antigen retrieval was achieved by treating the slides with citrate buffer at pH 6.0 and heating in a microwave for 13 min. The slides were incubated with 3% hydrogen peroxide to block endogenous peroxidase activity for 5 min and with 3% normal horse serum to block nonspecific binding for 20 min. Tissues were then washed with PBS solution. The sections were subsequently incubated with primary antibodies for IL-18 (Gene Tex, CA, United States), PPAR- γ (Santa Cruz Biotechnology, CA, United States), NF- κ B (Abcam, MA, United States), caspase-3, and cytochrome-C (R and D, United States) for 30 min at room temperature and washed again with PBS solution. The slides were then incubated with specific secondary antibodies for 30 min at room temperature. When color development with diaminobenzidine was detected, the sections were counterstained with hematoxylin.

Under light microscopy, IL-18-positive cells were defined as Kupffer cells with dark brown-stained nuclei. Hepatocytes with PPAR- γ , NF- κ B, caspase-3 and cytochrome-C expression were characterized as liver cells with brownish nuclei. Images of each sample were taken at high-magnification (40 \times). The numbers of positive stained cells were counted using Aperio ImageScope software (Leica Biosystems Imaging, Inc., MD, United States) and expressed as the percentage of immunoreactive cells or average intensity (pixel).

Histopathological examination

Liver samples were processed using a standard technique. Collected liver tissue was fixed in 10% formalin at room temperature for 24–48 h, embedded in paraffin and sectioned at 3 μ m using a microtome. Each tissue section was stained with hematoxylin and eosin and placed on glass slides for light microscopic examination. An experienced pathologist blinded to the experiment evaluated all samples. All fields in each section were examined and graded for steatosis (0–3), hepatocyte ballooning (0–3) and lobular inflammation (0–3) according to the criteria described by Brunt *et al.*^[12]. The percentage of apoptotic hepatocytes was determined by terminal deoxynucleotidyl transferase dUTP nick end labeling (TUNEL) method using the ApopTag® Peroxidase In Situ Apoptosis Detection kit (Millipore, CA, United States). The procedure was performed according to the manufacturer's instructions.

Statistical analysis

Continuous data are presented as mean \pm SD. One-way ANOVA and the post-hoc Tukey HSD were used to compare results between the groups. A *P* value of less than 0.05 was considered statistically significant. All statistical analyses were performed using SPSS Statistics for Windows version 17 (SPSS, Inc., Chicago, IL, United States).

RESULTS

Body weight changes in each group

There were no differences in body weight among the groups at the beginning of the experiment. After eight weeks, rats fed with the HFHFD (NASH group) had lower body weight than those in the control group (223 ± 14.0 g *vs* 417 ± 11.2 g, respectively, *P* < 0.001). Following aloe vera administration, rats in the treatment arm gained more weight than those in the NASH group (276 ± 3.6 g *vs* 223 ± 14.0 g, respectively, *P* < 0.001) (Figure 1).

Liver histopathology

The histologic scores in each group are summarized in Table 1. Liver histology was normal in the control group. In contrast, liver pathology in the NASH group revealed significant macrovesicular and microvesicular steatosis, hepatocyte ballooning and lobular inflammation. Following aloe vera treatment, liver pathology significantly improved with only mild steatosis, minimal hepatocyte ballooning and lobular inflammation present (Figure 2A).

Hepatic MDA and GSH levels

As shown in Figure 3A, MDA levels in the NASH group were significantly higher than those in the control group (377 ± 77 nmol/mg *vs* 129 ± 51 nmol/mg protein, *P* < 0.001). MDA levels declined significantly in rats receiving aloe vera along with HFHFD compared to those receiving HFHFD alone (199 ± 35 nmol/mg *vs* 377 ± 77 nmol/mg protein, *P* < 0.001). As demonstrated in Figure 3B, GSH levels in the NASH group were significantly lower than those in the control group (9 ± 2 nmol/mg *vs* 24 ± 8

Table 1 Summary of steatohepatitis and necroinflammation scores in all experimental groups

Group	Steatosis				Inflammation				Ballooning		
	0	1	2	3	0	1	2	3	0	1	2
Control	-	-	-	-	-	-	-	-	-	-	-
Non-alcoholic steatohepatitis	-	-	3	3	0	5	1	-	-	4	2
Aloe vera	3	3	-	-	2	4	-	-	3	3	-

The scoring system was based on the study by Brunt *et al*^[11].

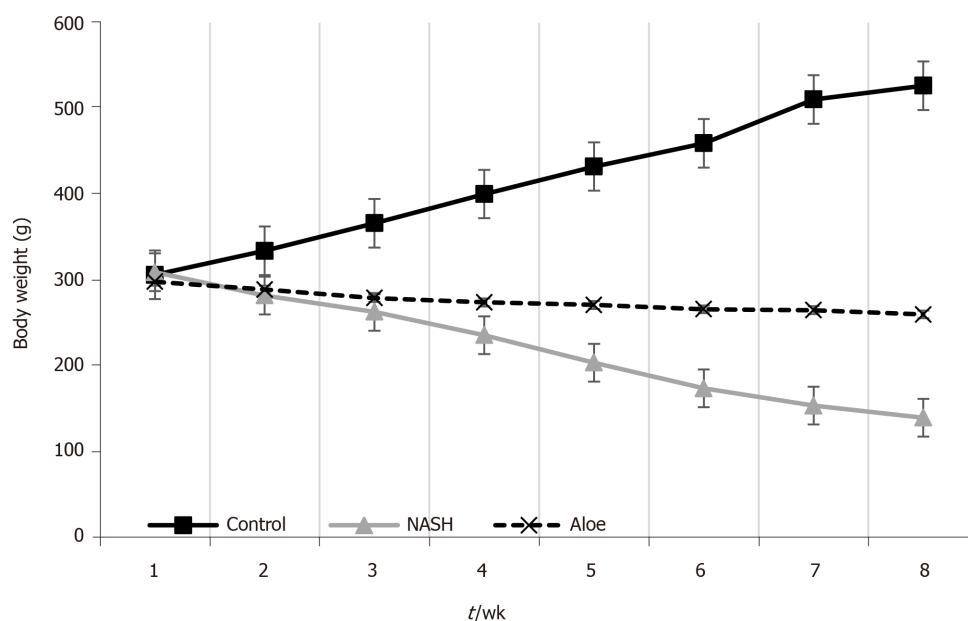


Figure 1 Mean body weight changes in rats in each group. Data at each time point are expressed as mean \pm SD. NASH: Non-alcoholic steatohepatitis.

nmol/mg protein, $P < 0.001$). Aloe vera treatment led to a notable rise in hepatic GSH levels (18 ± 4 nmol/mg *vs* 9 ± 2 nmol/mg protein in the aloe vera and NASH groups, respectively, $P = 0.04$).

Hepatic expression of IL-18, PPAR- γ , and NF- κ B by immunohistochemistry

As illustrated in Figures 2, 4, and 5, the expression of IL-18 and NF- κ B increased, while the percentage of PPAR- γ positive cells decreased in the NASH group as compared to controls. In contrast, aloe vera treatment restored the changes in hepatic IL-18, PPAR- γ , and NF- κ B expression to the levels close to those observed in the control group.

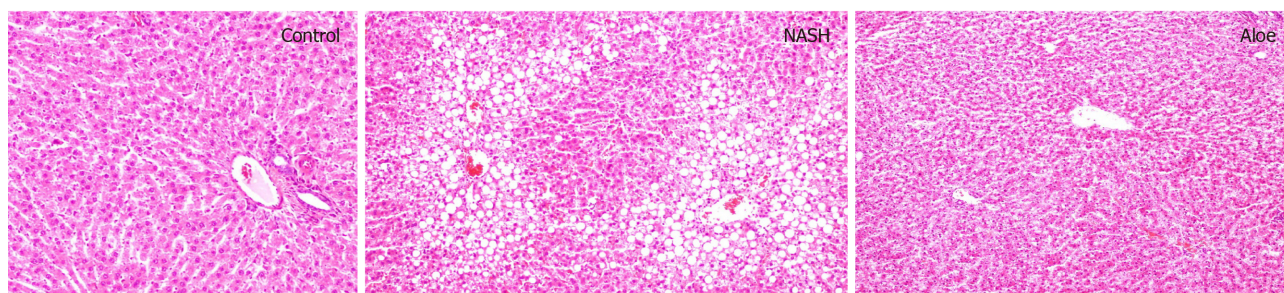
Hepatic expression of caspase-3 and cytochrome-C, and the degree of hepatocyte apoptosis by the TUNEL method

Using the TUNEL method, we found that the degree of hepatocyte apoptosis was significantly higher in the NASH group as compared with the control and aloe vera groups. Similarly, markers of apoptosis such as caspase-3 and cytochrome-C were also higher in the NASH group, while the expression of these 2 markers was similar in the control and aloe vera groups (Figures 2 and 6).

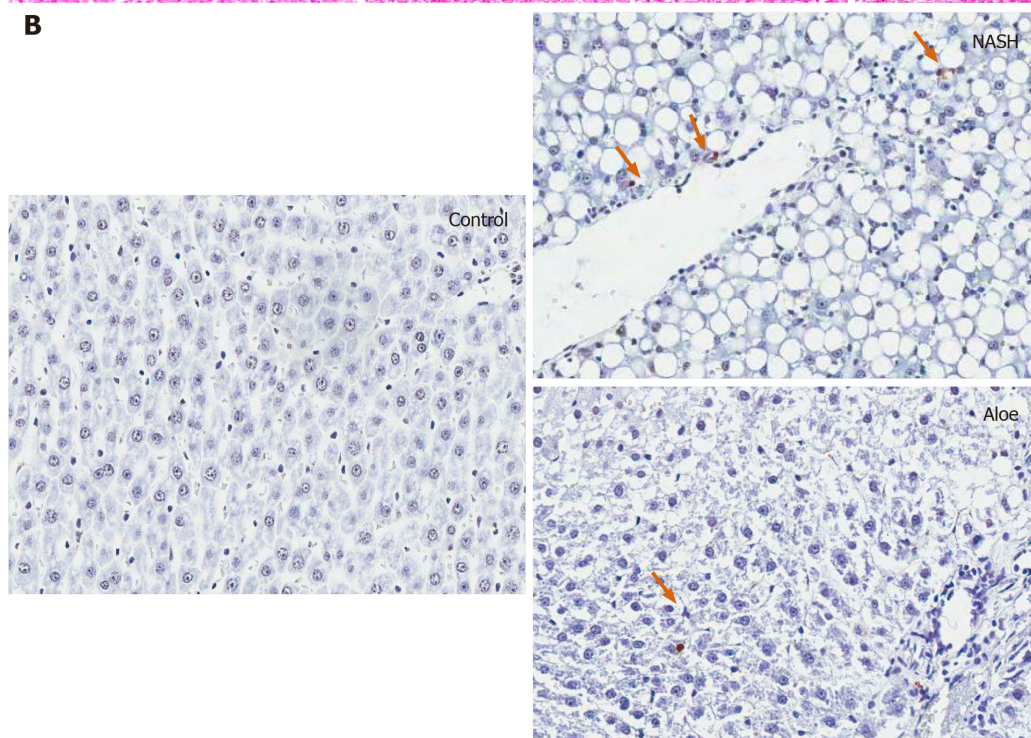
DISCUSSION

The pathogenesis of NAFLD is a complex process involving insulin resistance and lipid accumulation in the liver followed by lipid peroxidation, oxidative stress, and inflammatory responses^[13]. Insulin resistance facilitates adipose tissue lipolysis followed by the release of free fatty acids (FFA) in the serum, and promotes

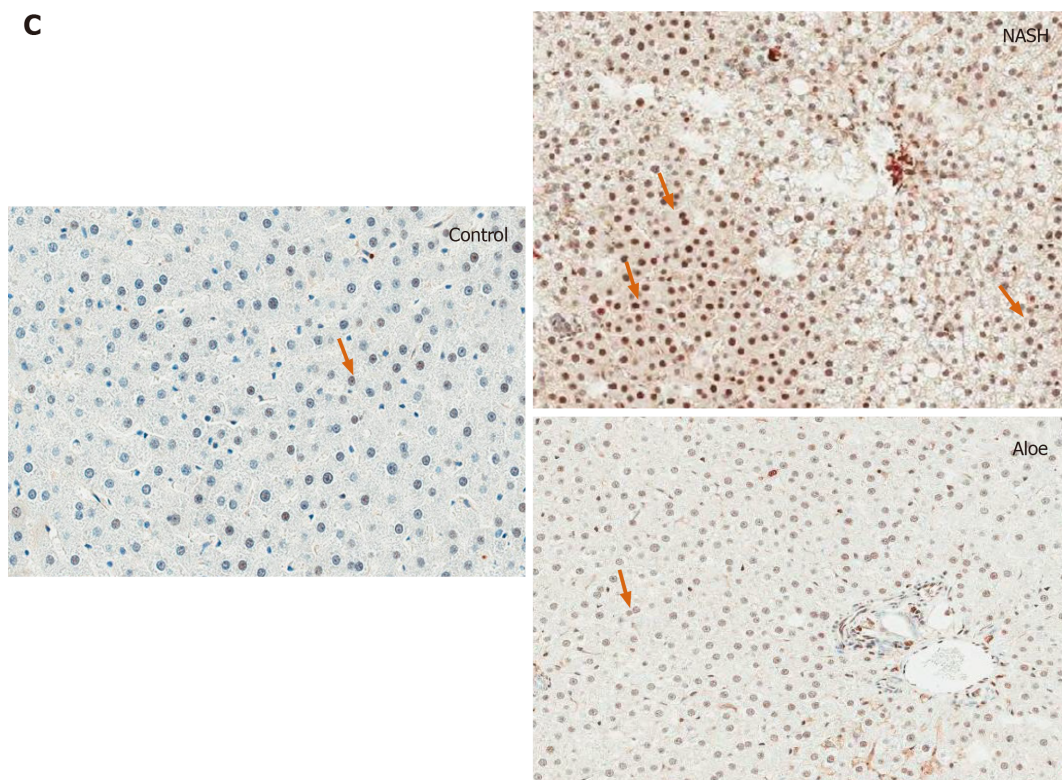
A



B



C



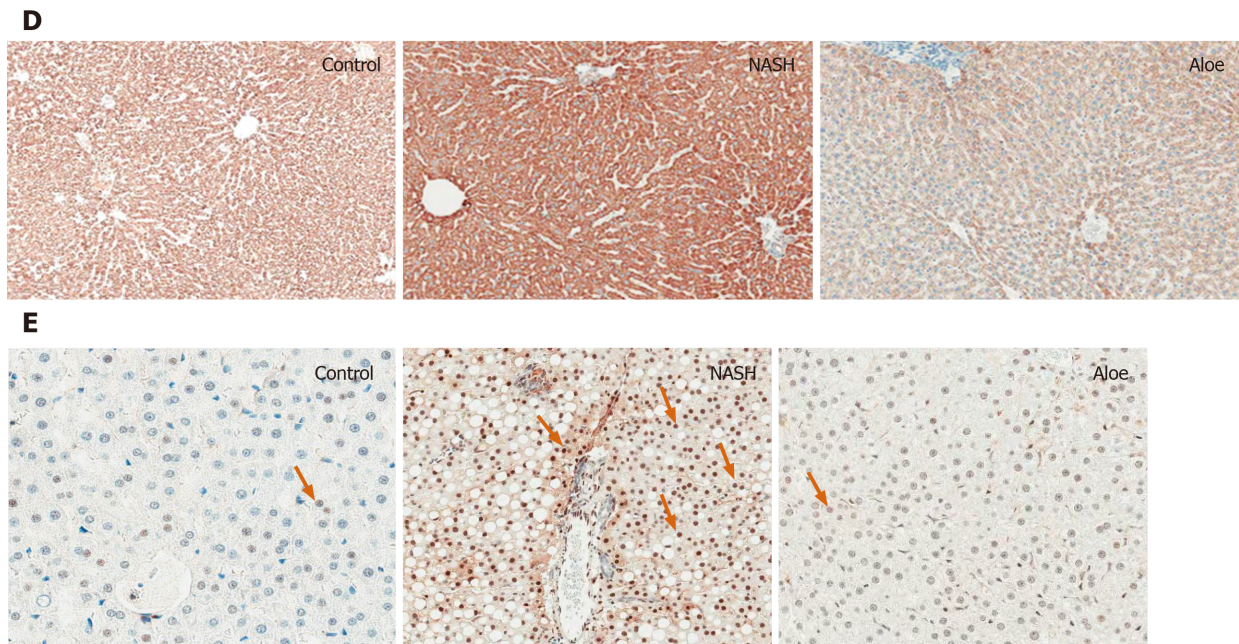


Figure 2 Representative images on light microscopy using hematoxylin and eosin stain, terminal deoxynucleotidyl transferase dUTP nick end labeling stain for apoptosis, or immunohistochemistry stains for NF- κ B, cytochrome-C and caspase-3. A: Hematoxylin and eosin stain; B: Terminal deoxynucleotidyl transferase dUTP nick end labeling stain; C: Immunohistochemistry stains; D: Cytochrome-C; E: Caspase-3. Control groups are presented on the left column; non-alcoholic steatohepatitis group in the middle and aloe vera group on the right column. Arrowheads point to positive cells. NASH: Non-alcoholic steatohepatitis.

lipogenesis in the liver, thus increasing hepatic fat accumulation. These lipids, especially saturated fatty acids (SFA), lead to lipotoxic stress in the endoplasmic reticulum and mitochondria and subsequently hepatocyte apoptosis. Moreover, SFA can activate toll-like receptor-4 leading to NF- κ B activation and TNF- α and IL-6 production, the important cytokines associated with inflammatory responses in the liver^[14].

Our results showed that aloe vera improved liver histopathological changes associated with HFHFD. In this experiment, we used aloe vera crude extract; therefore, we could not pinpoint the actual active ingredient of aloe vera that might have therapeutic effects against NASH. Previous studies suggested that phytosterols were the potential substances of interest. Misawa and colleagues evaluated the effects of lophenol and cycloartanol extracted from aloe vera gel on glucose and lipid metabolism in diabetic, obese rats. The authors found that lophenol and cycloartanol reduced the expression of both gluconeogenic and lipogenic genes in the liver along with the reduction in hepatic fat contents. This study, however, did not evaluate liver histology^[15]. Similarly, Nomaguchi *et al*^[16] used five phytosterols isolated from aloe vera gel in mice fed with high fat diet and found that aloe vera phytosterols could reduce body fat and liver triglyceride.

Accumulating evidence supports the implication of lipid peroxidation and oxidative stress in the development of NAFLD^[17-19]. In accordance with other research, we found that MDA levels, a marker of oxidative stress, increased in rats with NASH as compared with the control group. Moreover, natural antioxidants, such as GSH, significantly declined in animals receiving HFHFD further perpetuating oxidative stress in the liver. The administration of aloe vera attenuated the increment in MDA levels and restored GSH levels in rats with NASH. Despite not being studied directly in animal models of NASH, aloe vera has been shown to reduce oxidative stress markers such as thiobarbituric acid reactive substances and increase natural antioxidants such as GSH and superoxide dismutase in streptozotocin-induced diabetic rats^[20].

PPAR- γ , a member of the nuclear hormone receptor superfamily, is involved in the regulation of adipocyte differentiation, lipid metabolism, and liver inflammation^[21-23]. *In vitro* and *in vivo* studies suggested that PPAR- γ provided protection against NASH by inhibiting hepatic stellate cell proliferation and migration^[24], reducing pro-inflammatory cytokine production, and suppressing fatty acid synthesis^[22]. Zhao *et al*^[21] previously demonstrated that the mRNA levels of PPAR- γ were lower in rats fed with high fat diet and the levels were negatively correlated with the degree of hepatic

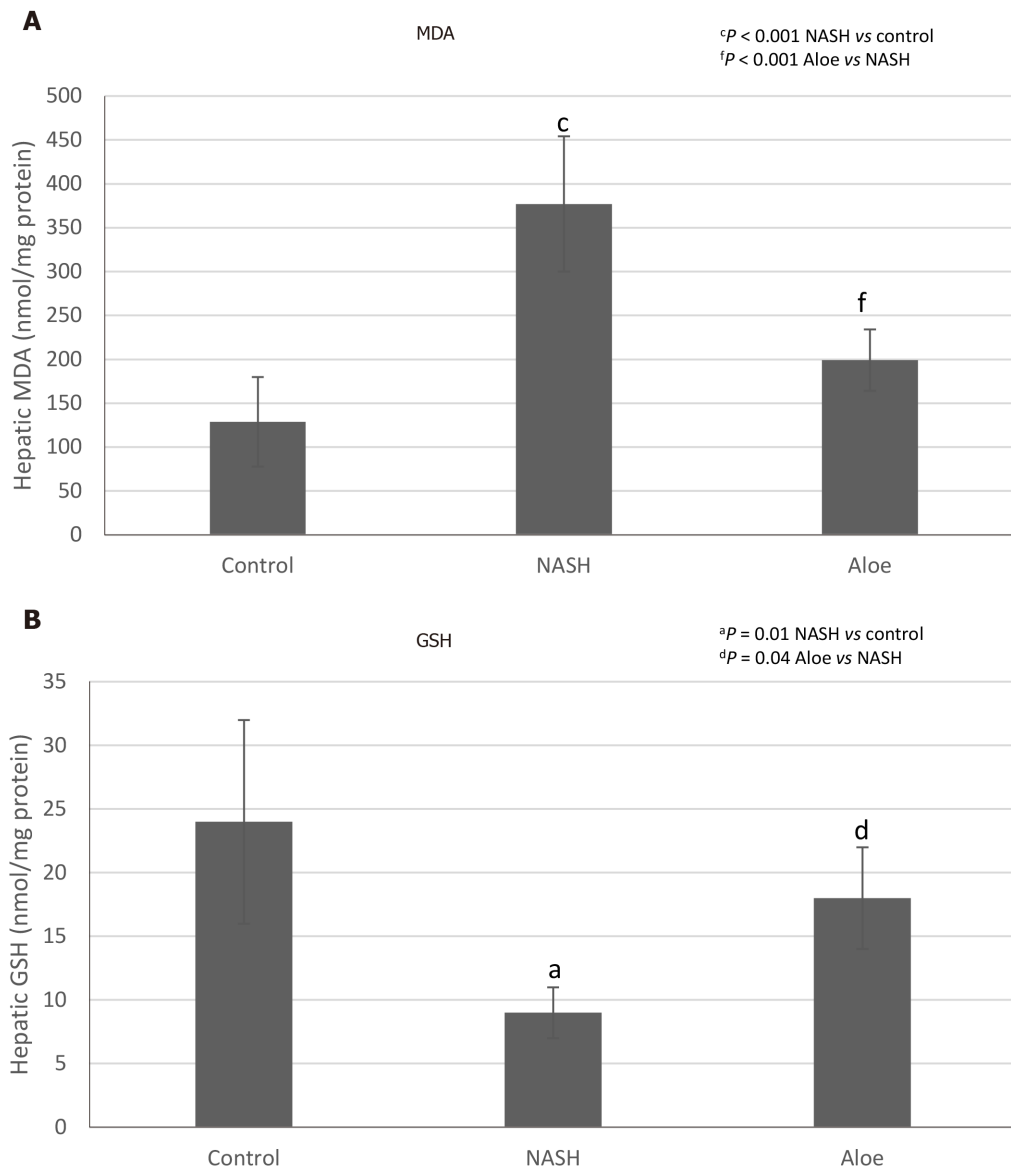
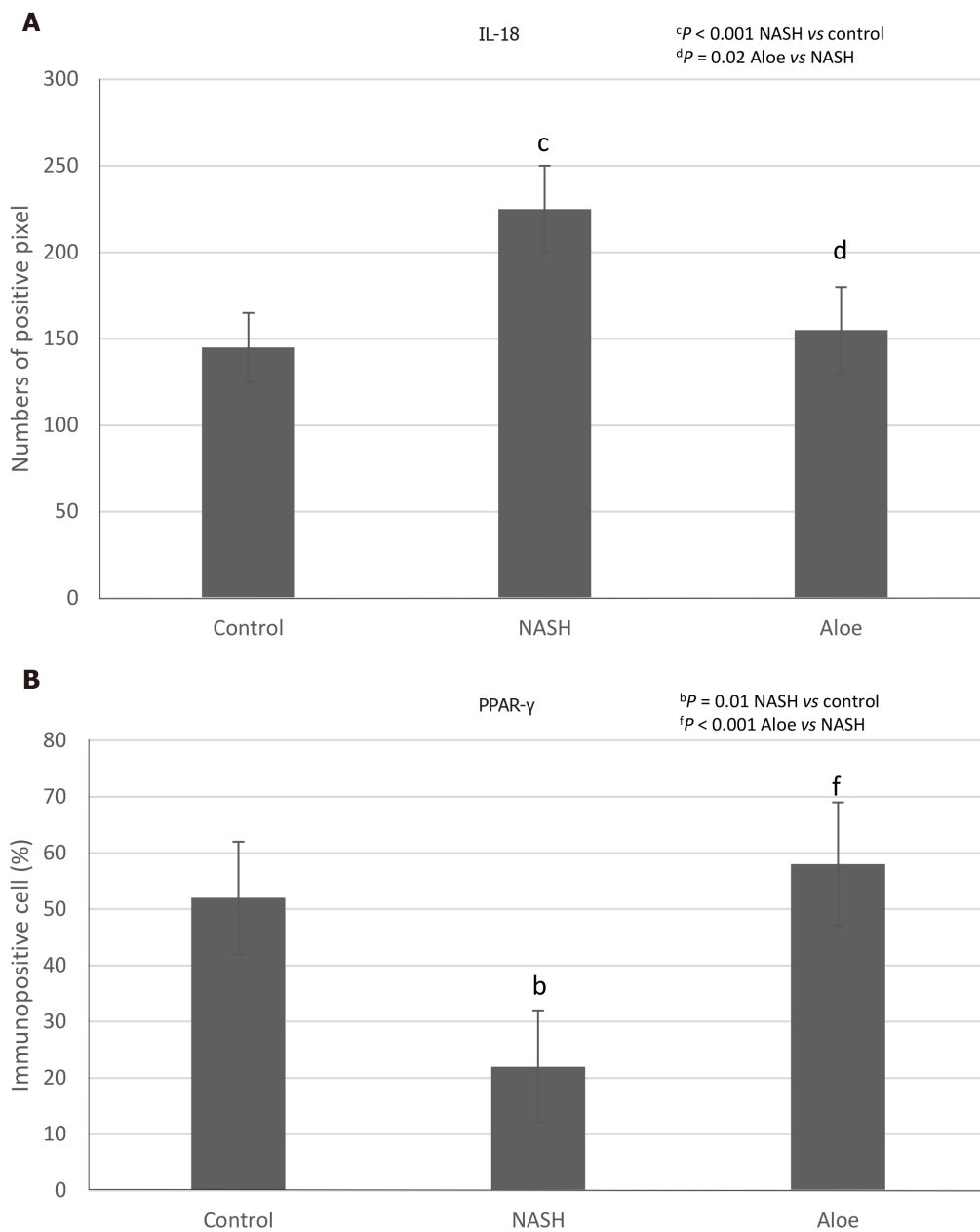


Figure 3 Hepatic malondialdehyde and glutathione levels in each group. A: Malondialdehyde; B: Glutathione. Data are expressed as mean \pm SD. NASH: Non-alcoholic steatohepatitis; MDA: Malondialdehyde; GSH: Glutathione.

inflammation, necrosis and fibrosis, as well as serum TNF- α and hepatic MDA contents. Similarly, we found that PPAR- γ expression was significantly lower in rats with NASH and this was restored to the level of control rats with aloe vera treatment. Comparable with our results, Nomaguchi *et al*^[16] found that aloe vera could stimulate PPAR- γ and α activities in a dose-dependent manner as well as decrease body fat, hepatic triglyceride levels and serum lipid panels in diet-induced obese mice^[16].

Recent data suggested that hepatocyte apoptosis may play a pivotal role in the progression of NAFLD^[25,26]. Lipid accumulation, especially saturated FFAs and free cholesterol, may sensitize Fas- and TNF-mediated hepatocyte apoptosis and induce mitochondrial dysfunction, thus activating both extrinsic and intrinsic pathways of apoptosis^[25-27]. The activation of both pathways leads to the release of pro-apoptotic proteins such as cytochrome-C, which then triggers the downstream effector caspases 3, 6, and 7 to initiate the apoptotic processes^[28]. In this study, we found increases in hepatocyte apoptosis on liver histology, and cytochrome-C and caspase-3 expression in rats with NASH. Conversely, the degree of apoptosis and its markers decreased significantly with aloe vera treatment. To the best of our knowledge, this is the first study to evaluate the effect of aloe vera on hepatocyte apoptosis.

IL-18 has previously been shown to be involved in both innate and acquired immune responses by inducing several cytokines such as interferon- γ , TNF- α and IL-1^[29]. However, recent studies demonstrated that IL-18 also played an important role in the regulation of metabolic functions and the development of NAFLD and NASH.



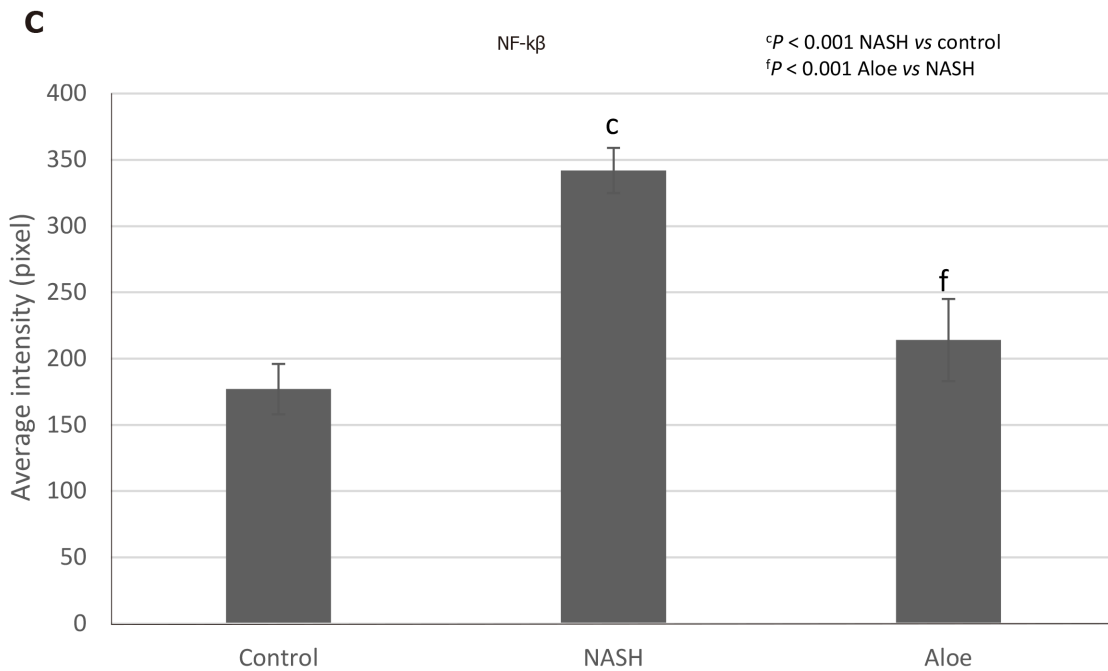


Figure 4 The expression of IL-18, PPAR- γ , and NF- κ B using immunohistochemistry methods. A: IL-18; B: PPAR- γ ; C: NF- κ B. The positive cells were counted by Aperio ImageScope software. Data are expressed as mean \pm SD. NASH: Non-alcoholic steatohepatitis.

Animal studies reported increases in food intake, body weight, insulin resistance, serum glucose and serum lipid levels, and eventually the development of NASH in IL-18 deficient mice^[30,31]. The severity of NASH also appeared to be higher in IL-18 knockout mice as compared to wild-type mice^[32]. In our study, we found increased expression of IL-18 in rats fed with HFHFD and this was normalized by the administration of aloe vera. These findings could be explained in 2 ways. The elevated IL-18 expression could be an attempt to offset the metabolic derangement due to HFHFD or simply the inflammatory responses from fat accumulation in the liver. Human studies showed similar results of elevated IL-18 levels in patients with NAFLD and these levels were positively correlated with the degree of liver injury^[33,34]. Although the presence of IL-18 is crucial in maintaining energy homeostasis, the overexpression of IL-18 could accelerate hepatocyte apoptosis and perpetuate severe liver damage^[35]. Aloe vera treatment decreased IL-18 expression through its anti-inflammatory and insulin sensitizing effects^[10].

A unique finding in our study was the presence of weight loss in rats fed with HFHFD. This was unexpected given that several experimental models of NASH showed significant weight gain in rats receiving HFHFD compared with control diet^[36-38]. This finding of weight loss was previously seen in a NASH model produced by a methionine and choline deficient diet^[39,40]. We could not ascertain the amount of methionine and choline in our diet formula but it was possible that both nutrients were at low levels given a protein content of only 10% in our custom diet. Another hypothesis was the presence of high monounsaturated and polyunsaturated fatty acid contents in our diet (19% and 6% of total energy, respectively). Studies have shown that mono- and polyunsaturated fatty acids are associated with higher post-prandial fat oxidation, diet-induced thermogenesis, decreased appetite and less weight gain as compared with SFAs^[41-44]. Lastly, we did not measure the total caloric intake of rats in each group; therefore, we could not say with absolute certainty that rats with HFHFD diet received an equal amount of calories compared to control rats. It is important to note, however, that liver histology in our model was consistent with NASH despite weight loss.

Our study, however, was not without limitations. First, rats with NASH in our model were slim, which differed from the usual NASH phenotype in humans. Our findings may be useful in the understanding of “lean” NASH in humans, but translating our results to “obese” NASH should be done with caution. Second, aloe vera and HFHFD were administered simultaneously resulting in our study representing more of a prevention model than treatment model. Further studies are warranted to confirm the therapeutic effects of aloe vera. Third, we only evaluated the gross effects of aloe vera on NASH development in this study. Additional *in vitro*

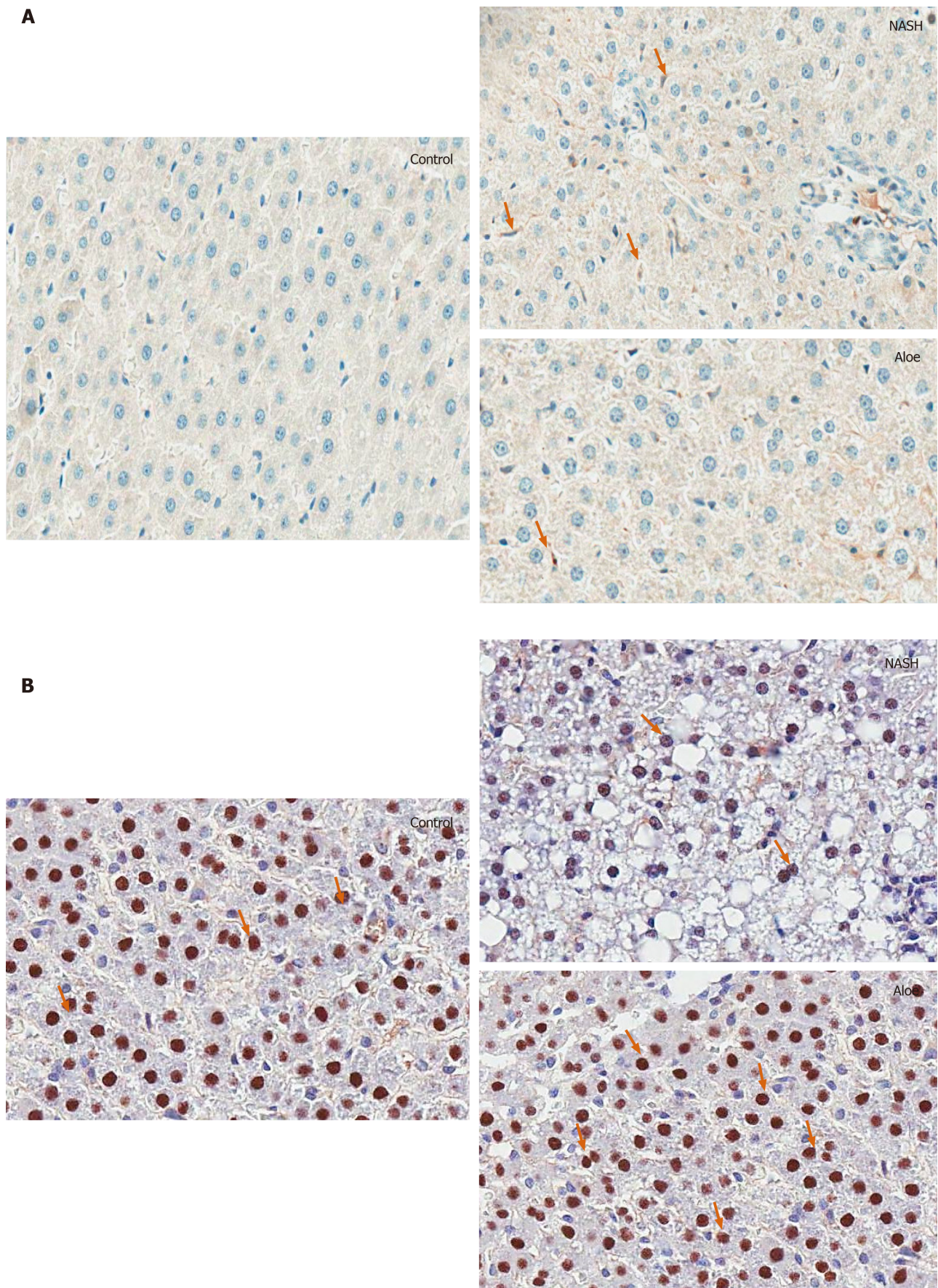


Figure 5 Representative images on light microscopy using immunohistochemistry stains for IL-18 and PPAR- γ . A: IL-18; B: PPAR- γ . Control groups are presented on the left column; non-alcoholic steatohepatitis group in the middle and aloe vera group on the right column. Arrowheads point to positive cells. NASH: Non-alcoholic steatohepatitis.

studies are needed to determine cellular and subcellular targets of aloe vera.

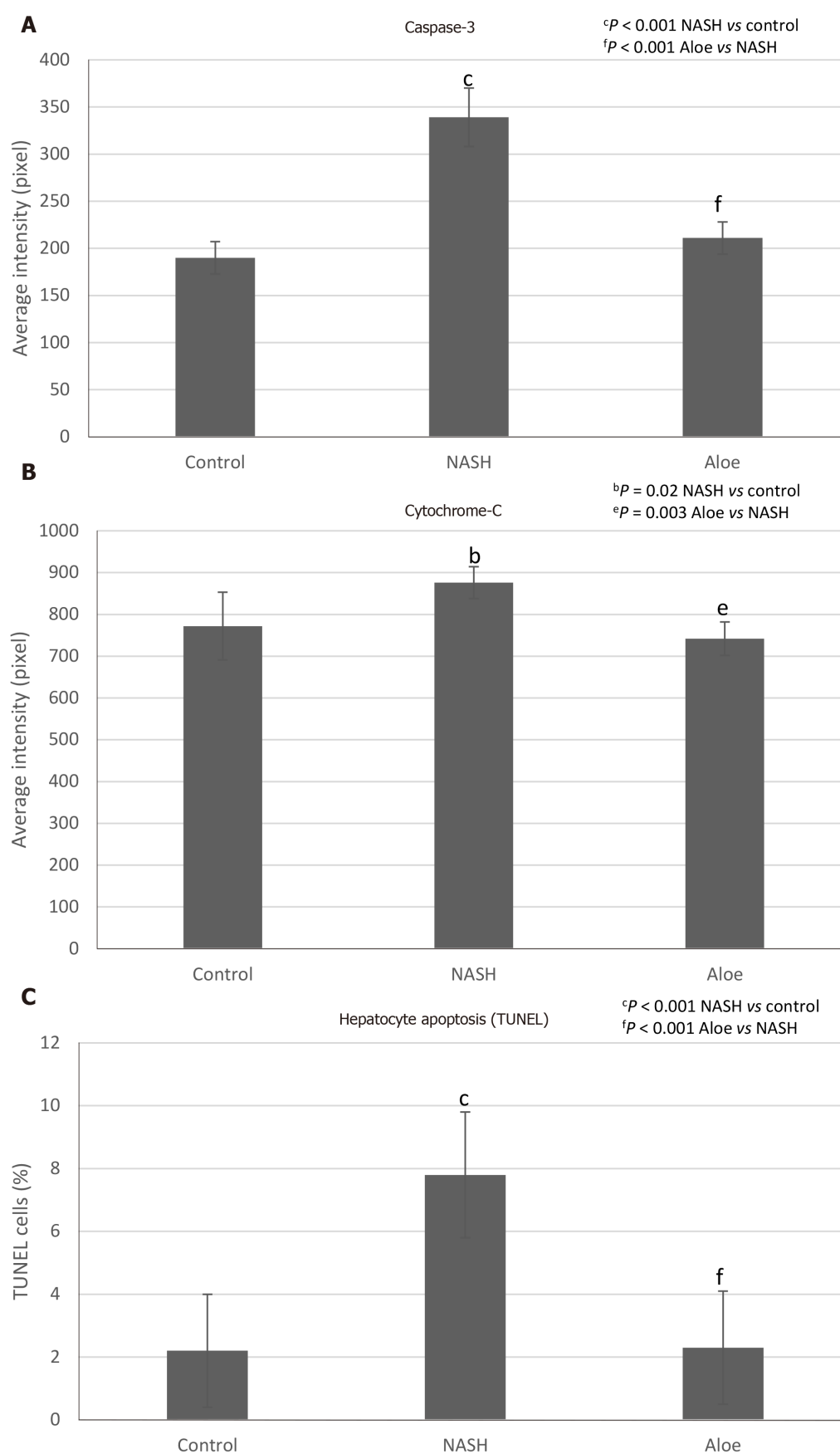


Figure 6 The expression of caspase-3 and cytochrome-C using immunohistochemistry methods, and the degree of hepatocyte apoptosis using terminal deoxynucleotidyl transferase dUTP nick end labeling methods. A: Caspase-3; B: Cytochrome-C; C: Degree of hepatocyte apoptosis. The positive cells were counted by Aperio ImageScope software. Data are expressed as mean \pm SD. NASH: Non-alcoholic steatohepatitis; TUNEL: Terminal deoxynucleotidyl transferase dUTP nick end labeling.

In summary, aloe vera reduced lipid accumulation, oxidative stress, hepatic inflammation, hepatocyte apoptosis and histologic changes in this rat model of NASH.

ARTICLE HIGHLIGHTS

Research background

Non-alcoholic fatty liver disease (NAFLD) is one of the most common liver diseases worldwide. However, there is no Food and Drug Administration (FDA) approved medication for the treatment of NAFLD. Aloe vera has previously been shown to have anti-inflammatory and anti-oxidant properties, which might be beneficial in the treatment of NAFLD.

Research motivation

With the absence of FDA-approved treatment for NAFLD, we attempted to find a safe and effective treatment for NAFLD. Alternative medicines that are safe, effective and inexpensive are attractive options for the management of life-long diseases, such as non-alcoholic steatohepatitis (NASH).

Research objectives

The main objective of this study was to evaluate the effects of aloe vera on NASH development in an animal model.

Research methods

Rats were divided into 3 groups: Control, NASH [rats received high-fat high-fructose diet (HFHFD) to induce NASH pathology], and NASH + aloe vera. We compared liver histopathology, oxidative stress marker [malondialdehyde (MDA)], anti-oxidant level [glutathione (GSH)], inflammatory marker (IL-18), degree and markers of hepatocyte apoptosis [terminal deoxynucleotidyl transferase dUTP nick end labeling (TUNEL), caspase-3, cytochrome-C], and PPAR- γ expression among the three groups.

Research results

We found that by administering aloe vera along with HFHFD, we were able to significantly reduce the severity of NASH pathology in this animal model. In this study, aloe vera treatment increased the level of natural anti-oxidant (GSH), reduced oxidative stress (MDA) and inflammatory markers (IL-18), and decreased the degree of hepatocyte apoptosis (TUNEL). At the subcellular level, we also found that aloe vera increased the expression of PPAR- γ and reduced the expression of NF- κ B, caspase-3 and cytochrome-C.

Research conclusions

This is the first study to evaluate the effects of aloe vera in rats with NASH. We found that aloe vera reduced the severity of NASH pathology in rats that received HFHFD. We hypothesized that aloe vera exerted its treatment effects by reducing oxidative stress and inflammation in the liver.

Research perspectives

The rats in our model were lean, so our results might not be entirely applicable to obese NASH that is seen more commonly in humans. Further studies with an obese rat model are warranted to confirm the effects of aloe vera in those conditions. Moreover, we used aloe vera crude extract in this study. Additional studies will be needed to identify the active ingredients in aloe vera that have anti-NASH effects.

REFERENCES

- 1 Younossi Z, Anstee QM, Marietti M, Hardy T, Henry L, Eslam M, George J, Bugianesi E. Global burden of NAFLD and NASH: trends, predictions, risk factors and prevention. *Nat Rev Gastroenterol Hepatol* 2018; **15**: 11-20 [PMID: 28930295 DOI: 10.1038/nrgastro.2017.109]
- 2 Noureddin M, Vipani A, Bresee C, Todo T, Kim IK, Alkhouri N, Setiawan VW, Tran T, Ayoub WS, Lu SC, Klein AS, Sundaram V, Nissen NN. NASH Leading Cause of Liver Transplant in Women: Updated Analysis of Indications For Liver Transplant and Ethnic and Gender Variances. *Am J Gastroenterol* 2018; **113**: 1649-1659 [PMID: 29880964 DOI: 10.1038/s41395-018-0088-6]
- 3 Ekstedt M, Nasr P, Kechagias S. Natural History of NAFLD/NASH. *Curr Hepatol Rep* 2017;

- 16: 391-397 [PMID: [29984130](#) DOI: [10.1007/s11901-017-0378-2](#)]
- 4 **Ong JP**, Younossi ZM. Epidemiology and natural history of NAFLD and NASH. *Clin Liver Dis* 2007; **11**: 1-16, vii [PMID: [17544968](#) DOI: [10.1016/j.cld.2007.02.009](#)]
- 5 **Rahmani AH**, Aldebasi YH, Srikar S, Khan AA, Aly SM. Aloe vera: Potential candidate in health management via modulation of biological activities. *Pharmacogn Rev* 2015; **9**: 120-126 [PMID: [26392709](#) DOI: [10.4103/0973-7847.162118](#)]
- 6 **Rajeswari R**, Umadevi M, Sharmila Rahale C, Pushpa R, Selvavenkadesh S, Sampath Kumar KP, Bhowmik D. Aloe vera: The Miracle Plant Its Medicinal and Traditional Uses in India. *J Pharm Phytochem* 2012; **1**: 118-124
- 7 **Surjushe A**, Vasani R, Saple DG. Aloe vera: a short review. *Indian J Dermatol* 2008; **53**: 163-166 [PMID: [19882025](#) DOI: [10.4103/0019-5154.44785](#)]
- 8 **Foster M**, Hunter D, Samman S, Benzie IFF, Wachtel-Galor S. Evaluation of the Nutritional and Metabolic Effects of Aloe vera. In: *Herbal Medicine: Biomolecular and Clinical Aspects*. 2nd edition. Herbal Medicine: Biomolecular and Clinical Aspects. Boca Raton (FL): CRC Press/Taylor & Francis; 2011 [PMID: [22593933](#) DOI: [10.1201/b10787-4](#)]
- 9 **Werawatganon D**, Linlawan S, Thanapirom K, Somanawat K, Klaikew N, Rerknimitr R, Siriviriyakul P. Aloe vera attenuated liver injury in mice with acetaminophen-induced hepatitis. *BMC Complement Altern Med* 2014; **14**: 229 [PMID: [25005608](#) DOI: [10.1186/1472-6882-14-229](#)]
- 10 **Shin E**, Shim KS, Kong H, Lee S, Shin S, Kwon J, Jo TH, Park YI, Lee CK, Kim K. Dietary Aloe Improves Insulin Sensitivity via the Suppression of Obesity-induced Inflammation in Obese Mice. *Immune Netw* 2011; **11**: 59-67 [PMID: [21494375](#) DOI: [10.4110/in.2011.11.1.59](#)]
- 11 **Rajasekaran S**, Ravi K, Sivagnanam K, Subramanian S. Beneficial effects of aloe vera leaf gel extract on lipid profile status in rats with streptozotocin diabetes. *Clin Exp Pharmacol Physiol* 2006; **33**: 232-237 [PMID: [16487267](#) DOI: [10.1111/j.1440-1681.2006.04351.x](#)]
- 12 **Brunt EM**, Janney CG, Di Bisceglie AM, Neuschwander-Tetri BA, Bacon BR. Nonalcoholic steatohepatitis: a proposal for grading and staging the histological lesions. *Am J Gastroenterol* 1999; **94**: 2467-2474 [PMID: [10484010](#) DOI: [10.1111/j.1572-0241.1999.01377.x](#)]
- 13 **Chen Z**, Yu R, Xiong Y, Du F, Zhu S. A vicious circle between insulin resistance and inflammation in nonalcoholic fatty liver disease. *Lipids Health Dis* 2017; **16**: 203 [PMID: [29037210](#) DOI: [10.1186/s12944-017-0572-9](#)]
- 14 **Fuchs M**, Sanyal AJ. Lipotoxicity in NASH. *J Hepatol* 2012; **56**: 291-293 [PMID: [21741924](#) DOI: [10.1016/j.jhep.2011.05.019](#)]
- 15 **Misawa E**, Tanaka M, Nomaguchi K, Nabeshima K, Yamada M, Toida T, Iwatsuki K. Oral ingestion of aloe vera phytosterols alters hepatic gene expression profiles and ameliorates obesity-associated metabolic disorders in Zucker diabetic fatty rats. *J Agric Food Chem* 2012; **60**: 2799-2806 [PMID: [22352711](#) DOI: [10.1021/jf204465j](#)]
- 16 **Nomaguchi K**, Tanaka M, Misawa E, Yamada M, Toida T, Iwatsuki K, Goto T, Kawada T. Aloe vera phytosterols act as ligands for PPAR and improve the expression levels of PPAR target genes in the livers of mice with diet-induced obesity. *Obes Res Clin Pract* 2011; **5**: e190-e201 [PMID: [24331101](#) DOI: [10.1016/j.orcp.2011.01.002](#)]
- 17 **Sumida Y**, Niki E, Naito Y, Yoshikawa T. Involvement of free radicals and oxidative stress in NAFLD/NASH. *Free Radic Res* 2013; **47**: 869-880 [PMID: [24004441](#) DOI: [10.3109/10715762.2013.837577](#)]
- 18 **Videla LA**, Rodrigo R, Orellana M, Fernandez V, Tapia G, Quiñones L, Varela N, Contreras J, Lazarte R, Csendes A, Rojas J, Maluenda F, Burdiles P, Diaz JC, Smok G, Thielemann L, Ponichik J. Oxidative stress-related parameters in the liver of non-alcoholic fatty liver disease patients. *Clin Sci (Lond)* 2004; **106**: 261-268 [PMID: [14556645](#) DOI: [10.1042/cs20030285](#)]
- 19 **Li S**, Tan HY, Wang N, Zhang ZJ, Lao L, Wong CW, Feng Y. The Role of Oxidative Stress and Antioxidants in Liver Diseases. *Int J Mol Sci* 2015; **16**: 26087-26124 [PMID: [26540040](#) DOI: [10.3390/ijms161125942](#)]
- 20 **Rajasekaran S**, Sivagnanam K, Subramanian S. Antioxidant effect of Aloe vera gel extract in streptozotocin-induced diabetes in rats. *Pharmacol Rep* 2005; **57**: 90-96 [PMID: [15849382](#)]
- 21 **Zhao CY**, Jiang LL, Li L, Deng ZJ, Liang BL, Li JM. Peroxisome proliferator activated receptor-gamma in pathogenesis of experimental fatty liver disease. *World J Gastroenterol* 2004; **10**: 1329-1332 [PMID: [15112352](#) DOI: [10.3748/wjg.v10.i9.1329](#)]
- 22 **Wu CW**, Chu ES, Lam CN, Cheng AS, Lee CW, Wong VW, Sung JJ, Yu J. PPARgamma is essential for protection against nonalcoholic steatohepatitis. *Gene Ther* 2010; **17**: 790-798 [PMID: [20376096](#) DOI: [10.1038/gt.2010.41](#)]
- 23 **Everett L**, Galli A, Crabb D. The role of hepatic peroxisome proliferator-activated receptors (PPARs) in health and disease. *Liver* 2000; **20**: 191-199 [PMID: [10902968](#) DOI: [10.1034/j.1600-0676.2000.020003191.x](#)]
- 24 **Marra F**, Efsen E, Romanelli RG, Caligiuri A, Pastacaldi S, Batignani G, Bonacchi A, Caporale R, Laffi G, Pinzani M, Gentilini P. Ligands of peroxisome proliferator-activated receptor gamma modulate profibrogenic and proinflammatory actions in hepatic stellate cells. *Gastroenterology* 2000; **119**: 466-478 [PMID: [10930382](#) DOI: [10.1053/gast.2000.9365](#)]
- 25 **Feldstein AE**, Gores GJ. Apoptosis in alcoholic and nonalcoholic steatohepatitis. *Front Biosci* 2005; **10**: 3093-3099 [PMID: [15970563](#) DOI: [10.2741/1765](#)]
- 26 **Alkhoury N**, Carter-Kent C, Feldstein AE. Apoptosis in nonalcoholic fatty liver disease: diagnostic and therapeutic implications. *Expert Rev Gastroenterol Hepatol* 2011; **5**: 201-212 [PMID: [21476915](#) DOI: [10.1586/egh.11.6](#)]
- 27 **Mari M**, Caballero F, Colell A, Morales A, Caballeria J, Fernandez A, Enrich C, Fernandez-Checa JC, Garcia-Ruiz C. Mitochondrial free cholesterol loading sensitizes to TNF- and Fas-mediated steatohepatitis. *Cell Metab* 2006; **4**: 185-198 [PMID: [16950136](#) DOI: [10.1016/j.cmet.2006.07.006](#)]
- 28 **Thapaliya S**, Wree A, Povero D, Inzaugarat ME, Berk M, Dixon L, Papouchado BG, Feldstein AE. Caspase 3 inactivation protects against hepatic cell death and ameliorates fibrogenesis in a diet-induced NASH

- model. *Dig Dis Sci* 2014; **59**: 1197-1206 [PMID: [24795036](#) DOI: [10.1007/s10620-014-3167-6](#)]
- 29 **Dinareello CA.** Interleukin-18. *Methods* 1999; **19**: 121-132 [PMID: [10525448](#) DOI: [10.1006/meth.1999.0837](#)]
- 30 **Netea MG,** Joosten LA, Lewis E, Jensen DR, Voshol PJ, Kullberg BJ, Tack CJ, van Krieken H, Kim SH, Stalenhoe AF, van de Loo FA, Verschuere I, Pulawa L, Akira S, Eckel RH, Dinareello CA, van den Berg W, van der Meer JW. Deficiency of interleukin-18 in mice leads to hyperphagia, obesity and insulin resistance. *Nat Med* 2006; **12**: 650-656 [PMID: [16732281](#) DOI: [10.1038/nm1415](#)]
- 31 **Yamanishi K,** Maeda S, Kuwahara-Otani S, Watanabe Y, Yoshida M, Ikubo K, Okuzaki D, El-Darawish Y, Li W, Nakasho K, Nojima H, Yamanishi H, Hayakawa T, Okamura H, Matsunaga H. Interleukin-18-deficient mice develop dyslipidemia resulting in nonalcoholic fatty liver disease and steatohepatitis. *Transl Res* 2016; **173**: 101-114.e7 [PMID: [27063959](#) DOI: [10.1016/j.trsl.2016.03.010](#)]
- 32 **Henao-Mejia J,** Elinav E, Jin C, Hao L, Mehal WZ, Strowig T, Thaiss CA, Kau AL, Eisenbarth SC, Jurczak MJ, Camporez JP, Shulman GI, Gordon JI, Hoffman HM, Flavell RA. Inflammasome-mediated dysbiosis regulates progression of NAFLD and obesity. *Nature* 2012; **482**: 179-185 [PMID: [22297845](#) DOI: [10.1038/nature10809](#)]
- 33 **Vecchiet J,** Falasca K, Cacciatore P, Zingariello P, Dalessandro M, Marinopicolli M, D'Amico E, Palazzi C, Petrarca C, Conti P, Pizzigallo E, Guagnano MT. Association between plasma interleukin-18 levels and liver injury in chronic hepatitis C virus infection and non-alcoholic fatty liver disease. *Ann Clin Lab Sci* 2005; **35**: 415-422 [PMID: [16254258](#) DOI: [10.1097/01.fld.0000175910.68539.33](#)]
- 34 **Flisiak-Jackiewicz M,** Bobrus-Chociej A, Tarasów E, Wojtkowska M, Białokoz-Kalinowska I, Lebensztejn DM. Predictive Role of Interleukin-18 in Liver Steatosis in Obese Children. *Can J Gastroenterol Hepatol* 2018; **2018**: 3870454 [PMID: [29854715](#) DOI: [10.1155/2018/3870454](#)]
- 35 **Finotto S,** Siebler J, Hausding M, Schipp M, Wirtz S, Klein S, Protschka M, Doganci A, Lehr HA, Trautwein C, Khosravi-Far R, Strand D, Lohse A, Galle PR, Blessing M, Neurath MF. Severe hepatic injury in interleukin 18 (IL-18) transgenic mice: a key role for IL-18 in regulating hepatocyte apoptosis in vivo. *Gut* 2004; **53**: 392-400 [PMID: [14960523](#) DOI: [10.1136/gut.2003.018572](#)]
- 36 **Lozano I,** Van der Werf R, Bietiger W, Seyfritz E, Peronet C, Pinget M, Jeandidier N, Maillard E, Marchioni E, Sigrist S, Dal S. High-fructose and high-fat diet-induced disorders in rats: impact on diabetes risk, hepatic and vascular complications. *Nutr Metab (Lond)* 2016; **13**: 15 [PMID: [26918024](#) DOI: [10.1186/s12986-016-0074-1](#)]
- 37 **Jensen VS,** Hvid H, Damgaard J, Nygaard H, Ingvorsen C, Wulff EM, Lykkesfeldt J, Fledelius C. Dietary fat stimulates development of NAFLD more potently than dietary fructose in Sprague-Dawley rats. *Diabetol Metab Syndr* 2018; **10**: 4 [PMID: [29410708](#) DOI: [10.1186/s13098-018-0307-8](#)]
- 38 **Kucera O,** Cervinkova Z. Experimental models of non-alcoholic fatty liver disease in rats. *World J Gastroenterol* 2014; **20**: 8364-8376 [PMID: [25024595](#) DOI: [10.3748/wjg.v20.i26.8364](#)]
- 39 **Veteläinen R,** van Vliet A, van Gulik TM. Essential pathogenic and metabolic differences in steatosis induced by choline or methionine-choline deficient diets in a rat model. *J Gastroenterol Hepatol* 2007; **22**: 1526-1533 [PMID: [17716355](#) DOI: [10.1111/j.1440-1746.2006.04701.x](#)]
- 40 **George J,** Pera N, Phung N, Leclercq I, Yun Hou J, Farrell G. Lipid peroxidation, stellate cell activation and hepatic fibrogenesis in a rat model of chronic steatohepatitis. *J Hepatol* 2003; **39**: 756-764 [PMID: [14568258](#) DOI: [10.1016/S0168-8278\(03\)00376-3](#)]
- 41 **Yang SC,** Lin SH, Chang JS, Chien YW. High Fat Diet with a High Monounsaturated Fatty Acid and Polyunsaturated/Saturated Fatty Acid Ratio Suppresses Body Fat Accumulation and Weight Gain in Obese Hamsters. *Nutrients* 2017; **9**: 1148 [PMID: [29048361](#) DOI: [10.3390/nu9101148](#)]
- 42 **Piers LS,** Walker KZ, Stoney RM, Soares MJ, O'Dea K. The influence of the type of dietary fat on postprandial fat oxidation rates: monounsaturated (olive oil) vs saturated fat (cream). *Int J Obes Relat Metab Disord* 2002; **26**: 814-821 [PMID: [12037652](#) DOI: [10.1038/sj.ijo.0801993](#)]
- 43 **Piers LS,** Walker KZ, Stoney RM, Soares MJ, O'Dea K. Substitution of saturated with monounsaturated fat in a 4-week diet affects body weight and composition of overweight and obese men. *Br J Nutr* 2003; **90**: 717-727 [PMID: [13129479](#) DOI: [10.1079/BJN2003948](#)]
- 44 **Lawton CL,** Delargy HJ, Brockman J, Smith FC, Blundell JE. The degree of saturation of fatty acids influences post-ingestive satiety. *Br J Nutr* 2000; **83**: 473-482 [PMID: [10953671](#) DOI: [10.1017/S000711450000060X](#)]



Published by **Baishideng Publishing Group Inc**
7041 Koll Center Parkway, Suite 160, Pleasanton, CA 94566, USA

Telephone: +1-925-3991568

E-mail: bpgoffice@wjgnet.com

Help Desk: <https://www.f6publishing.com/helpdesk>

<https://www.wjgnet.com>

