

World Journal of *Clinical Cases*

World J Clin Cases 2020 June 26; 8(12): 2408-2673



**REVIEW**

- 2408** Assessment of diaphragmatic function by ultrasonography: Current approach and perspectives
Boussuges A, Rives S, Finance J, Brégeon F
- 2425** Mechanisms of resveratrol in the prevention and treatment of gastrointestinal cancer
Wang LY, Zhao S, Lv GJ, Ma XJ, Zhang JB

MINIREVIEWS

- 2438** Clinical benefits of rational-emotive stress management therapy for job burnout and dysfunctional distress of special education teachers
Onuigbo LN, Onyishi CN, Eseadi C
- 2448** Functions and mechanisms of chemokine receptor 7 in tumors of the digestive system
Xin Q, Sun Q, Zhang CS, Zhang Q, Li CJ
- 2464** Computer navigation-assisted minimally invasive percutaneous screw placement for pelvic fractures
Yu T, Cheng XL, Qu Y, Dong RP, Kang MY, Zhao JW

ORIGINAL ARTICLE**Case Control Study**

- 2473** Elevated serum growth differentiation factor 15 in multiple system atrophy patients: A case control study
Yue T, Lu H, Yao XM, Du X, Wang LL, Guo DD, Liu YM

Retrospective Study

- 2484** Research on diagnosis-related group grouping of inpatient medical expenditure in colorectal cancer patients based on a decision tree model
Wu SW, Pan Q, Chen T
- 2494** Clinical outcomes of sacral neuromodulation in non-neurogenic, non-obstructive dysuria: A 5-year retrospective, multicentre study in China
Meng LF, Zhang W, Wang JY, Zhang YG, Zhang P, Liao LM, Lv JW, Ling Q, Wei ZQ, Zhong T, Xu ZH, Wen W, Li JY, Luo DY
- 2502** Magnetic resonance imaging features of minimal-fat angiomyolipoma and causes of preoperative misdiagnosis
Li XL, Shi LX, Du QC, Wang W, Shao LW, Wang YW
- 2510** Evaluation of internal and shell stiffness in the differential diagnosis of breast non-mass lesions by shear wave elastography
Xu P, Wu M, Yang M, Xiao J, Ruan ZM, Wu LY

Observational Study

- 2520** Recovery from prolonged disorders of consciousness: A dual-center prospective cohort study in China
Chen WG, Li R, Zhang Y, Hao JH, Du JB, Guo AS, Song WQ
- 2530** Gene testing for osteonecrosis of the femoral head in systemic lupus erythematosus using targeted next-generation sequencing: A pilot study
Sun HS, Yang QR, Bai YY, Hu NW, Liu DX, Qin CY
- 2542** Real-time three-dimensional echocardiography predicts cardiotoxicity induced by postoperative chemotherapy in breast cancer patients
Zhou F, Niu L, Zhao M, Ni WX, Liu J

Prospective Study

- 2554** Epidemiological and clinical characteristics of COVID-19 patients in Hengyang, Hunan Province, China
Zhong ZF, Huang J, Yang X, Peng JL, Zhang XY, Hu Y, Fu N, Lin HL, Jiang B, Tian YY, Yao HY, Deng LP, Tang XQ, Zhou JC, Tang J, Xie X, Liu Q, Liu J, Dou CY, Dai RJ, Yan B, Yang XF

CASE REPORT

- 2566** Demyelinating polyneuropathy and lymphoplasmacytic lymphoma coexisting in 36-year-old man: A case report
Rozlucka L, Semik-Grabarczyk E, Pietrukaniec M, Żak-Golqb A, Grabarczyk M, Grosicki S, Holecki M
- 2574** Lenvatinib for large hepatocellular carcinomas with portal trunk invasion: Two case reports
Komiyama S, Numata K, Moriya S, Fukuda H, Chuma M, Maeda S
- 2585** Biopsy-proven acute phosphate nephropathy: A case report
Medina-Liabres KRP, Kim BM, Kim S
- 2590** Endodontic management of the maxillary first molar with special root canals: A case report and review of the literature
Zhang ZH, Yao HL, Zhang Y, Wang X
- 2597** Novel approach for the diagnosis of occult cytomegalovirus cholangitis after pediatric liver transplantation: A case report
Liu Y, Sun LY, Zhu ZJ, Qu W
- 2603** Anti-N-methyl-D-aspartate-receptor antibody encephalitis combined with syphilis: A case report
Li XY, Shi ZH, Guan YL, Ji Y
- 2610** Collision tumor of squamous cell carcinoma and neuroendocrine carcinoma in the head and neck: A case report
Wu SH, Zhang BZ, Han L

- 2617** Successful treatment of plasma exchange-refractory thrombotic thrombocytopenic purpura with rituximab: A case report
Chen J, Jin JX, Xu XF, Zhang XX, Ye XN, Huang J
- 2623** Ovarian endometrioid carcinoma resembling sex cord-stromal tumor: A case report
Wei XX, He YM, Jiang W, Li L
- 2629** Headache and sick sinus syndrome: A case report
Bi YC, Gong L
- 2634** Modified pararectus approach for treatment of atypical acetabular anterior wall fracture: A case report
Wang JJ, Ni JD, Song DY, Ding ML, Huang J, He GX, Li WZ
- 2641** Pleomorphic rhabdomyosarcoma of the spermatic cord and a secondary hydrocele testis: A case report
Chen X, Zou C, Yang C, Gao L, Bi LK, Xie DD, Yu DX
- 2647** Comprehensive treatment of rare multiple endocrine neoplasia type 1: A case report
Ma CH, Guo HB, Pan XY, Zhang WX
- 2655** Low-grade fever during COVID-19 convalescence: A report of 3 cases
Zhuang SF, Hu J, Qiao N, Lan ZH, Lai JY, Wu JG, Wu XY
- 2662** Diffuse alveolar hemorrhage with histopathologic manifestations of pulmonary capillaritis: Three case reports
Xie J, Zhao YY, Liu J, Nong GM
- 2667** Presentation of gallbladder torsion at an abnormal position: A case report
Chai JS, Wang X, Li XZ, Yao P, Yan ZZ, Zhang HJ, Ning JY, Cao YB

ABOUT COVER

Editorial Board Member of *World Journal of Clinical Cases*, Marco Fiore, MD, MSc, Doctor, Research Scientist, Department of Women, Child and General and Specialized Surgery, University of Campania "Luigi Vanvitelli", Naples 80138, Italy

AIMS AND SCOPE

The primary aim of *World Journal of Clinical Cases* (WJCC, *World J Clin Cases*) is to provide scholars and readers from various fields of clinical medicine with a platform to publish high-quality clinical research articles and communicate their research findings online.

WJCC mainly publishes articles reporting research results and findings obtained in the field of clinical medicine and covering a wide range of topics, including case control studies, retrospective cohort studies, retrospective studies, clinical trials studies, observational studies, prospective studies, randomized controlled trials, randomized clinical trials, systematic reviews, meta-analysis, and case reports.

INDEXING/ABSTRACTING

The WJCC is now indexed in PubMed, PubMed Central, Science Citation Index Expanded (also known as SciSearch®), and Journal Citation Reports/Science Edition. The 2019 Edition of Journal Citation Reports cites the 2018 impact factor for WJCC as 1.153 (5-year impact factor: N/A), ranking WJCC as 99 among 160 journals in Medicine, General and Internal (quartile in category Q3).

RESPONSIBLE EDITORS FOR THIS ISSUE

Responsible Electronic Editor: Ji-Hong Liu

Proofing Production Department Director: Xiang Li

Responsible Editorial Office Director: Jin-Lai Wang

NAME OF JOURNAL

World Journal of Clinical Cases

ISSN

ISSN 2307-8960 (online)

LAUNCH DATE

April 16, 2013

FREQUENCY

Semimonthly

EDITORS-IN-CHIEF

Dennis A Bloomfield, Bao-Gan Peng, Sandro Vento

EDITORIAL BOARD MEMBERS

<https://www.wjnet.com/2307-8960/editorialboard.htm>

PUBLICATION DATE

June 26, 2020

COPYRIGHT

© 2020 Baishideng Publishing Group Inc

INSTRUCTIONS TO AUTHORS

<https://www.wjnet.com/bpg/gerinfo/204>

GUIDELINES FOR ETHICS DOCUMENTS

<https://www.wjnet.com/bpg/GerInfo/287>

GUIDELINES FOR NON-NATIVE SPEAKERS OF ENGLISH

<https://www.wjnet.com/bpg/gerinfo/240>

PUBLICATION ETHICS

<https://www.wjnet.com/bpg/GerInfo/288>

PUBLICATION MISCONDUCT

<https://www.wjnet.com/bpg/gerinfo/208>

ARTICLE PROCESSING CHARGE

<https://www.wjnet.com/bpg/gerinfo/242>

STEPS FOR SUBMITTING MANUSCRIPTS

<https://www.wjnet.com/bpg/GerInfo/239>

ONLINE SUBMISSION

<https://www.f6publishing.com>

Modified pararectus approach for treatment of atypical acetabular anterior wall fracture: A case report

Jun-Jie Wang, Jiang-Dong Ni, De-Ye Song, Mu-Liang Ding, Jun Huang, Guang-Xu He, Wen-Zhao Li

ORCID number: Jun-Jie Wang (0000-0002-9412-1043); Jiang-Dong Ni (0000-0001-6196-0185); De-Ye Song (0000-0002-5522-3098); Mu-Liang Ding (0000-0002-4927-2766); Jun Huang (0000-0001-8714-483X); Guang-Xu He (0000-0003-4084-8252); Wen-Zhao Li (0000-0002-4144-4025).

Author contributions: Wang JJ, Ni JD, Song DY, and He GX performed the surgery and wrote the paper; Wang JJ, Ding ML, and Huang J collected the information and followed the patient; Song DY and Li WZ revised the paper; all authors read and approved the final manuscript.

Supported by the Xiangya Famous Doctors of Central South University, No. 201468.

Informed consent statement: The patient provided informed written consent about personal and medical data collection prior to study enrolment.

Conflict-of-interest statement: The authors declare that they have no conflict of interest.

CARE Checklist (2016) statement: The authors have read the CARE Checklist (2016), and the manuscript was prepared and revised according to the CARE Checklist (2016).

Open-Access: This article is an open-access article that was selected by an in-house editor and fully peer-reviewed by external reviewers. It is distributed in accordance with the Creative Commons Attribution

Jun-Jie Wang, Jiang-Dong Ni, De-Ye Song, Mu-Liang Ding, Jun Huang, Guang-Xu He, Wen-Zhao Li, Department of Orthopedics, The Second Xiangya Hospital of Central South University, Changsha 410011, Hunan Province, China

Corresponding author: De-Ye Song, MD, Chief Doctor, Professor, Department of Orthopedics, The Second Xiangya Hospital of Central South University, No. 139, Middle Renmin Road, Changsha 410011, Hunan Province, China. songdeye@csu.edu.cn

Abstract

BACKGROUND

Acetabular anterior wall fracture with preservation of the pelvic brim is extremely rare. It is different from anterior wall fracture classified by Judet and Letournel. Few studies have reported cases treated by open reduction and internal fixation *via* the Smith-Petersen or iliofemoral approach.

CASE SUMMARY

We report a 48-year-old Chinese woman who had difficulty moving her right hip from abduction and external rotation after falling from 3 m. Pelvic radiograph and three-dimensional reconstruction of computed tomography revealed acetabular anterior wall fractures combined with fractures of the anterior inferior iliac spine and the iliac wing but not involving the pelvic brim. First, the patient underwent interim management by closed reduction of the hip dislocation and skin traction for 6 d. Then, we used a modified pararectus approach for treatment to fix the acetabular fractures with a reconstruction plate and nonlocking T-shape plate. At the 9-mo follow-up, the patient could walk painlessly without necrosis of the femoral head or heterotopic ossification, and the X-rays and computed tomography scan reconstructions showed good bone union.

CONCLUSION

The modified pararectus approach described here can facilitate exposure, reduction, and osteosynthesis for atypical acetabular fracture with less invasiveness.

Key words: Acetabulum; Fracture; Modified; Pararectus approach; Case report

©The Author(s) 2020. Published by Baishideng Publishing Group Inc. All rights reserved.

Core tip: Acetabular anterior wall fracture without involvement of the pelvic brim is extremely rare. We present a case about the surgical outcome of a patient with atypical

NonCommercial (CC BY-NC 4.0) license, which permits others to distribute, remix, adapt, build upon this work non-commercially, and license their derivative works on different terms, provided the original work is properly cited and the use is non-commercial. See: <http://creativecommons.org/licenses/by-nc/4.0/>

Manuscript source: Unsolicited manuscript

Received: March 7, 2020

Peer-review started: March 7, 2020

First decision: April 22, 2020

Revised: May 14, 2020

Accepted: May 26, 2020

Article in press: May 26, 2020

Published online: June 26, 2020

P-Reviewer: Aprato A

S-Editor: Zhang L

L-Editor: Wang TQ

E-Editor: Ma YJ



acetabular anterior wall fracture. The patient underwent open reduction and internal fixation *via* a modified pararectus approach that has not been reported. Follow-up X-ray and computed tomography scans showed satisfactory bone union. The function of the hip was excellent at the 9-mo follow-up after surgery.

Citation: Wang JJ, Ni JD, Song DY, Ding ML, Huang J, He GX, Li WZ. Modified pararectus approach for treatment of atypical acetabular anterior wall fracture: A case report. *World J Clin Cases* 2020; 8(12): 2634-2640

URL: <https://www.wjnet.com/2307-8960/full/v8/i12/2634.htm>

DOI: <https://dx.doi.org/10.12998/wjcc.v8.i12.2634>

INTRODUCTION

Before Judet *et al*^[1] and Letournel *et al*^[2] proposed and developed the classification and management of acetabular fracture in the late 20th century, acetabular fractures were treated inappropriately. According to the Judet-Letournel classification, the anterior wall fracture is a separation of the anterior wall of the articular surface, together with the corresponding segment of the iliopectineal line^[2]. However, lesions of the anterior wall with preservation of the pelvic brim were not included in the Judet-Letournel classification, but have been described by others^[3,4]. The morphology of the isolated anterior wall fracture is similar to that of the posterior wall fracture. But the anterior wall fracture without involvement of the pelvic brim is rare, so it is named atypical anterior wall fracture in some literature^[4]. In this type of acetabular fracture, there is always an extraarticular component of different sizes accompanying with the articular component, including the anterior inferior iliac spine (AIIS) and the interspinous region, and even the anterior superior iliac spine (ASIS) or iliac wing^[3,4].

Indications for surgical treatment of acetabular fracture are incongruent or unstable fractures with verified dislocation greater than 5 mm^[5]. The modified Smith-Peterson approach described by Judet *et al*^[1] is used for the treatment of anterior wall fracture^[3,4,5]. Several modifications of the Smith-Peterson approach have been introduced, with different osteotomies or muscle stripping for atypical anterior wall fracture^[4,6,7].

This report describes a rare acetabular anterior wall fracture with preservation of the pelvic brim, but consisting of the AIIS and iliac wing. A modified pararectus approach was used for therapeutic management and was successful in achieving a good outcome. The advantages accruing from this approach include minimal tissue damage and sufficient exposure of the osseous lesions.

CASE PRESENTATION

Chief complaints

A 48-year-old Chinese woman presented with difficulty moving her right hip from abduction and external rotation after falling from 3 m that occurred 3 d ago.

History of present illness

Due to right hip pain, the patient underwent an X-ray examination in the outpatient department and was diagnosed with "right acetabular fracture," after which she was admitted to the hospital.

Physical examination

The patient exhibited pain and external rotation of the right hip. Tenderness was present near the hip joint and movements were painful and limited. The neurovascular status was normal.

Imaging examination

Standard radiographs at admission revealed fractures of the right acetabular anterior wall in association with fractures of the AIIS and the iliac wing, with preservation of the pelvic brim (Figure 1). Computed tomography showed fractures of the acetabular anterior wall, the AIIS, and the iliac wing with retained integrity of the pelvic brim (Figure 1).

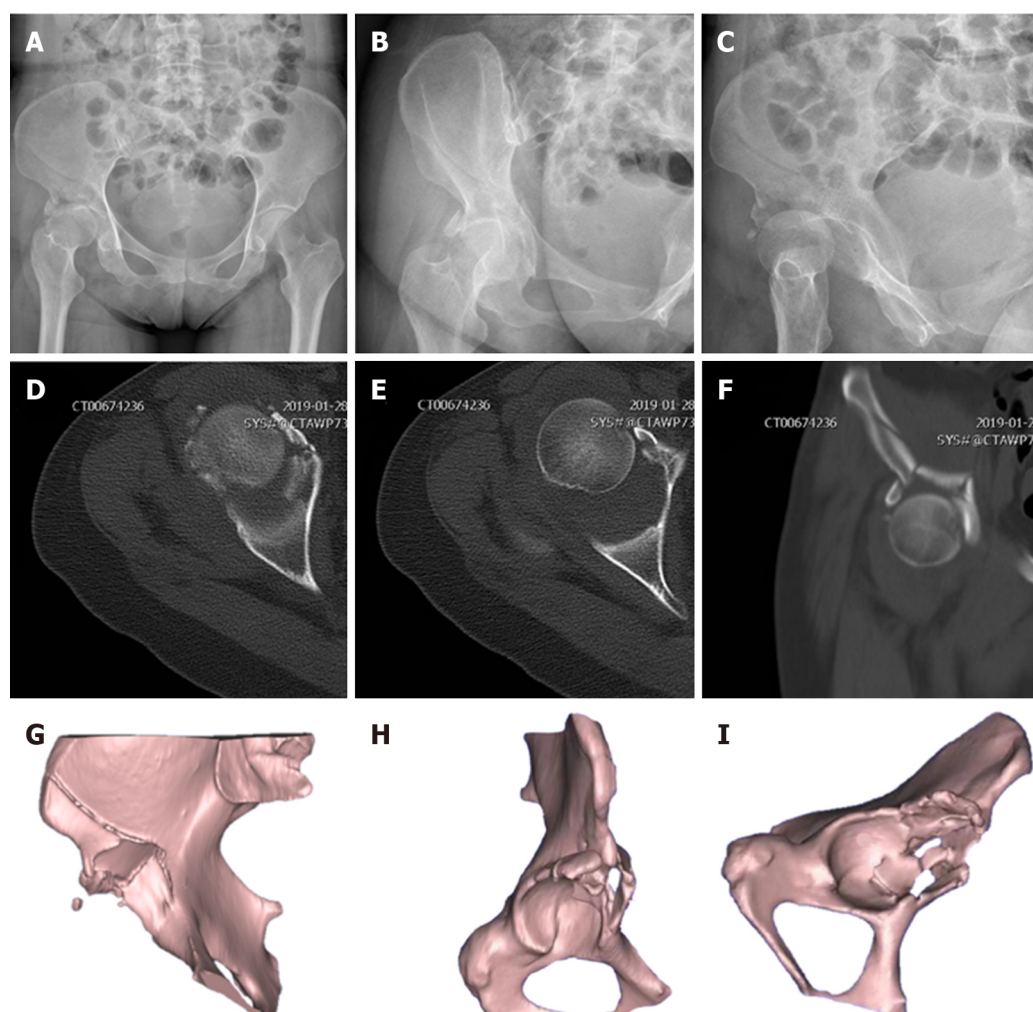


Figure 1 Preoperative plain radiographs and computed tomography scans. A: Anteroposterior view radiography; B: Obturator oblique view radiography; C: Iliac oblique view radiography; D and E: Axial computed tomography (CT) images; F: Coronal CT image; G-I: Three-dimensional reconstructed CT images.

Preoperative closed reduction and skin traction

The patient underwent interim management by closed reduction of the hip dislocation and skin traction for 6 d.

Preoperative diagnosis and treatment plan

For the treatment of right atypical acetabular anterior wall fracture and iliac fracture, open reduction and rigid internal fixation were performed *via* a modified pararectus approach under general anesthesia.

Surgical procedures

The surgery was performed on the 7th day following the traumatic injury. Under general anesthesia, the patient was placed supine on a radiolucent operating table and the ipsilateral leg was prepared and draped freely, facilitating reduction maneuvers. To reduce the tension of the iliopsoas muscle and protect the femoral nerve, hip joints were slightly flexed by putting a bump underneath both knees. In order to monitor potential iatrogenic bladder injury during surgery, a Foley catheter was placed in the bladder before surgery.

A modified pararectus approach was used, in which the skin incision was started from the junction of the medial and middle thirds of the line connecting the ASIS with the umbilicus to the junction of the middle and lateral thirds of the line connecting the symphysis with the ASIS, and extended distally-laterally to the AIIS (**Figure 2A**).

To facilitate exposure of the anterior layer of rectus sheath, the subcutaneous fatty tissue, fascia of Camper, fascia of Scarpa, and external oblique muscle aponeurosis were dissected. The incision of the anterior fascial layer of rectus sheath and the transversalis fascia was made to expose the extraperitoneal space in the true pelvis, with care taken to identify the round ligament and the inferior epigastric vessels. The expanded first window of pararectus approach^[8] was developed between the iliac

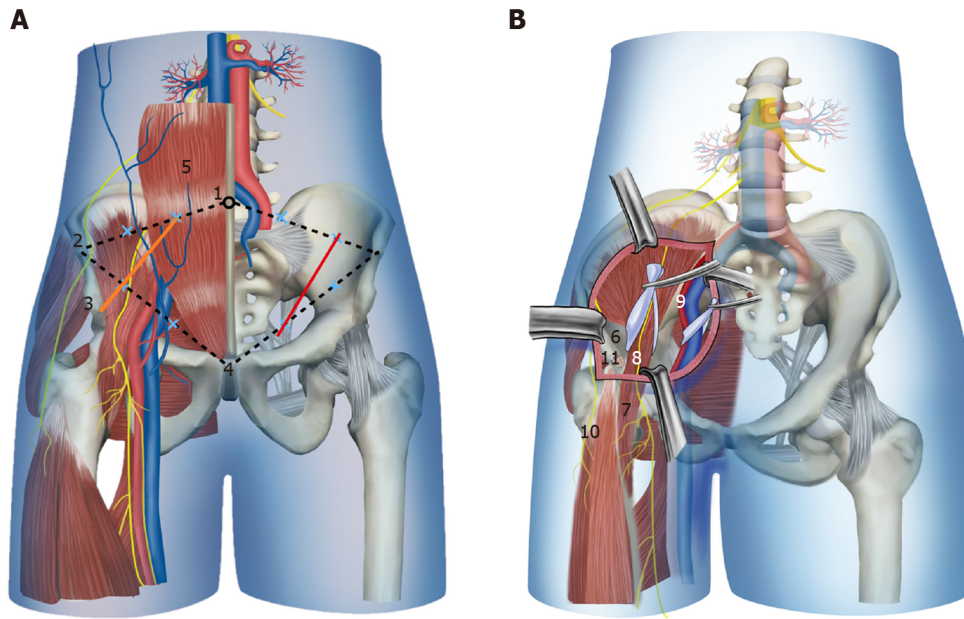


Figure 2 Schematic drawing demonstrating the skin incision and anatomic structures in the modified pararectus approach. A: Skin incision; B: Anatomic structures. Orange line: Modified pararectus approach; Red line: Pararectus approach; 1: Umbilicus; 2: Anterior superior iliac spine; 3: Anterior inferior iliac spine; 4: Symphysis; 5: Rectus abdominis; 6: Iliac fossa; 7: Iliopsoas muscle; 8: Femoral nerve; 9: External iliac vessels; 10: Lateral femoral cutaneous nerve; 11: Avulsion fracture of anterior inferior iliac spine.

crest and iliopsoas muscle by dissecting the iliacus muscle along the inner surface of the iliac crest and dragging it medially. By retracting the iliopsoas muscle laterally and the external iliac vessels medially, the second window^[8] was created. Through the expanded first and second windows, both the anterior wall and anterior column could be seen (Figure 2B).

Once the approach was complete, the fracture fragments were identified, namely, two main fragments of the anterior wall with superior extension of fracture above the iliopectineal line into iliac wing, and a fragment of AIIS that was attached by the direct head of the rectus femoris tendon. The reflected head of the rectus femoris tendon was released to allow mobilization of the fragment. Manual distraction was performed by placing a subtrochanteric Schanz screw parallel to the femoral neck, which was then used to visualize the joint after incision through the hip capsule, and the articular impaction was addressed.

The fracture fragments were anatomically reduced under direct visualization, and the cancellous bone void left beneath the elevated impacted fragments was filled with allograft. Interfragmentary lag screws were used to fix the AIIS and iliac wing. The fixation of anterior wall was achieved by using a nonlocking, precontoured, low-profile reconstruction plate and a nonlocking T-shape plate. The T-shape plate was situated near the border of the acetabulum, and was slightly under-bent to enable compressing and buttressing of the fragments. Intraoperative fluoroscopy was used to evaluate the reduction and position of the implants. The hip capsule and rectus release were repaired, and the anterior layer of rectus sheath, subcutaneous tissue, and skin were sutured sequentially. A suction drain was placed for 24 h.

Prophylactic intravenous antibiotic was used from 30 min before surgery to 24 h postoperatively. Rivaroxaban was employed for 5 wk as prophylaxis against deep venous thromboembolism. The patient was started on muscle strengthening as soon as medically possible but with restricted mobilization to toe-touch weight-bearing for the first 3 mo. The postoperative X-rays and computed tomography scans revealed good reduction of the fracture (Figure 3).

FINAL DIAGNOSIS

Right acetabular anterior wall fracture with preservation of the pelvic brim, associated with fracture of the AIIS and the iliac wing.

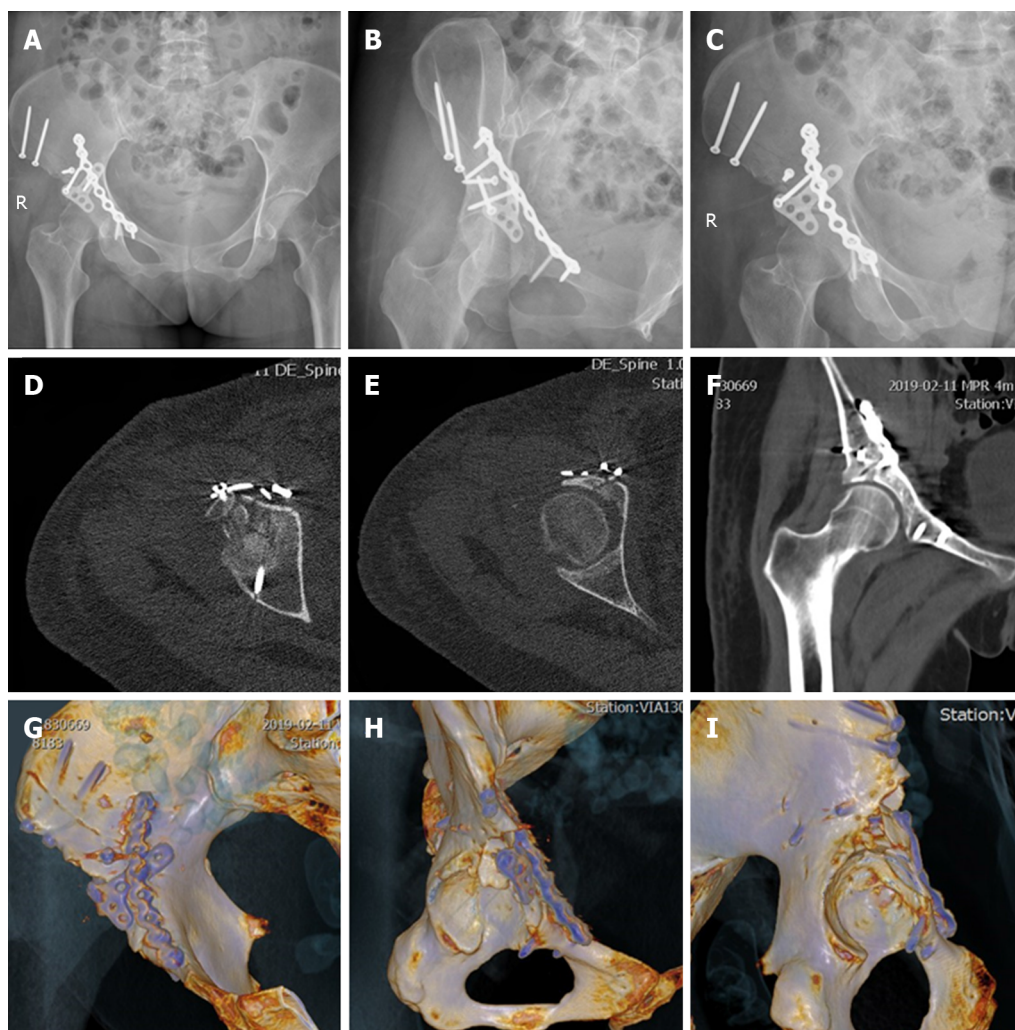


Figure 3 Postoperative plain radiographs and computed tomography scans. A: Anteroposterior view radiography; B: Obturator oblique view radiography; C: Iliac oblique view radiography; D and E: Axial computed tomography (CT) images; F: Coronal CT image; G-I: Three-dimensional reconstructed CT images.

TREATMENT

The patient was treated by open reduction and internal fixation with interfragmentary lag screws, reconstruction plate and T-shape plate *via* a modified pararectus approach.

OUTCOME AND FOLLOW-UP

The patient was followed monthly. At 9 mo postoperatively, an X-ray showed that the fracture lines were blurred. The patient was satisfied with the function of the injured hip (Figure 4).

DISCUSSION

Acetabular anterior wall fractures with preservation of the pelvic brim are very uncommon. As far as we know, there are only ten cases reported previously in the literature^[3,4,9]. Mirovsky *et al*^[9] reported an acetabular anterior wall fracture with anterior hip dislocation treated by hip arthroplasty in a 67-year-old woman. Badelon *et al*^[10] and Piriou *et al*^[3] reported three similar cases, but they were treated by open reduction and internal fixation. Lenarz *et al*^[4] reported a series of anterior acetabular fracture without involvement of the pelvic brim, and defined the special form of acetabular anterior wall fracture as atypical anterior wall fracture of the acetabulum.

Previously reported cases and the present case have common features. The lesions, in all cases, included the anterior wall of the acetabulum with preservation of the

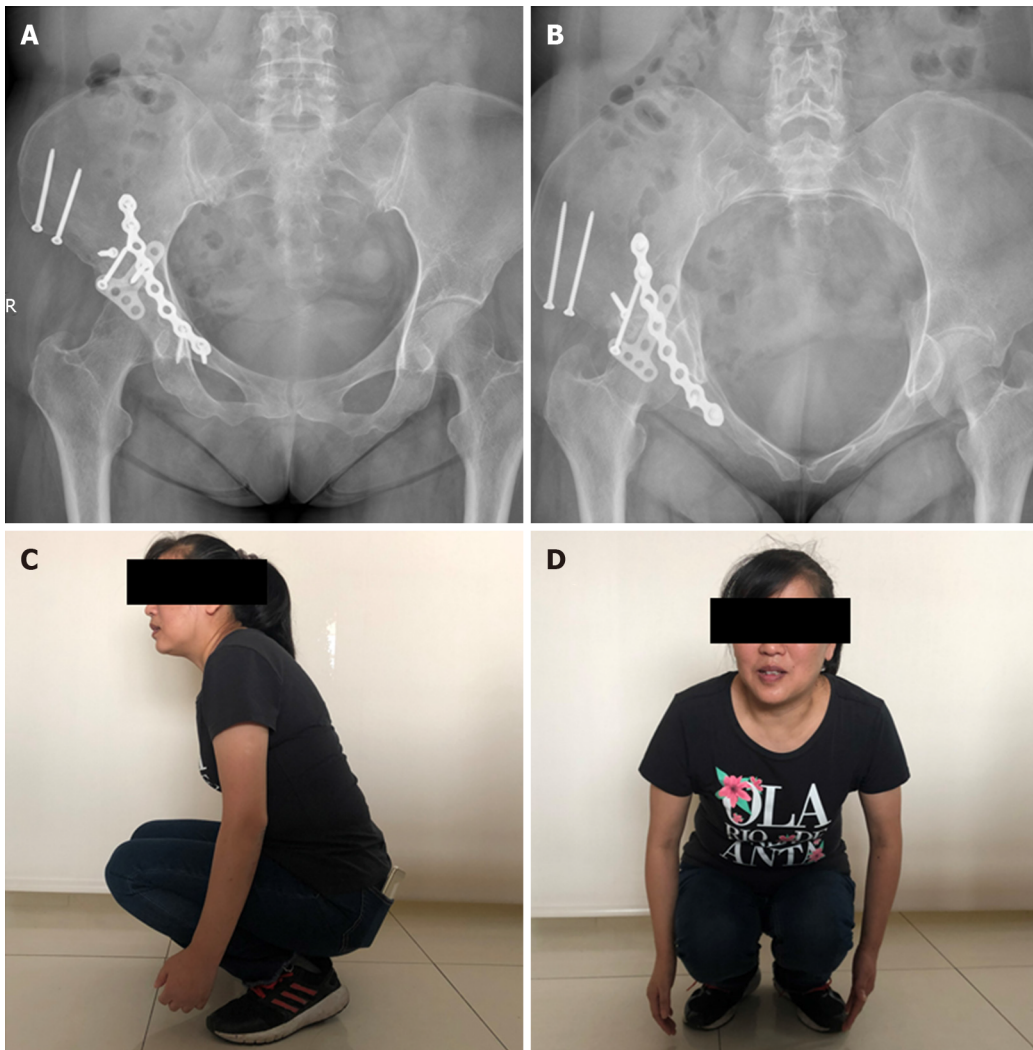


Figure 4 Postoperative X-rays and hip mobility at 9 mo. A: Anteroposterior view radiography; B: Inlet view radiography; C and D: Flexion of the hip with a full load.

pelvic brim, unlike the anterior wall fracture described in the Judet-Letournel classification. The anterosuperior part of the acetabulum, rather than the entire roof, was fractured, differing from the anterior wall fracture described in the Judet-Letournel classification^[2]. Furthermore, the fractures extended to the AIIS in all cases and even the interspinous region in some cases. The indications for surgical treatment of acetabular fracture are incongruent or unstable fractures with a dislocation verified to be greater than 5 mm^[5], so that no alternative treatment to surgery was considered in our case.

The operative approach should provide access to the anterior column, anterior wall, AIIS, and hip joint for direct reduction and osteosynthesis. According to Tannast's study about survivorship of the hip in 810 patients with operatively treated acetabular fractures, anterior wall fractures had the worst survivorship, which might be related to marginal impaction and nonanatomical articular reduction associated with limited exposure^[11]. Because the Smith-Petersen approach could provide exposure of the anterior column and wall extending from the inner table to the outer table, and a complete intra-articular view to judge reduction and address articular impaction^[6], it was employed for open reduction and rigid internal fixation in all of the nine cases previously reported. The ilioinguinal approach, which is often used as a recommended treatment for anterior lesions, is absolutely incapable of treating such fractures because of limited potential for intraarticular manipulation through fracture line. Despite the excellent exposure of the Smith-Petersen approach for anterior acetabular fractures, it requires detachment of iliopsoas muscle, release of rectus femoris muscle, and even release of the attachment of the gluteus medius muscle or osteotomy of the ASIS for more extensive exposure.

The modified pararectus approach described here combines advantages of the pararectus approach and Smith-Petersen approach. It provides access to the anterior column and wall as with the pararectus approach but with less invasive tissue

dissection^[8]. Furthermore, by changing the orientation of the skin incision towards the AIIS, the anterior impacted articular lesion could be manipulated under direct vision, after retracting fractured AIIS. Although the modified pararectus approach provides a less exposed area of intra-articular surface and outer table of iliac wing than the Smith-Petersen approach, it offered adequate view and operation space in our case and prevented further damage to the iliac wing from osteotomy.

The major advantage of the modified pararectus approach compared with the original pararectus approach is the enlarged first and second windows, so that fractures of the low anterior column with marginal impaction can be well operated. On the other hand, more dissection of subcutaneous tissue is needed, and a smaller range of the superior ramus of the pubis is exposed.

CONCLUSION

We report a rare acetabular anterior wall fracture with preservation of the pelvic brim, but consisting of the AIIS and iliac wing in a 48-year-old woman. This atypical acetabular anterior wall fracture is different from the Judet-Letournel classification in terms of morphology and surgical procedure. A modified pararectus approach was used in our case, which could facilitate exposure, reduction, and osteosynthesis for atypical acetabular fracture with less invasiveness.

REFERENCES

- 1 **Judet R**, Judet J, Letournel E. Fractures of the acetabulum: Classification and surgical approaches for open reduction. *J Bone Joint Surg Am* 1964; **46**: 1615-1646 [PMID: [14239854](#) DOI: [10.2106/00004623-196446080-00001](#)]
- 2 **Letournel E**. Acetabulum fractures: classification and management. *Clin Orthop Relat Res* 1980; **151**: 81-106 [PMID: [7418327](#)]
- 3 **Piriou P**, Siguier T, De Loynes B, Charnley G, Judet T. Anterior wall acetabular fractures: report of two cases and new strategies in operative management. *J Trauma* 2002; **53**: 553-557 [PMID: [12352496](#) DOI: [10.1097/00005373-200209000-00026](#)]
- 4 **Lenarz CJ**, Moed BR. Atypical anterior wall fracture of the acetabulum: case series of anterior acetabular rim fracture without involvement of the pelvic brim. *J Orthop Trauma* 2007; **21**: 515-522 [PMID: [17805017](#) DOI: [10.1097/BOT.0b013e31814612e5](#)]
- 5 **Grubor P**, Krupic F, Biscevic M, Grubor M. Controversies in treatment of acetabular fracture. *Med Arch* 2015; **69**: 16-20 [PMID: [25870470](#) DOI: [10.5455/medarch.2015.69.16-20](#)]
- 6 **Lefavre KA**, Starr AJ, Reinert CM. A modified anterior exposure to the acetabulum for treatment of difficult anterior acetabular fractures. *J Orthop Trauma* 2009; **23**: 370-378 [PMID: [19390366](#) DOI: [10.1097/BOT.0b013e3181a5367c](#)]
- 7 **Mears DC**, Gordon RG. Internal fixation of acetabular fractures. *Techniques in Orthopaedics* 1990; **4**: 36-51 [DOI: [10.1097/00013611-199001000-00005](#)]
- 8 **Keel MJB**, Siebenrock KA, Tannast M, Bastian JD. The Pararectus Approach: A New Concept. *JBJS Essent Surg Tech* 2018; **8**: e21 [PMID: [30588366](#) DOI: [10.2106/JBJS.ST.17.00060](#)]
- 9 **Mirovsky Y**, Fischer S, Hendel D, Halperin N. Traumatic anterior dislocation of the hip joint with fracture of the acetabulum: a case report. *J Trauma* 1988; **28**: 1597-1599 [PMID: [3184226](#) DOI: [10.1097/00005373-198811000-00016](#)]
- 10 **Badelon O**, Leroux D, Hutten D, Duparc J. [Anterior luxation of the hip associated with a fracture of the anterior aspect of the acetabulum. Apropos of a case]. *Ann Chir* 1986; **40**: 38-40 [PMID: [3707004](#)]
- 11 **Tannast M**, Najibi S, Matta JM. Two to twenty-year survivorship of the hip in 810 patients with operatively treated acetabular fractures. *J Bone Joint Surg Am* 2012; **94**: 1559-1567 [PMID: [22992846](#) DOI: [10.2106/JBJS.K.00444](#)]



Published by Baishideng Publishing Group Inc
7041 Koll Center Parkway, Suite 160, Pleasanton, CA 94566, USA
Telephone: +1-925-3991568
E-mail: bpgoffice@wjgnet.com
Help Desk: <https://www.f6publishing.com/helpdesk>
<https://www.wjgnet.com>

