

World Journal of *Radiology*

World J Radiol 2020 May 28; 12(5): 48-86





REVIEW

- 48 Vascular depression for radiology: A review of the construct, methodology, and diagnosis
Rushia SN, Shehab AAS, Motter JN, Egglefield DA, Schiff S, Sneed JR, Garcon E

MINIREVIEWS

- 68 Adaptive radiation therapy of breast cancer by repeated imaging during irradiation
Sager O, Dincoglan F, Demiral S, Uysal B, Gamsiz H, Ozcan F, Colak O, Elcim Y, Gundem E, Dirican B, Beyzadeoglu M
- 76 Diagnostic problems in two-dimensional shear wave elastography of the liver
Naganuma H, Ishida H, Uno A, Nagai H, Kuroda H, Ogawa M

ABOUT COVER

Editorial Board Member of *World Journal of Radiology*, Siarhei Kharuzhyk, MD, PhD, Associate Professor, Lecturer, Department of Radiology, N.N. Alexandrov National Cancer Center of Belarus, Minsk 223040, Belarus

AIMS AND SCOPE

The primary aim of *World Journal of Radiology* (*WJR*, *World J Radiol*) is to provide scholars and readers from various fields of radiology with a platform to publish high-quality basic and clinical research articles and communicate their research findings online.

WJR mainly publishes articles reporting research results and findings obtained in the field of radiology and covering a wide range of topics including state of the art information on cardiopulmonary imaging, gastrointestinal imaging, genitourinary imaging, musculoskeletal imaging, neuroradiology/head and neck imaging, nuclear medicine and molecular imaging, pediatric imaging, vascular and interventional radiology, and women's imaging.

INDEXING/ABSTRACTING

The *WJR* is now abstracted and indexed in Emerging Sources Citation Index (Web of Science), PubMed, PubMed Central, China National Knowledge Infrastructure (CNKI), China Science and Technology Journal Database (CSTJ), and Superstar Journals Database.

RESPONSIBLE EDITORS FOR THIS ISSUE

Responsible Electronic Editor: *Mei-Yi Liu*

Proofing Production Department Director: *Xiang Li*

Responsible Editorial Office Director: *Ruo-Yu Ma*

NAME OF JOURNAL

World Journal of Radiology

ISSN

ISSN 1949-8470 (online)

LAUNCH DATE

January 31, 2009

FREQUENCY

Monthly

EDITORS-IN-CHIEF

Venkatesh Mani

EDITORIAL BOARD MEMBERS

<https://www.wjgnet.com/1949-8470/editorialboard.htm>

PUBLICATION DATE

May 28, 2020

COPYRIGHT

© 2020 Baishideng Publishing Group Inc

INSTRUCTIONS TO AUTHORS

<https://www.wjgnet.com/bpg/gerinfo/204>

GUIDELINES FOR ETHICS DOCUMENTS

<https://www.wjgnet.com/bpg/GerInfo/287>

GUIDELINES FOR NON-NATIVE SPEAKERS OF ENGLISH

<https://www.wjgnet.com/bpg/gerinfo/240>

PUBLICATION ETHICS

<https://www.wjgnet.com/bpg/GerInfo/288>

PUBLICATION MISCONDUCT

<https://www.wjgnet.com/bpg/gerinfo/208>

ARTICLE PROCESSING CHARGE

<https://www.wjgnet.com/bpg/gerinfo/242>

STEPS FOR SUBMITTING MANUSCRIPTS

<https://www.wjgnet.com/bpg/GerInfo/239>

ONLINE SUBMISSION

<https://www.f6publishing.com>

Adaptive radiation therapy of breast cancer by repeated imaging during irradiation

Omer Sager, Ferrat Dincoglan, Selcuk Demiral, Bora Uysal, Hakan Gamsiz, Fatih Ozcan, Onurhan Colak, Yelda Elcim, Esin Gundem, Bahar Dirican, Murat Beyzadeoglu

ORCID number: Omer Sager (0000-0001-7866-2598); Ferrat Dincoglan (0000-0002-7668-0976); Selcuk Demiral (0000-0002-3408-0323); Bora Uysal (0000-0002-7288-7005); Hakan Gamsiz (0000-0002-7791-3487); Fatih Ozcan (0000-0002-1965-7067); Onurhan Colak (0000-0003-1421-4678); Yelda Elcim (0000-0001-6274-1267); Esin Gundem (0000-0002-9482-8567); Bahar Dirican (0000-0002-1749-5375); Murat Beyzadeoglu (0000-0003-1035-7209).

Author contributions: Sager O, Dincoglan F, Demiral S, Uysal B, Gamsiz H, Ozcan F and Colak O played significant role in data acquisition, interpretation of data, reviewing and writing of the manuscript; Elcim Y, Gundem E and Dirican B worked on checking the manuscript for important intellectual content; Beyzadeoglu M took part in designing, reviewing and writing of the manuscript and checking the manuscript for important intellectual content; all authors read and approved the final version of the manuscript.

Conflict-of-interest statement: No conflicts to disclose.

Open-Access: This article is an open-access article that was selected by an in-house editor and fully peer-reviewed by external reviewers. It is distributed in accordance with the Creative Commons Attribution NonCommercial (CC BY-NC 4.0) license, which permits others to

Omer Sager, Ferrat Dincoglan, Selcuk Demiral, Bora Uysal, Hakan Gamsiz, Fatih Ozcan, Onurhan Colak, Yelda Elcim, Esin Gundem, Bahar Dirican, Murat Beyzadeoglu, Department of Radiation Oncology, Gulhane Medical Faculty, University of Health Sciences, Etlik, Ankara 06018, Turkey

Corresponding author: Omer Sager, MD, Associate Professor, Department of Radiation Oncology, Gulhane Medical Faculty, University of Health Sciences, Etlik, Ankara 06018, Turkey. omersager@gmail.com

Abstract

Breast cancer is the most frequent cancer among females and also a leading cause of cancer related mortality worldwide. A multimodality treatment approach may be utilized for optimal management of patients with combinations of surgery, radiation therapy (RT) and systemic treatment. RT composes an integral part of breast conserving treatment, and is typically used after breast conserving surgery to improve local control. Recent years have witnessed significant improvements in the discipline of radiation oncology which allow for more focused and precise treatment delivery. Adaptive radiation therapy (ART) is among the most important RT techniques which may be utilized for redesigning of treatment plans to account for dynamic changes in tumor size and anatomy during the course of irradiation. In the context of breast cancer, ART may serve as an excellent tool for patients receiving breast irradiation followed by a sequential boost to the tumor bed. Primary benefits of ART include more precise boost localization and potential for improved normal tissue sparing with adapted boost target volumes particularly in the setting of seroma reduction during the course of irradiation. Herein, we provide a concise review of ART for breast cancer in light of the literature.

Key words: Breast cancer; Adaptive radiation therapy; Tumor bed boost; Computed tomography; Imaging; Replanning

©The Author(s) 2020. Published by Baishideng Publishing Group Inc. All rights reserved.

Core tip: Adaptive radiation therapy (ART) refers to redesigning of treatment plans with respect to dynamic changes in tumor size and anatomy during the course of irradiation. There have been several applications of ART for a variety of cancers. In the context of breast cancer, ART may serve as an excellent tool for patients receiving breast

distribute, remix, adapt, build upon this work non-commercially, and license their derivative works on different terms, provided the original work is properly cited and the use is non-commercial. See: <http://creativecommons.org/licenses/by-nc/4.0/>

Manuscript source: Invited manuscript

Received: February 28, 2020

Peer-review started: February 28, 2020

First decision: April 25, 2020

Revised: May 8, 2020

Accepted: May 16, 2020

Article in press: May 16, 2020

Published online: May 28, 2020

P-Reviewer: Koukourakis GV

S-Editor: Zhang H

L-Editor: A

E-Editor: Li X



irradiation followed by a sequential boost to the tumor bed. Primary benefits of ART include more precise boost localization and potential for improved normal tissue sparing with adapted boost target volumes particularly in the setting of seroma reduction during the course of irradiation.

Citation: Sager O, Dincoglan F, Demiral S, Uysal B, Gamsiz H, Ozcan F, Colak O, Elcim Y, Gundem E, Dirican B, Beyzadeoglu M. Adaptive radiation therapy of breast cancer by repeated imaging during irradiation. *World J Radiol* 2020; 12(5): 68-75

URL: <https://www.wjgnet.com/1949-8470/full/v12/i5/68.htm>

DOI: <https://dx.doi.org/10.4329/wjr.v12.i5.68>

INTRODUCTION

Breast cancer is the most frequent cancer among females and also a leading cause of cancer related mortality worldwide. A multimodality treatment approach may be utilized for optimal management of patients with combinations of surgery, radiation therapy (RT) and systemic treatment. RT composes an integral part of breast conserving treatment (BCT), and is typically used after breast conserving surgery (BCS) to improve local control. Recent years have witnessed significant improvements in the discipline of radiation oncology which allow for more focused and precise treatment delivery. Adaptive radiation therapy (ART) is among the most important RT techniques which may be utilized for redesigning of treatment plans to account for dynamic changes in tumor size and anatomy during the course of irradiation. In the context of breast cancer, ART may serve as an excellent tool for patients receiving breast irradiation followed by a sequential boost to the tumor bed. Primary benefits of ART include more precise boost localization and potential for improved normal tissue sparing with adapted boost target volumes particularly in the setting of seroma reduction during the course of irradiation. Herein, we provide a concise review of ART for breast cancer in light of the literature.

MASTECTOMY AND BREAST CONSERVING TREATMENT FOR BREAST CANCER MANAGEMENT

Both mastectomy and BCT are widely used therapeutic options for management of patients suffering from breast cancer. Selection of surgical modality as BCS or mastectomy is based on several factors including patient and tumor characteristics, assessment of outcomes in terms of cosmesis, treatment morbidity and local control, and patient preferences. In terms of efficacy, BCT and mastectomy provide comparable results which have been supported by data from randomized trials and collaborative group studies^[1-3]. In this context, BCT has been alternatively used for management of patients with breast cancer. Recent studies also support the utility of BCS and RT as a viable alternative to mastectomy with encouraging results^[4-8].

UTILITY OF RADIATION THERAPY AS PART OF BREAST CONSERVING TREATMENT

Use of RT as part of BCT is increasing in line with accumulating evidence and improvements in the discipline of radiation oncology including sophisticated delivery techniques and modernized treatment equipment^[9,10]. Although omission of RT after BCS may be considered for a very highly selected subgroup of patients given the relatively lower local recurrence rates after BCS and endocrine treatment^[11-13], RT is widely recognized as an integral part of BCT particularly to decrease the rates of local recurrence^[14-21].

CONVENTIONALLY FRACTIONATED RADIATION THERAPY OF THE INTACT BREAST: TO BOOST OR NOT TO BOOST

Irradiation of the intact breast with conventionally fractionated RT as part of BCT typically includes whole breast irradiation (WBI) followed by a sequential tumor bed boost directed at the lumpectomy cavity. Main rationale of adjuvant RT following BCS is reduction of local recurrence. Utility of RT for breast cancer management has been assessed in a comprehensive metaanalysis^[14]. This metaanalysis reported a substantial reduction in the 10-year first recurrence rate from 35% to 19.3%, and incorporation of adjuvant RT also resulted in a breast cancer survival gain of 3.8% at 15 years, suggesting substantial benefit of adding RT after surgical management^[14]. Since local recurrence comprises a critical pattern of recurrence for breast cancer patients affecting prognosis^[22,23], achieving durable local control rates is a pertinent goal of management. Given the tendency of breast tumors to recur primarily at the original tumor site, delivery of a boost RT dose to the lumpectomy cavity has been utilized for achieving improved local control rates^[24-33]. Rationale for boost RT includes elimination of microscopic tumor cells located at the primary tumor site to improve local control. Delivery of boost dose to the lumpectomy cavity may be performed by use of several techniques including external photon beams, external electron beams, and brachytherapy^[24,25,34].

DEFINITION OF THE BOOST TARGET VOLUME

Definition of the boost target volume is a critical component of breast cancer RT. Surgical scar and clips, ultrasonography, mammography, Computerized Tomography (CT), Magnetic Resonance Imaging (MRI), clinical examination findings may be incorporated for determining the localization of tumor bed boost^[35-44]. However, there is no consensus on this critical issue with wide variations among clinical practices worldwide. Clearly, all methods have their advantages and drawbacks which renders a complementary or integrative approach more feasible to achieve precise target volume localization.

THE CONCEPT OF ADAPTIVE RADIATION THERAPY

ART refers to redesigning of treatment plans with respect to dynamic changes in tumor size and anatomy during the course of irradiation. There have been several applications of ART for a variety of indications including breast cancer, head and neck cancers, prostate cancer, and several other cancers throughout the human body^[45-52]. Primary objective of ART is achieving an improved therapeutic ratio. Accounting for volumetric and anatomical changes during the course of irradiation has great potential for improving treatment outcomes. This pertinent goal of RT may be achieved by incorporating smaller boost target volumes when substantial reduction in tumor burden is confirmed on periodical imaging during the RT course. Indeed, this rationale has been tested in the setting of RT after induction chemotherapy for limited-stage small cell lung cancer^[53]. The authors concluded that irradiation of the postchemotherapy volumes instead of baseline prechemotherapy volumes did not decrease locoregional control^[53]. While chemotherapy may confer substantial shrinkage of tumor volumes particularly for chemosensitive cancers, RT may also achieve reduction in tumor burden which may be exploited by use of ART techniques. Besides tumor shrinkage, replanning for boost RT may provide additional advantages for precise target localization accounting for the potential changes in patient anatomy due to weight loss or edema.

ADAPTIVE RADIATION THERAPY OF THE INTACT BREAST BY REPEATED IMAGING DURING THE COURSE OF IRRADIATION

For breast cancer patients receiving conventionally fractionated RT over 5-6 wk followed by a sequential tumor bed boost, ART may be utilized for more precisely focused boost RT. Replanning for the tumor bed boost may prevent excessive normal tissue exposure particularly for patients having seroma at the initiation of WBI. Several studies have reported on volumetric changes in the lumpectomy cavity during the course of breast irradiation^[45,54-63]. Data from selected studies incorporating

ART for breast cancer by use of repeated imaging during the course of breast irradiation are summarized in [Table 1](#).

A consistent finding of the aforementioned studies is the dynamic nature of the tumor bed during the course of breast irradiation. In this context, ART may be exploited to optimize normal tissue sparing particularly in the presence of substantial seroma reduction during RT by using reduced boost target volumes. Another potential benefit of repeated imaging may be avoidance of boost localization inaccuracies due to dynamic changes during the course of breast irradiation which may allow for improved precision in boost RT. These potential benefits of ART should be considered thoroughly for management of patients with breast cancer to achieve an improved therapeutic ratio. [Figure 1](#) shows axial CT images of a patient acquired at initial CT-simulation (on the left) for WBI planning and repeated CT-simulation (on the right) for tumor bed boost planning.

CONCLUSION

ART with repeated imaging during the course of irradiation may serve as an excellent tool for patients receiving breast RT followed by a sequential boost to the tumor bed. Utility of ART with widely accepted hypofractionated breast irradiation protocols, frequency of imaging for treatment plan adaptation, selection of patients for ART or routinization of the technique for every patient are areas of active investigation. There is accumulating evidence supporting the utility of ART for breast cancer management, however, future trials are needed for validation of dosimetric and clinical results of ART with repeated imaging at different time points during the course of breast irradiation.

Table 1 Selected studies incorporating adaptive radiation therapy for breast cancer by use of repeated imaging during the course of breast irradiation

Ref.	Year of publication	Number of patients receiving ART by use of repeated imaging	Relevant findings at initial imaging for RT	Relevant findings at repeated imaging for boost RT	P value
Oh <i>et al</i> ^[55]	2006	30	Cavity volume before WBI 32.1 cc	Cavity volume after WBI 25.1 cc	< 0.0001
Sharma <i>et al</i> ^[56]	2009	24	Median seroma volume 50 cc before WBI	Median seroma volume 29 cc at repeated CT-simulation for tumor bed boost	< 0.001
Tersteeg <i>et al</i> ^[57]	2009	77	Gross Tumor Volume before WBI 78.7 cc	Gross Tumor Volume 29.7 cc at repeated CT-simulation for tumor bed boost	< 0.001
Flannery <i>et al</i> ^[58]	2009	43	Median lumpectomy volume 38.2 cc at initial CT-simulation for WBI	Median lumpectomy volume 21.7 cc at repeated CT-simulation for tumor bed boost	< 0.001
Hurkmans <i>et al</i> ^[59]	2009	10	Boost volume 40 cc at initial CT-simulation for WBI	Boost volume 25-28 cc at repeated CT-simulations for tumor bed boost	= 0.02
Alderliesten <i>et al</i> ^[60]	2011	21	Mean seroma volume 63 cc at initial CT-simulation for WBI	Mean seroma volume 25 cc at repeated CT-simulation for tumor bed boost	< 0.001
Cho <i>et al</i> ^[61]	2011	70	Lumpectomy cavity volume 50.4 cc before WBI	Lumpectomy cavity volume 40.7 cc after WBI	< 0.001
Hurkmans <i>et al</i> ^[62]	2012	113	Tumor bed volume 70 cc at initial CT-simulation for breast RT	Tumor bed volume 45 cc at repeated CT-simulation	< 0.001
Mohiuddin <i>et al</i> ^[63]	2012	40	Median lumpectomy cavity volume 42 cc at initial CT-simulation for WBI	Median lumpectomy cavity volume 22 cc at repeated CT-simulation for tumor bed boost	< 0.001
Sager <i>et al</i> ^[45]	2018	48	Median boost target volume 33.85 cc at initial CT-simulation for WBI	Median boost target volume 14.55 cc at repeated CT-simulation for tumor bed boost	< 0.0001

ART: Adaptive radiation therapy; RT: Radiation therapy; CT: Computed tomography; WBI: Whole breast irradiation.

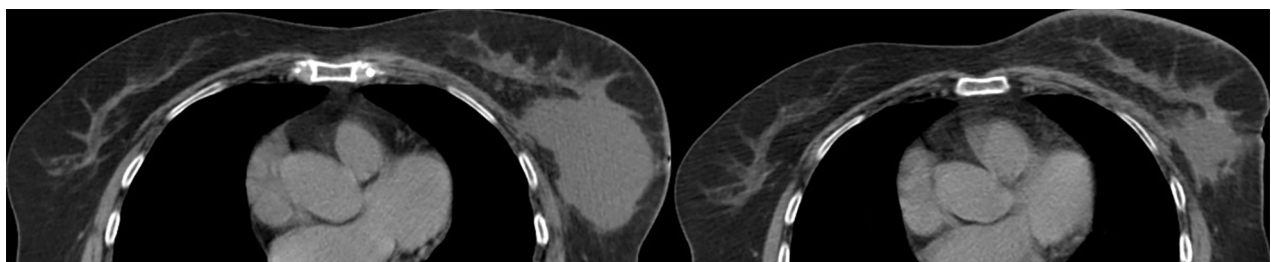


Figure 1 Axial computed tomography images. A patient acquired at initial computed tomography-simulation (on the left) for whole breast irradiation planning and repeated computed tomography-simulation (on the right) for tumor bed boost planning.

REFERENCES

1. **Litière S**, Werutsky G, Fentiman IS, Rutgers E, Christiaens MR, Van Limbergen E, Baaijens MH, Bogaerts J, Bartelink H. Breast conserving therapy versus mastectomy for stage I-II breast cancer: 20 year follow-up of the EORTC 10801 phase 3 randomised trial. *Lancet Oncol* 2012; **13**: 412-419 [PMID: 22373563 DOI: 10.1016/S1470-2045(12)70042-6]
2. **Early Breast Cancer Trialists' Collaborative Group**. Radiotherapy for early breast cancer. *Cochrane Database Syst Rev* 2002; CD003647 [PMID: 12076497 DOI: 10.1002/14651858.CD003647]
3. **Fisher B**, Anderson S, Bryant J, Margolese RG, Deutsch M, Fisher ER, Jeong JH, Wolmark N. Twenty-

- year follow-up of a randomized trial comparing total mastectomy, lumpectomy, and lumpectomy plus irradiation for the treatment of invasive breast cancer. *N Engl J Med* 2002; **347**: 1233-1241 [PMID: 12393820 DOI: 10.1056/NEJMoa022152]
- 4 **Corradini S**, Reitz D, Pazos M, Schönecker S, Braun M, Harbeck N, Matuschek C, Bölke E, Ganswindt U, Alongi F, Niyazi M, Belka C. Mastectomy or Breast-Conserving Therapy for Early Breast Cancer in Real-Life Clinical Practice: Outcome Comparison of 7565 Cases. *Cancers (Basel)* 2019; **11**: 160 [PMID: 30709048 DOI: 10.3390/cancers11020160]
 - 5 **Chen K**, Liu J, Zhu L, Su F, Song E, Jacobs LK. Comparative effectiveness study of breast-conserving surgery and mastectomy in the general population: A NCDB analysis. *Oncotarget* 2015; **6**: 40127-40140 [PMID: 26517676 DOI: 10.18632/oncotarget.5394]
 - 6 **Onitilo AA**, Engel JM, Stankowski RV, Doi SA. Survival Comparisons for Breast Conserving Surgery and Mastectomy Revisited: Community Experience and the Role of Radiation Therapy. *Clin Med Res* 2015; **13**: 65-73 [PMID: 25487237 DOI: 10.3121/cm.2014.1245]
 - 7 **Christiansen P**, Carstensen SL, Ejlersen B, Kroman N, Offersen B, Bodilsen A, Jensen MB. Breast conserving surgery versus mastectomy: overall and relative survival-a population based study by the Danish Breast Cancer Cooperative Group (DBCG). *Acta Oncol* 2018; **57**: 19-25 [PMID: 29168674 DOI: 10.1080/0284186X.2017.1403042]
 - 8 **van Maaren MC**, de Munck L, de Bock GH, Jobsen JJ, van Dalen T, Linn SC, Poortmans P, Strobbe LJA, Siesling S. 10 year survival after breast-conserving surgery plus radiotherapy compared with mastectomy in early breast cancer in the Netherlands: a population-based study. *Lancet Oncol* 2016; **17**: 1158-1170 [PMID: 27344114 DOI: 10.1016/S1470-2045(16)30067-5]
 - 9 **Dincoglan F**, Beyzadeoglu M, Sager O, Oysul K, Kahya YE, Gamsiz H, Uysal B, Demiral S, Dirican B, Surenkok S. Dosimetric evaluation of critical organs at risk in mastectomized left-sided breast cancer radiotherapy using breath-hold technique. *Tumori* 2013; **99**: 76-82 [PMID: 23549004 DOI: 10.1700/1248.13792]
 - 10 **Sager O**, Dincoglan F, Demiral S, Uysal B, Gamsiz H, Ozcan F, Colak O, Elcim Y, Dirican B, Beyzadeoglu M. Breathing adapted radiation therapy for leukemia relapse in the breast: A case report. *World J Clin Oncol* 2019; **10**: 369-374 [PMID: 31815096 DOI: 10.5306/wjco.v10.i11.369]
 - 11 **Hughes KS**, Schnaper LA, Berry D, Cirrincione C, McCormick B, Shank B, Wheeler J, Champion LA, Smith TJ, Smith BL, Shapiro C, Muss HB, Winer E, Hudis C, Wood W, Sugarbaker D, Henderson IC, Norton L; Cancer and Leukemia Group B; Radiation Therapy Oncology Group; Eastern Cooperative Oncology Group. Lumpectomy plus tamoxifen with or without irradiation in women 70 years of age or older with early breast cancer. *N Engl J Med* 2004; **351**: 971-977 [PMID: 15342805 DOI: 10.1056/NEJMoa040587]
 - 12 **Hughes KS**, Schnaper LA, Bellon JR, Cirrincione CT, Berry DA, McCormick B, Muss HB, Smith BL, Hudis CA, Winer EP, Wood WC. Lumpectomy plus tamoxifen with or without irradiation in women age 70 years or older with early breast cancer: long-term follow-up of CALGB 9343. *J Clin Oncol* 2013; **31**: 2382-2387 [PMID: 23690420 DOI: 10.1200/JCO.2012.45.2615]
 - 13 **Kunkler IH**, Williams LJ, Jack WJ, Cameron DA, Dixon JM; PRIME II investigators. Breast-conserving surgery with or without irradiation in women aged 65 years or older with early breast cancer (PRIME II): a randomised controlled trial. *Lancet Oncol* 2015; **16**: 266-273 [PMID: 25637340 DOI: 10.1016/S1470-2045(14)71221-5]
 - 14 **Early Breast Cancer Trialists' Collaborative Group**, Darby S, McGale P, Correa C, Taylor C, Arriagada R, Clarke M, Cutter D, Davies C, Ewertz M, Godwin J, Gray R, Pierce L, Whelan T, Wang Y, Peto R. Effect of radiotherapy after breast-conserving surgery on 10-year recurrence and 15-year breast cancer death: meta-analysis of individual patient data for 10,801 women in 17 randomised trials. *Lancet* 2011; **378**: 1707-1716 [PMID: 22019144 DOI: 10.1016/S0140-6736(11)61629-2]
 - 15 **Holli K**, Hietanen P, Saaristo R, Huhtala H, Hakama M, Joensuu H. Radiotherapy after segmental resection of breast cancer with favorable prognostic features: 12-year follow-up results of a randomized trial. *J Clin Oncol* 2009; **27**: 927-932 [PMID: 19114687 DOI: 10.1200/JCO.2008.19.7129]
 - 16 **Pötter R**, Gnant M, Kwasny W, Tausch C, Handl-Zeller L, Pakisch B, Taucher S, Hammer J, Luschin-Ebengreuth G, Schmid M, Sedlmayer F, Stierer M, Reiner G, Kapp K, Hofbauer F, Rottenfusser A, Pöstlberger S, Haider K, Draxler W, Jakesz R; Austrian Breast and Colorectal Cancer Study Group. Lumpectomy plus tamoxifen or anastrozole with or without whole breast irradiation in women with favorable early breast cancer. *Int J Radiat Oncol Biol Phys* 2007; **68**: 334-340 [PMID: 17363187 DOI: 10.1016/j.ijrobp.2006.12.045]
 - 17 **Lim M**, Bellon JR, Gelman R, Silver B, Recht A, Schnitt SJ, Harris JR. A prospective study of conservative surgery without radiation therapy in select patients with Stage I breast cancer. *Int J Radiat Oncol Biol Phys* 2006; **65**: 1149-1154 [PMID: 16750330 DOI: 10.1016/j.ijrobp.2006.02.006]
 - 18 **Fyles AW**, McCready DR, Manchul LA, Trudeau ME, Merante P, Pintilie M, Weir LM, Olivetto IA. Tamoxifen with or without breast irradiation in women 50 years of age or older with early breast cancer. *N Engl J Med* 2004; **351**: 963-970 [PMID: 15342804 DOI: 10.1056/NEJMoa040595]
 - 19 **Fisher B**, Bryant J, Dignam JJ, Wickerham DL, Mamounas EP, Fisher ER, Margolese RG, Nesbitt L, Paik S, Pisansky TM, Wolmark N; National Surgical Adjuvant Breast and Bowel Project. Tamoxifen, radiation therapy, or both for prevention of ipsilateral breast tumor recurrence after lumpectomy in women with invasive breast cancers of one centimeter or less. *J Clin Oncol* 2002; **20**: 4141-4149 [PMID: 12377957 DOI: 10.1200/JCO.2002.11.101]
 - 20 **Fisher B**, Redmond C. Lumpectomy for breast cancer: an update of the NSABP experience. National Surgical Adjuvant Breast and Bowel Project. *J Natl Cancer Inst Monogr* 1992; **11**: 7-13 [PMID: 1627432]
 - 21 **Clark RM**, McCulloch PB, Levine MN, Lipa M, Wilkinson RH, Mahoney LJ, Basrur VR, Nair BD, McDermot RS, Wong CS. Randomized clinical trial to assess the effectiveness of breast irradiation following lumpectomy and axillary dissection for node-negative breast cancer. *J Natl Cancer Inst* 1992; **84**: 683-689 [PMID: 1314910 DOI: 10.1093/jnci/84.9.683]
 - 22 **Sarsenov D**, Ilgun S, Ordu C, Alco G, Bozdogan A, Elbuken F, Nur Pilanci K, Agacayak F, Erdogan Z, Eralp Y, Dincer M, Ozmen V. True Local Recurrences after Breast Conserving Surgery have Poor Prognosis in Patients with Early Breast Cancer. *Cureus* 2016; **8**: e541 [PMID: 27158571 DOI: 10.7759/cureus.541]
 - 23 **Belkacemi Y**, Hanna NE, Besnard C, Majdoul S, Gligorov J. Local and Regional Breast Cancer Recurrences: Salvage Therapy Options in the New Era of Molecular Subtypes. *Front Oncol* 2018; **8**: 112 [PMID: 29719816 DOI: 10.3389/fonc.2018.00112]
 - 24 **Kindts I**, Laenen A, Depuydt T, Weltens C. Tumour bed boost radiotherapy for women after breast-

- conserving surgery. *Cochrane Database Syst Rev* 2017; **11**: CD011987 [PMID: [29105051](#) DOI: [10.1002/14651858.CD011987.pub2](#)]
- 25 **Graham P**, Fourquet A. Placing the boost in breast-conservation radiotherapy: A review of the role, indications and techniques for breast-boost radiotherapy. *Clin Oncol (R Coll Radiol)* 2006; **18**: 210-219 [PMID: [16605052](#) DOI: [10.1016/j.clon.2005.11.008](#)]
 - 26 **Bartelink H**, Horiot JC, Poortmans P, Struikmans H, Van den Bogaert W, Barillot I, Fourquet A, Borger J, Jager J, Hoogenraad W, Collette L, Pierart M; European Organization for Research and Treatment of Cancer Radiotherapy and Breast Cancer Groups. Recurrence rates after treatment of breast cancer with standard radiotherapy with or without additional radiation. *N Engl J Med* 2001; **345**: 1378-1387 [PMID: [11794170](#) DOI: [10.1056/NEJMoa010874](#)]
 - 27 **Bartelink H**, Horiot JC, Poortmans PM, Struikmans H, Van den Bogaert W, Fourquet A, Jager JJ, Hoogenraad WJ, Oei SB, Wárlám-Rodenhuis CC, Pierart M, Collette L. Impact of a higher radiation dose on local control and survival in breast-conserving therapy of early breast cancer: 10-year results of the randomized boost versus no boost EORTC 22881-10882 trial. *J Clin Oncol* 2007; **25**: 3259-3265 [PMID: [17577015](#) DOI: [10.1200/JCO.2007.11.4991](#)]
 - 28 **Romestaing P**, Lehingue Y, Carrie C, Coquard R, Montbarbon X, Ardiet JM, Mamelle N, Gérard JP. Role of a 10-Gy boost in the conservative treatment of early breast cancer: results of a randomized clinical trial in Lyon, France. *J Clin Oncol* 1997; **15**: 963-968 [PMID: [9060534](#) DOI: [10.1200/JCO.1997.15.3.963](#)]
 - 29 **Polgár C**, Fodor J, Orosz Z, Major T, Takácsi-Nagy Z, Mangel LC, Sulyok Z, Somogyi A, Kásler M, Németh G. Electron and high-dose-rate brachytherapy boost in the conservative treatment of stage I-II breast cancer first results of the randomized Budapest boost trial. *Strahlenther Onkol* 2002; **178**: 615-623 [PMID: [12426672](#) DOI: [10.1007/s00066-002-1053-1](#)]
 - 30 **Hau E**, Browne LH, Khanna S, Cail S, Cert G, Chin Y, Clark C, Inder S, Swajcar A, Graham PH. Radiotherapy breast boost with reduced whole-breast dose is associated with improved cosmesis: the results of a comprehensive assessment from the St. George and Wollongong randomized breast boost trial. *Int J Radiat Oncol Biol Phys* 2012; **82**: 682-689 [PMID: [21255943](#) DOI: [10.1016/j.ijrobp.2010.11.025](#)]
 - 31 **Forrest AP**, Stewart HJ, Everington D, Prescott RJ, McArdle CS, Harnett AN, Smith DC, George WD. Randomised controlled trial of conservation therapy for breast cancer: 6-year analysis of the Scottish trial. Scottish Cancer Trials Breast Group. *Lancet* 1996; **348**: 708-713 [PMID: [8806289](#) DOI: [10.1016/s0140-6736\(96\)02133-2](#)]
 - 32 **Arriagada R**, Le MG, Dunant A, Tubiana M, Contesso G. Twenty-five years of follow-up in patients with operable breast carcinoma: correlation between clinicopathologic factors and the risk of death in each 5-year period. *Cancer* 2006; **106**: 743-750 [PMID: [16411216](#) DOI: [10.1002/cncr.21659](#)]
 - 33 **Arriagada R**, Lê MG, Guinebrière JM, Dunant A, Rochard F, Tursz T. Late local recurrences in a randomised trial comparing conservative treatment with total mastectomy in early breast cancer patients. *Ann Oncol* 2003; **14**: 1617-1622 [PMID: [14581268](#) DOI: [10.1093/annonc/mdg452](#)]
 - 34 **Jalali R**, Singh S, Budrukkar A. Techniques of tumour bed boost irradiation in breast conserving therapy: current evidence and suggested guidelines. *Acta Oncol* 2007; **46**: 879-892 [PMID: [17851869](#) DOI: [10.1080/02841860701441798](#)]
 - 35 **de Freitas TB**, Lopes de Barros Lima KM, de Andrade Carvalho H, de Azevedo Marques P, Belfort Mattos FT, Franco Fonseca AS, Munhoz AM, Filassi JR, Stuart SR, Marta GN. What a difference a clip makes! Analysis of boost volume definition in radiation therapy for partial breast surgery. *Eur J Surg Oncol* 2018; **44**: 1312-1317 [PMID: [30041975](#) DOI: [10.1016/j.ejso.2018.06.010](#)]
 - 36 **Kirby AM**, Yarnold JR, Evans PM, Morgan VA, Schmidt MA, Scurr ED, desouza NM. Tumor bed delineation for partial breast and breast boost radiotherapy planned in the prone position: what does MRI add to X-ray CT localization of titanium clips placed in the excision cavity wall? *Int J Radiat Oncol Biol Phys* 2009; **74**: 1276-1282 [PMID: [19464816](#) DOI: [10.1016/j.ijrobp.2009.02.028](#)]
 - 37 **Major T**, Gutiérrez C, Guix B, van Limbergen E, Strnad V, Polgár C, Breast Cancer Working Group of GEC-ESTRO. Recommendations from GEC ESTRO Breast Cancer Working Group (II): Target definition and target delineation for accelerated or boost partial breast irradiation using multicatheter interstitial brachytherapy after breast conserving open cavity surgery. *Radiother Oncol* 2016; **118**: 199-204 [PMID: [26776444](#) DOI: [10.1016/j.radonc.2015.12.006](#)]
 - 38 **Al-Hammadi N**, Caparrotti P, Divakar S, Riyas M, Chandramouli SH, Hammoud R, Hayes J, Mc Garry M, Paloor SP, Petric P. MRI Reduces Variation of Contouring for Boost Clinical Target Volume in Breast Cancer Patients Without Surgical Clips in the Tumour Bed. *Radiol Oncol* 2017; **51**: 160-168 [PMID: [28740451](#) DOI: [10.1515/raon-2017-0014](#)]
 - 39 **DEN Hartogh MD**, Philippens ME, VAN Dam IE, Kleynen CE, Tersteeg RJ, Kotte AN, VAN Vulpen M, VAN Asselen B, VAN DEN Bongard DH. Post-lumpectomy CT-guided tumor bed delineation for breast boost and partial breast irradiation: Can additional pre- and postoperative imaging reduce interobserver variability? *Oncol Lett* 2015; **10**: 2795-2801 [PMID: [26722244](#) DOI: [10.3892/ol.2015.3697](#)]
 - 40 **Giezen M**, Kouwenhoven E, Scholten AN, Coerkamp EG, Heijnenbroek M, Jansen WP, Mast ME, Petoukhova AL, Struikmans H. MRI- versus CT-based volume delineation of lumpectomy cavity in supine position in breast-conserving therapy: an exploratory study. *Int J Radiat Oncol Biol Phys* 2012; **82**: 1332-1340 [PMID: [21708426](#) DOI: [10.1016/j.ijrobp.2011.05.008](#)]
 - 41 **Ciernik IF**, Voss H, Wösle M. Standardization of the target volume for boost or partial breast radiation therapy after lumpectomy of breast cancer. *Int J Radiat Oncol Biol Phys* 2014; **89**: 690-691 [PMID: [24929170](#) DOI: [10.1016/j.ijrobp.2014.02.037](#)]
 - 42 **Hlavka A**, Vanasek J, Odrázká K, Stuk J, Dolezel M, Ulrych V, Vitkova M, Mynarik J, Kolarova I, Vilasova Z. Tumor bed radiotherapy in women following breast conserving surgery for breast cancer-safety margin with/without image guidance. *Oncol Lett* 2018; **15**: 6009-6014 [PMID: [29556317](#) DOI: [10.3892/ol.2018.8083](#)]
 - 43 **Lewis L**, Cox J, Morgia M, Atyeo J, Lamoury G. A clip-based protocol for breast boost radiotherapy provides clear target visualisation and demonstrates significant volume reduction over time. *J Med Radiat Sci* 2015; **62**: 177-183 [PMID: [26451239](#) DOI: [10.1002/jmrs.114](#)]
 - 44 **Ciernik IF**, Greiss AM. Visualization of the tumor cavity after lumpectomy of breast cancer for postoperative radiotherapy. *Clin Transl Radiat Oncol* 2019; **14**: 47-50 [PMID: [30555941](#) DOI: [10.1016/j.ctro.2018.11.003](#)]
 - 45 **Sager O**, Dincoglan F, Uysal B, Demiral S, Gamsiz H, Elcim Y, Gundem E, Dirican B, Beyzadeoglu M. Evaluation of adaptive radiotherapy (ART) by use of replanning the tumor bed boost with repeated computed tomography (CT) simulation after whole breast irradiation (WBI) for breast cancer patients having clinically evident seroma. *Jpn J Radiol* 2018; **36**: 401-406 [PMID: [29623550](#) DOI: [10.1007/s10339-018-0001-1](#)]

- 10.1007/s11604-018-0735-2]
- 46 **Sager O**, Beyzadeoglu M, Dincoglan F, Demiral S, Uysal B, Gamsiz H, Akin M, Gundem E, Dirican B. Adaptive splenic radiotherapy for symptomatic splenomegaly management in myeloproliferative disorders. *Tumori* 2015; **101**: 84-90 [PMID: 25702680 DOI: 10.5301/tj.5000221]
 - 47 **Morgan HE**, Sher DJ. Adaptive radiotherapy for head and neck cancer. *Cancers Head Neck* 2020; **5**: 1 [PMID: 31938572 DOI: 10.1186/s41199-019-0046-z]
 - 48 **Splinter M**, Bostel T, Sachpazidis I, Fechter T, Zamboglou C, Jäkel O, Huber PE, Debus J, Baltas D, Nicolay NH. Dosimetric Impact of Interfractional Variations for Post-prostatectomy Radiotherapy to the Prostatic Fossa-Relevance for the Frequency of Position Verification Imaging and Treatment Adaptation. *Front Oncol* 2019; **9**: 1191 [PMID: 31788450 DOI: 10.3389/fonc.2019.01191]
 - 49 **Mittauer KE**, Hill PM, Geurts MW, De Costa AM, Kimple RJ, Bassetti MF, Bayouth JE. STAT-ART: The Promise and Practice of a Rapid Palliative Single Session of MR-Guided Online Adaptive Radiotherapy (ART). *Front Oncol* 2019; **9**: 1013 [PMID: 31696053 DOI: 10.3389/fonc.2019.01013]
 - 50 **Belshaw L**, Agnew CE, Irvine DM, Rooney KP, McGarry CK. Adaptive radiotherapy for head and neck cancer reduces the requirement for rescans during treatment due to spinal cord dose. *Radiat Oncol* 2019; **14**: 189 [PMID: 31675962 DOI: 10.1186/s13014-019-1400-3]
 - 51 **Appel S**, Bar J, Alezra D, Ben-Ayun M, Rabin-Alezra T, Honig N, Katzman T, Chatterji S, Symon Z, Lawrence YR. Image-guidance triggered adaptive replanning of radiation therapy for locally advanced lung cancer: an evaluation of cases requiring plan adaptation. *Br J Radiol* 2020; **93**: 20190743 [PMID: 31670581 DOI: 10.1259/bjr.20190743]
 - 52 **Bostel T**, Sachpazidis I, Splinter M, Bougaff N, Fechter T, Zamboglou C, Jäkel O, Huber PE, Baltas D, Debus J, Nicolay NH. Dosimetric Impact of Interfractional Variations in Prostate Cancer Radiotherapy-Implications for Imaging Frequency and Treatment Adaptation. *Front Oncol* 2019; **9**: 940 [PMID: 31612106 DOI: 10.3389/fonc.2019.00940]
 - 53 **Hu X**, Bao Y, Zhang L, Guo Y, Chen YY, Li KX, Wang WH, Liu Y, He H, Chen M. Omitting elective nodal irradiation and irradiating postinduction versus preinduction chemotherapy tumor extent for limited-stage small cell lung cancer: interim analysis of a prospective randomized noninferiority trial. *Cancer* 2012; **118**: 278-287 [PMID: 21598237 DOI: 10.1002/cncr.26119]
 - 54 **Prendergast B**, Indelicato DJ, Grobmyer SR, Saito AI, Lightsey JL, Snead FE, Morris CG, Copeland EM, Mendenhall NP. The dynamic tumor bed: volumetric changes in the lumpectomy cavity during breast-conserving therapy. *Int J Radiat Oncol Biol Phys* 2009; **74**: 695-701 [PMID: 19168296 DOI: 10.1016/j.ijrobp.2008.08.044]
 - 55 **Oh KS**, Kong FM, Griffith KA, Yanke B, Pierce LJ. Planning the breast tumor bed boost: changes in the excision cavity volume and surgical scar location after breast-conserving surgery and whole-breast irradiation. *Int J Radiat Oncol Biol Phys* 2006; **66**: 680-686 [PMID: 16863683 DOI: 10.1016/j.ijrobp.2006.04.042]
 - 56 **Sharma R**, Spierer M, Mutyal S, Thawani N, Cohen HW, Hong L, Garg MK, Kalnicki S. Change in seroma volume during whole-breast radiation therapy. *Int J Radiat Oncol Biol Phys* 2009; **75**: 89-93 [PMID: 19362786 DOI: 10.1016/j.ijrobp.2008.10.037]
 - 57 **Tersteeg RJ**, Roesink JM, Albregts M, Wárlám-Rodenhuis CC, van Asselen B. Changes in excision cavity volume: prediction of the reduction in absolute volume during breast irradiation. *Int J Radiat Oncol Biol Phys* 2009; **74**: 1181-1185 [PMID: 19117693 DOI: 10.1016/j.ijrobp.2008.09.056]
 - 58 **Flannery TW**, Nichols EM, Cheston SB, Marter KJ, Naqvi SA, Markham KM, Ali I, Mohiuddin MM. Repeat computed tomography simulation to assess lumpectomy cavity volume during whole-breast irradiation. *Int J Radiat Oncol Biol Phys* 2009; **75**: 751-756 [PMID: 19289260 DOI: 10.1016/j.ijrobp.2008.11.024]
 - 59 **Hurkmans C**, Admiraal M, van der Sangen M, Dijkmans I. Significance of breast boost volume changes during radiotherapy in relation to current clinical interobserver variations. *Radiother Oncol* 2009; **90**: 60-65 [PMID: 18207594 DOI: 10.1016/j.radonc.2007.12.001]
 - 60 **Alderliesten T**, den Hollander S, Yang TJ, Elkhuijzen PH, van Mourik AM, Hurkmans C, Remeijer P, van Vliet-Vroegindewij C. Dosimetric impact of post-operative seroma reduction during radiotherapy after breast-conserving surgery. *Radiother Oncol* 2011; **100**: 265-270 [PMID: 21497929 DOI: 10.1016/j.radonc.2011.03.008]
 - 61 **Cho H**, Kim C. Volumetric changes in the lumpectomy cavity during whole breast irradiation after breast conserving surgery. *Radiat Oncol J* 2011; **29**: 277-282 [PMID: 22984681 DOI: 10.3857/roj.2011.29.4.277]
 - 62 **Hurkmans CW**, Dijkmans I, Reijnen M, van der Leer J, van Vliet-Vroegindewij C, van der Sangen M. Adaptive radiation therapy for breast IMRT-simultaneously integrated boost: three-year clinical experience. *Radiother Oncol* 2012; **103**: 183-187 [PMID: 22280808 DOI: 10.1016/j.radonc.2011.12.014]
 - 63 **Mohiuddin MM**, Nichols EM, Marter KJ, Flannery TW. Decrease of the lumpectomy cavity volume after whole-breast irradiation affects small field boost planning. *Med Dosim* 2012; **37**: 339-343 [PMID: 22305933 DOI: 10.1016/j.meddos.2011.11.008]



Published by Baishideng Publishing Group Inc
7041 Koll Center Parkway, Suite 160, Pleasanton, CA 94566, USA
Telephone: +1-925-3991568
E-mail: bpgoffice@wjgnet.com
Help Desk: <https://www.f6publishing.com/helpdesk>
<https://www.wjgnet.com>

