



Name of Journal: *World Journal of Orthopedics*

Manuscript NO: 55095

Manuscript Type: CASE REPORT

Müller-Weiss disease: Four case reports

Volpe A *et al.* Müller-Weiss disease

Antonio Volpe, Luca Monestier, Teresa Malara, Giacomo Riva, Giuseppe La Barbera,
Michele Francesco Surace

Match Overview

1	Crossref 57 words Lu, Chun-Kuan, Yin-Chih Fu, Yuh-Min Cheng, and Peng-Ju ... Huang. "Isolated talonavicular arthrodesis for Müller-Weiss di	2%
2	Internet 44 words crawled on 09-Dec-2019 journals.sagepub.com	2%
3	Crossref 34 words Brian Reade, Gregg Atlas, John Distazio, Stephen Kruljac. "... Mueller-weiss syndrome: An uncommon cause of midfoot pa	1%
4	Crossref 30 words Manuel Monteagudo, Ernesto Maceira. "Management of Müll er-Weiss Disease", Foot and Ankle Clinics, 2019	1%
5	Crossref 28 words Tosun, B.. "Spontaneous Osteonecrosis of the Tarsal Navic ... ar in an Adult: Mueller-Weiss Syndrome", The Journal of Foot	1%
6	Crossref 27 words Hongtao Zhang, Junkun Li, Yusen Qiao, Jia Yu, Yu Cheng, Ya n Liu, Chao Gao, Jiaxin Li. "Open triple fusion versus TNC ...	1%
7	Crossref 16 words T.H. Lui. "Arthroscopic triple arthrodesis in patients with Müll er Weiss disease", Foot and Ankle Surgery, 2009	1%
8	Crossref 12 words Anouk Tan, Yvonne C.M.M. Smulders, Oliver T. Zöphel. "Use of Remodeled Femoral Head Allograft for Tarsal Reconstruct...	<1%

Müller-Weiss disease: Four case reports



ALL

IMAGES

VIDEOS

41,500,000 Results

Any time ▼

Müller-Weiss disease - Journal of Medical Imaging and ...

medimagingcasereports.com/2019/03/29/muller-weiss-disease ▼

Mar 29, 2019 · **Müller-Weiss disease** is an uncommon idiopathic condition characterized by dorsolateral collapse and fragmentation of navicular bone. Most patients present as a chronic mid and hindfoot pain with deformity. We **report** a **case** of 61-year-old women with a progressive mid-foot pain, diagnosed as **Müller-Weiss disease**.

Flatfoot in Müller-Weiss syndrome: a case series

<https://www.ncbi.nlm.nih.gov/pmc/articles/PMC3459784>

Aug 01, 2012 · However, **Müller-Weiss** syndrome is a very rare **disease**, and there are few studies of this **disease** in terms of open surgical treatment in more than one patient. We adopted open operative methods to manage six patients with **Müller-Weiss** syndrome, and all subsequently achieved bony fusion and a pain-free condition.

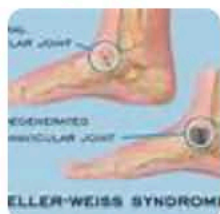
Cited by: 14

Author: Xu Wang, Xin Ma, Chao Zhang, Jia-Zha...

Publish Year: 2012

What is Mueller-Weiss Syndrome? - MASS4D® Foot Orthotics

<https://www.mass4d.com/blogs/clinicians-blog/mueller-weiss-syndrome> ▼



References: Wang X., Ma X., Zhang C., Huang J. Z., Jian J. Y. (2012) Flatfoot in **Müller-Weiss** syndrome: A **case** series. Journal of Medical **Case Reports** 6: August 2012 ...

Flatfoot in Müller-Weiss syndrome: a case series | Journal ...

<https://jmedicalcasereports.biomedcentral.com/articles/10.1186/1752-1947-6-228>

Aug 01, 2012 · However, **Müller-Weiss** syndrome is a very rare **disease**, and there are few studies of this **disease** in terms of open surgical treatment in more than one patient. We adopted open operative methods to manage six patients with **Müller-Weiss** syndrome, and all subsequently



Müller-Weiss disease: Four case reports



ALL IMAGES VIDEOS MAPS NEWS SHOPPING

18,300,000 Results Any time ▾

Do you mean **mueller-weiss** disease four case reports?

Müller-Weiss disease - Journal of Medical Imaging and ...

medimagingcasereports.com/2019/03/29/muller-weiss-disease ▾

Mar 29, 2019 · **Müller-Weiss disease** is an uncommon idiopathic condition characterized by dorsolateral collapse and fragmentation of navicular bone. Most patients present as a chronic mid and hindfoot pain with deformity. We **report** a **case** of 61-year-old women with a progressive mid-foot pain, diagnosed as **Müller-Weiss disease**.

Case 228: Mueller-Weiss Disease | Radiology

<https://pubs.rsna.org/doi/abs/10.1148/radiol.2016132280>

Mar 18, 2016 · **Müller-Weiss disease**: clinical and biomechanical features. Foot Ankle Clin 2004;9(1):105–125. Crossref, Medline, Google Scholar, 4. Yu G, Zhao Y, Zhou J, Zhang M. Fusion of talonavicular and naviculocuneiform joints for the treatment of **Müller-Weiss disease**. J Foot Ankle Surg 2012;51(4):415–419. Crossref, Medline, Google Scholar, 5.

Cited by: 4

Author: Kimia Khalatbari Kani, Hyojeong Mulcahy...

Publish Year: 2016

(PDF) Müller-Weiss Disease

https://www.researchgate.net/publication/332180018_Muller-Weiss_Disease

PDF | **Müller-Weiss disease** is an uncommon idiopathic condition characterized by dorsolateral collapse and fragmentation of navicular bone. Most patients... | Find, read and cite all the research ...

Müller-Weiss disease | Eurorad

<https://www.eurorad.org/case/12207> ▾

Jan 13, 2015 · **Müller-Weiss Disease** (MWD) is a complex idiopathic foot condition, presenting as a chronic mid and hind foot pain and with deformity of the tarsal navicular in adults. To this date, aetiology of the MWD has remained controversial. [1]

Flatfoot in Müller-Weiss syndrome: a case series ...

<https://europepmc.org/article/PMC/PMC3459784> ▾

Aug 01, 2012 · However, **Müller-Weiss** syndrome is a very rare **disease**, and there are few studies of **this disease** in terms of open surgical treatment in more than one patient. We adopted open operative