



Name of Journal: *World Journal of Clinical Cases*

Manuscript NO: 55349

Manuscript Type: CASE REPORT

Headache and sick sinus syndrome: A case report

Bi YC *et al.* Headache and sick sinus syndrome

You-Cai Bi, Liang Gong

Abstract

BACKGROUND

Sick sinus syndrome is a common disease in cardiology. Typical symptoms include palpitations, dizziness, shortness of breath, chest tightness and amaurosis. However, to date, there are no known reports of sick sinus syndrome presenting with headache. Whether there is a correlation between headache and sick sinus syndrome merits further research. In this report, we describe a case of headache induced by sick sinus syndrome.

CASE SUMMARY

A 73-year-old female patient presented to our department with the chief complaint of recurrent paroxysmal headache for more than seven years. The patient described paroxysmal palpitations, usually headache occurring after

Match Overview

1	Crossref 15 words Shih-Pin Chen, Jong-Ling Fuh, Wen-Chung Yu, Shuu-Jiun Wang. "Cardiac Cephalalgia", European Neurology, 2004	1%
2	Internet 14 words crawled on 27-Apr-2020 www.wjgnet.com	1%
3	Internet 12 words crawled on 16-May-2020 worldwidescience.org	1%



ALL

IMAGES

VIDEOS

14,600,000 Results

Any time

Myxedema coma accompanied by sick sinus syndrome and ...

<https://www.ncbi.nlm.nih.gov/pmc/articles/PMC6732564>

Jun 25, 2019 · Cardiovascular complications with severe hypothyroidism include sick sinus syndrome, AV block, decreased myocardial contractility, low cardiac output, and hypotension. Myxedema coma requiring temporary or permanent pacemaker implantation is rare, and the requirement of the procedure is mainly due to second-degree or complete AV block.

Author: Ko Harada, Shuntaro Murakami, Kazuki ... Publish Year: 2019

[PDF] Sick sinus syndrome - a case report of paroxysmal ...

www.clinicalcases.eu/index.php/acc/article/download/333/130

case of sick sinus syndrome when the patient's symptoms cannot be attributed to the bradycardia, but to the tachyarrhythmic episodes, it is often most efficient to treat the patient's paroxysmal supraventricular tachycardia by radiofrequency ablation, rather than using cardiac pacing.

Author: Ștefan Ailoei, Laura Cătălina Țăpoi, M... Publish Year: 2017

Marijuana Induced Sick Sinus Syndrome: A Case Report.

<https://www.ncbi.nlm.nih.gov/pubmed/31227686>

Jun 22, 2019 · Electrocardiogram (ECG) showed sinus bradycardia. A series of investigations, including a stress test and tilt table testing, were negative. The drug screen was positive for marijuana. A loop recorder was implanted to evaluate the cause of syncope and was positive for a long sinus pause of more than 3 second, indicative of sick sinus syndrome.

Cited by: 1 Author: Arshad Muhammad Iqbal, Ateeq Mubarik, ...

Publish Year: 2019

Myxedema coma accompanied by sick sinus syndrome and ...

<https://www.ncbi.nlm.nih.gov/pubmed/31516809>

Jun 25, 2019 · We herein report a case of myxedema coma accompanied by sick sinus syndrome requiring temporary cardiac pacing and hypercapnic respiratory failure in an 87-year-old woman. This case is unique because both of the cardiac and pulmonary manifestations were reversible and successfully treated with thyroid hormone replacement.

Author: Ko Harada, Shuntaro Murakami, Kazuki ... Publish Year: 2019

Case Report: Woman With Headache Pain, Dizziness, and ...

<https://www.neurologytimes.com/headache-and...>

Sep 11, 2018 · Case Report: Woman With Headache Pain, Dizziness, and Nausea. A 33-year-old woman has been experiencing recurrent episodes of nausea, headaches, and dizziness for the past 8 months. She has come to the emergency department because she is concerned about her current episode, which is slightly different from her previous ones.

Author: Heidi Moawad Publish Year: 2018

Lyme carditis presenting as sick sinus syndrome ...

<https://www.sciencedirect.com/science/article/pii/S0022073620300145>

Sick sinus syndrome is failure of the sinoatrial (SA) node, the pacemaker of the heart. Signs and symptoms consistent with sick sinus syndrome are syncope, dizziness, bradycardia, and sinus pauses. It is a condition prevalent in the aging population, occurring in 1 in 600 people over the age of 65, but is rare in younger age groups.

Author: Naomi Gazendam, Cynthia Yeung, Adria... Publish Year: 2020

Sick Sinus Syndrome | Australia| PDF | PPT| Case Reports ...

<https://www.omicsonline.org/australia/sick-sinus...>

Patients with sick sinus syndrome feels slower than normal pulse (bradycardia) , Fatigue , Dizziness or lightheadedness , Fainting or near fainting , Shortness of breath Chest pains , A sensation of rapid, fluttering heartbeats (palpitations)

Atrial Fibrillation and Sick Sinus Syndrome: A Clinical ...

<https://www.patientcareonline.com/atrial-fibrillation/atrial-fibrillation-and-sick...>

Nov 02, 2016 · Both atrial fibrillation and sick sinus syndrome (a subset of which is also known as "tachy-brady" syndrome) are more common in elderly patients. The problem comes when they co-exist and as a result, make management of each disease more challenging.

Author: Payal Kohli Publish Year: 2016

Complex regional pain syndrome induced by pacemaker ...

<https://www.sciencedirect.com/science/article/pii/S1880427617301643>

A 53-year-old woman reported burning pain, muscle weakness, and dysesthesia of the left arm 2 months after permanent pacemaker insertion in the ipsilateral side for the treatment of sick sinus syndrome. Complex regional pain syndrome (CRPS) induced by pacemaker implantation was diagnosed.

Author: Megumi Kisanuki, Kazumasa Fujita, Sh... Publish Year: 2017

Sick sinus syndrome associated with hypopituitarism: a ...

<https://www.ncbi.nlm.nih.gov/pmc/articles/PMC4197395>

Sick sinus syndrome (SSS) may result from various lesions of the sinoatrial node (SN) and its surrounding tissue and mainly manifests as sinus bradycardia combined with ectopic tachycardia. Several studies[1]-[4] have reported an association between autoimmune diseases and SSS.

Author: Dongsheng Zhao, Qing Zhang, Jingping... Publish Year: 2014

Related searches for Headache and sick sinus syndrome: a case r...

treatment of sick sinus syndrome

sick sinus syndrome mortality

sick sinus syndrome and afib

sick sinus syndrome ecg example

sick sinus syndrome ekg

sick sinus syndrome pacemaker

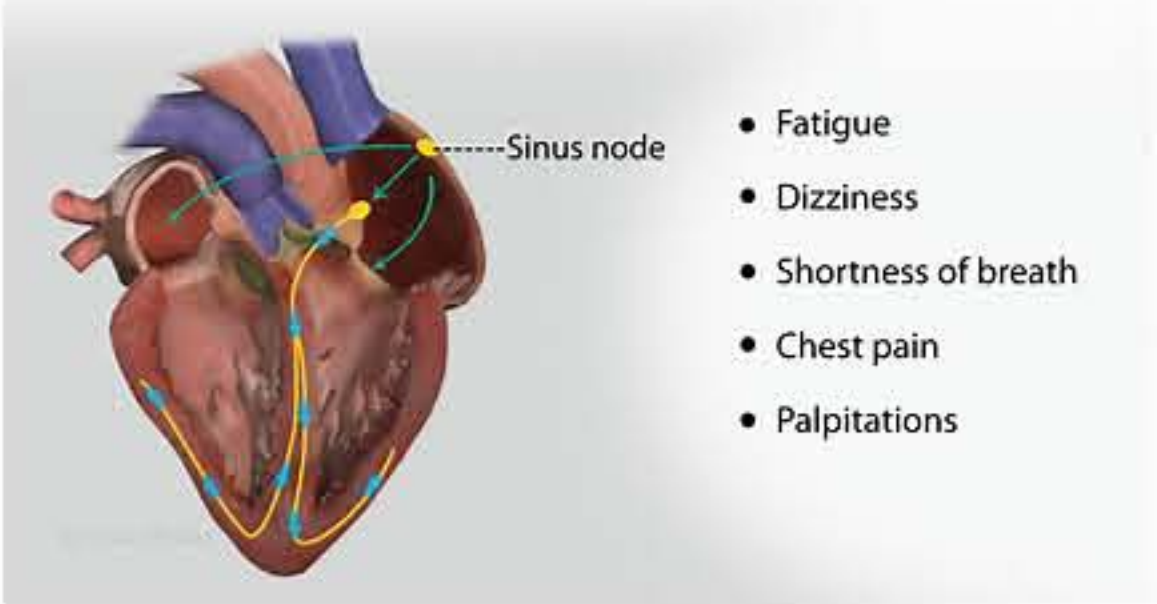
sick sinus syndrome ekg strip

sick sinus syndrome differential diagnosis

Sick Sinus Syndrome

Medical Condition

Dysfunction of the heart's pacemaker called sinoatrial node



A group of abnormal heart rhythms resulting from the malfunction of hearts primary pacemaker, sinus node.

Rare (Fewer than 200,000 cases per year in US)

Often requires lab test or imaging

Treatment from medical professional advised

Can be lifelong

It results from the conditions that cause scarring or damage to the electrical system of the heart. Slower than normal pulse rate of the heart (bradycardia) and fainting are the commonly observed symptoms. It can be managed by replacing the medicines resulting in this condition and putting artificial pacemakers to make the heart function normally.

Symptoms

The most commonly observed symptoms are:

- Fatigue
- Dizziness
- Fainting
- Shortness of breath
- Chest pain/angina
- Palpitations
- Bradycardia

Treatments

The treatment is based on the cause of the condition and aims at eliminating or decreasing the intensity of the symptoms.

Medication

- Antihypertensives: High blood pressure can be managed by Beta blockers and Calcium channel blockers. · Atenolol · Losartan
- Anti-arrhythmic drugs: Used to control the pace of the heart. Metoprolol · Bisoprolol · Amiodarone
- Blood thinners: Used in case of atrial fibrillation or other abnormal heart rhythms which increase the risk of stroke. Warfarin · Dabigatran

Medical procedures: Atrioventricular (AV) node ablation · Radiofrequency ablation · Replacement of pacemaker

Causes

Types of sick sinus syndrome are sinoatrial block, sinus arrest and bradycardia which occur due to the following causes:

- Conditions which cause scarring or damage heart electrical system
- Scar tissues from previous heart surgery
- Heart diseases
- Wear and tear of heart muscles in relation to age
- Some medicines used in management of high blood pressure such as calcium channel blockers and beta blockers like atenolol are also responsible

People also search for

Wolff-Parkinson-White Syndrome

Bradycardia

Atrial Fibrillation

Atrial Flutter

Third-degree atrioventricular block

See more

Data from Focus Medica. Reviewed by a panel of doctors.Learn more

Consult a medical professional for advice

Suggest an edit





国内版

国际版

Headache and sick sinus syndrome: A case report



ALL

IMAGES

VIDEOS

16,500,000 Results

Any time ▼

[PDF] Sick sinus syndrome - a case report of paroxysmal ...

www.clinicalcases.eu/index.php/acc/article/download/333/130

case of sick sinus syndrome when the patient's **symptoms** cannot be attributed to the **bradycardia**, but to the tachyarrhythmic episodes, it is often most efficient to treat the **patient's paroxysmal supraventricular tachycardia** by radiofrequency ablation, rather than using **cardiac pacing**.

Author: Ștefan Ailoei, Laura Cătălina Țăpoi... **Publish Year:** 2017

Marijuana Induced Sick Sinus Syndrome: A Case Report.

<https://www.ncbi.nlm.nih.gov/pubmed/31227686>

Jun 22, 2019 · Our **case** describes the association of abusing marijuana and the development of **sick sinus syndrome**. **CASE REPORT** A 27-year-old male carpenter was admitted to the hospital for recurrent syncopal episodes. He reported 2 episodes of syncope every month for the last 5 years. He denied alcohol or nicotine intake but **reports** using marijuana daily.

Cited by: 1

Author: Arshad Muhammad Iqbal, Ateeq Muba...

Publish Year: 2019

Myxedema coma accompanied by sick sinus syndrome and ...

<https://www.ncbi.nlm.nih.gov/pmc/articles/PMC6732564>

Cardiovascular complications with **severe hypothyroidism** include **sick sinus syndrome**, AV block, decreased **myocardial contractility**, low **cardiac output**, and **hypotension**. **Myxedema coma** requiring temporary or permanent pacemaker implantation is rare, and the requirement of the procedure is mainly due to second-degree or complete AV block.

Author: Ko Harada, Shuntaro Murakami, Ka... **Publish Year:** 2019



[PDF] Sick sinus syndrome - a case report of paroxysmal ...

www.clinicalcases.eu/index.php/acc/article/download/333/130

case of sick sinus syndrome when the patient's **symptoms** cannot be attributed to the **bradycardia**, but to the tachyarrhythmic episodes, it is often most efficient to treat the **patient's paroxysmal supraventricular tachycardia** by radiofrequency ablation, rather than using **cardiac pacing**.

Author: Ștefan Ailoei, Laura Cătălina Țăpoi, ... **Publish Year:** 2017

Marijuana Induced Sick Sinus Syndrome: A Case Report.

<https://www.ncbi.nlm.nih.gov/pubmed/31227686>

Jun 22, 2019 - Our **case** describes the association of abusing marijuana and the development of **sick sinus syndrome**. **CASE REPORT** A 27-year-old male carpenter was admitted to the hospital for recurrent syncopal episodes. He reported 2 episodes of syncope every month for the last 5 years. He denied alcohol or nicotine intake but **reports** using marijuana daily.

Cited by: 1 **Author:** Arshad Muhammad Iqbal, Ateeq Mubarik, ...

Publish Year: 2019

Sick Sinus Syndrome: A Review - PubMed

<https://pubmed.ncbi.nlm.nih.gov/23939447>

Sick sinus syndrome refers to a collection of disorders marked by the heart's inability to perform its pacemaking function. Predominantly affecting older adults, **sick sinus syndrome** comprises various arrhythmias, including bradyarrhythmias with or without accompanying tachyarrhythmias. At least 50 p ...

PEOPLE ALSO ASK

Is bradycardia a symptom of sick sinus syndrome? ▾

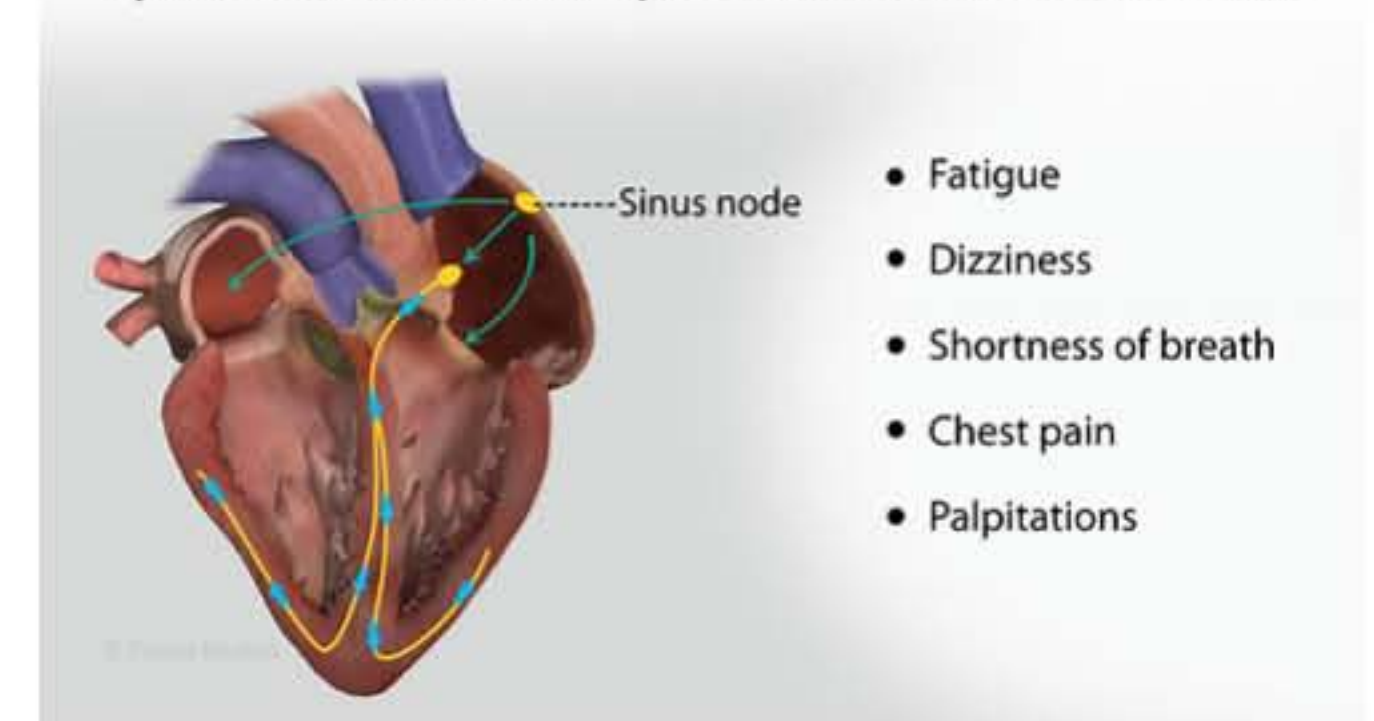
Can sick sinus syndrome be caused by a disease? ▾

What are the symptoms of sick sinus syndrome? ▾

Sick Sinus Syndrome

Medical Condition

Dysfunction of the heart's pacemaker called sinoatrial node



A group of abnormal heart rhythms resulting from the malfunction of hearts primary pacemaker, sinus node.

🏠 Rare (Fewer than 200,000 cases per year in US)

🧪 Often requires lab test or imaging

👨🏻‍⚕️ Treatment from medical professional advised

🕒 Can be lifelong

It results from the conditions that cause scarring or damage to the electrical system of the heart. Slower than normal pulse rate of the heart (bradycardia) and fainting are the commonly observed symptoms. It can be managed by replacing the medicines resulting in this condition and putting artificial pacemakers to make the heart function normally.

Symptoms