

World Journal of *Clinical Cases*

World J Clin Cases 2020 August 26; 8(16): 3377-3620



OPINION REVIEW

- 3377** Novel computerized psychometric tests as primary screening tools for the diagnosis of minimal hepatic encephalopathy
Luo M, Mu R, Liu JF, Bai FH

REVIEW

- 3390** Management of cancer patients during COVID-19 pandemic at developing countries
González-Montero J, Valenzuela G, Ahumada M, Barajas O, Villanueva L

MINIREVIEWS

- 3405** Liver in the limelight in the corona (COVID-19) time
Chela HK, Pasha SB, Basar O, Daglilar E, Tahan V
- 3411** Steroid-responsive pancreatitis
Pelaez-Luna M, Soriano-Rios A, Lira-Treviño AC, Uscanga-Domínguez L

ORIGINAL ARTICLE

Clinical and Translational Research

- 3431** Application of molybdenum target X-ray photography in imaging analysis of caudal intervertebral disc degeneration in rats
Su QH, Zhang Y, Shen B, Li YC, Tan J
- 3440** Accuracy study of a binocular-stereo-vision-based navigation robot for minimally invasive interventional procedures
Wang R, Han Y, Luo MZ, Wang NK, Sun WW, Wang SC, Zhang HD, Lu LJ

Retrospective Study

- 3450** Value of virtual bronchoscopic navigation and transbronchial ultrasound-guided sheath-guided exploration in diagnosis of peripheral lung cancer
Liu Y, Wang F, Zhang QC, Tong ZH
- 3458** Significance of serum fibroblast growth factor-23 and miR-208b in pathogenesis of atrial fibrillation and their relationship with prognosis
Chen JM, Zhong YT, Tu C, Lan J
- 3465** Home quarantine compliance is low in children with fever during COVID-19 epidemic
Lou Q, Su DQ, Wang SQ, Gao E, Li LQ, Zhuo ZQ

- 3474** Combination of endoscopic submucosal dissection and laparoscopic sentinel lymph node dissection in early mucinous gastric cancer: Role of lymph node metastasis

Li H, Zhao LL, Zhang XC, Liu DX, Wang GY, Huo ZB, Chen SB

- 3483** Factors affecting failed trial of labor and countermeasures: A retrospective analysis

Wang JG, Sun JL, Shen J

- 3493** Value of miR-1271 and glypican-3 in evaluating the prognosis of patients with hepatocellular carcinoma after transcatheter arterial chemoembolization

Guo Z, Wang J, Li L, Liu R, Fang J, Tie B

Observational Study

- 3503** Follow-up study on symptom distress in esophageal cancer patients undergoing repeated dilation

Liu L, Liu QW, Wu XD, Liu SY, Cao HJ, Hong YT, Qin HY

- 3515** Long-term medical treatment of patients with severe burns at exposed sites

Du Y, Lv GZ, Yu S, Wang D, Tan Q

CASE REPORT

- 3527** Laparoscopic management of a giant mucinous benign ovarian mass weighing 10150 grams: A case report

Sanna E, Madeddu C, Melis L, Nemolato S, Macciò A

- 3534** Concurrent hepatocellular carcinoma metastasis to stomach, colon, and brain: A case report

Kim R, Song J, Kim SB

- 3542** Disseminated osteomyelitis after urinary tract infection in immunocompetent adult: A case report

Kim YJ, Lee JH

- 3548** Pelvic lipomatosis and renal transplantation: A case report

Zhao J, Fu YX, Feng G, Mo CB

- 3553** Intestinal obstruction in pregnancy with reverse rotation of the midgut: A case report

Zhao XY, Wang X, Li CQ, Zhang Q, He AQ, Liu G

- 3560** Clinical laboratory investigation of a patient with an extremely high D-dimer level: A case report

Sun HX, Ge H, Xu ZQ, Sheng HM

- 3567** Recovery from a biliary stricture of a common bile duct ligature injury: A case report

Fan Z, Pan JY, Zhang YW

- 3573** Spontaneous pneumomediastinum in an elderly COVID-19 patient: A case report

Kong N, Gao C, Xu MS, Xie YL, Zhou CY

- 3578** Acute generalized exanthematous pustulosis with airway mucosa involvement: A case report

Li LL, Lu YQ, Li T

- 3583** Multifocal neuroendocrine cell hyperplasia accompanied by tumorlet formation and pulmonary sclerosing pneumocytoma: A case report
Han XY, Wang YY, Wei HQ, Yang GZ, Wang J, Jia YZ, Ao WQ
- 3591** Giant benign phyllodes breast tumour with pulmonary nodule mimicking malignancy: A case report
Zhang T, Feng L, Lian J, Ren WL
- 3601** Spontaneous multivessel coronary artery spasm diagnosed with intravascular ultrasound imaging: A case report
Wu HY, Cao YW, Chang FJ, Liang L
- 3608** Delayed perforation after endoscopic resection of a colonic laterally spreading tumor: A case report and literature review
Zhou GYJ, Hu JL, Wang S, Ge N, Liu X, Wang GX, Sun SY, Guo JT
- 3616** First branchial cleft cyst accompanied by external auditory canal atresia and middle ear malformation: A case report
Zhang CL, Li CL, Chen HQ, Sun Q, Liu ZH

ABOUT COVER

Editorial board member of *World Journal of Clinical Cases*, Dr. Kvolik is a Professor in the School of Medicine, Osijek University, Croatia. She obtained her MD degree, with specialization in the field of anesthesiology, resuscitation and intensive care from the Zagreb Medical School, Croatia. Afterwards, she undertook postgraduate training in Clinical Pharmacology at the same institution, defending both a Master's thesis and PhD thesis. In 2006, she joined the Osijek University Medical Faculty as a lecturer and was promoted to Professor in 2009. In 2012, she was elected Head of the Department of Anesthesiology, Resuscitation, Intensive Care and Pain Therapy, a position she occupies to this day. She is also the current Head of the Intensive Care Unit at the Osijek University Hospital, Croatia. (L-Editor: Filipodia)

AIMS AND SCOPE

The primary aim of *World Journal of Clinical Cases* (*WJCC*, *World J Clin Cases*) is to provide scholars and readers from various fields of clinical medicine with a platform to publish high-quality clinical research articles and communicate their research findings online.

WJCC mainly publishes articles reporting research results and findings obtained in the field of clinical medicine and covering a wide range of topics, including case control studies, retrospective cohort studies, retrospective studies, clinical trials studies, observational studies, prospective studies, randomized controlled trials, randomized clinical trials, systematic reviews, meta-analysis, and case reports.

INDEXING/ABSTRACTING

The *WJCC* is now indexed in Science Citation Index Expanded (also known as SciSearch®), Journal Citation Reports/Science Edition, PubMed, and PubMed Central. The 2020 Edition of Journal Citation Reports® cites the 2019 impact factor (IF) for *WJCC* as 1.013; IF without journal self cites: 0.991; Ranking: 120 among 165 journals in medicine, general and internal; and Quartile category: Q3.

RESPONSIBLE EDITORS FOR THIS ISSUE

Production Editor: Ji-Hong Lin; Production Department Director: Xiang Li; Editorial Office Director: Jin-Lai Wang.

NAME OF JOURNAL

World Journal of Clinical Cases

ISSN

ISSN 2307-8960 (online)

LAUNCH DATE

April 16, 2013

FREQUENCY

Semimonthly

EDITORS-IN-CHIEF

Dennis A Bloomfield, Sandro Vento, Bao-Gan Peng

EDITORIAL BOARD MEMBERS

<https://www.wjgnet.com/2307-8960/editorialboard.htm>

PUBLICATION DATE

August 26, 2020

COPYRIGHT

© 2020 Baishideng Publishing Group Inc

INSTRUCTIONS TO AUTHORS

<https://www.wjgnet.com/bpg/gerinfo/204>

GUIDELINES FOR ETHICS DOCUMENTS

<https://www.wjgnet.com/bpg/GerInfo/287>

GUIDELINES FOR NON-NATIVE SPEAKERS OF ENGLISH

<https://www.wjgnet.com/bpg/gerinfo/240>

PUBLICATION ETHICS

<https://www.wjgnet.com/bpg/GerInfo/288>

PUBLICATION MISCONDUCT

<https://www.wjgnet.com/bpg/gerinfo/208>

ARTICLE PROCESSING CHARGE

<https://www.wjgnet.com/bpg/gerinfo/242>

STEPS FOR SUBMITTING MANUSCRIPTS

<https://www.wjgnet.com/bpg/GerInfo/239>

ONLINE SUBMISSION

<https://www.f6publishing.com>

Pelvic lipomatosis and renal transplantation: A case report

Jie Zhao, Ying-Xin Fu, Gang Feng, Chun-Bai Mo

ORCID number: Jie Zhao 0000-0002-6450-5046; Ying-Xin Fu 0000-0001-8010-224X; Gang Feng 0000-0002-1627-372X; Chun-Bai Mo 0000-0002-2426-5519.

Author contributions: Zhao J summarized the clinical data, and drafted the manuscript; Fu YX contributed to the conception of the study; Mo CB and Feng G performed the operation.

Supported by National Natural Science Foundation of China, No. 81970654.

Informed consent statement: Informed written consent was obtained from the patient for publication of this report and any accompanying images.

Conflict-of-interest statement: The authors declare that they have no conflict of interest.

CARE Checklist (2016) statement: The authors have read the CARE Checklist (2016), and the manuscript was prepared and revised according to the CARE Checklist (2016).

Open-Access: This article is an open-access article that was selected by an in-house editor and fully peer-reviewed by external reviewers. It is distributed in accordance with the Creative Commons Attribution NonCommercial (CC BY-NC 4.0)

Jie Zhao, Ying-Xin Fu, Gang Feng, Chun-Bai Mo, Department of Kidney Transplant, Tianjin First Central Hospital, Tianjin 300192, China

Corresponding author: Ying-Xin Fu, MD, PhD, Chief Doctor, Surgeon, Department of Kidney Transplant, Tianjin First Central Hospital, No. 24 Fukang Road, Nankai District, Tianjin 300192, China. fuyingxintj@163.com

Abstract

BACKGROUND

Pelvic lipomatosis is a rare disease of unknown etiology, characterized by the overgrowth of pelvic adipose tissue that causes compression of the urinary tract including the bladder and ureters, rectum and blood vessels. The patient may progressively develop obstructive uropathy which could subsequently lead to renal failure. At present, there are no reports of renal transplantation due to uremia caused by pelvic lipomatosis. The ideal management of patients with pelvic lipomatosis after renal transplantation is not yet well-established due to the lack of literature and follow-up data.

CASE SUMMARY

We report a 37-year-old male patient with pelvic lipomatosis who received a successful living donor renal transplantation on July 22, 2015. The operation was complicated as the iliac vessels and bladder were wrapped entirely in excessive abnormal fat. The external iliac artery and vein were located using ultrasonographic guidance. The adipose tissue around the right bladder was removed as far as possible, and the graft ureter was reimplanted into the bladder, using the Lich-Gregoir technique. At 22 mo after transplantation, graft percutaneous nephrostomy was performed under ultrasonographic guidance for urinary diversion due to hydronephrosis of the graft kidney. Follow-up at four years showed that the renal allograft function was stable.

CONCLUSION

When patients with pelvic lipomatosis develop renal failure, renal transplantation could be a feasible treatment strategy.

Key words: Pelvic lipomatosis; Kidney transplantation; Uremia; Hydronephrosis; Bladder; Urinary obstruction; Case report

©The Author(s) 2020. Published by Baishideng Publishing Group Inc. All rights reserved.

license, which permits others to distribute, remix, adapt, build upon this work non-commercially, and license their derivative works on different terms, provided the original work is properly cited and the use is non-commercial. See: <http://creativecommons.org/licenses/by-nc/4.0/>

Manuscript source: Unsolicited manuscript

Received: April 6, 2020

Peer-review started: April 6, 2020

First decision: April 24, 2020

Revised: May 1, 2020

Accepted: July 16, 2020

Article in press: July 16, 2020

Published online: August 26, 2020

P-Reviewer: Granata A, Pham PTT

S-Editor: Zhang L

L-Editor: Webster JR

P-Editor: Liu JH



Core tip: We describe a patient with pelvic lipomatosis who underwent renal transplantation due to uremia. Such patients may progressively develop obstructive uropathy which can subsequently lead to renal failure. At present, there are no reports of renal transplantation due to uremia caused by pelvic lipomatosis. The ideal management of patients with pelvic lipomatosis after renal transplantation is not yet well-established due to the lack of literature and follow-up data.

Citation: Zhao J, Fu YX, Feng G, Mo CB. Pelvic lipomatosis and renal transplantation: A case report. *World J Clin Cases* 2020; 8(16): 3548-3552

URL: <https://www.wjgnet.com/2307-8960/full/v8/i16/3548.htm>

DOI: <https://dx.doi.org/10.12998/wjcc.v8.i16.3548>

INTRODUCTION

Pelvic lipomatosis is a rare disease of unknown etiology, characterized by the overgrowth of pelvic adipose tissue that causes compression of the urinary tract including the bladder and ureters, rectum and blood vessels^[1]. These patients progressively develop obstructive uropathy, and 40% deteriorate into renal failure after an average period of five years^[2-4]. At present, there are no reports of renal transplantation due to uremia caused by pelvic lipomatosis. The bladder and iliac vessels are entirely wrapped in this abnormal fat, making it difficult to dissociate iliac vessels and bladder during renal transplantation. Urinary tract obstruction may occur again after renal transplantation. The ideal management of patients with pelvic lipomatosis after renal transplantation is not yet well-established due to the lack of literature and follow-up data. Here, we report a 37-year-old male patient with pelvic lipomatosis who received a successful living donor renal transplantation.

CASE PRESENTATION

Chief complaints

A 37-year-old male patient presented to our hospital with complaints of fatigue and vomiting for two weeks on November 18, 2014.

History of present illness

On admission, a computed tomography (CT) scan showed bilateral severe hydronephrosis and a compressed and thick-walled bladder and extra fat tissues in the pelvis (Figure 1). The patient underwent cystoscopy, which showed an elongation of the prostatic urethra and elevation of the bladder neck. There were several bullous lesions over the wall of the neck and the trigone of the bladder. The bilateral ureteral orifices were not identified. A double "J" ureteral stent could not be placed appropriately. Tissue biopsy of the bladder demonstrated cystitis glandularis (Figure 2A). Bilateral percutaneous nephrostomy was performed under ultrasonographic guidance. Anterograde urography revealed bilateral hydronephrosis and tortuous dilated ureter, symmetrical compression and elevation of the bladder (a pear-shaped bladder) (Figure 3). Thus, a diagnosis of pelvic lipomatosis was confirmed. Despite an output of 1000-1500 mL urine in 24 h, renal function did not improve. The patient was diagnosed with end-stage renal disease and underwent hemodialysis.

History of past illness

He also had a history of persistent suprapubic pain and nocturia (2-3 times) for more than four years and a single episode of gross hematuria.

Physical examination

On admission, his height was 170 cm and weight was 71 kg, with a body mass index of 24. The physical examination revealed a palpable suprapubic mass and mild edema of both lower legs.

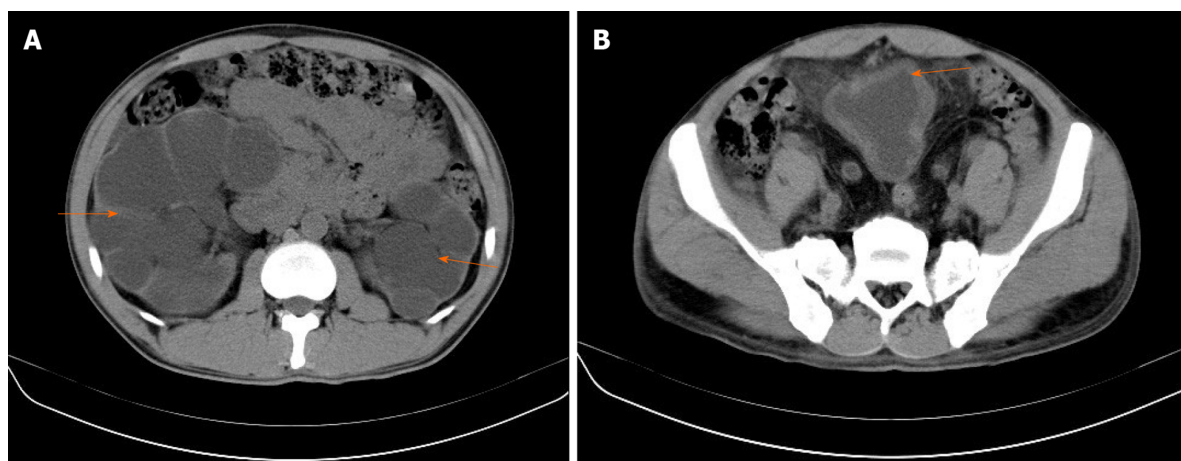


Figure 1 Computed tomography examination. A: Computed tomography showed bilateral hydronephrosis (orange arrow); B: A thick walled urinary bladder (orange arrow) with increased fat density around the bladder.

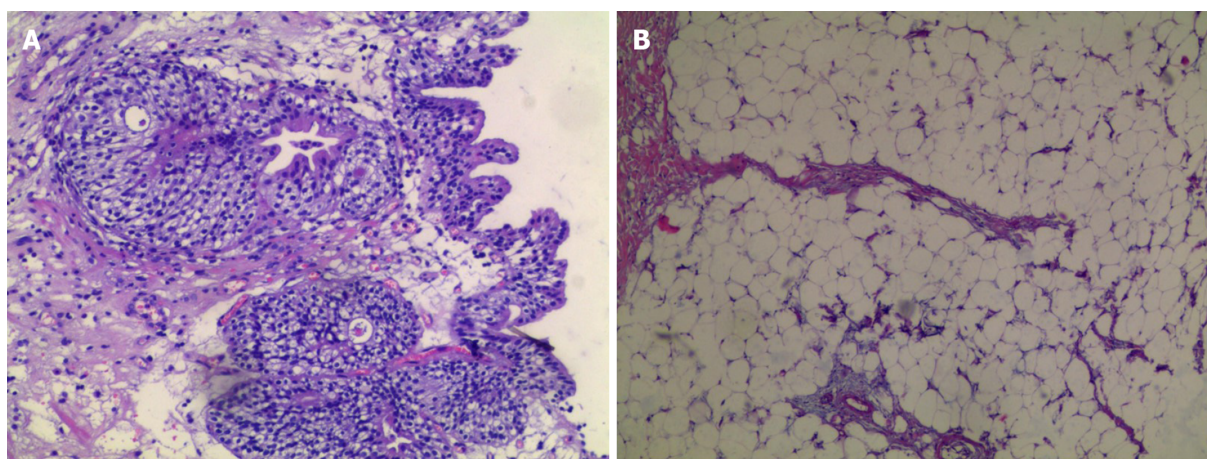


Figure 2 Histopathological examination. A: Tissue biopsy of the bladder demonstrated cystitis glandularis; B: Histopathological examination of the fat showed a benign lipomatous lesion.

Laboratory examinations

His serum creatinine was 1500 $\mu\text{mol/L}$ and hemoglobin was 79 g/L.

Imaging examinations

Anterograde urography revealed bilateral hydronephrosis and tortuous dilated ureter, symmetrical compression and elevation of the bladder (a pear-shaped bladder) (Figure 3).

FINAL DIAGNOSIS

End-stage renal disease, pelvic lipomatosis, hydronephrosis.

TREATMENT

Bilateral nephrectomy and living donor renal transplantation (kidney obtained from his brother) were performed on July 22, 2015. The operation was complicated as the iliac vessels and bladder were completely wrapped in excessive abnormal fat. The external iliac artery and vein were located using ultrasonographic guidance. The adipose tissue around the right bladder was removed as far as possible, and the graft ureter was reimplanted into the bladder, using the Lich-Gregoir technique. Histopathological examination of the fat showed a benign lipomatous lesion

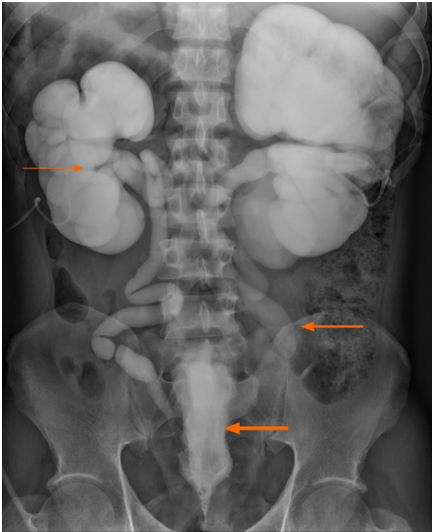


Figure 3 Anterograde urography revealed bilateral hydronephrosis (thin orange arrow) and tortuous dilated ureter (orange arrow), symmetrical compression and elevation of the bladder (a pear-shaped bladder) (thick orange arrow).

(Figure 2B). The double “J” stents were removed three months after the operation. Serum creatinine was 120 $\mu\text{mol/L}$ after transplantation.

OUTCOME AND FOLLOW-UP

At six months postoperatively, mild hydronephrosis in the graft kidney was identified by magnetic resonance urography (Figure 4A), and graft function was stable. However, B-ultrasound showed moderate hydronephrosis at 22 mo after transplantation. Graft percutaneous nephrostomy was performed under ultrasonographic guidance for urinary diversion (Figure 4B). During the four-year follow-up period, the patient was in a stable condition and serum creatinine was 121 $\mu\text{mol/L}$.

DISCUSSION

Pelvic lipomatosis is a rare condition defined as a non-malignant overgrowth of normal fat in the pelvis. It was previously reported that the incidence of pelvic lipomatosis was 0.6-1.7 per 100000 hospital admissions in the United States^[5]. Clinical manifestations are due to various compression phenomena spanning the rectum (constipation, tenesmus), the urinary tract (lower urinary tract symptoms), and venous structures (lower limb edema and thrombosis). The best definitive diagnostic procedure is CT, which demonstrates increased adipose tissue surrounding the bladder and rectum. A pear-shaped bladder and hydronephrosis are common findings on the CT urogram and are important characteristic indications of pelvic lipomatosis^[2].

However, the etiology of pelvic lipomatosis is unknown. To date, various methods to treat pelvic lipomatosis, including steroids, long-term antibiotics, weight reduction, and radiation therapy have been proven to be ineffective^[1]. The recommended management strategy includes close monitoring of the development and progression of hydronephrosis and renal function. When obstruction develops, an appropriate diversion can be performed by ureteral reimplantation, nephrostomy, ureterostomy or a conduit^[6]. Klein *et al*^[7] reported that urinary diversion was eventually required in 39% of patients during a 7.5-year follow-up period^[7]. The surgical removal of adipose tissue surrounding the bladder does not lead to a radiological abnormality or remission of the condition^[8].

When bilateral hydronephrosis progresses, 40% of patients deteriorate into renal failure after an average period of five years and kidney transplantation can be considered. Even though excision of the pelvic fat and dissection of adhesions of the external vessels and bladder may be difficult, transplantation is not entirely impossible. Reconstruction of the urinary tract can be considered according to

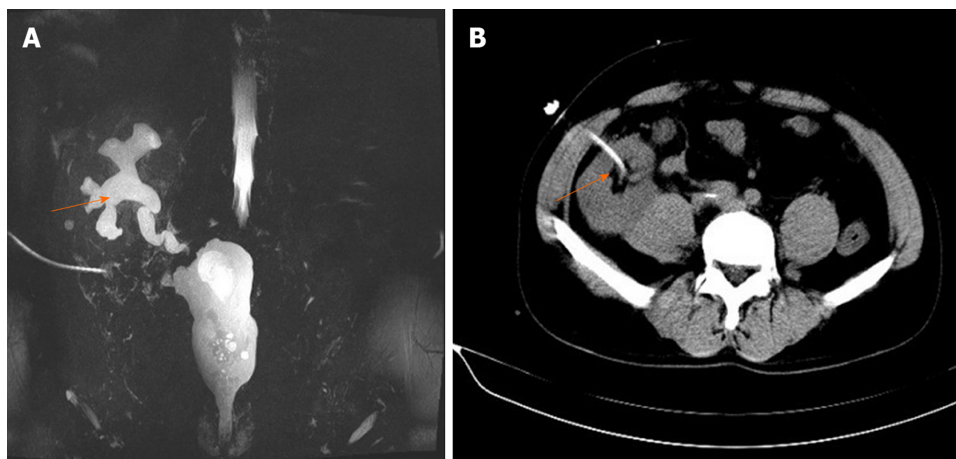


Figure 4 Magnetic resonance urography. A: Magnetic resonance urography show mild hydronephrosis in the graft kidney at 6 mo postoperation (orange arrow); B: Graft percutaneous nephrostomy was performed under ultrasonographic guidance for urinary diversion (orange arrow).

conventional ureteral bladder replantation. The recurrence of graft urinary obstruction associated with pelvic lipomatosis is also possible. However, there are no literature reports on the recurrence of ureteral obstruction after renal transplantation. The recommended management strategy includes close monitoring of the graft renal function, and if progression due to obstruction is observed, urinary diversion should be considered.

We are also concerned that the graft renal vein and external iliac vein may be compressed by excess adipose tissue after the operation, leading to thrombosis. Currently, there are several reports of deep venous thrombosis in patients with pelvic lipomatosis^[9-11]. Schechter^[9] reported a patient with venous thrombosis of the left iliac vein as a result of pelvic lipomatosis. Therefore, we administered aspirin to prevent venous thrombosis, and no thrombosis was found during the follow-up period.

CONCLUSION

When patients with pelvic lipomatosis develop renal failure, renal transplantation could be a feasible treatment strategy.

REFERENCES

- 1 Heyns CF. Pelvic lipomatosis: a review of its diagnosis and management. *J Urol* 1991; **146**: 267-273 [PMID: 1856914 DOI: 10.1016/s0022-5347(17)37767-4]
- 2 Xia S, Yan Y, Peng B, Yang B, Zheng J. Image characteristics of computer tomography urography in pelvic lipomatosis. *Int J Clin Exp Med* 2014; **7**: 296-299 [PMID: 24482720]
- 3 Golding PL, Singh M, Worthington B. Bilateral ureteric obstruction caused by benign pelvic lipomatosis. *Br J Surg* 1972; **59**: 69-72 [PMID: 5007675 DOI: 10.1002/bjs.1800590119]
- 4 Crane DB, Smith MJ. Pelvic lipomatosis: 5-year followup. *J Urol* 1977; **118**: 547-550 [PMID: 916046 DOI: 10.1016/s0022-5347(17)58103-3]
- 5 Old WL Jr, Stokes TL. Pelvic lipomatosis. *Surgery* 1978; **83**: 173-180 [PMID: 622692]
- 6 Miglani U, Sinha T, Gupta SK, Doddamani D, Sethi GS, Talwar R, Agrawal S, Chandra M, Rana YP, Harker S. Rare etiology of obstructive uropathy: pelvic lipomatosis. *Urol Int* 2010; **84**: 239-241 [PMID: 20215833 DOI: 10.1159/000277606]
- 7 Klein FA, Smith MJ, Kasenetz I. Pelvic lipomatosis: 35-year experience. *J Urol* 1988; **139**: 998-1001 [PMID: 3361678 DOI: 10.1016/s0022-5347(17)42744-3]
- 8 Prabakaran R, Abraham G, Kurien A, Mathew M, Parthasarathy R. Pelvic lipomatosis. *Kidney Int* 2016; **90**: 453 [PMID: 27418096 DOI: 10.1016/j.kint.2016.05.009]
- 9 Schechter LS. Venous obstruction in pelvic lipomatosis. *J Urol* 1974; **111**: 757-759 [PMID: 4830877 DOI: 10.1016/s0022-5347(17)60065-x]
- 10 Locko RC, Interrante AL. Pelvic lipomatosis. Case of inferior vena caval obstruction. *JAMA* 1980; **244**: 1473-1474 [PMID: 7420639 DOI: 10.1001/jama.244.13.1473]
- 11 Sercan Ö. Pelvic lipomatosis associated with portal vein thrombosis and hydronephrosis: a case report. *J Int Med Res* 2019; **47**: 2674-2678 [PMID: 30971132 DOI: 10.1177/0300060519840912]



Published by **Baishideng Publishing Group Inc**
7041 Koll Center Parkway, Suite 160, Pleasanton, CA 94566, USA

Telephone: +1-925-3991568

E-mail: bpgoffice@wjgnet.com

Help Desk: <https://www.f6publishing.com/helpdesk>

<https://www.wjgnet.com>

