

World Journal of *Clinical Cases*

World J Clin Cases 2020 September 6; 8(17): 3621-3919



Contents

Semimonthly Volume 8 Number 17 September 6, 2020

REVIEW

- 3621 Autoimmunity as the comet tail of COVID-19 pandemic
Talotta R, Robertson E
- 3645 Gender medicine: Lessons from COVID-19 and other medical conditions for designing health policy
Machluf Y, Chaïter Y, Tal O

MINIREVIEWS

- 3669 Complexities of diagnosis and management of COVID-19 in autoimmune diseases: Potential benefits and detriments of immunosuppression
Georgiev T, Angelov AK

ORIGINAL ARTICLE

Retrospective Study

- 3691 Emergency surgery in COVID-19 outbreak: Has anything changed? Single center experience
D'Urbano F, Fabbri N, Koleva Radica M, Rossin E, Carcoforo P
- 3697 Somatostatin receptor scintigraphy in the follow up of neuroendocrine neoplasms of appendix
Saponjski J, Macut D, Sobic-Saranovic D, Ognjanovic S, Bozic Antic I, Pavlovic D, Artiko V
- 3708 Efficacy of stool multiplex polymerase chain reaction assay in adult patients with acute infectious diarrhea
Ahn JS, Seo SI, Kim J, Kim T, Kang JG, Kim HS, Shin WG, Jang MK, Kim HY
- 3718 Comparison of gemcitabine plus nab-paclitaxel and FOLFIRINOX in metastatic pancreatic cancer
Han SY, Kim DU, Seol YM, Kim S, Lee NK, Hong SB, Seo HI
- 3730 Shear wave elastography may be sensitive and more precise than transient elastography in predicting significant fibrosis
Yao TT, Pan J, Qian JD, Cheng H, Wang Y, Wang GQ
- 3743 Radioactive ¹²⁵I seed implantation for locally advanced pancreatic cancer: A retrospective analysis of 50 cases
Li CG, Zhou ZP, Jia YZ, Tan XL, Song YY
- 3751 Active surveillance in metastatic pancreatic neuroendocrine tumors: A 20-year single-institutional experience
Gao HL, Wang WQ, Xu HX, Wu CT, Li H, Ni QX, Yu XJ, Liu L
- 3763 Clinical efficacy of tocilizumab treatment in severe and critical COVID-19 patients
Zeng J, Xie MH, Yang J, Chao SW, Xu EL

- 3774** Phosphatidylinositol-3,4,5-trisphosphate dependent Rac exchange factor 1 is a diagnostic and prognostic biomarker for hepatocellular carcinoma

Cai Y, Zheng Q, Yao DJ

Observational Study

- 3786** Awareness and attitude of fecal microbiota transplantation through transendoscopic enteral tubing among inflammatory bowel disease patients

Zhong M, Sun Y, Wang HG, Marcella C, Cui BT, Miao YL, Zhang FM

CASE REPORT

- 3797** Cauda equina arachnoiditis – a rare manifestation of West Nile virus neuroinvasive disease: A case report

Santini M, Zupetic I, Viskovic K, Krznaric J, Kutlesa M, Krajinovic V, Polak VL, Savic V, Tabain I, Barbic L, Bogdanic M, Stevanovic V, Mrzljak A, Vilbic-Cavlek T

REVIEW

- 3804** Portal gas in neonates; is it always surgical? A case report

Altokhais TI

CASE REPORT

- 3808** Large lingual heterotopic gastrointestinal cyst in a newborn: A case report

Lee AD, Harada K, Tanaka S, Yokota Y, Mima T, Enomoto A, Kogo M

- 3814** Osteochondral lesion of talus with gout tophi deposition: A case report

Kim T, Choi YR

- 3821** Traumatic neuroma of remnant cystic duct mimicking duodenal subepithelial tumor: A case report

Kim DH, Park JH, Cho JK, Yang JW, Kim TH, Jeong SH, Kim YH, Lee YJ, Hong SC, Jung EJ, Ju YT, Jeong CY, Kim JY

- 3828** Autoimmune hepatitis in a patient with immunoglobulin A nephropathy: A case report

Jeon YH, Kim DW, Lee SJ, Park YJ, Kim HJ, Han M, Kim IY, Lee DW, Song SH, Lee SB, Seong EY

- 3835** Diagnosis of an actively bleeding brachial artery hematoma by contrast-enhanced ultrasound: A case report

Ma JJ, Zhang B

- 3841** Lung adenocarcinoma harboring rare epidermal growth factor receptor L858R and V834L mutations treated with icotinib: A case report

Zhai SS, Yu H, Gu TT, Li YX, Lei Y, Zhang HY, Zhen TH, Gao YG

- 3847** Gastroduodenitis associated with ulcerative colitis: A case report

Yang Y, Li CQ, Chen WJ, Ma ZH, Liu G

- 3853** Majocchi's granuloma caused by *Trichophyton rubrum* after facial injection with hyaluronic acid: A case report

Liu J, Xin WQ, Liu LT, Chen CF, Wu L, Hu XP

- 3859** Novel deletion mutation in Bruton's tyrosine kinase results in X-linked agammaglobulinemia: A case report
Hu XM, Yuan K, Chen H, Chen C, Fang YL, Zhu JF, Liang L, Wang CL
- 3867** Multidisciplinary treatment of life-threatening hemoptysis and paraplegia of choriocarcinoma with pulmonary, hepatic and spinal metastases: A case report
Lin YY, Sun Y, Jiang Y, Song BZ, Ke LJ
- 3875** Diagnostic value of ultrasound in the spontaneous rupture of renal angiomyolipoma during pregnancy: A case report
Zhang T, Xue S, Wang ZM, Duan XM, Wang DX
- 3881** Gallbladder sarcomatoid carcinoma: Seven case reports
Qin Q, Liu M, Wang X
- 3890** Surgical strategy used in multilevel cervical disc replacement and cervical hybrid surgery: Four case reports
Wang XF, Meng Y, Liu H, Hong Y, Wang BY
- 3903** Diagnosis and treatment of an elderly patient with 2019-nCoV pneumonia and acute exacerbation of chronic obstructive pulmonary disease in Gansu Province: A case report
He TP, Wang DL, Zhao J, Jiang XY, He J, Feng JK, Yuan Y
- 3911** Diagnosis and treatment of mixed infection of hepatic cystic and alveolar *echinococcosis*: Four case reports
A JD, Chai JP, Wang H, Gao W, Peng Z, Zhao SY, A XR

ABOUT COVER

Editorial board member of World Journal of Clinical Cases, Dr. Elia de Maria is Adjunct Professor of Arrhythmology Lab in the Cardiology Unit, Ramazzini Hospital in Carpi, Italy. He graduated in Medicine and Surgery from the University of Napoli in 1999, continuing on to obtain specialization in Cardiology in 2003. He also holds the distinction of High Degree Master in Electrophysiology and Cardiac Stimulation. Since 2005, he has practiced as a Permanent Consultant Cardiologist in the Italian Public Hospitals, and since 2015 as an External Contract Professor in the Faculty of Medicine and Surgery of University of Verona. His clinical and research interests encompass pharmacological therapy in acute and chronic cardiac conditions, temporary and definitive pacing, thoracentesis and pericardiocentesis, and hemodynamic monitoring. (L-Editor: Filipodia)

AIMS AND SCOPE

The primary aim of *World Journal of Clinical Cases (WJCC, World J Clin Cases)* is to provide scholars and readers from various fields of clinical medicine with a platform to publish high-quality clinical research articles and communicate their research findings online.

WJCC mainly publishes articles reporting research results and findings obtained in the field of clinical medicine and covering a wide range of topics, including case control studies, retrospective cohort studies, retrospective studies, clinical trials studies, observational studies, prospective studies, randomized controlled trials, randomized clinical trials, systematic reviews, meta-analysis, and case reports.

INDEXING/ABSTRACTING

The *WJCC* is now indexed in Science Citation Index Expanded (also known as SciSearch®), Journal Citation Reports/Science Edition, PubMed, and PubMed Central. The 2020 Edition of Journal Citation Reports® cites the 2019 impact factor (IF) for *WJCC* as 1.013; IF without journal self cites: 0.991; Ranking: 120 among 165 journals in medicine, general and internal; and Quartile category: Q3.

RESPONSIBLE EDITORS FOR THIS ISSUE

Production Editor: Yan-Xia Xing; Production Department Director: Yun-Xiaojian Wu; Editorial Office Director: Jin-Lai Wang.

NAME OF JOURNAL

World Journal of Clinical Cases

ISSN

ISSN 2307-8960 (online)

LAUNCH DATE

April 16, 2013

FREQUENCY

Semimonthly

EDITORS-IN-CHIEF

Dennis A Bloomfield, Sandro Vento, Bao-Gan Peng

EDITORIAL BOARD MEMBERS

<https://www.wjgnet.com/2307-8960/editorialboard.htm>

PUBLICATION DATE

September 6, 2020

COPYRIGHT

© 2020 Baishideng Publishing Group Inc

INSTRUCTIONS TO AUTHORS

<https://www.wjgnet.com/bpg/gerinfo/204>

GUIDELINES FOR ETHICS DOCUMENTS

<https://www.wjgnet.com/bpg/GerInfo/287>

GUIDELINES FOR NON-NATIVE SPEAKERS OF ENGLISH

<https://www.wjgnet.com/bpg/gerinfo/240>

PUBLICATION ETHICS

<https://www.wjgnet.com/bpg/GerInfo/288>

PUBLICATION MISCONDUCT

<https://www.wjgnet.com/bpg/gerinfo/208>

ARTICLE PROCESSING CHARGE

<https://www.wjgnet.com/bpg/gerinfo/242>

STEPS FOR SUBMITTING MANUSCRIPTS

<https://www.wjgnet.com/bpg/GerInfo/239>

ONLINE SUBMISSION

<https://www.f6publishing.com>



Lung adenocarcinoma harboring rare epidermal growth factor receptor L858R and V834L mutations treated with icotinib: A case report

Shu-Sen Zhai, Hui Yu, Tian-Tian Gu, Yan-Xia Li, Yan Lei, Hai-Yan Zhang, Tong-Huan Zhen, Yun-Ge Gao

ORCID number: Shu-Sen Zhai 0000-0002-5008-1182; Hui Yu 0000-0002-7110-2827; Tian-Tian Gu 0000-0002-9534-2497; Yan-Xia Li 0000-0002-1843-6676; Yan Lei 0000-0001-7083-9002; Hai-Yan Zhang 0000-0001-7461-8995; Tong-Huan Zhen 0000-0002-1868-3714; Yun-Ge Gao 0000-0002-3737-3199.

Author contributions: Zhai SS, Lei Y, Zhang HY, Zhen TH and Gao YG treated the patient; Yu Hand Gu TT wrote and edited the case report; Li YX made pathological interpretation; All authors read and approved the final manuscript; all authors contributed to the study conception and design.

Informed consent statement: Informed written consent was obtained from the patient for publication of this report and any accompanying images.

Conflict-of-interest statement: The authors declare that they have no conflicts of interest.

CARE Checklist (2016) statement: The authors have read the CARE Checklist (2016), and the manuscript was prepared and revised according to the CARE Checklist (2016).

Open-Access: This article is an

Shu-Sen Zhai, Yan Lei, Hai-Yan Zhang, Tong-Huan Zhen, Yun-Ge Gao, Oncology Section, PLA Strategic Support Force Characteristic Medical Center, Beijing 100101, China

Hui Yu, Tian-Tian Gu, Yan-Xia Li, Cancer Research Institute, YuceBio, Shenzhen 518000, Guangdong Province, China

Corresponding author: Yun-Ge Gao, MD, PhD, Chief Doctor, Oncology Section, PLA Strategic Support Force Characteristic Medical Center, No. 9 Anxiang North Lane, Chaoyang District, Beijing 100101, China. gaoyunge306dr@163.com

Abstract

BACKGROUND

Epidermal growth factor receptor (EGFR) tyrosine-kinase inhibitors are widely used for the treatment of non-small-cell lung cancer with *EGFR* mutations. However, patients with rare, even compound *EGFR* mutations have different responses to EGFR-tyrosine-kinase inhibitors, which bring uncertainty to clinical treatment.

CASE SUMMARY

A 45-year-old female patient presented with a 3-mo history of cough and white sputum without chest pain. Chest computed tomography revealed lung space-occupying lesions and multiple lymphadenectasis. Bronchoscopy and pathology suggested lung adenocarcinoma. Compound variation of *EGFR* gene (exon 21 L858R/V834L) was detected in both tissue and circulating tumor deoxyribonucleic acid samples. As a result of next-generation sequencing and her family's wishes, the patient was given oral treatment with icotinib hydrochloride (125 mg/d, tid) from March 21, 2019 and has achieved stable disease for the last 1 year.

CONCLUSION

Non-small cell lung adenocarcinoma with *EGFR* L858R/V834L was treated successfully with icotinib, and it may be a new medication treatment option.

Key words: Icotinib hydrochloride; Epidermal growth factor receptor L858R/V834L; Non-small cell lung cancer; Stable disease; Case report

open-access article that was selected by an in-house editor and fully peer-reviewed by external reviewers. It is distributed in accordance with the Creative Commons Attribution NonCommercial (CC BY-NC 4.0) license, which permits others to distribute, remix, adapt, build upon this work non-commercially, and license their derivative works on different terms, provided the original work is properly cited and the use is non-commercial. See: <http://creativecommons.org/licenses/by-nc/4.0/>

Manuscript source: Unsolicited manuscript

Received: May 12, 2020

Peer-review started: May 12, 2020

First decision: May 21, 2020

Revised: June 2, 2020

Accepted: July 30, 2020

Article in press: July 30, 2020

Published online: September 6, 2020

P-Reviewer: Zhang KQ

S-Editor: Zhang L

L-Editor: Filipodia

P-Editor: Xing YX



©The Author(s) 2020. Published by Baishideng Publishing Group Inc. All rights reserved.

Core tip: In non-small cell lung cancer, epidermal growth factor receptor (EGFR) L858R/V834L compound mutation is rare and targeted treatment of this mutation with icotinib has not been reported. In this report, the patient failed to achieve complete or partial response but achieved stable disease. The patient has been in remission for 1 year with no evidence of metastatic nodal disease, and there are signs of continuous remission. So far, the effect of this compound mutation on the efficacy of EGFR tyrosine kinase inhibitors is not clear. It is also unclear which EGFR tyrosine kinase inhibitor is most effective for this variation. This case suggests icotinib may be a possible clinical treatment.

Citation: Zhai SS, Yu H, Gu TT, Li YX, Lei Y, Zhang HY, Zhen TH, Gao YG. Lung adenocarcinoma harboring rare epidermal growth factor receptor L858R and V834L mutations treated with icotinib: A case report. *World J Clin Cases* 2020; 8(17): 3841-3846

URL: <https://www.wjgnet.com/2307-8960/full/v8/i17/3841.htm>

DOI: <https://dx.doi.org/10.12998/wjcc.v8.i17.3841>

INTRODUCTION

Non-small cell lung cancer (NSCLC) is one of the leading causes of cancer mortality. Epidermal growth factor receptor (*EGFR*) gene mutations in lung adenocarcinoma account for about 48% of patients. *EGFR* gene exon 19 single nucleotide polymorphism and deletion variation is a common type of mutation^[1]. However, non-*EGFR* Del19/L858R rare mutations account for 23% of cases, mainly composed of exon 20ins, G719X, *de novo* T790M and L861Q combined with the classic mutation of the compound mutation. For the rare compound mutations of *EGFR*, there have been some drug studies. For example, first-generation *EGFR* tyrosine kinase inhibitors (TKIs) are effective for G719X, 21L861Q and the compound mutations carrying sensitive mutations, but more data are needed for efficacy against 20S768I^[2,3]. The second-generation *EGFR*-TKIs have a wider spectrum. They are effective for G719X, S768I, L861Q and complex mutations, and studies have shown a significant increase in progression-free survival compared to first generation *EGFR*-TKIs^[4]. The third-generation *EGFR*-TKIs have shown some therapeutic effect in small phase II studies, but this needs to be verified^[5].

The molecularly targeted drug for lung cancer, icotinib hydrochloride (Kemena), is a small anticancer drug with completely independent intellectual property rights in China. The drug was approved by the China Food and Drug Administration on June 7, 2011 for the first-line treatment of patients with locally advanced or metastatic NSCLC with sensitive mutations in the *EGFR* gene. According to the phase III clinical trial and BRAIN studies, compared with the control group, progression-free survival and objective response rates were significantly prolonged in patients with *EGFR* mutation treated with icotinib, adverse reactions were significantly reduced and the safety was acceptable^[6,7]. Here, we report a case of NSCLC with rare *EGFR* L858R/V834L compound mutation who was treated with icotinib. The treatment was effective, and there was no sign of resistance to icotinib.

CASE PRESENTATION

Chief complaints

A 45-year-old woman presented to the outpatient department of our hospital complaining of hoarseness and a cough with sputum.

History of present illness

Since December 2018, the patient had had cough and sputum without obvious inducement, a small amount of white phlegm, no fever, no chest tightness, no shortness of breath and no headache.

History of past illness

Her past medical history was unremarkable.

Personal and family history

No specific personal history of disease was recorded.

Physical examination

Her mental state was good. She had a hoarse voice. Superficial lymph nodes were not affected, heart and lung auscultation were normal, liver and spleen were not enlarged and neither lower limbs had edema.

Laboratory examinations

Routine blood examination, liver and kidney function and electrolyte test indicators were, normal and carcinoembryonic antigen was 17.6 ng/mL (reference value < 5 ng/mL). Blood gases were normal. Laryngoscopy suggested vocal cord paralysis.

Imaging examinations

Lungs were examined by computed tomography (CT) (mediastinal window) on March 12, 2019. A soft tissue mass shadow was found in the left lower hilum of the lung; the boundary of the shadow was not clear, and it measured about 27.5 mm × 26.8 mm; and the three-stage CT value was about 56/68/81 Hu. Multiple swollen lymph nodes were found in the left supraclavicular area and mediastinum, and the largest was about 11.6 mm × 27.2 mm and was located beside the aortic arch. A small amount of liquid density shadow was seen in the left thoracic cavity. CT examination (pulmonary window) revealed a mass shadow in the left lower lung dorsal segment, with coarse margin, pleural traction and dorsal bronchial occlusion. Multiple small nodules < 10 mm were found in both lungs, with clear boundaries; ground-glass nodules, 17.2 mm × 18.2 mm, were found in the right upper lung, some of which were high density. Magnetic resonance imaging of the head was normal, and abdominal CT was normal.

Further diagnostic work-up

To determine potential therapeutic methods, with the patient's consent, tissue samples from lung bronchoscopy and whole blood as a control were subjected to next-generation sequencing using by a 757-gene panel (Yucebio, Shenzhen, China). Compound variation of *EGFR* gene (exon 21 L858R/V834L) was detected in both tissue and circulating tumor deoxyribonucleic acid samples (Figure 1A). Immunohistochemistry showed that EGFR expression in tumor tissue was positive, and programmed death-ligand 1 expression was < 1% (total cholesterol < 1%) (Figures 1B and C).

FINAL DIAGNOSIS

CT examination showed lung space occupying lesions and multiple lymphadenectasis. Bronchoscopy and pathology were performed in the outpatient department. The results were: CT4N3M1, stage IV lung adenocarcinoma (according to American Joint Cancer Committee, 8th edition), with both lungs, mediastinal and left periclavicular lymph nodes metastasis (Figure 2).

TREATMENT

As a result of the tests and her family's wishes, the patient was treated with oral icotinib hydrochloride (125 mg/d, tid) from March 21, 2019.

OUTCOME AND FOLLOW-UP

In the course of treatment, the patient's condition gradually improved, hoarseness lessened, no adverse drug reaction occurred and carcinoembryonic antigen gradually decreased by 5.6 ng/mL. Lung CT examination showed that multiple small pulmonary nodules gradually reduced and disappeared, mediastinal lymph node metastasis decreased and periclavicular lymph node metastasis decreased and

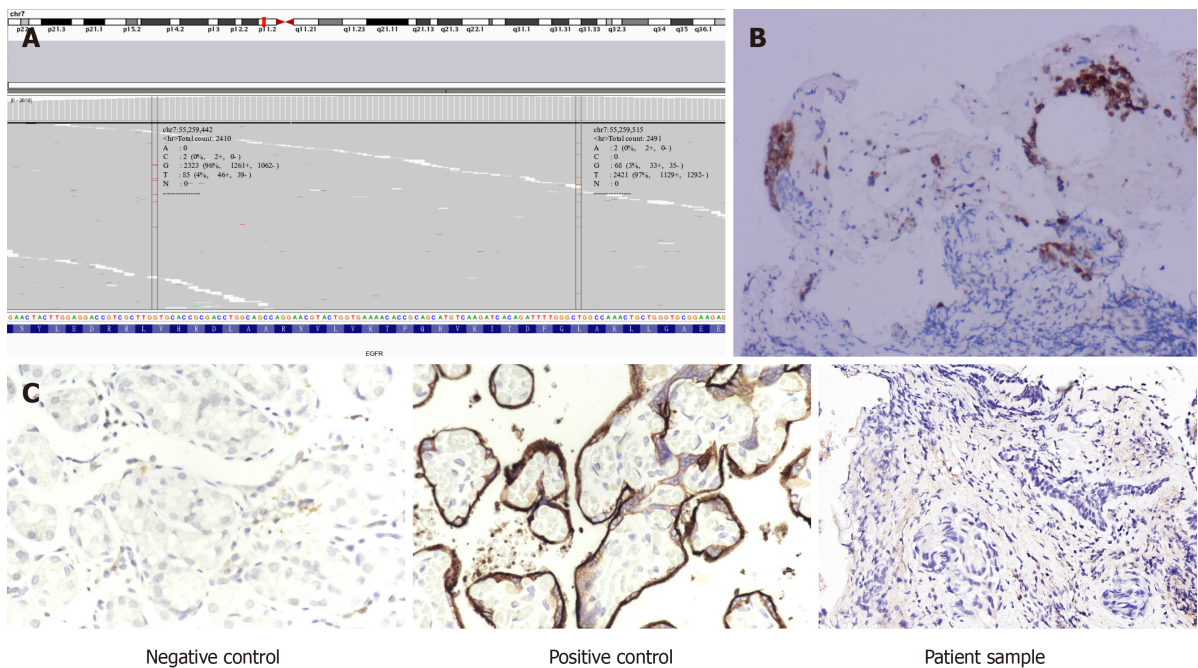


Figure 1 Next generation sequencing result and immunoassay of epidermal growth factor receptor and programmed death-ligand 1. A: Next generation sequencing result of the patient's tissue sample, showing variation in epidermal growth factor receptor exon 21; B: Epidermal growth factor receptor immunoassay; C: Programmed death-ligand 1 immunoassay.

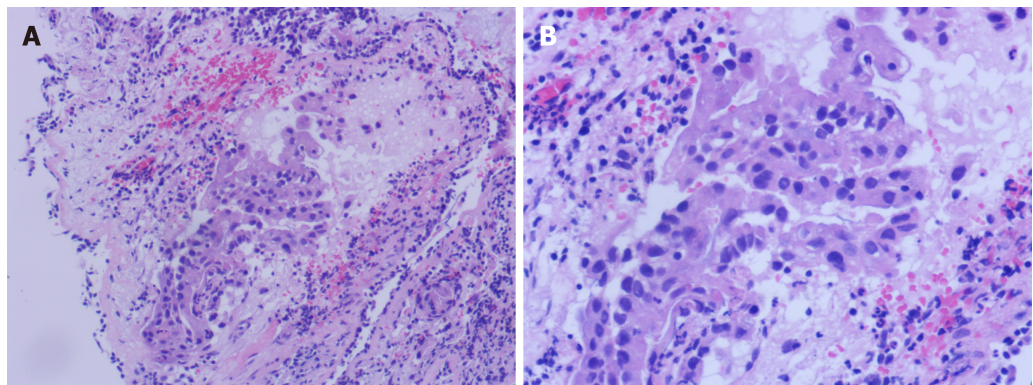


Figure 2 Representative images of hematoxylin and eosin-stained lung adenocarcinoma. A and B: The tumor cells were characterized by the variation in nucleus size and shape, the deep staining and the increased nucleoplasm index, which was marked by a closed curve; Also, hematoxylin and eosin staining showed that the tumor cells invaded the surrounding tissue (A: 100 × and B: 200 ×).

disappeared (Figure 3). No abnormality was found by head magnetic resonance imaging examination. At present, we continue to treat her with icotinib hydrochloride with regular follow-up in the outpatient clinic.

DISCUSSION

The somatic variant of *EGFR* V834L is a rare mutation. Only three cases have previously been found in lung adenocarcinoma, but little is known about its clinical significance. None of the cases reported targeted therapy of *EGFR* L858R/V834L complex mutation. In 2018, a study assessed the efficacy of first-generation of *EGFR*-TKI icotinib in patients with NSCLC carrying rare *EGFR* mutations and found that icotinib had clinical benefit for patients with rare, especially complex mutations^[8]. In two previous reports containing cases of *EGFR* L858R/V834L, gefitinib and erlotinib were used for treatment of patients, and there was no targeted drug treatment for *EGFR* L858R/V834L patients^[9,10]. Coincidentally, the cases with *EGFR* V834L mutation also had *EGFR* L858R mutation. In addition, in 2018, Li *et al*^[11] found that a patient with

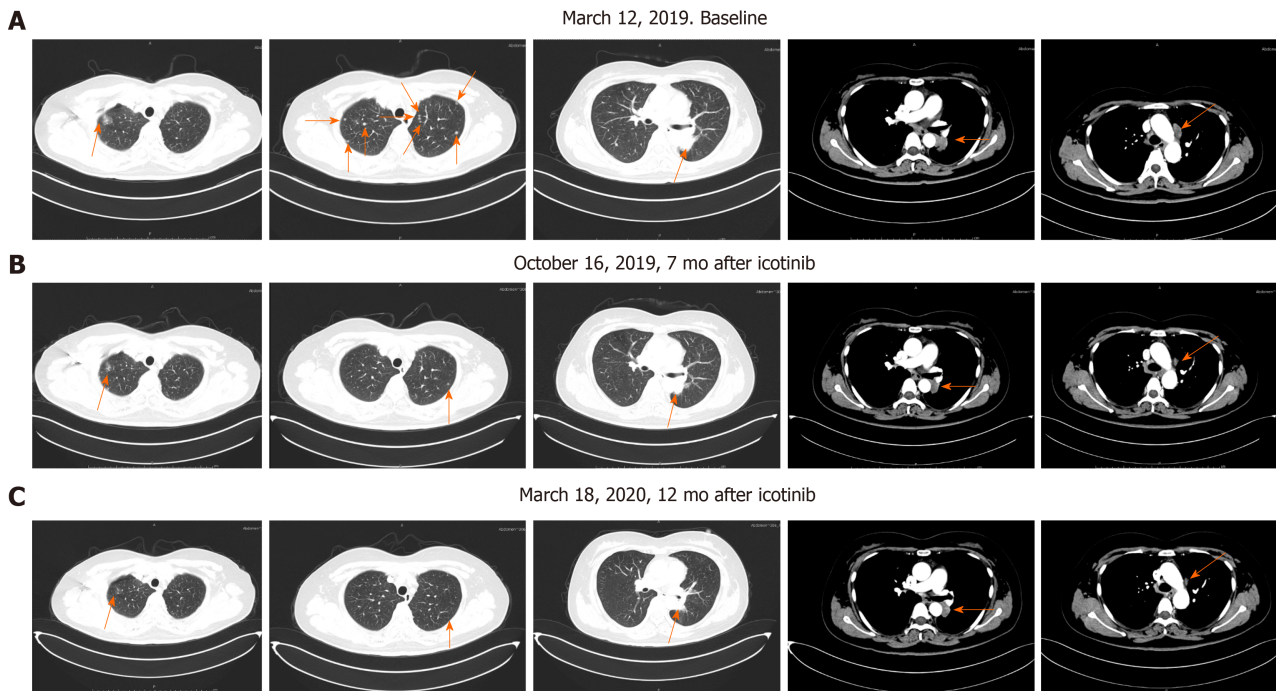


Figure 3 Primary lung cancer and mediastinal metastases before and after icotinib therapy. A: Panel 1: Ground-glass nodules in the right upper lung; Panel 2: Multiple small nodules in both lungs; Panel 3: A mass shadow in the left lower lung dorsal segment; Panel 4: Soft tissue mass shadow in the left lower hilum of lung; Panel 5: Multiple swollen lymph nodes in the mediastinum, with largest located beside the aortic arch; B and C: Multiple small pulmonary nodules gradually reduced and disappeared, mediastinal lymph node metastasis decreased and periclavicular lymph node metastasis decreased and disappeared.

NSCLC who progressed to multiline therapy carried an *EGFR* L858R/V834L complex mutation when the disease progressed slowly from 2012 to 2016. After 2016, the relapse time was shortened, and the driver mutation changed to *EGFR* 19 del. The authors speculated that this complex mutation might be related to a relatively inactive disease state^[11].

In our case, the patient carried a somatic compound mutation of *EGFR* V834L/L858R, and there are no specific reports of drug treatment of such patients at present. After treatment with icotinib, multiple nodular lesions continued to be alleviated, and the clinical efficacy was evaluated by achievement of stable disease, suggesting that icotinib has some therapeutic effect on NSCLC with *EGFR* V834L/L858R compound mutation. The wild-type amino acid in *EGFR* position 834, valine, and mutation-type amino acid leucine are both hydrophobic, and leucine only has an additional C-H group compared to valine, which may have little effect on the protein structure (Figure 4A and B). According to the structure of *EGFR* protein and considering that positions 834 and 858 are close in the spatial structure of the protein (Figure 4), they may have some effect on the drug binding of some *EGFR*-TKIs^[12]. Therefore, it is necessary to carry out targeted drug therapy for NSCLC patients with this rare complex mutation.

CONCLUSION

In this case of NSCLC with *EGFR* V834L/L858R complex mutation, icotinib achieved good clinical efficacy. However, this treatment needs to be validated in a larger population.

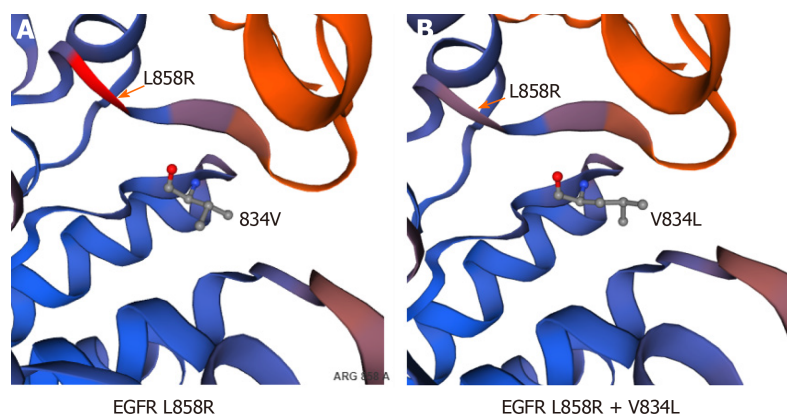


Figure 4 Structural analysis of epidermal growth factor receptor L858R and V834L mutants.

REFERENCES

- Gou LY, Wu YL. Prevalence of driver mutations in non-small-cell lung cancers in the People's Republic of China. *Lung Cancer (Auckl)* 2014; **5**: 1-9 [PMID: [28210137](#) DOI: [10.2147/LCTT.S40817](#)]
- Zhang B, Wang S, Qian J, Yang W, Qian F, Lu J, Zhang Y, Qiao R, Han B. Complex epidermal growth factor receptor mutations and their responses to tyrosine kinase inhibitors in previously untreated advanced lung adenocarcinomas. *Cancer* 2018; **124**: 2399-2406 [PMID: [29543321](#) DOI: [10.1002/cncr.31329](#)]
- Yang JC, Sequist LV, Geater SL, Tsai CM, Mok TS, Schuler M, Yamamoto N, Yu CJ, Ou SH, Zhou C, Massey D, Zazulina V, Wu YL. Clinical activity of afatinib in patients with advanced non-small-cell lung cancer harbouring uncommon EGFR mutations: a combined post-hoc analysis of LUX-Lung 2, LUX-Lung 3, and LUX-Lung 6. *Lancet Oncol* 2015; **16**: 830-838 [PMID: [26051236](#) DOI: [10.1016/S1470-2045\(15\)00026-1](#)]
- Shen YC, Tseng GC, Tu CY, Chen WC, Liao WC, Chen WC, Li CH, Chen HJ, Hsia TC. Comparing the effects of afatinib with gefitinib or Erlotinib in patients with advanced-stage lung adenocarcinoma harboring non-classical epidermal growth factor receptor mutations. *Lung Cancer* 2017; **110**: 56-62 [PMID: [28676220](#) DOI: [10.1016/j.lungcan.2017.06.007](#)]
- Nick T, Michael T, Pan ZY, Jerome G, Michael S, Rebeca M and Vladimir H. Clinical comparison of ABP 215 and bevacizumab in patients with NSCLC: Pharmacokinetic results and justification for extrapolation across bevacizumab indications. *Journal of Clinical Oncology* 2017; **35**: 9050 [DOI: [10.1200/JCO.2017.35.15_suppl.9050](#)]
- Shi Y, Zhang L, Liu X, Zhou C, Zhang L, Zhang S, Wang D, Li Q, Qin S, Hu C, Zhang Y, Chen J, Cheng Y, Feng J, Zhang H, Song Y, Wu YL, Xu N, Zhou J, Luo R, Bai C, Jin Y, Liu W, Wei Z, Tan F, Wang Y, Ding L, Dai H, Jiao S, Wang J, Liang L, Zhang W, Sun Y. Icotinib versus gefitinib in previously treated advanced non-small-cell lung cancer (ICOGEN): a randomised, double-blind phase 3 non-inferiority trial. *Lancet Oncol* 2013; **14**: 953-961 [PMID: [23948351](#) DOI: [10.1016/S1470-2045\(13\)70355-3](#)]
- Yang JJ, Zhou C, Huang Y, Feng J, Lu S, Song Y, Huang C, Wu G, Zhang L, Cheng Y, Hu C, Chen G, Zhang L, Liu X, Yan HH, Tan FL, Zhong W, Wu YL. Icotinib versus whole-brain irradiation in patients with EGFR-mutant non-small-cell lung cancer and multiple brain metastases (BRAIN): a multicentre, phase 3, open-label, parallel, randomised controlled trial. *Lancet Respir Med* 2017; **5**: 707-716 [PMID: [28734822](#) DOI: [10.1016/S2213-2600\(17\)30262-X](#)]
- Zhou SY, Hu XS, Wang Y, Li JL, Zhou LQ, Hao XZ, Liu YT and Shi YK. Effectiveness of icotinib against non-small-cell lung cancer with uncommon EGFR mutation. *Journal of Clinical Oncology* 2018; e21083-e21083 [DOI: [10.1200/JCO.2018.36.15_suppl.e21083](#)]
- Wu SG, Chang YL, Hsu YC, Wu JY, Yang CH, Yu CJ, Tsai MF, Shih JY, Yang PC. Good response to gefitinib in lung adenocarcinoma of complex epidermal growth factor receptor (EGFR) mutations with the classical mutation pattern. *Oncologist* 2008; **13**: 1276-1284 [PMID: [19060236](#) DOI: [10.1634/theoncologist.2008-0093](#)]
- Lgnatius SH, Ali SM, Bogart J, Stephen L, Graziano, Michael DM, Jeffrey SR, Vincent AM and Alexa BS. Characterization of 1,233 NSCLCs with non-del19/L858R EGFR mutations (EGFRm) using comprehensive genomic profiling (CGP). *Journal of Clinical Oncology* 2018; **36**: 9040 [DOI: [10.1200/JCO.2018.36.15_suppl.9040](#)]
- Li J, Zhang L, Wu Y, Yang W, Yang Z, Zhang H. Clinical Outcome and Molecular Analysis of a Chinese Patient With Lung Adenocarcinoma Harboring Rare EGFR Mutation V834L. *J Thorac Oncol* 2018; **13**: e189-e191 [PMID: [29705137](#) DOI: [10.1016/j.jtho.2018.04.021](#)]
- Yasuda H, Park E, Yun CH, Sng NJ, Lucena-Araujo AR, Yeo WL, Huberman MS, Cohen DW, Nakayama S, Ishioka K, Yamaguchi N, Hanna M, Oxnard GR, Lathan CS, Moran T, Sequist LV, Chaff JE, Riely GJ, Arcila ME, Soo RA, Meyerson M, Eck MJ, Kobayashi SS, Costa DB. Structural, biochemical, and clinical characterization of epidermal growth factor receptor (EGFR) exon 20 insertion mutations in lung cancer. *Sci Transl Med* 2013; **5**: 216ra177 [PMID: [24353160](#) DOI: [10.1126/scitranslmed.3007205](#)]



Published by **Baishideng Publishing Group Inc**
7041 Koll Center Parkway, Suite 160, Pleasanton, CA 94566, USA

Telephone: +1-925-3991568

E-mail: bpgoffice@wjgnet.com

Help Desk: <https://www.f6publishing.com/helpdesk>

<https://www.wjgnet.com>

