

World Journal of *Orthopedics*

World J Orthop 2020 November 18; 11(11): 475-533



MINIREVIEWS

- 475 Radiographic evaluation of vascularity in scaphoid nonunions: A review
Cheema HS, Cheema AN

ORIGINAL ARTICLE**Retrospective Study**

- 483 Does proximal femoral nail antirotation achieve better outcome than previous-generation proximal femoral nail?
Baek SH, Baek S, Won H, Yoon JW, Jung CH, Kim SY

Randomized Controlled Trial

- 492 Patients' perspectives on the conventional synthetic cast *vs* a newly developed open cast for ankle sprains
Min BC, Yoon JS, Chung CY, Park MS, Sung KH, Lee KM

SYSTEMATIC REVIEWS

- 499 Proximal fibular osteotomy: Systematic review on its outcomes
Ashraf M, Purudappa PP, Sakthivelnathan V, Sambandam S, Mounsamy V

CASE REPORT

- 507 Müller-Weiss disease: Four case reports
Volpe A, Monestier L, Malara T, Riva G, La Barbera G, Surace MF
- 516 Treatment of a rotator cuff tear combined with iatrogenic glenoid fracture and shoulder instability: A rare case report
Chiang CH, Tsai TC, Tung KK, Chih WH, Yeh ML, Su WR
- 523 Modified surgical treatment for a patient with neurofibromatosis scoliosis: A case report
Shi Y, Li YH, Guan ZP, Huang YC, Yu BS
- 528 Use of short stems in revision of standard femoral stem: A case report
Evola FR, Evola G, Sessa G

ABOUT COVER

Editorial board member of *World Journal of Orthopedics*, Dr. Georgios A Koumantakis is an Assistant Professor at the University of West Attica (UNIWA) in Athens, Greece. Having received his Bachelor's degree from the Technological Educational Institute of Athens in 1996, Dr. Koumantakis undertook his postgraduate training in the United Kingdom. He received his Master's degree from the Manchester School of Physiotherapy in 1997 and his PhD from the University of Manchester in 2001. He became Clinical Physiotherapist at the 401 General Army Hospital of Athens in 2006, where he stayed until 2020, when he became Assistant Professor at UNIWA. His ongoing research interests involve the application of evidence-based physiotherapy practice in prevention and management of neuromusculoskeletal pathologies, particularly the effects of physiotherapy interventions within a wide age, occupational and physical activity population spectrum. (L-Editor: Filipodia)

AIMS AND SCOPE

The primary aim of *World Journal of Orthopedics* (*WJO*, *World J Orthop*) is to provide scholars and readers from various fields of orthopedics with a platform to publish high-quality basic and clinical research articles and communicate their research findings online.

WJO mainly publishes articles reporting research results and findings obtained in the field of orthopedics and covering a wide range of topics including arthroscopy, bone trauma, bone tumors, hand and foot surgery, joint surgery, orthopedic trauma, osteoarthropathy, osteoporosis, pediatric orthopedics, spinal diseases, spine surgery, and sports medicine.

INDEXING/ABSTRACTING

The *WJO* is now abstracted and indexed in PubMed, PubMed Central, Emerging Sources Citation Index (Web of Science), Scopus, China National Knowledge Infrastructure (CNKI), China Science and Technology Journal Database (CSTJ), and Superstar Journals Database.

RESPONSIBLE EDITORS FOR THIS ISSUE

Production Editor: Yan-Xia Xing; **Production Department Director:** Xiang Li; **Editorial Office Director:** Jia-Ping Yan.

NAME OF JOURNAL

World Journal of Orthopedics

ISSN

ISSN 2218-5836 (online)

LAUNCH DATE

November 18, 2010

FREQUENCY

Monthly

EDITORS-IN-CHIEF

Massimiliano Leigheb

EDITORIAL BOARD MEMBERS

<http://www.wjgnet.com/2218-5836/editorialboard.htm>

PUBLICATION DATE

November 18, 2020

COPYRIGHT

© 2020 Baishideng Publishing Group Inc

INSTRUCTIONS TO AUTHORS

<https://www.wjgnet.com/bpg/gerinfo/240>

GUIDELINES FOR ETHICS DOCUMENTS

<https://www.wjgnet.com/bpg/GerInfo/287>

GUIDELINES FOR NON-NATIVE SPEAKERS OF ENGLISH

<https://www.wjgnet.com/bpg/gerinfo/240>

PUBLICATION ETHICS

<https://www.wjgnet.com/bpg/GerInfo/288>

PUBLICATION MISCONDUCT

<https://www.wjgnet.com/bpg/gerinfo/208>

ARTICLE PROCESSING CHARGE

<https://www.wjgnet.com/bpg/gerinfo/242>

STEPS FOR SUBMITTING MANUSCRIPTS

<https://www.wjgnet.com/bpg/GerInfo/239>

ONLINE SUBMISSION

<https://www.f6publishing.com>



Proximal fibular osteotomy: Systematic review on its outcomes

Munis Ashraf, Prabhudev Prasad Purudappa, Vishaal Sakthivelnathan, Senthilnathan Sambandam, Varatharaj Mounsamy

ORCID number: Munis Ashraf 0000-0002-3657-9478; Prabhudev Prasad Purudappa 0000-0002-7297-474X; Vishaal Sakthivelnathan 0000-0003-0850-9314; Senthilnathan Sambandam 0000-0001-7074-9197; Varatharaj Mounsamy 0000-0002-0032-5775.

Author contributions: Ashraf M contributed to the study by study design, review of literature, manuscript preparation and submission; Sakthivelnathan V performed the review of literature and statistical analysis; Purudappa PP, Sambandam S and Mounsamy V contributed equally in formulation of study design, editing of manuscript and final review of manuscript.

Conflict-of-interest statement: The authors disclose that there is no conflict of interest.

PRISMA 2009 Checklist statement: The authors have read the PRISMA 2009 Checklist, and the manuscript was prepared and revised according to the PRISMA 2009 Checklist.

Open-Access: This article is an open-access article that was selected by an in-house editor and fully peer-reviewed by external reviewers. It is distributed in accordance with the Creative Commons Attribution NonCommercial (CC BY-NC 4.0) license, which permits others to

Munis Ashraf, Department of Orthopedic Surgery, Yenepoya Medical College Hospital, Mangalore 575108, India

Prabhudev Prasad Purudappa, Department of Orthopedic Surgery, Boston VA Medical Center, Boston, MA 02130, United States

Vishaal Sakthivelnathan, School of Medicine, University of Texas Medical Branch, Texas, TX 77030, United States

Senthilnathan Sambandam, Varatharaj Mounsamy, Department of Orthopedic Surgery, Dallas VA Medical center, Dallas, TX 75216, United States

Corresponding author: Munis Ashraf, DNB, Orthopedic Surgeon, Department of Orthopedic Surgery, Yenepoya Medical College Hospital, Derlakatte, Mangalore 575108, India. keyi.orth@gmail.com

Abstract

BACKGROUND

The morbidity and burden of knee osteoarthritis affecting millions of lives worldwide has created a constant pursuit in finding the ideal treatment for knee osteoarthritis. There has been a paradigm shift in the surgical treatment of osteoarthritis ever since the initial description of Volkmann's tibial osteotomy. This review focuses on one such recent procedure, the proximal fibular osteotomy (PFO) for medial compartment knee osteoarthritis. This review encompasses the history, evidence, risk factors, outcomes and technical considerations of PFO.

AIM

To understand the evidence and its techniques, and whether this could be an alternative solution to the problem of knee osteoarthritis in the developing world.

METHODS

The phrases "proximal fibular osteotomy" and "knee osteoarthritis" were searched (date of search December 20, 2019) on PubMed to identify articles evaluating the biomechanical and clinical outcomes of PFO in patients with knee osteoarthritis. A total of 258 were retrieved. After reviewing the summary of the texts, 22 articles written in English were marked for abstract review. Articles that were case studies or cadaver experiments were excluded. The abstracts of the remaining articles were read, and only those that focused on the history, outcomes of case studies and technical considerations of PFO were included in the review. A total of 12 articles were included in this review.

distribute, remix, adapt, build upon this work non-commercially, and license their derivative works on different terms, provided the original work is properly cited and the use is non-commercial. See: <http://creativecommons.org/licenses/by-nc/4.0/>

Manuscript source: Unsolicited manuscript

Specialty type: Orthopedics

Country/Territory of origin: India

Peer-review report's scientific quality classification

Grade A (Excellent): 0

Grade B (Very good): 0

Grade C (Good): C

Grade D (Fair): 0

Grade E (Poor): 0

Received: April 21, 2020

Peer-review started: April 21, 2020

First decision: June 15, 2020

Revised: August 25, 2020

Accepted: September 22, 2020

Article in press: September 22, 2020

Published online: November 18, 2020

P-Reviewer: Halabchi F

S-Editor: Gao CC

L-Editor: Filipodia

P-Editor: Xing YX



RESULTS

At least six studies reported improvement in the visual analogue scale (VAS) from the average preoperative VAS score [6.32, 95% confidence interval (CI) = (4.05, 8.59)] to average postoperative VAS score [1.23, 95% CI: (-1.20, 3.71)], which was statistically significant. Similarly, the American Knee Society Score (KSS) functional score improved from an average preoperative KSS functional score [43.11, 95% CI: (37.83, 48.38)] to postoperative KSS functional score [66.145, 95% CI: (61.94, 70.35)], which was statistically significant. The femorotibial angle improved by around 7°, and the hip knee ankle angle improved by around 6°.

CONCLUSION

With the existing data, it seems that PFO is a viable option for treating medial joint osteoarthritis in selected patients. Long term outcome studies and progression of disease pathology are some of the important parameters that need to be addressed by use of multicenter randomized controlled trials.

Key Words: Proximal fibular osteotomy; High tibial osteotomy; Knee osteoarthritis; Functional outcome; Orthopedic

©The Author(s) 2020. Published by Baishideng Publishing Group Inc. All rights reserved.

Core Tip: The treatment of knee osteoarthritis with total knee arthroplasty is still a luxury and far-fetched for most patients from developing countries. The burden caused by the morbidity of knee osteoarthritis is more in Asian countries than in western countries, hence a treatment modality that could address this specific population subgroup within their financial hold is needed.

Citation: Ashraf M, Purudappa PP, Sakthivelnathan V, Sambandam S, Mounsamy V. Proximal fibular osteotomy: Systematic review on its outcomes. *World J Orthop* 2020; 11(11): 499-506

URL: <https://www.wjnet.com/2218-5836/full/v11/i11/499.htm>

DOI: <https://dx.doi.org/10.5312/wjo.v11.i11.499>

INTRODUCTION

An unassisted bipedal gait is a complex series of movements that results in a progression of the body. This is perhaps one of the most fundamental functions of the human race on which humanity has thrived. This complex series of movements is crippled in persons with osteoarthritis, thereby affecting their livelihood significantly. The prevalence of knee osteoarthritis reported in 1997 by the Framingham study group was at 15.6%^[1]. Since then, this rate has nearly doubled (28.7%) in countries like India^[2]. Treatment options include various nonsurgical and surgical management strategies; total knee arthroplasty (TKA) is the treatment of choice in end stage knee osteoarthritis. It is estimated that by 2030, the demand for TKA is projected to grow at a staggering 673%, reaching 3.4 million surgeries between the years 2005-2030^[3].

The procedure, although highly effective, incurs a significant expenditure to both the hospital and the patient^[4]. In most developed countries, with bundled payments, insurance coverage of costs, meticulous data collection and sample analysis by way of maintaining arthroplasty registries, TKA has been deemed a successful operation for treatment of osteoarthritis. On the contrary, the treatment of knee osteoarthritis with TKA is still a luxury and far-fetched for most patients from developing countries. The burden caused by the morbidity of knee osteoarthritis is more in Asian countries than in western countries, hence a treatment modality that could address this specific population subgroup within their financial hold is needed. Hence, this review on proximal fibular osteotomy (PFO) was undertaken to understand the evidence and its techniques, and whether this could be an alternative solution to the problem of knee osteoarthritis in the developing world.

MATERIALS AND METHODS

Methodology

The phrases “proximal fibular osteotomy” and “knee osteoarthritis” were searched (date of search December 20, 2019) on PubMed to identify articles evaluating the biomechanical and clinical outcomes of PFO in patients with knee osteoarthritis. A total of 258 were retrieved. After reviewing the summary of the texts, 22 articles written in English were marked for abstract review. Articles that were case studies or cadaver experiments were excluded. The abstracts of the remaining articles were read, and only those that focused on the history, outcomes of case studies and technical considerations of PFO were included in the review. A total of 12 articles were included in this review (Figure 1).

Quality assessment

Two investigators independently performed the quality assessment using the Coleman Methodology criteria, which has a maximum score of 100%. The average Coleman Methodology Score was 63.

RESULTS

In this review, there were eight clinical studies and four biomechanical studies on PFO. All of the reported studies were published after 2014. All of the clinical studies were from Asian countries (seven from China and one from Indonesia). The total number of knees analyzed in the clinical studies was 535 (Table 1). The PFO was done in these studies for all grades of symptomatic knee osteoarthritis. In two out of seven studies (including 203 knees), the authors did not document the grade of osteoarthritis in their patients undergoing PFO. Whereas, in the remaining 280 knees, the Kellegren-Lawrence grade of osteoarthritis was grade I (61 knees), grade 2 (97 knees), grade 3 (60 knees), and grade 4 (62 knees). The complications were listed only in three studies, there were twelve superficial peroneal nerve palsy and two common peroneal nerve palsy. However, all of these nerve palsies were transient and were recovered in an average time of 11.6 mo (range: 3 to 15 mo). The functional outcomes were assessed using the American Knee Society Score (KSS), Oxford Knee Score, Japanese Orthopaedic Association Knee Score, and Hospital for Special Surgery Score. The reported outcomes in all eight studies showed significant improvement of postoperative values as compared to preoperative values.

Among the biomechanical studies (Table 2), there were two cadaveric studies and three clinical studies. Unlike the clinical studies in this review, the demographics of the origin of these biomechanical studies did not belong to one particular region. All of the studies uniformly demonstrated medial compartment unloading following PFO.

Pooled sample analysis

Demographics and preoperative variables of the patients studied: A total of eight studies were included for the pooled sample quantitative analysis. The largest study to date by Yang *et al*^[6] included 156 patients on whom the PFO was performed, but only 110 patients were available for follow-up to obtain postoperative data. After excluding patients with incomplete data sets, we had 450 patients available for quantitative analysis. The age of the patients was reported by all eight studies, and the average age of the patients undergoing PFO was 60.76 (range 58.45 to 63.96). Body mass index (BMI) was reported by three studies, and average BMI was 25.30 (range 24.20 to 27.38). Follow-up duration was mentioned by seven studies, and the average duration of follow-up was 21.9 mo (range 6.0 to 49.1 mo).

Outcome measures studied: Pain was assessed using the visual analog scale (VAS) score and was reported preoperatively in seven studies and postoperatively in six studies. There was no uniformity in the type of clinical outcome scores used in various studies. The KSS clinical outcome measure was used by three studies, the KSS functional score was reported by two studies, the Oxford Score was used in one study, the Japanese Knee Score was used in one study, and the Hospital for Special Surgery Score was used for one study. Femorotibial angle was used as a radiological outcome by three studies, and the hip knee ankle angle was used by two studies.

At least six studies reported improvement in VAS from the average preoperative VAS score [6.32, 95% confidence interval (CI): 4.05, 8.59] to average postoperative VAS score (1.23, 95%CI: -1.20, 3.71), which was statistically significant. Similarly, the KSS

Table 1 Compilation of results from the selected clinical studies on proximal fibular osteotomy

No.	Ref.	Country	Year	Cases, n	Grade of osteoarthritis	Outcome score	Follow up period	Complications	Modified Colemans methodological quality assessment score
1	Yang <i>et al</i> ^[6]	China	2015	156	Not mentioned	KSS	49	CPN palsy = 2 nos; SPN palsy = 2 nos; All resolved	76
2	Zou <i>et al</i> ^[7]	China	2017	92	Grade 1, 2-30; grade 3, 4-10	JOA	25	NVI = 1; Fracture = 1; Recurrent deformity = 1	68
3	Wang <i>et al</i> ^[8]	China	2017	47	Not mentioned	KSS	12	Not available	63
4	Lu <i>et al</i> ^[9]	China	2018	31	Ahlback grade 1	HSS	24	SPN palsy = 1	53
5	Liu <i>et al</i> ^[10]	China	2018	111	Grade 2 = 17; Grade = 47; Grade = 47	KSS	12	Not available	68
6	Nie <i>et al</i> ^[11]	China	2018	16	Grade 2 = 3; Grade 3 = 16	HSS	12	Not available	63
7	Qin <i>et al</i> ^[12]	China	2018	67	KL score more than 2 with varus deformity	HSS	36	SPN palsy = 8	71
8	Utomo <i>et al</i> ^[13]	Indonesia	2018	15	All cases were grade 4	OKS	Immediate postoperative period only	Not available	51

KSS: American Knee Society Score; JOA: Japanese Orthopaedic Association Score; HSS: Hospital for Special Surgery Score; OKS: Oxford Knee Score; KL Score: Kellegren-Lawrence Score; CPN: Common peroneal nerve; SPN: Superficial peroneal nerve.

Table 2 Compilation of the biomechanical studies on proximal fibular osteotomy

No.	Ref.	Country	Year	Type of study	Cases, n	Medial compartment unloading	Remarks
1	Yazdi <i>et al</i> ^[14]	Iran	2015	Cadaveric study	6	Yes	Increase in pressure of lateral compartment
2	Huang <i>et al</i> ^[15]	China	2017	Clinical study with gait analysis	1	Yes	Reduction in knee pain due to increasing femoral valgus, femoral external rotation and distal translation of knee
3	Baldini <i>et al</i> ^[16]	United States	2018	Cadaveric study	10	Yes	A decrease in lateral compartment as well as ankle joint pressure was noted
4	Nie <i>et al</i> ^[11]	China	2018	Clinical study with gait analysis and dynamic musculoskeletal analysis	29 patient vs 20 controls	Yes	Decreased knee adduction moment was observed
5	Wang <i>et al</i> ^[17]	China	2019	Retrospective study with radiographic analysis	560 knees	Yes	Reduction in knee adduction moments and rebalance the biceps-proximal fibula-peroneus longus complex

functional score improved from an average preoperative KSS functional score (43.11, 95%CI: 37.83, 48.38) to postoperative KSS functional score (66.145, 95%CI: 61.94, 70.35), which was statistically significant. The femorotibial angle improved by around 7 °, and the hip knee ankle angle improved by around 6 °. Complications were reported by three studies with a mean complication of 8 (range 1 to 8).

Univariate analysis of factors affecting postoperative functional outcome and complication

For this part of the analysis, we stratified postoperative outcome as “good” if there was less than 30% improvement in the preoperative outcome score and “excellent” if there was more than 30% increase in the reported outcome score. Outcomes from six studies were categorized as good, and outcomes from two studies were categorized as

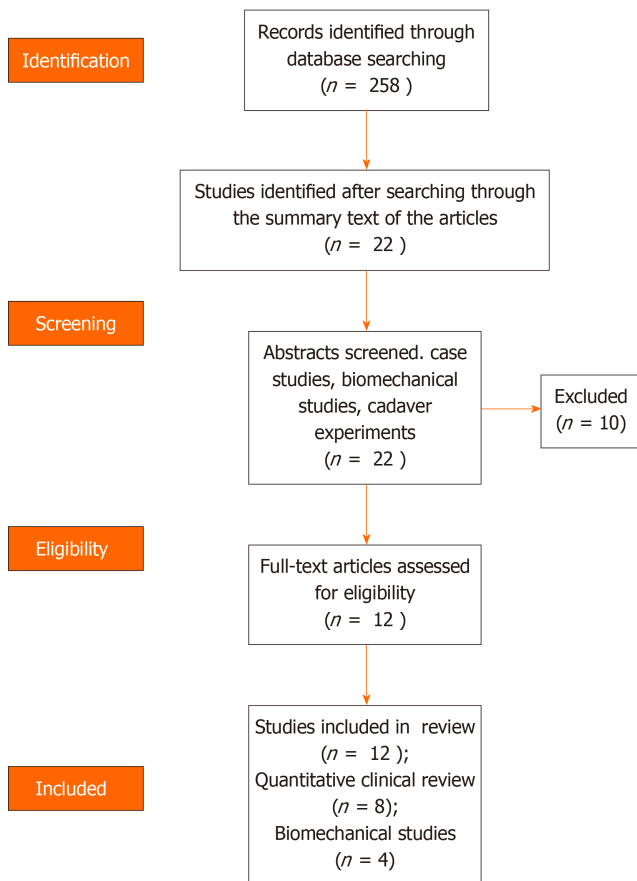


Figure 1 PRISMA flowchart.

excellent. There was no statistical difference between the two groups in any of the preoperative variables including age, BMI, preoperative functional score, or VAS scores. Patients with excellent outcomes tended to have longer follow-up (27.5 mo) compared to patients with good outcomes (19.6 mo). However, this difference was not statistically significant but shows a trend that the outcome continues to get better with continuing follow-up up to two years. We also noted that higher complications occurred in patients with good outcomes (3 complications) compared to patients with excellent outcomes (0 complications). This further signifies the need for good surgical technique thereby avoiding early complications, which could affect the outcome up to two years.

When analyzing studies reporting more complications, none of the preoperative variables were noted to significantly differ between studies with less than 10% or more than 10% complications. However, it is difficult to interpret because complications were only reported by three studies.

DISCUSSION

The technique of osteotomy in knee osteoarthritis was first reported by Volkmann in 1875, wherein he had described a simple high tibial osteotomy (HTO) for surgical management of knee osteoarthritis. According to Wardle *et al*^[18], combined tibial and fibular osteotomy was observed in Royal Southern Hospital, Liverpool in the year 1928. The reason for combining a fibular osteotomy was that it facilitates better union rates following the procedure. Over the years the tibial osteotomy procedure has been the workhorse procedure of choice in younger patients with osteoarthritis. The danger of nerve injuries following a combined tibia and fibula osteotomy was described by Preston *et al*^[19].

Conversion to total knee arthroplasty following PFO was observed in four cases reported by Yang *et al*^[6] after one year follow-up. Lu *et al*^[9] reported no conversion to total knee arthroplasty following PFO in their study. The other authors did not mention conversion to total knee arthroplasty.

It was noted by Lu *et al*^[9] that the disease progression had stopped when PFO was used in conjunction with medial meniscectomy. The authors felt that this could have happened as the medial meniscectomy addressing the theory of meniscal subluxation leading to osteoarthritis^[20].

A statistically significant decrease in operative time, bleeding, and complication rates were observed when PFO was compared with HTO^[7]. Also, in this study it was noted that there were improved clinical outcome scores in comparison with that of the HTO group.

The exact mechanism by which a PFO works is believed to be based on the principle of nonuniform settlement (discussed below). As reported by Wang *et al*^[17], it is stated that the lateral support provided to the osteoporotic tibia by the fibula-soft tissue complex may lead to non-uniform settlement and degeneration of the plateau bilaterally, which may cause the load from the normal distribution to shift farther medially to the medial plateau, consequently leading to knee Varus and aggravating the progression of medial compartment osteoarthritis of the knee joint. A PFO thereby nullifies the effect of lateral support provided by the fibula and leads to unloading of the medial compartment of the knee.

The settlement phenomenon was studied radiographically using objective measurements by Dong *et al*^[21]. Furthermore, they had also described that the proximal fibula had more bone density when compared with the proximal tibia by quantitative computed tomography bone scan.

Following a PFO, biomechanical cadaveric studies demonstrated that the medial compartment was unloaded. Meanwhile, gait analysis studies have shown a reduced knee adduction moment, increasing femoral valgus, femoral external rotation, and distal translation of knee. The factors that have been identified to be associated with outcome of PFO are the following^[10,12] (Table 3): (1) Medial joint space; (2) Condyle plateau angle; (3) Hip knee ankle angle; (4) Settlement value; (5) Preoperative functional score; and (6) Patient BMI. Of which (1)-(4) are radiographic parameters, and (5) and (6) are clinical parameters.

Technical considerations of PFO^[6]

Under epidural anesthesia, the pneumatic tourniquet was used for hemostasis, and the fibular posterolateral approach was performed in the supine position. The subcutaneous tissues were exposed, the intermuscular space between the peroneus longus and brevis and soleus muscle were found, curved forceps were used for layer separation until the proximal fibula, and then the subperiosteal dissection was performed. Two broad osteotomes were used to protect the soft tissues along the fibular medial surface. A 2 cm long fibula 6-10 cm away from the fibular head was cut off using a micro-oscillating saw and then washed thoroughly with 0.9% sodium chloride solution. The broken end was sealed by bone wax to reduce bleeding and pain. Combined with arthroscopic debridement, the synovial soft tissues and cartilage face were cleaned, loose bodies were removed, the meniscus was repaired and shaped, the lateral patellar retinaculum was released, and osteophytes were removed. The negative pressure drainage tube was placed and then removed within 24 h. The pneumatic pump was used to prevent lower limb venous thrombosis, and lower limb functional exercise was guided.

Peroneal nerve palsy is the most reported complication following PFO. Rupp *et al*^[22] described the danger zones while performing fibular osteotomy. The neurovascular structures at primary risk in the proximal third region are the common peroneal nerve, superficial peroneal nerve, deep peroneal nerve, and anterior tibial artery. In the middle third region, primary risk is to peroneal artery and superficial peroneal nerve. This anatomical consideration forms the basis of selecting a 2 cm long fibula roughly 6-10 cm away from fibular head.

CONCLUSION

The certain characteristics of the case studies included in this review that are to be noted are: (1) Almost all of the case studies have an Asian background; and (2) The level of evidence is low. Ever since the initial descriptions and reports of proximal fibular osteotomy for medial joint knee osteoarthritis had surfaced, it has been faced with less enthusiasm as is evident by the number of published studies when compared with the voluminous data that exist in literature regarding total knee arthroplasty. However, with the existing data, it seems that PFO is a viable option for treating medial joint osteoarthritis in selected patients. Long term outcome studies and

Table 3 Predictive factors affecting outcome of proximal fibular osteotomy

Radiological parameters	Clinical parameters
Medial joint space	Preoperative functional score
CP angle	Body mass index
HKA angle	
Settlement value	

CP angle: Condyle plateau angle; HKA angle: Hip knee ankle angle.

progression of disease pathology are some of the important parameters that need to be addressed by use of multicenter randomized controlled trials. Of particular note, the reason why studies on PFO from the developed countries remains sparse is rather intriguing. The rationale and technique of PFO seems to be promising but at a nascent stage according to the available literature.

ARTICLE HIGHLIGHTS

Research background

A systematic review of articles pertaining to proximal fibular osteotomy (PFO).

Research motivation

To better understand the effects of PFO in treating medial compartmental arthritis.

Research objectives

To conduct a systematic review and Coleman's methodological assessment.

Research methods

To evaluate using systematic review using PRISMA guidelines and methodological quality of studies using Coleman's scoring.

Research results

Short term and midterm outcomes have demonstrated clinically and statistically significant reduction in pain and functional outcomes.

Research conclusions

The results obtained are rather encouraging and PFO may be a viable option in selected patients.

Research perspectives

Further long term outcomes and randomized controlled trials are to be conducted to shed light on this treatment strategy.

REFERENCES

- 1 **Felson DT**, Zhang Y, Hannan MT, Naimark A, Weissman B, Aliabadi P, Levy D. Risk factors for incident radiographic knee osteoarthritis in the elderly: the Framingham Study. *Arthritis Rheum* 1997; **40**: 728-733 [PMID: 9125257 DOI: 10.1002/art.1780400420]
- 2 **Pal CP**, Singh P, Chaturvedi S, Pruthi KK, Vij A. Epidemiology of knee osteoarthritis in India and related factors. *Indian J Orthop* 2016; **50**: 518-522 [PMID: 27746495 DOI: 10.4103/0019-5413.189608]
- 3 **Kurtz S**, Ong K, Lau E, Mowat F, Halpern M. Projections of primary and revision hip and knee arthroplasty in the United States from 2005 to 2030. *J Bone Joint Surg Am* 2007; **89**: 780-785 [PMID: 17403800 DOI: 10.2106/JBJS.F.00222]
- 4 **Bumpass DB**, Nunley RM. Assessing the value of a total joint replacement. *Curr Rev Musculoskelet Med* 2012; **5**: 274-282 [PMID: 23054621 DOI: 10.1007/s12178-012-9139-6]
- 5 **Fransen M**, Bridgett L, March L, Hoy D, Penserga E, Brooks P. The epidemiology of osteoarthritis in Asia. *Int J Rheum Dis* 2011; **14**: 113-121 [PMID: 21518309 DOI: 10.1111/j.1756-185X.2011.01608.x]
- 6 **Yang ZY**, Chen W, Li CX, Wang J, Shao DC, Hou ZY, Gao SJ, Wang F, Li JD, Hao JD, Chen BC, Zhang YZ. Medial Compartment Decompression by Fibular Osteotomy to Treat Medial Compartment Knee

- Osteoarthritis: A Pilot Study. *Orthopedics* 2015; **38**: e1110-e1114 [PMID: [26652332](#) DOI: [10.3928/01477447-20151120-08](#)]
- 7 **Zou G**, Lan W, Zeng Y, Xie J, Chen S, Qiu Y. Early clinical effect of proximal fibular osteotomy on knee osteoarthritis. *Biomed Res* 2017; **28**: 9291-9294
- 8 **Wang X**, Wei L, Lv Z, Zhao B, Duan Z, Wu W, Zhang B, Wei X. Proximal fibular osteotomy: a new surgery for pain relief and improvement of joint function in patients with knee osteoarthritis. *J Int Med Res* 2017; **45**: 282-289 [PMID: [28222626](#) DOI: [10.1177/0300060516676630](#)]
- 9 **Lu ZK**, Huang C, Wang F, Miao S, Zeng L, He S, Ye S, Chen W. Combination of proximal fibulectomy with arthroscopic partial meniscectomy for medial compartment osteoarthritis accompanied by medial meniscal tear. *J Clin Diagn Res* 2018; **12**: 1-3 [DOI: [10.7860/JCDR/2018/29684.11019](#)]
- 10 **Liu B**, Chen W, Zhang Q, Yan X, Zhang F, Dong T, Yang G, Zhang Y. Proximal fibular osteotomy to treat medial compartment knee osteoarthritis: Preoperational factors for short-term prognosis. *PLoS One* 2018; **13**: e0197980 [PMID: [29795669](#) DOI: [10.1371/journal.pone.0197980](#)]
- 11 **Nie Y**, Ma J, Huang Z, Xu B, Tang S, Shen B, Kraus VB, Pei F. Upper partial fibulectomy improves knee biomechanics and function and decreases knee pain of osteoarthritis: A pilot and biomechanical study. *J Biomech* 2018; **71**: 22-29 [PMID: [29449003](#) DOI: [10.1016/j.jbiomech.2017.12.004](#)]
- 12 **Qin D**, Chen W, Wang J, Lv H, Ma W, Dong T, Zhang Y. Mechanism and influencing factors of proximal fibular osteotomy for treatment of medial compartment knee osteoarthritis: A prospective study. *J Int Med Res* 2018; **46**: 3114-3123 [PMID: [29848141](#) DOI: [10.1177/0300060518772715](#)]
- 13 **Utomo DN**, Mahyudin F, Wijaya AM, Widhiyanto L. Proximal fibula osteotomy as an alternative to TKA and HTO in late-stage varus type of knee osteoarthritis. *J Orthop* 2018; **15**: 858-861 [PMID: [30147277](#) DOI: [10.1016/j.jor.2018.08.014](#)]
- 14 **Yazdi H**, Mallakzadeh M, Mohtajeb M, Farshidfar SS, Bagheri A, Givchchian B. The effect of partial fibulectomy on contact pressure of the knee: a cadaveric study. *Eur J Orthop Surg Traumatol* 2014; **24**: 1285-1289 [PMID: [24318306](#) DOI: [10.1007/s00590-013-1381-0](#)]
- 15 **Huang W**, Lin Z, Zeng X, Ma L, Chen L, Xia H, Zhang Y. Kinematic Characteristics of an Osteotomy of the Proximal Aspect of the Fibula During Walking: A Case Report. *JBJS Case Connect* 2017; **7**: e43 [PMID: [29252873](#) DOI: [10.2106/JBJS.CC.16.00118](#)]
- 16 **Baldini T**, Roberts J, Hao J, Hunt K, Dayton M, Hogan C. Medial Compartment Decompression by Proximal Fibular Osteotomy: A Biomechanical Cadaver Study. *Orthopedics* 2018; **41**: e496-e501 [PMID: [29708573](#) DOI: [10.3928/01477447-20180424-05](#)]
- 17 **Wang J**, Lv HZ, Chen W, Fan MK, Li M, Zhang YZ. Anatomical Adaptation of Fibula and its Mechanism of Proximal Partial Fibulectomy Associated with Medial Compartment Knee Osteoarthritis. *Orthop Surg* 2019; **11**: 204-211 [PMID: [30955245](#) DOI: [10.1111/os.12437](#)]
- 18 **Wardle EN**. Osteotomy of the tibia and fibula in the treatment of chronic osteoarthritis of the knee. *Postgrad Med J* 1964; **40**: 536-542 [PMID: [14186291](#) DOI: [10.1136/pgmj.40.467.536](#)]
- 19 **Preston CF**, Fulkerson EW, Meislin R, Di Cesare PE. Osteotomy about the knee: applications, techniques, and results. *J Knee Surg* 2005; **18**: 258-272 [PMID: [16262007](#) DOI: [10.1055/s-0030-1248190](#)]
- 20 **Gale DR**, Chaisson CE, Totterman SM, Schwartz RK, Gale ME, Felson D. Meniscal subluxation: association with osteoarthritis and joint space narrowing. *Osteoarthritis Cartilage* 1999; **7**: 526-532 [PMID: [10558850](#) DOI: [10.1053/joca.1999.0256](#)]
- 21 **Dong T**, Chen W, Zhang F, Yin B, Tian Y, Zhang Y. Radiographic measures of settlement phenomenon in patients with medial compartment knee osteoarthritis. *Clin Rheumatol* 2016; **35**: 1573-1578 [PMID: [26712497](#) DOI: [10.1007/s10067-015-3146-0](#)]
- 22 **Rupp RE**, Podeszwa D, Ebraheim NA. Danger zones associated with fibular osteotomy. *J Orthop Trauma* 1994; **8**: 54-58 [PMID: [8169696](#) DOI: [10.1097/00005131-199402000-00012](#)]



Published by **Baishideng Publishing Group Inc**
7041 Koll Center Parkway, Suite 160, Pleasanton, CA 94566, USA

Telephone: +1-925-3991568

E-mail: bpgoffice@wjgnet.com

Help Desk: <https://www.f6publishing.com/helpdesk>

<https://www.wjgnet.com>

