

Name of Journal: *World Journal of Clinical Cases*

Manuscript NO: 56192

Manuscript Type: CASE REPORT

Pulmonary benign metastasizing leiomyoma: A case report

Dai HY *et al.* Pulmonary benign metastasizing leiomyoma

Hai-Yun Dai, Shu-Liang Guo, Jian Shen, Li Yang

Abstract

BACKGROUND

Pulmonary benign metastatic leiomyoma (PBML), which is globally rare, is a type of benign metastatic leiomyoma (BML). Here, we report a case of PBML, finally diagnosed through multidisciplinary team (MDT) discussions, and provide a

Match Overview

1	Crossref 19 words "Abstracts_Poster presentations", European Journal of Nuclear Medicine and Molecular Imaging, 2007	1%
2	Crossref 14 words "Abstracts from the 37th Annual Meeting of the Society of General Internal Medicine", Journal of General Internal Medicine	1%
3	Crossref 14 words Fu, Yili, Hui Li, Bo Tian, and Bin Hu. "Pulmonary benign metastasizing leiomyoma: a case report and review of the literature"	1%
4	Internet 11 words crawled on 07-Jan-2020 www.rronj.com	1%
5	Internet 10 words crawled on 03-Feb-2017 clinicaltrials.gov	1%
6	Internet 10 words crawled on 18-Jun-2020 www.wjgnet.com	1%
7	Internet 9 words crawled on 24-Feb-2020 www.ncbi.nlm.nih.gov	<1%



ALL

IMAGES

VIDEOS

37,400 Results

Any time ▾

[Pulmonary benign metastasizing leiomyoma: a case report ...](#)

<https://www.ncbi.nlm.nih.gov/pmc/articles/PMC4073417>

Jan 09, 2014 · This type of disease is usually called **pulmonary benign metastasizing leiomyoma** (PBML). Since the first case of **metastasizing leiomyoma** was discovered and reported by Steiner in 1939, more than 100 cases of PBML have been reported. Most cases have been discovered by chest X-ray or CT scan during routine examinations.

Cited by: 15

Author: Shi Chen, Rui-Ming Liu, Tian Li

Publish Year: 2014

[Pulmonary benign metastasizing leiomyoma: a case report ...](#)

<https://www.ncbi.nlm.nih.gov/pmc/articles/PMC3545911>

Pulmonary benign metastasizing leiomyoma characterized by the growth of **uterine leiomyoma** in the lung is a very rare disease. We herein report the case of a 46-year-old asymptomatic woman who underwent a total abdominal hysterectomy for her multiple **uterine leiomyomas** 5 years ago, with the presence of multiple shadows in her chest roentgenogram during the regular check-up.

Cited by: 14

Author: Yili Fu, Hui Li, Bo Tian, Bin Hu

Publish Year: 2012

[Images of Pulmonary Benign metastasizing leiomyoma a cas...](#)



Pulmonary benign metastasizing leiomyoma: A case report and I



ALL

IMAGES

VIDEOS

38,500 Results

Any time ▼

Pulmonary benign metastasizing leiomyoma: a case report ...

<https://www.ncbi.nlm.nih.gov/pmc/articles/PMC4073417>

Jan 09, 2014 · This type of disease is usually called **pulmonary benign metastasizing leiomyoma (PBML)**. Since the first **case of metastasizing leiomyoma** was discovered and **reported** by Steiner in 1939, more than 100 **cases** of PBML have been **reported**. Most **cases** have been discovered by chest X-ray or CT scan during routine examinations.

Cited by: 15

Author: Shi Chen, Rui-Ming Liu, Tian Li

Publish Year: 2014

Pulmonary benign metastasizing leiomyoma: a case report ...

<https://www.ncbi.nlm.nih.gov/pmc/articles/PMC3545911>

Pulmonary benign metastasizing leiomyoma is a very rare disease characterized by the growth of **uterine leiomyoma** tissue in the lung. In most **cases**, there is a previous history of total **abdominal hysterectomy** for **uterine leiomyoma**. However, the pathogenesis of this disease has not yet been elucidated.

Cited by: 14

Author: Yili Fu, Hui Li, Bo Tian, Bin Hu

Publish Year: 2012

Benign metastasizing leiomyoma of the lung: A case report ...

<https://www.ncbi.nlm.nih.gov/pmc/articles/PMC4487159>

Pulmonary benign metastasizing leiomyoma (BML) is a rare event characterized by benign soft-tissue tumors that occur when **uterine leiomyomas metastasize** to the lung. The present study **reports** the case



Pulmonary benign metastasizing leiomyoma: A case rep



ALL

IMAGES

VIDEOS

MAPS

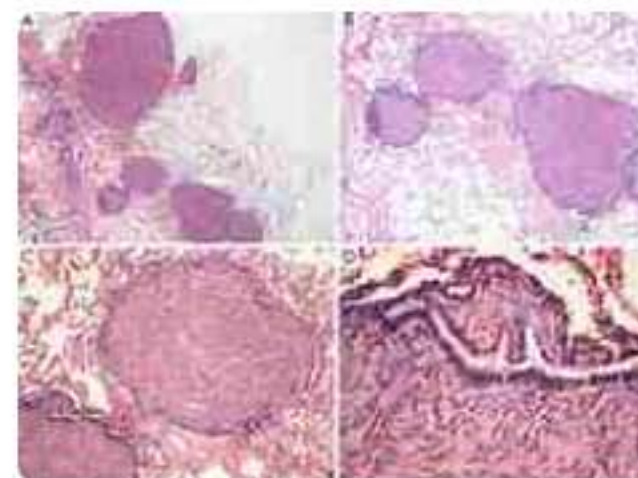
NEWS

SHOPPING

38,900 Results

Any time ▼

Pulmonary benign metastasizing leiomyoma: a case report and literature review Benign metastasizing leiomyoma (BML) is **a rare condition that occurs in all age groups and that is particularly prevalent among women of late childbearing age.**



[Pulmonary benign metastasizing leiomyoma: a case report ...](#)

jtd.amegroups.com/article/view/2476/3188

Was this helpful?



[Pulmonary benign metastasizing leiomyoma: a case report ...](#)

<https://www.ncbi.nlm.nih.gov/pmc/articles/PMC4073417>

Jan 09, 2014 - This type of disease is usually called **pulmonary benign metastasizing leiomyoma (PBML)**. Since the first **case of metastasizing leiomyoma** was discovered and **reported** by Steiner in 1939, more than 100 **cases** of PBML have been **reported**. Most **cases** have been discovered by chest X-ray or CT scan during routine examinations.

Cited by: 15

Author: Shi Chen, Rui-Ming Liu, Tian Li

Publish Year: 2014

[Pulmonary benign metastasizing leiomyoma: a case report ...](#)

<https://www.ncbi.nlm.nih.gov/pmc/articles/PMC3545911>

Pulmonary benign metastasizing leiomyoma is a very rare disease characterized by the growth of **uterine leiomyoma** tissue in the lung. In most **cases**, there is a previous history of total **abdominal hysterectomy** for **uterine leiomyoma**. However, the pathogenesis ...

Cited by: 14

Author: Yili Fu, Hui Li, Bo Tian, Bin Hu

Publish Year: 2012