

World Journal of *Clinical Cases*

World J Clin Cases 2020 October 26; 8(20): 4688-5069



MINIREVIEWS

- 4688 Relationship between non-alcoholic fatty liver disease and coronary heart disease
Arslan U, Yenercağ M

ORIGINAL ARTICLE

Retrospective Cohort Study

- 4700 Remission of hepatotoxicity in chronic pulmonary aspergillosis patients after lowering trough concentration of voriconazole
Teng GJ, Bai XR, Zhang L, Liu HJ, Nie XH

Retrospective Study

- 4708 Endoscopic submucosal dissection as alternative to surgery for complicated gastric heterotopic pancreas
Noh JH, Kim DH, Kim SW, Park YS, Na HK, Ahn JY, Jung KW, Lee JH, Choi KD, Song HJ, Lee GH, Jung HY
- 4719 Observation of the effects of three methods for reducing perineal swelling in children with developmental hip dislocation
Wang L, Wang N, He M, Liu H, Wang XQ
- 4726 Predictive value of serum cystatin C for risk of mortality in severe and critically ill patients with COVID-19
Li Y, Yang S, Peng D, Zhu HM, Li BY, Yang X, Sun XL, Zhang M
- 4735 Sleep quality of patients with postoperative glioma at home
Huang Y, Jiang ZJ, Deng J, Qi YJ
- 4743 Early complications of preoperative external traction fixation in the staged treatment of tibial fractures: A series of 402 cases
Yang JZ, Zhu WB, Li LB, Dong QR
- 4753 Retroperitoneal vs transperitoneal laparoscopic lithotripsy of 20-40 mm renal stones within horseshoe kidneys
Chen X, Wang Y, Gao L, Song J, Wang JY, Wang DD, Ma JX, Zhang ZQ, Bi LK, Xie DD, Yu DX
- 4763 Undifferentiated embryonal sarcoma of the liver: Clinical characteristics and outcomes
Zhang C, Jia CJ, Xu C, Sheng QJ, Dou XG, Ding Y
- 4773 Cerebral infarct secondary to traumatic internal carotid artery dissection
Wang GM, Xue H, Guo ZJ, Yu JL
- 4785 Home-based nursing for improvement of quality of life and depression in patients with postpartum depression
Zhuang CY, Lin SY, Cheng CJ, Chen XJ, Shi HL, Sun H, Zhang HY, Fu MA

Observational Study

- 4793** Cost-effectiveness of lutetium (^{177}Lu) oxodotreotide *vs* everolimus in gastroenteropancreatic neuroendocrine tumors in Norway and Sweden
Palmer J, Leeuwenkamp OR
- 4807** Factors related to improved American Spinal Injury Association grade of acute traumatic spinal cord injury
Tian C, Lv Y, Li S, Wang DD, Bai Y, Zhou F, Ma QB
- 4816** Intraoperative systemic vascular resistance is associated with postoperative nausea and vomiting after laparoscopic hysterectomy
Qu MD, Zhang MY, Wang GM, Wang Z, Wang X

META-ANALYSIS

- 4826** Underwater *vs* conventional endoscopic mucosal resection in treatment of colorectal polyps: A meta-analysis
Ni DQ, Lu YP, Liu XQ, Gao LY, Huang X

CASE REPORT

- 4838** Dehydrated patient without clinically evident cause: A case report
Palladino F, Fedele MC, Casertano M, Liguori L, Esposito T, Guarino S, Miraglia del Giudice E, Marzuillo P
- 4844** Intracranial malignant solitary fibrous tumor metastasized to the chest wall: A case report and review of literature
Usuda D, Yamada S, Izumida T, Sangen R, Higashikawa T, Nakagawa K, Iguchi M, Kasamaki Y
- 4853** End-of-life home care of an interstitial pneumonia patient supported by high-flow nasal cannula therapy: A case report
Goda K, Kenzaka T, Kuriyama K, Hoshijima M, Akita H
- 4858** Rupture of carotid artery pseudoaneurysm in the modern era of definitive chemoradiation for head and neck cancer: Two case reports
Kim M, Hong JH, Park SK, Kim SJ, Lee JH, Byun J, Ko YH
- 4866** Unremitting diarrhoea in a girl diagnosed anti-N-methyl-D-aspartate-receptor encephalitis: A case report
Onpoaree N, Veeravigrom M, Sanpavat A, Suratannon N, Sintusek P
- 4876** Paliperidone palmitate-induced facial angioedema: A case report
Srifuengfung M, Sukakul T, Liangcheep C, Viravan N
- 4883** Improvement of lenvatinib-induced nephrotic syndrome after adaptation to sorafenib in thyroid cancer: A case report
Yang CH, Chen KT, Lin YS, Hsu CY, Ou YC, Tung MC
- 4895** Adult metaplastic hutch diverticulum with robotic-assisted diverticulectomy and reconstruction: A case report
Yang CH, Lin YS, Ou YC, Weng WC, Huang LH, Lu CH, Hsu CY, Tung MC

- 4902** Thrombus straddling a patent foramen ovale and pulmonary embolism: A case report
Huang YX, Chen Y, Cao Y, Qiu YG, Zheng JY, Li TC
- 4908** Therapeutic experience of an 89-year-old high-risk patient with incarcerated cholecystolithiasis: A case report and literature review
Zhang ZM, Zhang C, Liu Z, Liu LM, Zhu MW, Zhao Y, Wan BJ, Deng H, Yang HY, Liao JH, Zhu HY, Wen X, Liu LL, Wang M, Ma XT, Zhang MM, Liu JJ, Liu TT, Huang NN, Yuan PY, Gao YJ, Zhao J, Guo XA, Liao F, Li FY, Wang XT, Yuan RJ, Wu F
- 4917** Woven coronary artery: A case report
Wei W, Zhang Q, Gao LM
- 4922** Idiopathic multicentric Castleman disease with pulmonary and cutaneous lesions treated with tocilizumab: A case report
Han PY, Chi HH, Su YT
- 4930** Perianorectal abscesses and fistula due to ingested jujube pit in infant: Two case reports
Liu YH, Lv ZB, Liu JB, Sheng QF
- 4938** Forniceal deep brain stimulation in severe Alzheimer's disease: A case report
Lin W, Bao WQ, Ge JJ, Yang LK, Ling ZP, Xu X, Jiang JH, Zuo CT, Wang YH
- 4946** Systemic autoimmune abnormalities complicated by cytomegalovirus-induced hemophagocytic lymphohistiocytosis: A case report
Miao SX, Wu ZQ, Xu HG
- 4953** Nasal mucosa pyoderma vegetans associated with ulcerative colitis: A case report
Yu SX, Cheng XK, Li B, Hao JH
- 4958** Amiodarone-induced hepatotoxicity — quantitative measurement of iodine density in the liver using dual-energy computed tomography: Three case reports
Lv HJ, Zhao HW
- 4966** Multisystem involvement Langerhans cell histiocytosis in an adult: A case report
Wang BB, Ye JR, Li YL, Jin Y, Chen ZW, Li JM, Li YP
- 4975** New mutation in EPCAM for congenital tufting enteropathy: A case report
Zhou YQ, Wu GS, Kong YM, Zhang XY, Wang CL
- 4981** Catastrophic vertebral artery and subclavian artery pseudoaneurysms caused by a fishbone: A case report
Huang W, Zhang GQ, Wu JJ, Li B, Han SG, Chao M, Jin K
- 4986** Anastomosing hemangioma arising from the left renal vein: A case report
Zheng LP, Shen WA, Wang CH, Hu CD, Chen XJ, Shen YY, Wang J
- 4993** Bladder perforation caused by long-term catheterization misdiagnosed as digestive tract perforation: A case report
Wu B, Wang J, Chen XJ, Zhou ZC, Zhu MY, Shen YY, Zhong ZX

- 4999** Primary pulmonary plasmacytoma accompanied by overlap syndrome: A case report and review of the literature
Zhou Y, Wang XH, Meng SS, Wang HC, Li YX, Xu R, Lin XH
- 5007** Gastrointestinal stromal tumor metastasis at the site of a totally implantable venous access port insertion: A rare case report
Yin XN, Yin Y, Wang J, Shen CY, Chen X, Zhao Z, Cai ZL, Zhang B
- 5013** Massive gastrointestinal bleeding caused by a Dieulafoy's lesion in a duodenal diverticulum: A case report
He ZW, Zhong L, Xu H, Shi H, Wang YM, Liu XC
- 5019** Plastic bronchitis associated with *Botrytis cinerea* infection in a child: A case report
Liu YR, Ai T
- 5025** Chest, pericardium, abdomen, and thigh penetrating injury by a steel rebar: A case report
Yang XW, Wang WT
- 5030** Monocular posterior scleritis presenting as acute conjunctivitis: A case report
Li YZ, Qin XH, Lu JM, Wang YP
- 5036** Choriocarcinoma with lumbar muscle metastases: A case report
Pang L, Ma XX
- 5042** Primary chondrosarcoma of the liver: A case report
Liu ZY, Jin XM, Yan GH, Jin GY
- 5049** Successful management of a tooth with endodontic-periodontal lesion: A case report
Alshawwa H, Wang JF, Liu M, Sun SF
- 5057** Rare imaging findings of hypersensitivity pneumonitis: A case report
Wang HJ, Chen XJ, Fan LX, Qi QL, Chen QZ
- 5062** Effective administration of cranial drilling therapy in the treatment of fourth degree temporal, facial and upper limb burns at high altitude: A case report
Shen CM, Li Y, Liu Z, Qi YZ

ABOUT COVER

Peer-reviewer of *World Journal of Clinical Cases*, Dr. Aleem Ahmed Khan is a Distinguished Scientist and Head of The Central Laboratory for Stem Cell Research and Translational Medicine, Centre for Liver Research and Diagnostics, Deccan College of Medical Sciences, Kanchanbagh, Hyderabad (India). Dr. Aleem completed his Doctorate from Osmania University, Hyderabad in 1998 and has since performed pioneering work in the treatment of acute liver failure and decompensated cirrhosis using hepatic stem cell transplantation. During his extensive research career he supervised 10 PhD students and published > 150 research articles, 7 book chapters, and 2 patents. His ongoing research involves developing innovative technologies for organ regeneration and management of advanced cancers. (L-Editor: Filipodia)

AIMS AND SCOPE

The primary aim of *World Journal of Clinical Cases* (*WJCC*, *World J Clin Cases*) is to provide scholars and readers from various fields of clinical medicine with a platform to publish high-quality clinical research articles and communicate their research findings online.

WJCC mainly publishes articles reporting research results and findings obtained in the field of clinical medicine and covering a wide range of topics, including case control studies, retrospective cohort studies, retrospective studies, clinical trials studies, observational studies, prospective studies, randomized controlled trials, randomized clinical trials, systematic reviews, meta-analysis, and case reports.

INDEXING/ABSTRACTING

The *WJCC* is now indexed in Science Citation Index Expanded (also known as SciSearch®), Journal Citation Reports/Science Edition, PubMed, and PubMed Central. The 2020 Edition of Journal Citation Reports® cites the 2019 impact factor (IF) for *WJCC* as 1.013; IF without journal self cites: 0.991; Ranking: 120 among 165 journals in medicine, general and internal; and Quartile category: Q3.

RESPONSIBLE EDITORS FOR THIS ISSUE

Production Editor: Ji-Hong Liu; Production Department Director: Xiang Li; Editorial Office Director: Jin-Lai Wang.

NAME OF JOURNAL

World Journal of Clinical Cases

ISSN

ISSN 2307-8960 (online)

LAUNCH DATE

April 16, 2013

FREQUENCY

Semimonthly

EDITORS-IN-CHIEF

Dennis A Bloomfield, Sandro Vento, Bao-Gan Peng

EDITORIAL BOARD MEMBERS

<https://www.wjgnet.com/2307-8960/editorialboard.htm>

PUBLICATION DATE

October 26, 2020

COPYRIGHT

© 2020 Baishideng Publishing Group Inc

INSTRUCTIONS TO AUTHORS

<https://www.wjgnet.com/bpg/gerinfo/204>

GUIDELINES FOR ETHICS DOCUMENTS

<https://www.wjgnet.com/bpg/GerInfo/287>

GUIDELINES FOR NON-NATIVE SPEAKERS OF ENGLISH

<https://www.wjgnet.com/bpg/gerinfo/240>

PUBLICATION ETHICS

<https://www.wjgnet.com/bpg/GerInfo/288>

PUBLICATION MISCONDUCT

<https://www.wjgnet.com/bpg/gerinfo/208>

ARTICLE PROCESSING CHARGE

<https://www.wjgnet.com/bpg/gerinfo/242>

STEPS FOR SUBMITTING MANUSCRIPTS

<https://www.wjgnet.com/bpg/GerInfo/239>

ONLINE SUBMISSION

<https://www.f6publishing.com>



Thrombus straddling a patent foramen ovale and pulmonary embolism: A case report

Yi-Xiong Huang, Yu Chen, Yi Cao, Yi-Gang Qiu, Jian-Yong Zheng, Tian-Chang Li

ORCID number: Yi-Xiong Huang 0000-0003-4936-1934; Yu Chen 0000-0001-7959-2691; Yi Cao 0000-0002-5561-1162; Yi-Gang Qiu 0000-0002-7692-7588; Jian-Yong Zheng 0000-0001-5094-1042; Tian-Chang Li 0000-0003-4503-0089.

Author contributions: Each author has contributed significantly to the submitted work; Huang YX and Cao Y were in charge of this patient; Qiu YG placed inferior vena cava filter for the patient; Huang YX drafted the manuscript; Chen Y and Zheng JY critically revised it for important intellectual content; Li TC, the corresponding author of this manuscript, finally approved the manuscript submitted; All authors have read and approve the final manuscript.

Supported by The Application of Clinical Features of Capital City of Science and Technology Commission China Beijing Special Subject, No. Z151100004015205.

Informed consent statement: Written informed consent was obtained from the patient for publication of this report and accompanying images.

Conflict-of-interest statement: Nothing to disclose.

CARE Checklist (2016) statement: The authors have read the CARE

Yi-Xiong Huang, Yu Chen, Yi Cao, Yi-Gang Qiu, Jian-Yong Zheng, Tian-Chang Li, Department of Cardiology, Sixth Medical Center of PLA General Hospital, Beijing 100048, China

Corresponding author: Tian-Chang Li, MD, PhD, Chief Physician, Department of Cardiology, Sixth Medical Center of PLA General Hospital, No. 6 Fucheng Road, Beijing 100048, China. lrc909@163.com

Abstract

BACKGROUND

Venous thromboembolism is a common vascular syndrome presenting as deep vein thrombosis and/or pulmonary embolism. Thrombus has the possibility of migrating into the left circulation *via* patent foramen ovale in certain extreme circumstances. Thrombus straddling a patent foramen ovale is a direct evidence of this scenario. However, the confirmed cases of thrombus in transit are still rare.

CASE SUMMARY

A 32-year-old man suffered from recurrent syncope and intermittent dyspnea for 1 wk. Transthoracic echocardiography confirmed a thrombus straddling the patent foramen ovale, and thrombi were also found in the bilateral pulmonary artery by computed tomography. The man underwent inferior vena cava filter placement and thrombolysis with alteplase. Echocardiography showed the absence of thrombi in both the right atrium and left atrium 2 d after hospitalization. The man was discharged to home on warfarin without any complications 2 wk later.

CONCLUSION

Scrutinizing intracardiac thrombi provides measurable value in pulmonary embolism as closure of patent foramen ovale may be considered in certain patients. Early intervention plays a critical role in thrombus straddling a patent foramen ovale. A sedentary lifestyle may predispose young adults to thromboembolism, even if there are no other risk factors.

Key Words: Thrombus; Patent foramen ovale; Pulmonary embolism; Case report

©The Author(s) 2020. Published by Baishideng Publishing Group Inc. All rights reserved.

Checklist (2016), and the manuscript was prepared and revised according to the CARE Checklist (2016).

Open-Access: This article is an open-access article that was selected by an in-house editor and fully peer-reviewed by external reviewers. It is distributed in accordance with the Creative Commons Attribution NonCommercial (CC BY-NC 4.0) license, which permits others to distribute, remix, adapt, build upon this work non-commercially, and license their derivative works on different terms, provided the original work is properly cited and the use is non-commercial. See: <http://creativecommons.org/licenses/by-nc/4.0/>

Manuscript source: Unsolicited manuscript

Received: April 22, 2020

Peer-review started: April 22, 2020

First decision: August 8, 2020

Revised: August 20, 2020

Accepted: September 10, 2020

Article in press: September 10, 2020

Published online: October 26, 2020

P-Reviewer: Inoue K, Schoenhagen P

S-Editor: Wang DM

L-Editor: Filipodia

P-Editor: Wang LL



Core Tip: Thrombus straddling a patent foramen ovale is a life-threatening condition that is usually complicated with pulmonary embolism. We present a rare case of deep venous thrombosis, concomitant with pulmonary embolism and transient ischemic attack. Transthoracic echocardiography revealed a large thrombus straddling the patent foramen ovale. There was no significant predisposing factor for thromboembolism except the sedentary lifestyle of the young patient. This case highlights the crucial role of echocardiography in a patient with pulmonary embolism. Identifying intracardiac thrombi may modify the strategies of thromboembolic disease. Moreover, a vigorous lifestyle should be recommended for avoiding thrombotic disaster among young adults.

Citation: Huang YX, Chen Y, Cao Y, Qiu YG, Zheng JY, Li TC. Thrombus straddling a patent foramen ovale and pulmonary embolism: A case report. *World J Clin Cases* 2020; 8(20): 4902-4907

URL: <https://www.wjgnet.com/2307-8960/full/v8/i20/4902.htm>

DOI: <https://dx.doi.org/10.12998/wjcc.v8.i20.4902>

INTRODUCTION

Venous thromboembolism (VTE), clinically presenting as deep vein thrombosis (DVT) or pulmonary embolism (PE) is a common vascular syndrome. Thrombus in transit can cause pulmonary embolism and paradoxical embolism, resulting in severe clinical outcomes. There is a link between paradoxical embolism and cryptogenic stroke^[1], and patent foramen ovale (PFO) plays a crucial role in this scenario. Echocardiography can detect PFO, which is a major cause of cryptogenic stroke. Therefore, screening PFO should be considered among patients diagnosed with pulmonary embolism.

The treatment of the thrombus in transit includes anticoagulation, reperfusion therapy, surgical embolectomy, venous filters and hemodynamic and respiratory support if necessary^[2]. We present a case of a young man who suffered from thrombus straddling a PFO and submassive PE simultaneously. The patient received thrombolysis with alteplase and recovered soon without any complications.

CASE PRESENTATION

Chief complaints

A 32-year-old man presented to the emergency room with repetitive episodes of syncope and intermittent dyspnea within 7 d.

History of present illness

The patient complained of chest distress on February 15, 2019. Then he had a transient, self-limited loss of consciousness lasting for 3-5 min, followed by prompt recovery. The syncope happened four times. The trigger of the attacks included physical exertion or inhaling cold air. There is no prodromal or accompanied symptom. He went to our hospital by himself on February 22, 2019 because of another onset of syncope.

History of past illness

The patient had no medical history nor family history of blood clotting disorders, but he had a sedentary lifestyle due to his job as a news editor.

Physical examination

His vital signs were stable at the time of the first medical contact. Physical examination results were as follows: Pulse rate: 96 beats/min; respiratory rate: 20 breaths/min; blood pressure: 15.5/10.1 kPa; body mass index: 23.1 kg/m²; pupils: Symmetric and responsive to light; prominent P2; symmetrical breath sounds without rales or wheezing; and warm extremities without edema. The neurological examination was negative.

Laboratory examinations

Initial laboratory test showed elevated serum D-dimer at 4150 ng/mL (reference < 500 ng/mL). Arterial blood gas analysis showed PaO₂ of 79 mmHg while he was breathing ambient air. N-terminal pro-B-type natriuretic peptide was 4460 pg/mL (reference < 450 pg/mL). The levels of serum cardiac enzyme series were normal.

Imaging examinations

The electrocardiogram showed sinus tachycardia. Doppler ultrasound revealed a deep venous thrombosis in the right popliteal vein (Figure 1). Transthoracic echocardiography showed a mass thrombus straddling a PFO concomitant dilated right atrium and moderate pulmonary hypertension (Figure 2). The size of the thrombus was 3 mm × 20 mm in the left atrium, 8 mm × 25 mm in the right atrium. Computed tomography angiography confirmed bilateral peripheral PE (Figure 3). The brain computed tomography scan was normal.

FINAL DIAGNOSIS

Thrombus straddling a PFO, PE and DVT.

TREATMENT

Given the risk of detachment of the thrombus from the right popliteal vein, inferior vena cava filter was placed immediately. Then the patient received thrombolysis with intravenous alteplase (100 mg over 2 h) and subcutaneous injection with enoxaparin (60 mg/12 h). Bedside transthoracic echocardiography showed the absence of a clot in the right and left atrium 2 d later. The inner diameter of the right heart chamber was also returned to normal.

Considering that there was no significant predisposing factor for the young patient, the thrombophilic screen was sent off. Antithrombin III, protein S and protein C were normal. Urine albumin was negative. Blood tests also ruled out autoimmune diseases. Dynamic electrocardiogram (Holter) showed no evidence of atrial fibrillation. The patient denied any medical history of trauma, surgery, cancer, drug abuse, long flight or dehydration. Therefore we speculated the sedentary lifestyle may be the major cause of the disease.

The inferior vena cava filter was removed on March 7, 2019. The patient was discharged to home on warfarin the next day.

OUTCOME AND FOLLOW-UP

The patient recovered quickly without any complications. Percutaneous closure of PFO was recommended, but the patient refused further interventional treatment. The patient followed the recommendation of exercise, such as jogging or swimming, five sessions per week lasting on average 30 min/session and involving moderate-to-vigorous intensity physical activity. Moreover, the patient was told not to stay up late at night and maintain a good mentality. He returned to his country 2 mo later. One year follow-up by WeChat showed that there was no recurrent thromboembolic event without anticoagulation therapy.

DISCUSSION

VTE, encompassing DVT and PE, is the third most frequent acute cardiovascular syndrome behind myocardial infarction and stroke^[3]. The incidence rate of VTE ranges from 115 to 269 per 100000 population^[4]. VTE may be lethal in acute phase or lead to chronic disease and disability. The predisposing factor of VTE includes hereditary disease and environmental factors. The patient was healthy before. Body mass index indicated that he was far from obesity. Laboratory examination ruled out autoimmune disease, nephrotic syndrome and hereditary coagulation disease. Furthermore, the patient was too young to be thrombophilic; the mean age of patients with trapped thrombus in a PFO is 59.3 ± 16.4 years^[5]. Nevertheless, the patient used to sit for a long

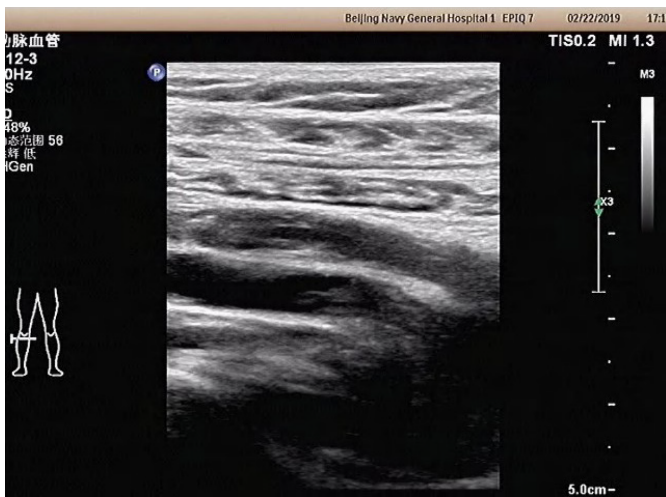

Figure 1 Doppler ultrasound revealed a deep venous thrombosis in the right popliteal vein.

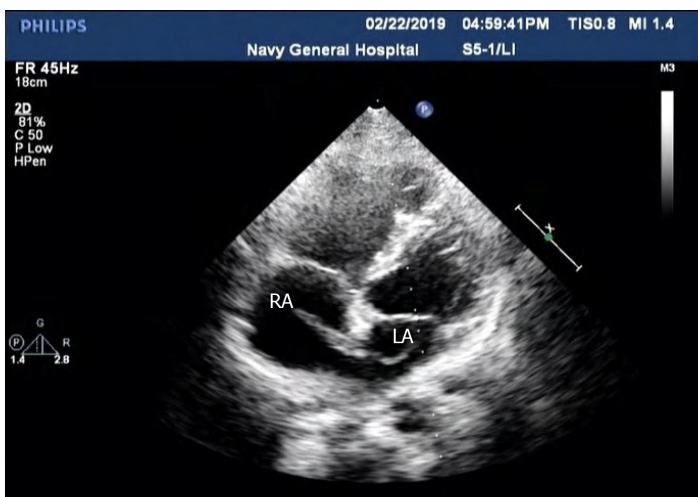


Figure 2 Transthoracic echocardiography showed a mass thrombus straddling a patent foramen ovale (3 mm × 20 mm in the left atrium, 8 mm × 25 mm in the right atrium). RA: Right atrium; LA: Left atrium.

time and burn the midnight oil as a news editor, which is a stressful job as he described. This may have predisposed him to develop spontaneous lower extremity DVT formation and subsequent thrombus straddling a PFO accompanied with acute submassive PE. Besides, there was another possibility that the thrombus originated from the PFO itself due to the special structure that can accelerate the blood flow. Because the DVT was confirmed, the diagnosis of thrombus in transit was our priority.

Thrombus in transit not only affects cerebrovascular but also migrates to other arteries. Wąsek *et al*^[6] reported a case of ST-segment-elevation myocardial infarction related to paradoxical embolization. Santangelo *et al*^[7] presented a patient diagnosed with PE complicated by right renal ischemia and multiple splenic infarcts due to a mobile thrombus entrapped in a PFO. Thus, it is necessary to pay attention to left circulation thromboembolism while unexplained organ damage happens.

PFO is a frequent finding on echocardiography and occurs in about 25% of the population^[8,9]. The presence of a PFO is implicated in the pathogenesis of cryptogenic stroke^[10]; the mechanism of which has been attributed to the paradoxical embolism of venous thrombi that shunt through the PFO while right atrial pressure is high. However, the diagnosis of paradoxical embolism is generally presumptive, mainly relying on the speculation of the physicians. The case we describe above provided direct evidence of thrombus passing through a PFO, which definitely confirmed the paradoxical embolism. Therefore, screening for a PFO with echocardiography seems to be plausible among patients diagnosed with PE. Because the detection rate of two-dimensional echocardiography is low, contrast-transesophageal echocardiography or

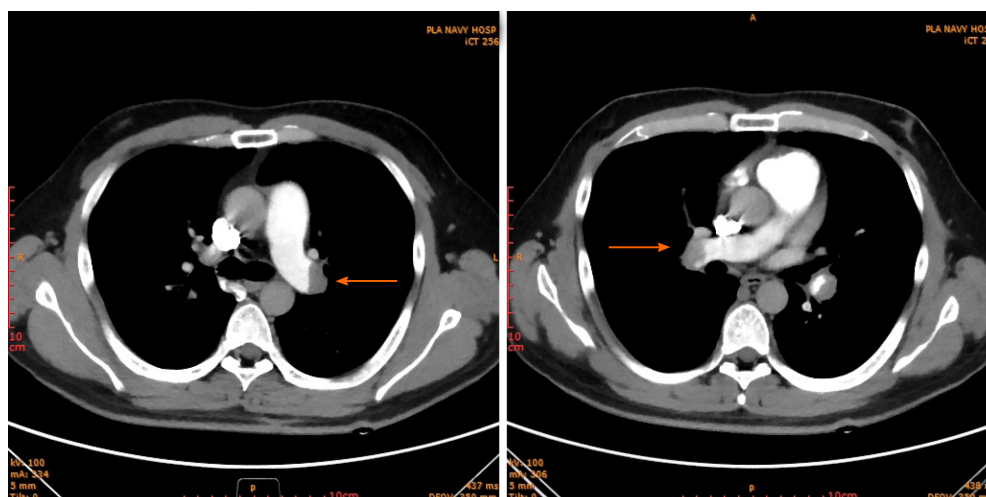


Figure 3 Computed tomography angiography confirmed bilateral pulmonary embolism.

contrast-enhanced transcranial Doppler should be taken into consideration^[11].

Theoretically speaking, patients with PFO and paradoxical embolism would benefit from closure of the PFO. But the evidence of PFO closure used to be controversial. The RESPECT study showed that there was no significant benefit associated with closure of a PFO in adults who had a cryptogenic ischemic stroke^[12]. Nevertheless, long-term follow-up revealed a lower rate of recurrent ischemic strokes in patients who received PFO closure than medical therapy alone^[13]. A meta-analysis also showed patients with PFO and cryptogenic stroke benefited from percutaneous closure in preventing future stroke compared to medical therapy^[14]. Given that the patient was diagnosed with PFO and transient ischemic attack, percutaneous closure PFO was suggested. However, he turned down the suggestion due to the concern about the complications of the surgery. The patient followed the advice of regular exercise. The long-term outcomes will be investigated by our heart team.

The therapeutic strategies of thrombus straddling a PFO include hemodynamic stabilization, respiratory support, filter implantation, anticoagulation, thrombolysis and thrombectomy. Because there is no guideline for the treatment of thrombus in transit, strategies should be personalized according to the patient's symptomology, hemodynamic stability, current clinical evidences, physician's decision and patient's intention. Initial shock or arrest were found in nearly 40% of the cases with trapped thrombus in a PFO^[5]. Extracorporeal membrane oxygenation plays a significant role in rescuing patients with PE complicating hemodynamic instability^[15]. The systematic review showed that thrombectomy was associated with a lower overall incidence of post-treatment embolic events and a lower 60-d mortality in patients with trapped thrombus in a PFO^[5]. Our patient fully and quickly recovered by filter placement and thrombolytics. Thus, conservative treatment with thrombolytics should be emphasized for the younger group, and therefore invasive strategies may be avoided in clinical practice. Although our patient did not accept the PFO closure, we will keep an eye on the long-term outcome of him since the precipitating factor was removed.

CONCLUSION

Thrombus straddling a PFO is a rare but severe clinical circumstance, which is always complicated with PE. Screening PFO with echocardiography should be considered among patients diagnosed with PE. The patient we describe above provides direct evidence of paradoxical embolism. Moreover, a vigorous lifestyle should be recommended for avoiding thrombotic disaster among young adults.

REFERENCES

- 1 Fonseca AC, Ferro JM. Cryptogenic stroke. *Eur J Neurol* 2015; **22**: 618-623 [PMID: 25597418 DOI: 10.1111/ene.12673]
- 2 Konstantinides SV, Meyer G, Becattini C, Bueno H, Geersing GJ, Harjola VP, Huisman MV, Humbert M,

- Jennings CS, Jiménez D, Kucher N, Lang IM, Lankeit M, Lorusso R, Mazzolai L, Meneveau N, Ánle FN, Prandoni P, Pruszczyk P, Righini M, Torbicki A, Van Belle E, Zamorano JL; The Task Force for the diagnosis and management of acute pulmonary embolism of the European Society of Cardiology (ESC). 2019 ESC Guidelines for the diagnosis and management of acute pulmonary embolism developed in collaboration with the European Respiratory Society (ERS): The Task Force for the diagnosis and management of acute pulmonary embolism of the European Society of Cardiology (ESC). *Eur Respir J* 2019; **54** [PMID: 31473594 DOI: 10.1183/13993003.01647-2019]
- 3 **Raskob GE**, Angchaisuksiri P, Blanco AN, Buller H, Gallus A, Hunt BJ, Hylek EM, Kakkar A, Konstantinides SV, McCumber M, Ozaki Y, Wendelboe A, Weitz JI; ISTH Steering Committee for World Thrombosis Day. Thrombosis: a major contributor to global disease burden. *Arterioscler Thromb Vasc Biol* 2014; **34**: 2363-2371 [PMID: 25304324 DOI: 10.1161/ATVBAHA.114.304488]
 - 4 **Wendelboe AM**, Raskob GE. Global Burden of Thrombosis: Epidemiologic Aspects. *Circ Res* 2016; **118**: 1340-1347 [PMID: 27126645 DOI: 10.1161/CIRCRESAHA.115.306841]
 - 5 **Seo WW**, Kim SE, Park MS, Lee JH, Park DG, Han KR, Oh DJ. Systematic Review of Treatment for Trapped Thrombus in Patent Foramen Ovale. *Korean Circ J* 2017; **47**: 776-785 [PMID: 28955396 DOI: 10.4070/kcj.2016.0295]
 - 6 **Wąsek WC**, Samul W, Ryzek R, Skrobowski A. Unique case of ST-segment-elevation myocardial infarction related to paradoxical embolization and simultaneous pulmonary embolization: clinical considerations on indications for patent foramen ovale closure in no-guidelines land. *Circulation* 2015; **131**: 1214-1223 [PMID: 25825398 DOI: 10.1161/CIRCULATIONAHA.114.009846]
 - 7 **Santangelo G**, Ielasi A, Pattarino F, Saino AT, Scopelliti PA, Tespili M. Pulmonary embolism with migrating thrombus through patent foramen ovale: A case for a mixed pharmacological and percutaneous management. *J Cardiol Cases* 2019; **19**: 19-21 [PMID: 30693053 DOI: 10.1016/j.jccase.2018.08.007]
 - 8 **Hoffman JI**, Kaplan S. The incidence of congenital heart disease. *J Am Coll Cardiol* 2002; **39**: 1890-1900 [PMID: 12084585 DOI: 10.1016/s0735-1097(02)01886-7]
 - 9 **Hagen PT**, Scholz DG, Edwards WD. Incidence and size of patent foramen ovale during the first 10 decades of life: an autopsy study of 965 normal hearts. *Mayo Clin Proc* 1984; **59**: 17-20 [PMID: 6694427 DOI: 10.1016/s0025-6196(12)60336-x]
 - 10 **Mojadidi MK**, Zaman MO, Elgendy IY, Mahmoud AN, Patel NK, Agarwal N, Tobis JM, Meier B. Cryptogenic Stroke and Patent Foramen Ovale. *J Am Coll Cardiol* 2018; **71**: 1035-1043 [PMID: 29495983 DOI: 10.1016/j.jacc.2017.12.059]
 - 11 **Mahmoud AN**, Elgendy IY, Agarwal N, Tobis JM, Mojadidi MK. Identification and Quantification of Patent Foramen Ovale-Mediated Shunts: Echocardiography and Transcranial Doppler. *Interv Cardiol Clin* 2017; **6**: 495-504 [PMID: 28886841 DOI: 10.1016/j.iccl.2017.05.002]
 - 12 **Carroll JD**, Saver JL, Thaler DE, Smalling RW, Berry S, MacDonald LA, Marks DS, Tirschwell DL; RESPECT Investigators. Closure of patent foramen ovale vs medical therapy after cryptogenic stroke. *N Engl J Med* 2013; **368**: 1092-1100 [PMID: 23514286 DOI: 10.1056/NEJMoa1301440]
 - 13 **Saver JL**, Carroll JD, Thaler DE, Smalling RW, MacDonald LA, Marks DS, Tirschwell DL; RESPECT Investigators. Long-Term Outcomes of Patent Foramen Ovale Closure or Medical Therapy after Stroke. *N Engl J Med* 2017; **377**: 1022-1032 [PMID: 28902590 DOI: 10.1056/NEJMoa1610057]
 - 14 **Dahal K**, Yousuf A, Watti H, Liang B, Sharma S, Rijal J, Katikaneni P, Modi K, Tandon N, Azrin M, Lee J. Who benefits from percutaneous closure of patent foramen ovale vs medical therapy for stroke prevention? In-depth and updated meta-analysis of randomized trials. *World J Cardiol* 2019; **11**: 126-136 [PMID: 31110604 DOI: 10.4330/wjcv.v11.i4.126]
 - 15 **Ayaon Albarrán A**, Pérez Chulia N, Meca Aguirrezabalaga J, Blázquez González JA. Thrombus straddling a patent foramen ovale and massive pulmonary embolism: Venous arterial extracorporeal membrane oxygenation as a valuable support tool. *J Card Surg* 2019; **34**: 867-870 [PMID: 31233236 DOI: 10.1111/jocs.14123]



Published by **Baishideng Publishing Group Inc**
7041 Koll Center Parkway, Suite 160, Pleasanton, CA 94566, USA

Telephone: +1-925-3991568

E-mail: bpgoffice@wjgnet.com

Help Desk: <https://www.f6publishing.com/helpdesk>

<https://www.wjgnet.com>

