

# World Journal of *Clinical Cases*

*World J Clin Cases* 2020 November 26; 8(22): 5496-5834



## Contents

Semimonthly Volume 8 Number 22 November 26, 2020

## EDITORIAL

- 5496 Is Dynesys dynamic stabilization system superior to posterior lumbar fusion in the treatment of lumbar degenerative diseases?

*Peng BG, Gao CH*

## MINIREVIEWS

- 5501 COVID-19: A review of what radiologists need to know  
*Tang L, Wang Y, Zhang Y, Zhang XY, Zeng XC, Song B*
- 5513 Holistic care model of time-sharing management for severe and critical COVID-19 patients  
*Yang B, Gao Y, Kang K, Li J, Wang L, Wang H, Bi Y, Dai QQ, Zhao MY, Yu KJ*

## ORIGINAL ARTICLE

## Case Control Study

- 5518 Bioequivalence of two esomeprazole magnesium enteric-coated formulations in healthy Chinese subjects  
*Liu ZZ, Ren Q, Zhou YN, Yang HM*
- 5529 Osteoprotegerin, interleukin and hepatocyte growth factor for prediction of diabetes and hypertension in the third trimester of pregnancy  
*Huang SJ, Wang HW, Wu HF, Wei QY, Luo S, Xu L, Guan HQ*

## Retrospective Study

- 5535 High serum lactate dehydrogenase and dyspnea: Positive predictors of adverse outcome in critical COVID-19 patients in Yichang  
*Lv XT, Zhu YP, Cheng AG, Jin YX, Ding HB, Wang CY, Zhang SY, Chen GP, Chen QQ, Liu QC*
- 5547 Risk factors analysis of prognosis of adult acute severe myocarditis  
*Zhang Q, Zhao R*
- 5555 Sonographic features of umbilical vein recanalization for a Rex shunt on cavernous transformation of portal vein in children  
*Zhang YQ, Wang Q, Wu M, Li Y, Wei XL, Zhang FX, Li Y, Shao GR, Xiao J*

## Clinical Trials Study

- 5564 Gemcitabine plus concurrent irreversible electroporation *vs* gemcitabine alone for locally advanced pancreatic cancer  
*Ma YY, Leng Y, Xing YL, Li HM, Chen JB, Niu LZ*

**Observational Study**

- 5576** No significant association between dipeptidyl peptidase-4 inhibitors and adverse outcomes of COVID-19  
*Zhou JH, Wu B, Wang WX, Lei F, Cheng X, Qin JJ, Cai JJ, Zhang X, Zhou F, Liu YM, Li HM, Zhu LH, She Z, Zhang X, Yang J, Li HL*

**META-ANALYSIS**

- 5589** Interobserver agreement for contrast-enhanced ultrasound of liver imaging reporting and data system: A systematic review and meta-analysis  
*Li J, Chen M, Wang ZJ, Li SG, Jiang M, Shi L, Cao CL, Sang T, Cui XW, Dietrich CF*

**CASE REPORT**

- 5603** CLAG-M chemotherapy followed by umbilical cord blood stem cell transplantation for primary refractory acute myeloid leukaemia in a child: A case report  
*Huang J, Yang XY, Rong LC, Xue Y, Zhu J, Fang YJ*
- 5611** Multiple schwannomas with pseudoglandular element synchronously occurring under the tongue: A case report  
*Chen YL, He DQ, Yang HX, Dou Y*
- 5618** Primary myelofibrosis with concurrent *CALR* and *MPL* mutations: A case report  
*Zhou FP, Wang CC, Du HP, Cao SB, Zhang J*
- 5625** Endometrial stromal sarcoma extending to the pulmonary artery: A rare case report  
*Fan JK, Tang GC, Yang H*
- 5632** Malignant acanthosis nigricans with Leser-Trélat sign and tripe palms: A case report  
*Wang N, Yu PJ, Liu ZL, Zhu SM, Zhang CW*
- 5639** Gastric plexiform fibromyxoma: A case report  
*Pei JY, Tan B, Liu P, Cao GH, Wang ZS, Qu LL*
- 5645** Rectoseminal vesicle fistula after radical surgery for rectal cancer: Four case reports and a literature review  
*Xia ZX, Cong JC, Zhang H*
- 5657** Azacitidine decreases reactive oxygen species production in peripheral white blood cells: A case report  
*Hasunuma H, Shimizu N, Yokota H, Tatsuno I*
- 5663** Oral granuloma in a pediatric patient with chronic graft-versus-host disease: A case report  
*Uesugi A, Tsushima F, Kodama M, Kuroshima T, Sakurai J, Harada H*
- 5670** Intrahepatic biliary cystadenoma: A case report  
*Xu RM, Li XR, Liu LH, Zheng WQ, Zhou H, Wang XC*
- 5678** Gene diagnosis of infantile neurofibromatosis type I: A case report  
*Li MZ, Yuan L, Zhuo ZQ*

- 5684** Localized amyloidosis affecting the lacrimal sac managed by endoscopic surgery: A case report  
*Song X, Yang J, Lai Y, Zhou J, Wang J, Sun X, Wang D*
- 5690** Endoscopic resection of benign esophageal schwannoma: Three case reports and review of literature  
*Li B, Wang X, Zou WL, Yu SX, Chen Y, Xu HW*
- 5701** Bouveret syndrome masquerading as a gastric mass-unmasked with endoscopic luminal laser lithotripsy: A case report  
*Parvataneni S, Khara HS, Diehl DL*
- 5707** Nonhypertensive male with multiple paragangliomas of the heart and neck: A case report  
*Wang Q, Huang ZY, Ge JB, Shu XH*
- 5715** Completed atrioventricular block induced by atrial septal defect occluder unfolding: A case report  
*He C, Zhou Y, Tang SS, Luo LH, Feng K*
- 5722** Clinical characteristics of adult-type annular pancreas: A case report  
*Yi D, Ding XB, Dong SS, Shao C, Zhao LJ*
- 5729** Port-site metastasis of unsuspected gallbladder carcinoma with ossification after laparoscopic cholecystectomy: A case report  
*Gao KJ, Yan ZL, Yu Y, Guo LQ, Hang C, Yang JB, Zhang MC*
- 5737** Gonadal dysgenesis in Turner syndrome with Y-chromosome mosaicism: Two case reports  
*Leng XF, Lei K, Li Y, Tian F, Yao Q, Zheng QM, Chen ZH*
- 5744** Gastric mixed adenoma-neuroendocrine tumor: A case report  
*Kohno S, Aoki H, Kato M, Ogawa M, Yoshida K*
- 5751** Sebaceous lymphadenocarcinoma of the parotid gland: A case report  
*Hao FY, Wang YL, Li SM, Xue LF*
- 5758** Misdiagnosis of ligamentoid fibromatosis of the small mesenteric: A case report  
*Xu K, Zhao Q, Liu J, Zhou D, Chen YL, Zhu X, Su M, Huang K, Du W, Zhao H*
- 5765** Intraoperative care of elderly patients with COVID-19 undergoing double lung transplantation: Two case reports  
*Wu Q, Wang Y, Chen HQ, Pan H*
- 5773** Amelioration of cognitive impairment following growth hormone replacement therapy: A case report and review of literature  
*Liu JT, Su PH*
- 5781** Early colon cancer with enteropathy-associated T-cell lymphoma involving the whole gastrointestinal tract: A case report  
*Zhang MY, Min CC, Fu WW, Liu H, Yin XY, Zhang CP, Tian ZB, Li XY*

- 5790** Bleeding of two lumbar arteries caused by one puncture following percutaneous nephrolithotomy: A case report  
*Liu Q, Yang C, Lin K, Yang D*
- 5795** Hemorrhagic fever with renal syndrome complicated with aortic dissection: A case report  
*Qiu FQ, Li CC, Zhou JY*
- 5802** Robot-assisted laparoscopic pyeloureterostomy for ureteropelvic junction rupture sustained in a traffic accident: A case report  
*Kim SH, Kim WB, Kim JH, Lee SW*
- 5809** Large leiomyoma of lower esophagus diagnosed by endoscopic ultrasonography-fine needle aspiration: A case report  
*Rao M, Meng QQ, Gao PJ*
- 5816** Endoscopic reduction of colocolonic intussusception due to metastatic malignant melanoma: A case report  
*Kasuga K, Sakamoto T, Takamaru H, Sekiguchi M, Yamada M, Yamazaki N, Hashimoto T, Uraoka T, Saito Y*
- 5821** Usefulness of ultrasonography to assess the response to steroidal therapy for the rare case of type 2b immunoglobulin G4-related sclerosing cholangitis without pancreatitis: A case report  
*Tanaka Y, Kamimura K, Nakamura R, Ohkoshi-Yamada M, Koseki Y, Mizusawa T, Ikarashi S, Hayashi K, Sato H, Sakamaki A, Yokoyama J, Terai S*

**LETTER TO THE EDITOR**

- 5831** Is positivity for hepatitis C virus antibody predictive of lower risk of death in COVID-19 patients with cirrhosis?  
*Mangia A, Cenderello G, Verucchi G, Ciancio A, Fontana A, Piazzolla V, Minerva N, Squillante MM, Copetti M*

**ABOUT COVER**

Peer-reviewer of *World Journal of Clinical Cases*, Dr. Galiatsatos Aristidis is an Associate Professor, Department of Biomedical Sciences, Division of Dental Technology, University of West Attica. After graduating from the Faculty of Dentistry of University of Thessaloniki in 1988, he completed his PhD in the Dental Prosthodontics Department of Athens University in 1996. From 1988 to 2005, he continued his professional training in the University of Athens as a Research Fellow in Prosthodontics. During the 1998-1999 academic year, he was hired as a paid research scientist in the same subject area. In 2009, he rose to Assistant and then Associate Professor in the University of West Attica. From September 2019, he has served as Director of the Division of Dental Technology. (L-Editor: Filipodia)

**AIMS AND SCOPE**

The primary aim of *World Journal of Clinical Cases* (*WJCC*, *World J Clin Cases*) is to provide scholars and readers from various fields of clinical medicine with a platform to publish high-quality clinical research articles and communicate their research findings online.

*WJCC* mainly publishes articles reporting research results and findings obtained in the field of clinical medicine and covering a wide range of topics, including case control studies, retrospective cohort studies, retrospective studies, clinical trials studies, observational studies, prospective studies, randomized controlled trials, randomized clinical trials, systematic reviews, meta-analysis, and case reports.

**INDEXING/ABSTRACTING**

The *WJCC* is now indexed in Science Citation Index Expanded (also known as SciSearch®), Journal Citation Reports/Science Edition, PubMed, and PubMed Central. The 2020 Edition of Journal Citation Reports® cites the 2019 impact factor (IF) for *WJCC* as 1.013; IF without journal self cites: 0.991; Ranking: 120 among 165 journals in medicine, general and internal; and Quartile category: Q3.

**RESPONSIBLE EDITORS FOR THIS ISSUE**

Production Editor: Ji-Hong Liu; Production Department Director: Xiang Li; Editorial Office Director: Jin-Lai Wang.

**NAME OF JOURNAL**

*World Journal of Clinical Cases*

**ISSN**

ISSN 2307-8960 (online)

**LAUNCH DATE**

April 16, 2013

**FREQUENCY**

Semimonthly

**EDITORS-IN-CHIEF**

Dennis A Bloomfield, Sandro Vento, Bao-Gan Peng

**EDITORIAL BOARD MEMBERS**

<https://www.wjgnet.com/2307-8960/editorialboard.htm>

**PUBLICATION DATE**

November 26, 2020

**COPYRIGHT**

© 2020 Baishideng Publishing Group Inc

**INSTRUCTIONS TO AUTHORS**

<https://www.wjgnet.com/bpg/gerinfo/204>

**GUIDELINES FOR ETHICS DOCUMENTS**

<https://www.wjgnet.com/bpg/GerInfo/287>

**GUIDELINES FOR NON-NATIVE SPEAKERS OF ENGLISH**

<https://www.wjgnet.com/bpg/gerinfo/240>

**PUBLICATION ETHICS**

<https://www.wjgnet.com/bpg/GerInfo/288>

**PUBLICATION MISCONDUCT**

<https://www.wjgnet.com/bpg/gerinfo/208>

**ARTICLE PROCESSING CHARGE**

<https://www.wjgnet.com/bpg/gerinfo/242>

**STEPS FOR SUBMITTING MANUSCRIPTS**

<https://www.wjgnet.com/bpg/GerInfo/239>

**ONLINE SUBMISSION**

<https://www.f6publishing.com>





## Endometrial stromal sarcoma extending to the pulmonary artery: A rare case report

Jian-Kun Fan, Guang-Cai Tang, Han Yang

**ORCID number:** Jian-Kun Fan 0000-0002-7653-6624; Guang-Cai Tang 0000-0003-2799-4677; Han Yang 0000-0001-8994-7804.

**Author contributions:** Fan JK collected the images, analyzed and interpreted the imaging findings, reviewed the literature and wrote the manuscript; Yang H collected clinical data and reviewed the literature; Tang GC designed the research, reviewed and revised the manuscript; all authors have read and approved the final manuscript.

### Informed consent statement:

Informed written consent was obtained from the patient.

**Conflict-of-interest statement:** The authors declare that they have no conflict of interest.

### CARE Checklist (2016) statement:

The manuscript was prepared and revised according to the CARE Checklist (2016).

**Open-Access:** This article is an open-access article that was selected by an in-house editor and fully peer-reviewed by external reviewers. It is distributed in accordance with the Creative Commons Attribution NonCommercial (CC BY-NC 4.0) license, which permits others to distribute, remix, adapt, build upon this work non-commercially,

**Jian-Kun Fan, Guang-Cai Tang, Han Yang,** Department of Radiology, The Affiliated Hospital of Southwest Medical University, Luzhou 646000, Sichuan Province, China

**Corresponding author:** Guang-Cai Tang, MD, Chief Doctor, Director, Full Professor, Department of Radiology, The Affiliated Hospital of Southwest Medical University, No. 23 Taiping Street, Luzhou 646000, Sichuan Province, China. [168345315@qq.com](mailto:168345315@qq.com)

## Abstract

### BACKGROUND

Endometrial stromal sarcoma (ESS) is a rare malignant mesenchymal tumor. Early in the disease, the findings on magnetic resonance imaging are similar to those of leiomyoma. When the lesion involves both vascular and cardiac tissue, it might be misdiagnosed as intravenous leiomyomatosis, which is not common in the clinic.

### CASE SUMMARY

We present the case of a 34-year-old female patient with tumor embolus, which extended from the right iliac vein and ovarian vein to the inferior vena cava (IVC), and then to the right atrium and right ventricle, and finally protruded into the pulmonary artery. The patient had undergone a hysteromyomectomy 7 years previously. Based on the findings of the imaging examinations, the diagnosis of intravenous leiomyomatosis was considered preoperatively. The patient then underwent complete resection of the endovascular and intracardiac tumor embolus. The postoperative pathology results confirmed metastatic ESS with endovascular and intracardiac involvement. The patient was discharged from hospital in good condition, and there was no sign of recurrence 5 mo after the operation.

### CONCLUSION

Extending from the iliac vein and ovarian vein to the IVC, this metastatic ESS invaded both vascular and cardiac tissues. For patients with ESS involving vascular and cardiac tissues, pathological examinations are essential for the differential diagnosis, such as intravenous leiomyomatosis. In addition, due to the high recurrence rate of ESS, long-term and close follow-up evaluation is necessary.

**Key Words:** Endometrial stromal sarcoma; Pulmonary artery; Inferior vena cava; Intracardiac extension; Endovascular extension; Case report

and license their derivative works on different terms, provided the original work is properly cited and the use is non-commercial. See: <http://creativecommons.org/licenses/by-nc/4.0/>

**Manuscript source:** Unsolicited manuscript

**Specialty type:** Radiology, nuclear medicine and medical imaging

**Country/Territory of origin:** China

**Peer-review report's scientific quality classification**

Grade A (Excellent): 0  
Grade B (Very good): 0  
Grade C (Good): C  
Grade D (Fair): 0  
Grade E (Poor): 0

**Received:** May 7, 2020

**Peer-review started:** May 7, 2020

**First decision:** September 14, 2020

**Revised:** September 21, 2020

**Accepted:** October 12, 2020

**Article in press:** October 12, 2020

**Published online:** November 26, 2020

**P-Reviewer:** Teragawa H

**S-Editor:** Zhang H

**L-Editor:** Webster JR

**P-Editor:** Liu JH



©The Author(s) 2020. Published by Baishideng Publishing Group Inc. All rights reserved.

**Core Tip:** Endometrial stromal sarcoma (ESS) is a rare mesenchymal malignant tumor which is infrequently complicated by endovascular and intracardiac involvement. We report a case of ESS with diffuse myometrial infiltration, as well as endovascular and intracardiac involvement. From the iliac vein and ovarian vein to the inferior vena cava, the metastatic ESS in our patient invaded vascular and cardiac tissues.

**Citation:** Fan JK, Tang GC, Yang H. Endometrial stromal sarcoma extending to the pulmonary artery: A rare case report. *World J Clin Cases* 2020; 8(22): 5625-5631

**URL:** <https://www.wjgnet.com/2307-8960/full/v8/i22/5625.htm>

**DOI:** <https://dx.doi.org/10.12998/wjcc.v8.i22.5625>

## INTRODUCTION

Endometrial stromal sarcoma (ESS) is a rare malignant mesenchymal tumor, accounting for an estimated 0.2% of all malignant uterine tumors and 10% to 15% of uterine sarcomas, with an annual incidence of 1-2 per million women<sup>[1,2]</sup>. The 2014 World Health Organization (WHO) classification scheme included the latest molecular findings, and divided ESS into low-grade endometrial stromal sarcoma (LGESS), high-grade endometrial stromal sarcoma (HGESS) and undifferentiated uterine sarcoma (UUS)<sup>[2-4]</sup>. LGESS is the second most common malignant mesenchymal tumor of the uterus, and its incidence is lower than that of leiomyosarcoma<sup>[3]</sup>. There are differences in the age of onset of ESS among the subtypes. The highest incidence of LGESS, HGESS and UUS is observed in those aged 40-55 years, 28-67 years (mean 50 years) and 60 years, respectively<sup>[2]</sup>. The clinical manifestations are abnormal uterine bleeding, pelvic mass and pelvic pain, but approximately 25% of LGESS patients have no obvious symptoms<sup>[2-4]</sup>. The ESS tends to spread to the nearby lymph nodes and veins, but rarely involves cardiac tissues<sup>[5]</sup>. We present the case of a 34-year-old female patient with ESS, extending from the right iliac vein and ovarian vein, to the inferior vena cava (IVC) and then to the right atrium and right ventricle, finally protruding into the pulmonary artery. The purpose of this report is to present this rare, but meaningful and educational case, by discussing the relevant clinical and imaging features, and the diagnosis when encountering such cases in future clinical work.

## CASE PRESENTATION

### Chief complaints

A 34-year-old female patient was admitted to the hospital due to vaginal bleeding, fatigue and shortness of breath for 4 d without chest pain, hemoptysis, dyspnea or other symptoms.

### History of present illness

Computed tomography (CT) examination revealed a filling defect in the IVC before admission, which was initially thought to be a thrombus. Anticoagulant therapy was administered immediately. No other conditions were recorded when admitted to our hospital.

### History of past illness

Seven years ago, the patient had undergone a hysteromyomectomy (no medical records/pathological specimens were available). No other significant history of past illnesses was identified.

### Personal and family history

The patient had no previous or family history of similar illnesses.



### Physical examination

Physical examination showed a surgical scar in the lower abdomen. A palpable hard mass was found in the lower abdomen, with poor mobility and mild tenderness. Vital signs were stable with a blood pressure of 135/80 mmHg, a heart rate 90 bpm, respiratory rate of 21 breaths/min and O<sub>2</sub> saturation of 98%. The electrocardiogram showed sinus rhythm and incomplete right bundle branch block.

### Laboratory examinations

The laboratory examinations showed elevated levels of cancer antigen 125 (47.73 U/mL), FDP (20.31 µg/mL) and D-Di (6.06 µg/mL), while the results of other laboratory examinations were in the normal range.

### Imaging examinations

Transvaginal ultrasonography showed that the uterus was 10.0 cm × 8.5 cm × 8.9 cm in size with multiple heterogeneously echogenic lesions. Transthoracic echocardiography revealed a strip-shaped mass extending to the right atrium and right ventricle, and protruding into the pulmonary artery (Figure 1). The diameter of the pulmonary artery was widened, and the pulmonary artery pressure was 66 mmHg. An enlarged uterus and multiple mixed-density masses in the myometrium were found on enhanced CT images (Figure 2A and C). Filling defects were observed in the right iliac vein, ovarian vein, IVC, right atrium, right ventricle, pulmonary trunk and bilateral pulmonary artery branches (Figure 2). Magnetic resonance imaging (MRI) showed extensive myometrial thickening which was heterogeneously hyperintense on T2-weighted images (Figure 3A and B). Diffuse infiltration of the cervix and vaginal vault was noted without rectal or pelvic wall involvement. Increased signal intensity of the lesions was observed on diffusion weighted imaging (DWI) (Figure 3C). Following an intravenous injection of contrast medium, contrast enhancement of the lesions was heterogeneous and less intense than in the myometrium. The vessels around the uterus and cervix increased, and filling defects in the right iliac vein and left ovarian vein were noted (Figure 3D). <sup>18</sup>F-FDG positron emission tomography/computed tomography (PET/CT) demonstrated slightly high <sup>18</sup>F-fluorodeoxyglucose uptake of the tumor in the IVC (Figure 4), and the maximum standard uptake value was approximately 2.8.

---

## FINAL DIAGNOSIS

---

High-grade ESS.

---

## TREATMENT

---

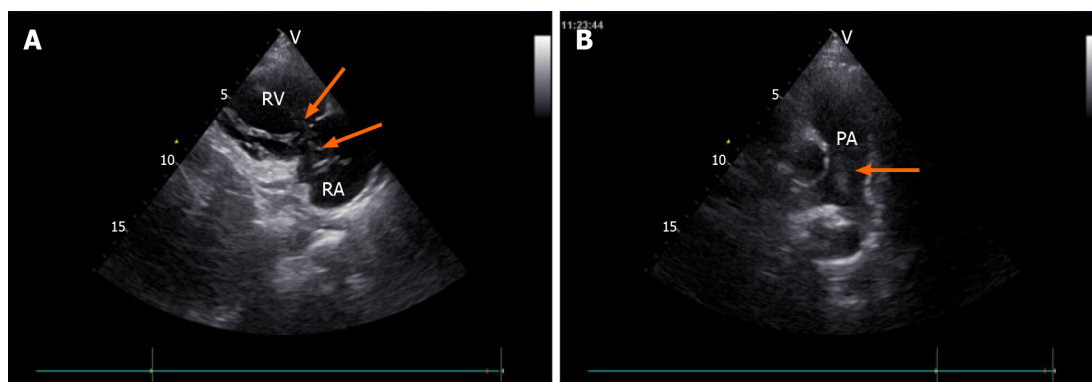
On hospitalization day seven, a combined operation was performed by cardiac surgeons, vascular surgeons and gynecologists (Figure 5A). The endovascular and cardiac tumors were completely removed with no adhesion or infiltration between the tumors and the vessel, and no obvious thrombus on the tumor surface. The gynecologist then performed a subtotal hysterectomy. The size of the uterine tumor was approximately 12 cm × 11 cm × 10 cm, and the tumor infiltrated nearly the whole layer of the myometrium. Cut sections showed multiple grey-white nodules and necrotic cystic areas in the myometrium, and some protruded into the uterine cavity as polypoidal masses (Figure 5B). The right ovary was removed, as a cauliflower-shaped lesion approximately 1.0 cm × 0.5 cm in size was found on the surface of the ovary.

---

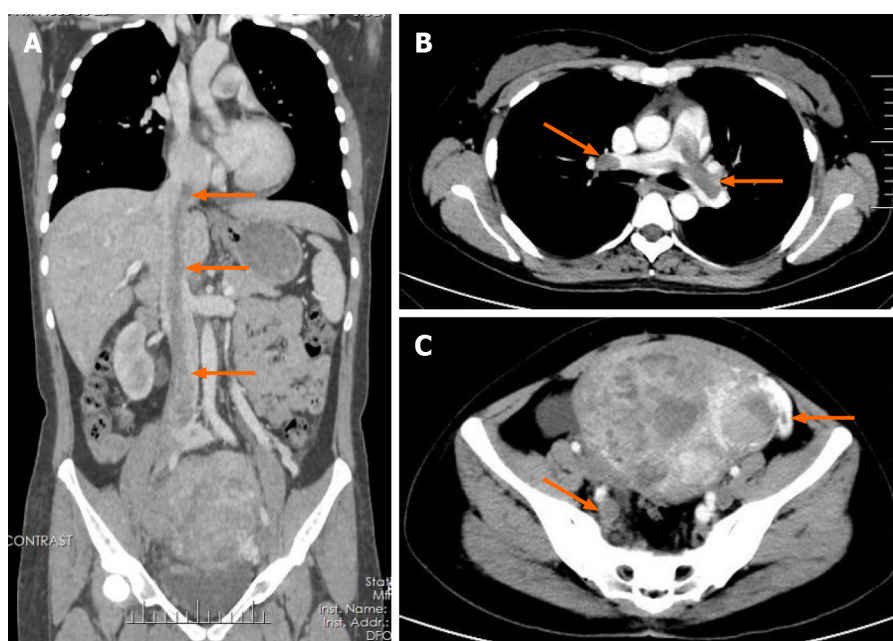
## OUTCOME AND FOLLOW-UP

---

The patient recovered well and was discharged 20 d after the operation. Transthoracic echocardiography after surgery revealed improved pulmonary hypertension (Figure 6C). The patient refused to be referred to the oncology department for further chemoradiotherapy. Five months after the operation, the patient was in good condition. Follow-up enhanced CT showed complete removal of the lesion (Figure 6A and B), and there was no sign of recurrence.



**Figure 1 Transthoracic echocardiography images.** A: Tumor (arrow) in the right atrium and the right ventricle, seen on the parasternal right ventricular inflow tract section; B: Tumor (arrow) in the pulmonary artery, seen on the long axis section of the pulmonary artery. RA: Right atrium; RV: Right ventricle; PA: Pulmonary artery.

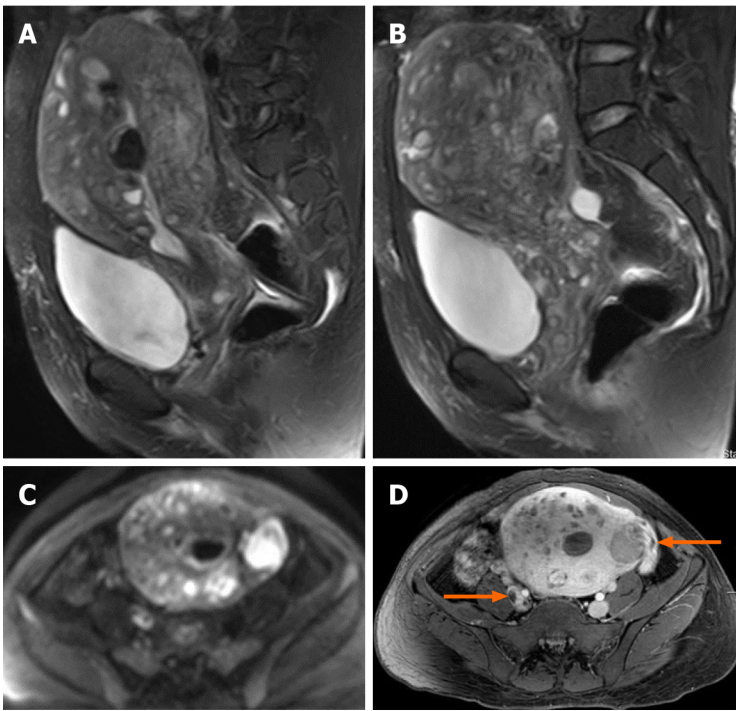


**Figure 2 Enhanced computed tomography images.** A: Coronal enhanced computed tomography (CT) shows a tumor thrombus (arrow) extending from the pelvis to the inferior vena cava and an enlarged uterus; B: Axial enhanced chest CT shows the tumor thrombus (arrow) protruding into the bilateral pulmonary artery branches; C: Axial enhanced pelvic CT shows multiple masses in the uterus and tumor thrombus in the right iliac vein and left ovarian vein (arrow).

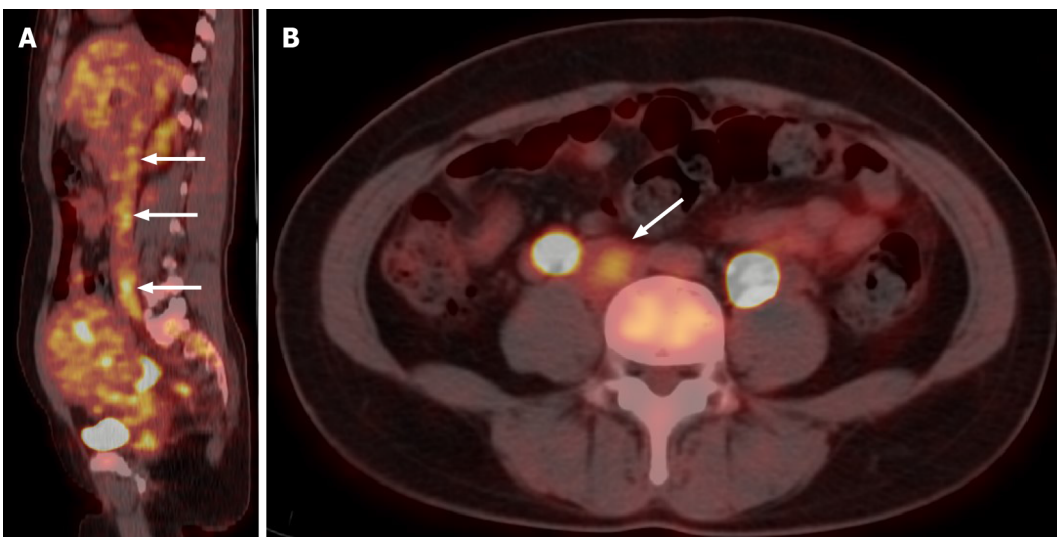
## DISCUSSION

Staging is an important factor in determining the prognosis of ESS patients<sup>[2-4]</sup>. The biological behavior and prognosis of HGEES fall between those of LGEES and UUS<sup>[2]</sup>. According to the size, extent of invasion and distant metastasis of the tumor, the International Federation of Gynecology and Obstetrics (FIGO) staging is as follows: A tumor limited to the uterus is I [ $< 5$  cm in diameter (I A) and  $\geq 5$  cm (I B)]; a tumor extending beyond the uterus but limited to the pelvic cavity is II [adnexal involvement (II A) and other pelvic cavity invasion (II B)]; a tumor outside the pelvic cavity is III; a tumor invading the bladder and rectum is IV A, and distant metastases is IV B<sup>[2,4]</sup>. The 5-year overall survival rate of patients with stage I and II LGEES exceeds 90%, but decreases to 50% for stage III and IV<sup>[2,4,6]</sup>. This patient was considered to have stage IVB, which has a poor prognosis. However, there was no distant metastasis to parenchymal organs or lymph nodes, at least according to the medical imaging findings. In this case, we were more concerned about the endovascular mass, due to the possibility of pulmonary embolism leading to sudden heart failure.

For patients with ESS accompanied by endovascular or intracardiac metastasis, preoperative imaging examinations are important. The imaging examinations can evaluate the extent of the tumor thrombus and show the relationship between the



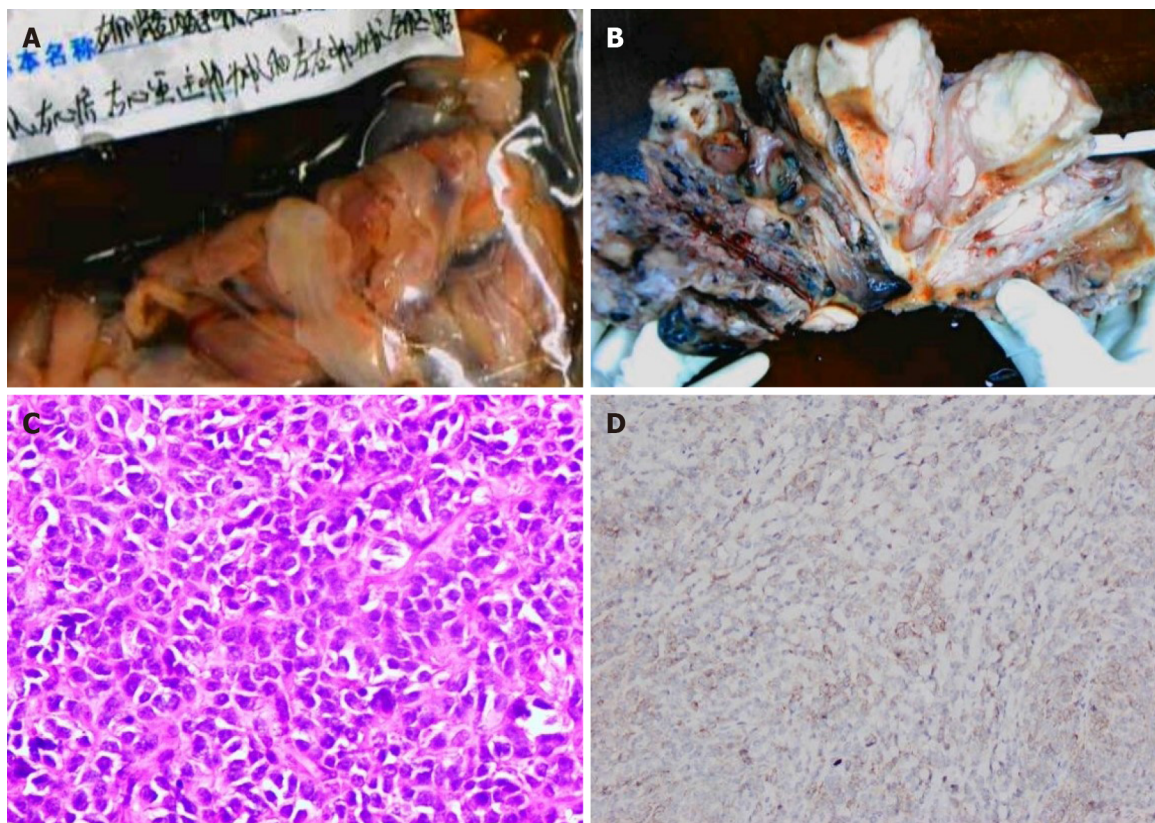
**Figure 3 Pelvic magnetic resonance imaging findings.** A and B: Sagittal T2-weighted images shows extensive myometrial thickening with heterogeneously hyperintense signals, and diffuse infiltration of the cervix and vaginal vault; C: Axial diffusion-weighted image shows high lesion signals; D: Axial T1-weighted image after contrast administration shows that contrast enhancement of the lesions was heterogeneous and tumor thrombus in the right iliac vein and the left ovarian vein (arrow).



**Figure 4  $^{18}\text{F}$ -FDG positron emission tomography/computed tomography images.** Sagittal and axial  $^{18}\text{F}$ -FDG positron emission tomography/computed tomography shows slightly high  $^{18}\text{F}$ -FDG uptake of the tumor in the inferior vena cava (arrow).

tumor thrombus and vessel wall clearly. The MRI findings of ESS commonly show a polypoid endometrial mass, a heterogeneously low signal on T1-weighted images and a hyperintense signal on T2-weighted images, and moderate contrast enhancement<sup>[7]</sup>. Worm-like extension bands caused by lymphatic and vascular invasion appear as hypointense bands on T2-weighted images, which represent preserved normal myometrium<sup>[7,8]</sup>. Distinctively, our patient presented features of a tumor with diffuse myometrial infiltration, and normal myometrium was not clearly demonstrated. Usually, the tumor shows marginal irregularity, which can be attributed to tumor invasion along the vessels and lymphatics<sup>[7]</sup>. However, MRI is neither specific nor sensitive to the diagnosis of these lesions<sup>[4]</sup>. Even histological examinations often miss early-stage ESS, with a failure rate as high as 40%<sup>[9]</sup>.





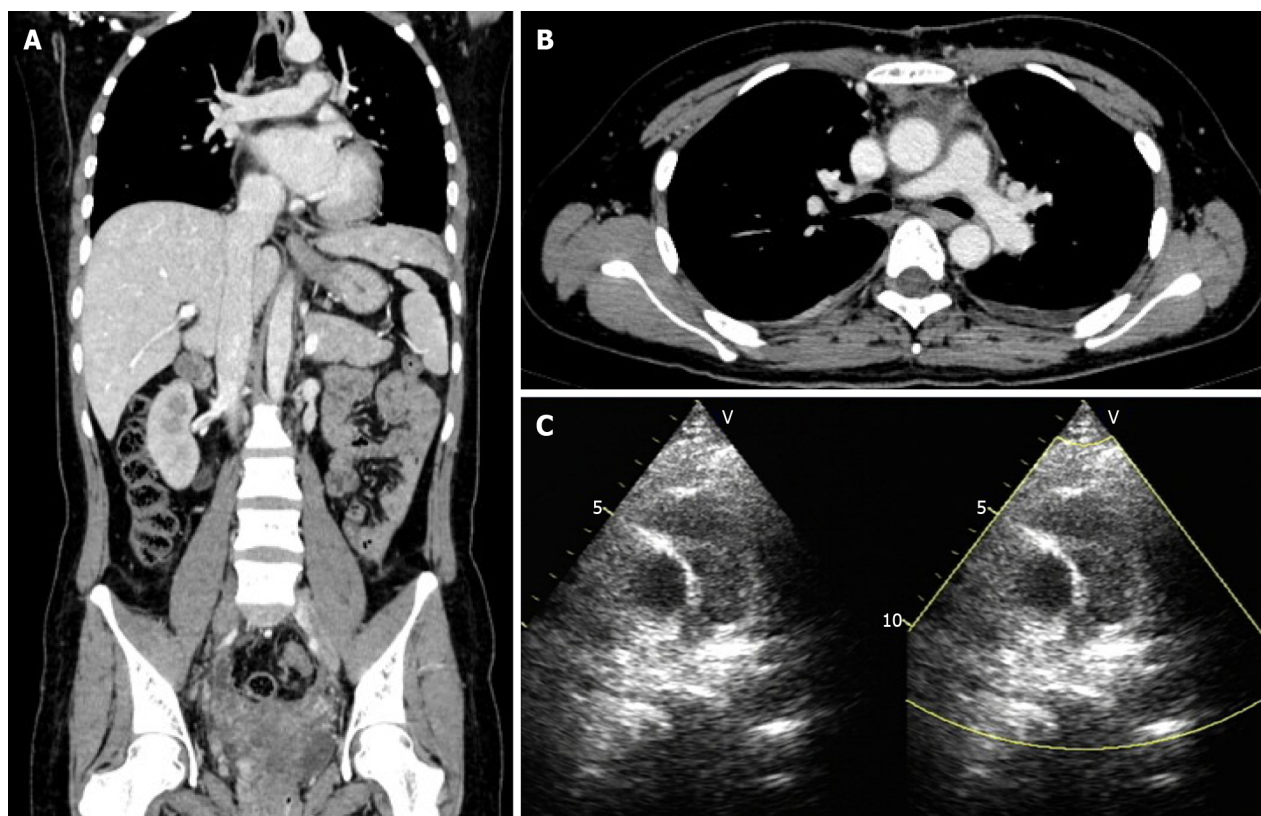
**Figure 5 Pathological images.** A: Endovascular and intracardiac tumors; B: Cut section of the uterine tumor shows that the tumor diffusely infiltrated the whole layer of the uterine wall; C: Microscopically, the tumor cells were closely arranged and cytologically atypical (hematoxylin eosin staining,  $\times 400$ ); D: The tumor shows positive CD10 immunoreactivity.

The appearance of early-stage ESS on MRI, although similar to that of leiomyoma, generally has an infiltrative margin. The results of DWI and apparent diffusion coefficient (ADC) values may have the potential to differentiate ESS from benign leiomyomas<sup>[10]</sup>. ESS shows a high signal on DWI, and the ADC value of ESS is significantly lower than that of benign leiomyoma<sup>[10]</sup>. When accompanied by endovascular or intracardiac involvement, ESS may be misdiagnosed as intravenous leiomyomatosis, which has a similar biological behavior to ESS and can display vascular invasion. The manifestations of these two lesions on CT and MRI are similar. Thus, pathological immunohistochemical examinations are essential for the differential diagnosis.

Compared with LGESS, patients with HGESS have earlier and more frequent recurrences (usually no more than 1 year), and are more likely to die of the disease<sup>[2,4]</sup>. The common sites of tumor recurrence are the local pelvic cavity, distant abdomen and lungs, or both<sup>[2-4]</sup>.

## CONCLUSION

Tumor stage is the most important factor affecting the prognosis of ESS patients. Metastatic ESS extending from the iliac vein and ovarian vein to the IVC and invading vascular and cardiac tissues was seen in this patient. The results of DWI and ADC values are helpful in differentiating early-stage ESS from benign leiomyoma. For patients with endovascular and intracardiac involvement, ESS should be differentiated from intravenous leiomyomatosis, and pathological examinations are essential. Due to the high recurrence rate of ESS, it is necessary to carry out long-term and close follow-up evaluations.



**Figure 6** Postoperative transthoracic echocardiography and follow-up enhanced computed tomography images. A and B: Follow-up enhanced computed tomography showed complete removal of the lesion in the inferior vena cava and pulmonary artery; C: Postoperative transthoracic echocardiography revealed improved pulmonary hypertension.

## REFERENCES

- 1 **Rauh-Hain JA**, del Carmen MG. Endometrial stromal sarcoma: a systematic review. *Obstet Gynecol* 2013; **122**: 676-683 [PMID: [23921879](#) DOI: [10.1097/AOG.0b013e3182a189ac](#)]
- 2 **Mbatani N**, Olawaiye AB, Prat J. Uterine sarcomas. *Int J Gynaecol Obstet* 2018; **143** Suppl 2: 51-58 [PMID: [30306577](#) DOI: [10.1002/tjgo.12613](#)]
- 3 **Ali RH**, Rouzbahman M. Endometrial stromal tumours revisited: an update based on the 2014 WHO classification. *J Clin Pathol* 2015; **68**: 325-332 [PMID: [25595274](#) DOI: [10.1136/jclinpath-2014-202829](#)]
- 4 **Hong HC**, Wen KC, Wang PH, Chen YJ, Yen MS, Ng HT; Taiwan Association of Gynecology Systematic Review Group. Uterine sarcoma Part II-Uterine endometrial stromal sarcoma: The TAG systematic review. *Taiwan J Obstet Gynecol* 2016; **55**: 472-479 [PMID: [27590366](#) DOI: [10.1016/j.tjog.2016.04.034](#)]
- 5 **Gabal S**, Ashour Z, Hamada G, Aziz SA, Khairy H, Badawy H, Hamada EM, Saied K. Low-grade endometrial stromal sarcoma with intravenous extension to the heart. *Medscape J Med* 2009; **11**: 23 [PMID: [19295944](#)]
- 6 **Chan JK**, Kavar NM, Shin JY, Osann K, Chen LM, Powell CB, Kapp DS. Endometrial stromal sarcoma: a population-based analysis. *Br J Cancer* 2008; **99**: 1210-1215 [PMID: [18813312](#) DOI: [10.1038/sj.bjc.6604527](#)]
- 7 **Santos P**, Cunha TM. Uterine sarcomas: clinical presentation and MRI features. *Diagn Interv Radiol* 2015; **21**: 4-9 [PMID: [25347940](#) DOI: [10.5152/dir.2014.14053](#)]
- 8 **Shah SH**, Jagannathan JP, Krajewski K, O'Regan KN, George S, Ramaiya NH. Uterine sarcomas: then and now. *AJR Am J Roentgenol* 2012; **199**: 213-223 [PMID: [22733915](#) DOI: [10.2214/AJR.11.7287](#)]
- 9 **Scher D**, Nghiem W, Aziz S, Rahbar R, Banks W, Venbrux A, Sarin S. Endometrial Stromal Sarcoma Metastatic from the Uterus to the Inferior Vena Cava and Right Atrium. *Tex Heart Inst J* 2015; **42**: 558-560 [PMID: [26664311](#) DOI: [10.14503/THIJ-14-4235](#)]
- 10 **Tamai K**, Koyama T, Saga T, Morisawa N, Fujimoto K, Mikami Y, Togashi K. The utility of diffusion-weighted MR imaging for differentiating uterine sarcomas from benign leiomyomas. *Eur Radiol* 2008; **18**: 723-730 [PMID: [17929022](#) DOI: [10.1007/s00330-007-0787-7](#)]



Published by **Baishideng Publishing Group Inc**  
7041 Koll Center Parkway, Suite 160, Pleasanton, CA 94566, USA

**Telephone:** +1-925-3991568

**E-mail:** [bpgoffice@wjgnet.com](mailto:bpgoffice@wjgnet.com)

**Help Desk:** <https://www.f6publishing.com/helpdesk>

<https://www.wjgnet.com>

