

World Journal of *Gastrointestinal Endoscopy*

World J Gastrointest Endosc 2020 September 16; 12(9): 256-322



EXPERT RECOMMENDATIONS

- 256 Endoscopy during COVID-19 pandemic: An overview of infection control measures and practical application

Teng M, Tang SY, Koh CJ

ORIGINAL ARTICLE

Retrospective Study

- 266 Comparison of the reverse bevel versus Franseen type endoscopic ultrasound needle

Chow CW, Haider SA, Ragnath K, Aithal GP, James MW, Ortiz-Fernandez-Sordo J, Aravinthan AD, Venkatachalapathy SV

- 276 Kyoto classification in patients who developed multiple gastric carcinomas after *Helicobacter pylori* eradication

Sakitani K, Nishizawa T, Toyoshima A, Yoshida S, Matsuno T, Yamada T, Irokawa M, Takahashi Y, Nakai Y, Toyoshima O, Koike K

Observational Study

- 285 Optimization of biliary drainage in inoperable distal malignant strictures

Elshimi E, Morad W, Elshaarawy O, Attia A

CASE REPORT

- 297 Endoscopic approach to gastric remnant outlet obstruction after gastric bypass: A case report

Zarrin A, Sorathia S, Choksi V, Kaplan SR, Kasmin F

- 304 Small invasive colon cancer with adenoma observed by endocytoscopy: A case report

Akimoto Y, Kudo SE, Ichimasa K, Kouyama Y, Misawa M, Hisayuki T, Kudo T, Nemoto T

- 310 Laparoscopy-assisted resection of colorectal cancer with situs inversus totalis: A case report and literature review

Chen W, Liang JL, Ye JW, Luo YX, Huang MJ

LETTER TO THE EDITOR

- 317 Do available data support the widespread adoption of pancreatoscopy guided-lithotripsy?

De Luca L

- 320 Comment on: Should a colonoscopy be offered routinely to patients with CT proven acute diverticulitis? A retrospective cohort study and meta-analysis of best available evidence

Meyer J, Buchs NC, Schiltz B, Liot E, Ris F

ABOUT COVER

Editor-in-Chief of *World Journal of Gastrointestinal Endoscopy*, Dr. Sang Chul Lee is a Professor in the Department of General Surgery of the College of Medicine, Catholic University of Korea and a Colorectal Surgeon at Daejeon St. Mary's Hospital, which is famous for minimally invasive surgery in Korea. His clinical practice specialization in laparoscopic surgery involves a focus in the field of single-port laparoscopic techniques. His standard and routine operation modality is single-port laparoscopic SOLO surgery, with application in a vast spectrum of disease entities and conducted by use of a camera-holder instead of a human assistant. His ongoing research interests are minimally invasive surgery and endoscopic procedures, and for the last several years, he has been performing completely scar-less surgeries. He serves as editorial board member and reviewer for several scientific journals and has published more than 120 peer-reviewed articles. (L-Editor: Filipodia)

AIMS AND SCOPE

The primary aim of *World Journal of Gastrointestinal Endoscopy* (WJGE, *World J Gastrointest Endosc*) is to provide scholars and readers from various fields of gastrointestinal endoscopy with a platform to publish high-quality basic and clinical research articles and communicate their research findings online.

WJGE mainly publishes articles reporting research results and findings obtained in the field of gastrointestinal endoscopy and covering a wide range of topics including capsule endoscopy, colonoscopy, double-balloon enteroscopy, duodenoscopy, endoscopic retrograde cholangiopancreatography, endosonography, esophagoscopy, gastrointestinal endoscopy, gastroscopy, laparoscopy, natural orifice endoscopic surgery, proctoscopy, and sigmoidoscopy.

INDEXING/ABSTRACTING

The WJGE is now abstracted and indexed in Emerging Sources Citation Index (Web of Science), PubMed, PubMed Central, China National Knowledge Infrastructure (CNKI), and Superstar Journals Database.

RESPONSIBLE EDITORS FOR THIS ISSUE

Production Editor: Li-Li Wang; Production Department Director: Yun-Xiaojuan Wu; Editorial Office Director: Jia-Ping Yan.

NAME OF JOURNAL

World Journal of Gastrointestinal Endoscopy

ISSN

ISSN 1948-5190 (online)

LAUNCH DATE

October 15, 2009

FREQUENCY

Monthly

EDITORS-IN-CHIEF

Anastasios Koulaouzidis, Bing Hu, Sang Chul Lee

EDITORIAL BOARD MEMBERS

<https://www.wjgnet.com/1948-5190/editorialboard.htm>

PUBLICATION DATE

September 16, 2020

COPYRIGHT

© 2020 Baishideng Publishing Group Inc

INSTRUCTIONS TO AUTHORS

<https://www.wjgnet.com/bpg/gerinfo/204>

GUIDELINES FOR ETHICS DOCUMENTS

<https://www.wjgnet.com/bpg/GerInfo/287>

GUIDELINES FOR NON-NATIVE SPEAKERS OF ENGLISH

<https://www.wjgnet.com/bpg/gerinfo/240>

PUBLICATION ETHICS

<https://www.wjgnet.com/bpg/GerInfo/288>

PUBLICATION MISCONDUCT

<https://www.wjgnet.com/bpg/gerinfo/208>

ARTICLE PROCESSING CHARGE

<https://www.wjgnet.com/bpg/gerinfo/242>

STEPS FOR SUBMITTING MANUSCRIPTS

<https://www.wjgnet.com/bpg/GerInfo/239>

ONLINE SUBMISSION

<https://www.f6publishing.com>

Endoscopic approach to gastric remnant outlet obstruction after gastric bypass: A case report

Arash Zarrin, Sufian Sorathia, Vivek Choksi, Steven Robert Kaplan, Franklin Kasmin

ORCID number: Arash Zarrin 0000-0002-7151-2009; Sufian Sorathia 0000-0001-6883-1087; Vivek Choksi 0000-0001-9658-3404; Steven Robert Kaplan 0000-0002-5922-2148; Franklin Kasmin 0000-0002-6670-4487.

Author contributions: Zarrin A, Sorathia S and Choksi V reviewed the literature and contributed to manuscript drafting; Zarrin A, Sorathia S and Kasmin F performed the Gastroenterology consultation; Kasmin F performed the endoscopy; Kaplan S and Kasmin F were responsible for the revision of the manuscript for important intellectual content; all authors issued final approval for the version to be submitted.

Informed consent statement:

Informed written consent was obtained from the patient for publication of this report and any accompanying images.

Conflict-of-interest statement: No conflicts of interest declared.

CARE Checklist (2016) statement:

The authors have read the CARE Checklist (2016), and the manuscript was prepared and revised according to the CARE Checklist (2016).

Open-Access: This article is an open-access article that was

Arash Zarrin, Department of Internal Medicine, Aventura Hospital and Medical Center, Miami, FL 33180, United States

Sufian Sorathia, Vivek Choksi, Steven Robert Kaplan, Franklin Kasmin, Department of Gastroenterology, Aventura Hospital and Medical Center, Miami, FL 33180, United States

Corresponding author: Arash Zarrin, DO, Doctor, Department of Internal Medicine, Aventura Hospital and Medical Center, 20900 Biscayne BLVD, Miami, FL 33180, United States. arash.zarrin@hcahealthcare.com

Abstract

BACKGROUND

Acute gastric remnant bleeding is a rare complication of bariatric surgery. Furthermore, acute bleeding from the gastric remnant resulting in gastric remnant outlet obstruction has not been described previously. Endoscopic management of gastric remnant bleed has been challenging due to difficulty accessing the excluded stomach. Traditionally, this necessitates surgical intervention. Recently, however, the adoption of endoscopic ultrasound-directed transgastric intervention provides an alternative approach to management.

CASE SUMMARY

A 65-year-old male with a prior gastric bypass presented with the sudden onset of progressive abdominal distension, nausea, and melena of two days duration. His imaging illustrated a massively distended stomach. A nasogastric tube did not result in drainage of fluid or decompression of his abdomen. His endoscopy revealed a normal-appearing gastro-jejunal anastomosis and confirmed the distended "fluid"-filled gastric remnant. An endoscopic ultrasound-directed gastrogastrostomy was created to decompress the gastric remnant. Two liters of blood was suctioned before a large adherent clot was visualized in the gastric antrum. The patient underwent emergent angiography with embolization of the gastroduodenal artery. He was discharged with a stable hemoglobin level and resolution of symptoms. Healing superficial gastric ulcers were visualized on a follow-up endoscopy. Gastric biopsies were consistent with *Helicobacter pylori* infection for which the patient was treated, and successful eradication was achieved.

CONCLUSION

This patient benefited from a timely diagnosis and effective therapy of an acute gastric remnant obstruction from a bleeding ulcer with endoscopic ultrasound-

selected by an in-house editor and fully peer-reviewed by external reviewers. It is distributed in accordance with the Creative Commons Attribution NonCommercial (CC BY-NC 4.0) license, which permits others to distribute, remix, adapt, build upon this work non-commercially, and license their derivative works on different terms, provided the original work is properly cited and the use is non-commercial. See: <http://creativecommons.org/licenses/by-nc/4.0/>

Manuscript source: Unsolicited manuscript

Received: May 12, 2020

Peer-review started: May 8, 2020

First decision: May 26, 2020

Revised: June 4, 2020

Accepted: August 15, 2020

Article in press: August 15, 2020

Published online: September 16, 2020

P-Reviewer: Goenka MK

S-Editor: Zhang L

L-Editor: A

P-Editor: Li JH



directed transgastric intervention.

Key Words: Gastrointestinal bleeding; Gastric outlet obstruction; Gastric remnant; Endoscopic ultrasound directed transgastric intervention; Gastrogastrostomy; Case report

©The Author(s) 2020. Published by Baishideng Publishing Group Inc. All rights reserved.

Core Tip: The gastric remnant can be safely and effectively accessed by endoscopic ultrasound-directed transgastric intervention by the formation of a gastrogastrostomy using a lumen apposing metal stent to treat several conditions, including but not limited to bleeding gastric ulcers and gastric outlet obstruction among patients who have previously undergone Roux-en-Y gastric bypass. This method is an effective, safe, and less invasive alternative to surgery.

Citation: Zarrin A, Sorathia S, Choksi V, Kaplan SR, Kasmin F. Endoscopic approach to gastric remnant outlet obstruction after gastric bypass: A case report. *World J Gastrointest Endosc* 2020; 12(9): 297-303

URL: <https://www.wjgnet.com/1948-5190/full/v12/i9/297.htm>

DOI: <https://dx.doi.org/10.4253/wjge.v12.i9.297>

INTRODUCTION

Complications following Roux-en-Y gastric bypass (RYGB) can be acute or chronic and can be potentially life-threatening if not immediately recognized and treated. Complications of the pancreatobiliary limb (PBL) and the excluded stomach after RYGB have been reported. However, acute gastric remnant bleeding is an infrequent complication of bariatric surgery. Endoscopic management with either push or balloon enteroscopy is challenging due to technical difficulties in accessing the excluded stomach. In most cases, surgical intervention is necessary and is the standard approach^[1,2].

We present a patient who had a timely diagnosis and successful treatment with endoscopic decompression using a lumen-apposing metal stent (LAMS). This approach is more recently described under the spectrum of endoscopic ultrasound (EUS) directed transgastric intervention (EDGI). EDGI defines any EUS-directed procedure requiring transgastric intervention to adjacent luminal structures, including the gastric remnant among RYGB patients^[3]. Several studies have shown EDGI to be more effective than balloon enteroscopy, and equally as effective as a surgical intervention with fewer complications.

CASE PRESENTATION

Chief complaints

A 65-year-old male presented with the sudden onset of progressive abdominal distension.

History of present illness

The patient's symptoms started two days prior and included associated nausea, dry-heaves, lightheadedness, and melena.

History of past illness

His only medical history is a remote RYGB eight years prior for weight loss.

Personal and family history

The patient denied further medical history. He also denied a history of tobacco, alcohol, and NSAID use. His father died of myocardial infarction at age 70 and his mother was diabetic. He denied a family history of gastrointestinal malignancy.

Physical examination

On presentation, he was afebrile and hemodynamically stable. However, he appeared pale with conjunctival pallor. The abdomen was distended but non-tender with normal bowel sounds. The rectal exam exhibited melena.

Laboratory examinations

Complete blood count and complete metabolic panel were notable for a hemoglobin of 12 g/dL and hematocrit of 35.8%, which were near his baseline. His blood urea nitrogen was 23 mg/dL and his creatinine was 0.8 mg/dL. The remainder of these laboratory examinations, including liver enzymes and coagulation studies, were within normal limits.

Imaging examinations

Chest X-ray was normal. A subsequent computerized tomography scan with intravenous contrast illustrated a massively distended stomach, which was "fluid"-filled (Figure 1).

Further hospital course

A nasogastric tube was inserted, which did not result in any immediate drainage of fluid or decompression of his abdomen.

He immediately underwent an emergent upper endoscopy and EUS for decompression of the gastric remnant. The endoscopy revealed a normal-appearing gastro-jejunal anastomosis without marginal ulceration or evidence of active or recent bleeding in either limb. EUS confirmed the distended "fluid"-filled gastric remnant. We then proceeded to decompress the gastric remnant by creating a gastro-gastrostomy using a Hot AXIOS™ LAMS delivery system. Fine needle aspiration with a 19-gauge needle into the "fluid"-filled gastric remnant revealed maroon aspirate. A safe window for stent placement was found using doppler guidance. A 15 mm × 10 mm AXIOS™ stent was deployed, first by rapidly puncturing the fluid cavity under doppler guidance with the AXIOS™ tip electrified at 90 Watts, then by the ultrasound-controlled deployment of the inner phalange of the stent, and then finally by the endoscopy-controlled deployment of the outer phalange in the lumen of the gastric pouch. Upon deployment, maroon-colored blood immediately started draining. After extensive suctioning, the gastric remnant was decompressed (Figure 2).

Next, balloon dilatation of the stent allowed a gastroscope to access the gastric remnant. Approximately two liters of blood was suctioned before a large adherent clot was visualized in the gastric antrum. Fresh blood was observed oozing around the clot (Figure 3). Endoscopic therapy was not pursued due to the sheer size of the clot and concern of stent dislodgement. The patient was sent for emergent angiography with embolization of the gastroduodenal artery (Figure 4). He remained hospitalized for two additional days. He was discharged with a stable hemoglobin level and resolution of abdominal distension and bleeding. After a three-week interval, a repeat endoscopy for evaluation of the gastric remnant through the gastrogastric fistula was performed. Healing superficial gastric ulcers were visualized (Figure 5). The LAMS was left in place with plans for removal at an interval date. Gastric biopsies were consistent with *Helicobacter pylori* infection for which the patient was treated, and successful eradication was achieved.

FINAL DIAGNOSIS

Helicobacter Pylori infection-induced gastric remnant ulcer bleeding causing outlet obstruction.

TREATMENT

Endoscopic ultrasound-directed transgastric intervention, gastroduodenal artery embolization, and triple therapy including Clarithromycin, Amoxicillin, and Pantoprazole dosed twice daily for a duration of 14 d. This was the treatment of choice given low rates of Clarithromycin resistance in our area and lack of patient risk factors for Clarithromycin resistance.

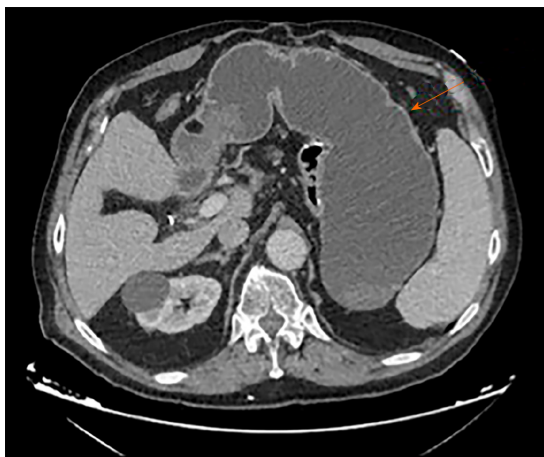


Figure 1 Computerized tomography scan revealing gastric remnant outlet obstruction.

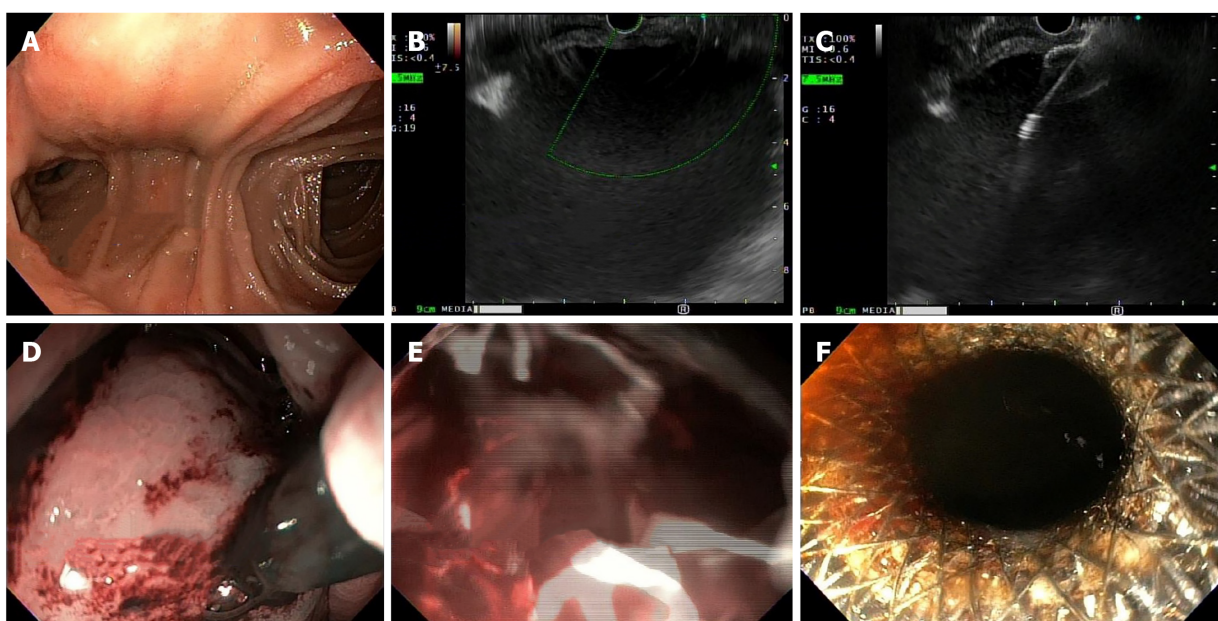


Figure 2 Endoscopy. A: Healthy-appearing mucosa of Roux-en-Y; B: Gastric distension visualized on Endoscopic ultrasound; C: Introduction of Lumen-Appling Metal Stent; D: Endoscopic view of Lumen-Appling Metal Stent placement; E: Immediate decompression with flow of blood through stent; and F: Successful endoscopic ultrasound guided gastro-gastrostomy using Lumen-Appling Metal Stent.

OUTCOME AND FOLLOW-UP

The patient recovered well without complications or weight gain. He completed the course of triple therapy and has not had a recurrence of symptoms. Successful eradication was achieved. He is scheduled for retrieval of his lumen apposing metal stent.

DISCUSSION

Marginal ulcers comprise the vast majority of gastrointestinal bleeding complications in patients who have undergone a RYGB, with an estimated incidence of 0.6%-16%^[4]. Marginal ulcers are easily diagnosed and treated with conventional upper endoscopy. However, ulceration of the gastric remnant or duodenum is rare, with approximately 25 reported cases in the literature^[5-10]. Risk factors for developing such ulcers include hyperacidity of the gastric remnant without the buffering effect of ingested food, bile acid reflux, NSAIDs use, and *Helicobacter pylori* infection^[9]. Most instances of obstruction of the gastric remnant were due to malignancy. Pyloric stenosis was

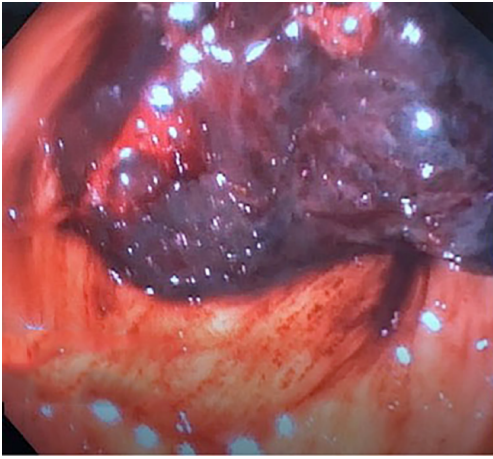


Figure 3 A large clot in gastric antrum of the excluded stomach.

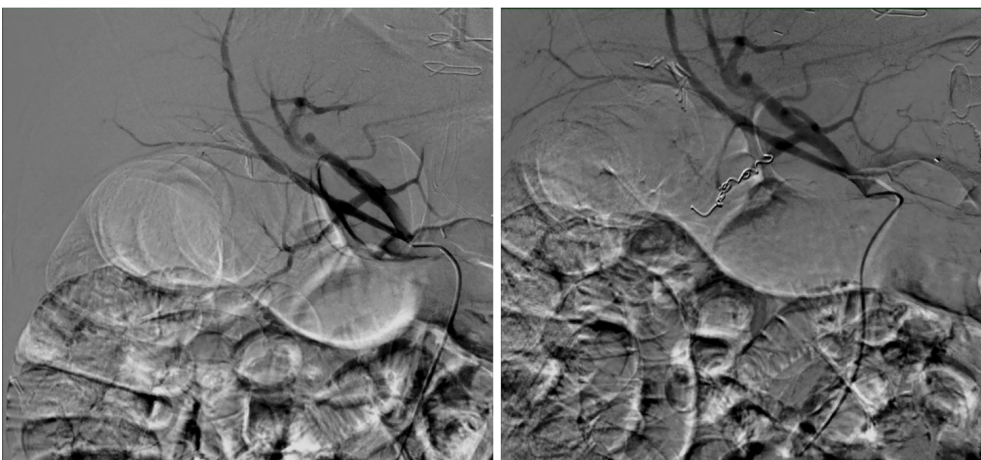


Figure 4 Angiography and embolization of gastroduodenal artery.

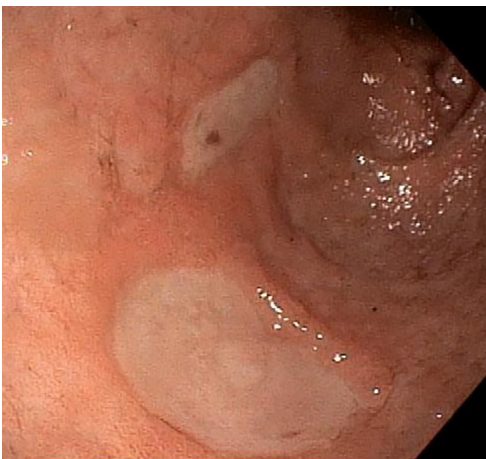


Figure 5 Healing gastric ulcers on follow up endoscopy.

reported as a benign etiology in only one case study^[11]. We were unable to uncover any instances of outlet obstruction of the gastric remnant caused by bleeding ulcers.

Historically, ulceration of the gastric remnant and duodenum has been treated by laparotomy and endoscopy through either a surgical gastrostomy or by enteroscopy. Hakim *et al*^[9] describe two cases of afferent limb bleeding with successful exploration and treatment by push enteroscopy or single-balloon enteroscopy^[9]. However, this

method is not always successful due to difficulty intubating the excluded segment. The low success rate is due to difficulty reaching the duodenum and gastric remnant^[1,2].

Our case supports the use of an alternative and less invasive approach to gastric outlet obstruction of the gastric remnant through EUS-directed creation of gastrogastrostomy with a LAMS. This method is diagnostic, giving the operator the ability to visualize the pathological process by an antegrade approach. It is also therapeutic, forming a conduit by which built up secretions and blood can drain into the patent roux limb, as well as allowing for endoscopic hemostasis to be attempted. The necessity to treat pancreaticobiliary disease with ERCP following a RYGB has resulted in the advent of EUS-directed transgastric ERCP (EDGE). More recently, this method has been grouped under the umbrella term "EDGI", a phrase coined by Krafft *et al*^[3] to highlight the increasing use of this method for accessing the PBL for other diagnostic and therapeutic interventions in addition to ERCP^[3].

Studies on EDGE have shown EUS-directed access of the gastric remnant to be clinically safe and effective. Xu *et al*^[12] describe a case of bile leak that was successfully treated with ERCP performed through a gastrogastrostomy formed by EUS-directed LAMS placement^[12]. The high success rate of accessing the PBL by EUS guidance is highlighted by Kedia *et al*^[13]. In their study, technical success, which was defined as successful deployment of LAMS to form either gastrogastrostomy or jejunogastrostomy, was 100%. Clinical success, which was defined as successful endoscopy through the LAMS, was 90%. Complications included LAMS migration at the index procedure in three patients and jejunal perforation with the insertion of the duodenoscope through the LAMS in one patient. Importantly, none of these patients suffered from clinical sequelae or necessitated surgical intervention^[13,14].

An international, multicenter study of patients who demonstrated the safety and efficacy of EDGI for either benign or malignant gastric outlet obstruction. Not only was the success rate comparable to the surgical approach, but it also was successful as salvage therapy for patients who failed surgery. Adverse events occurred in 11.5%. In comparison, the complication rate of surgical gastrojejunostomy has been reported to be as high as 40%^[15]. Follow-up data after EDGE for these patients revealed no symptom recurrence after a mean follow-up of 7.9 wk in the clinically successful cases^[16]. Though none of these patients presented with bleeding ulcers causing outlet obstruction of the gastric remnant, as in our case, these studies provide evidence for the safety and efficacy of EUS-directed gastrogastrostomy formation with LAMS.

Krafft *et al*^[3] provide direct evidence for clinical and technical effectiveness, as well as safety for EDGI in cases with indications other than ERCP. Their multicenter, retrospective analysis included patients with RYGB who underwent EDGI for indications including gastroduodenal mass, duodenal ulcer perforation, biopsy of pancreatic mass, drainage of pancreatic fluid collections, and common bile duct dilation. Technical success, defined as successful transmural fistula creation using LAMS, and clinical success, defined as the attainment of diagnosis and partial or complete symptom relief, each showed rates of 100% in this small study^[3].

CONCLUSION

Based on our literature review, this is the first described case of an outlet obstruction of the gastric remnant caused by a bleeding ulcer. This case was successfully managed by the creation of a gastrogastrostomy using a lumen-apposing metal stent. Our case adds to the literature evidence for safe and efficacious access to the gastric remnant by EDGI. It sets a precedent for the use of this technique in treating similar clinical scenarios. This method is an effective, safe, and less invasive alternative to surgery.

REFERENCES

- 1 Tagaya N, Kasama K, Inamine S, Zaha O, Kanke K, Fujii Y, Kanehira E, Hiraishi H, Kubota K. Evaluation of the excluded stomach by double-balloon endoscopy after laparoscopic Roux-en-Y gastric bypass. *Obes Surg* 2007; **17**: 1165-1170 [PMID: [18074489](#) DOI: [10.1007/s11695-007-9198-8](#)]
- 2 Sakai P, Kuga R, Safatle-Ribeiro AV, Faintuch J, Gama-Rodrigues JJ, Ishida RK, Furuya CK Jr, Yamamoto H, Ishioka S. Is it feasible to reach the bypassed stomach after Roux-en-Y gastric bypass for morbid obesity? The use of the double-balloon enteroscope. *Endoscopy* 2005; **37**: 566-569 [PMID: [15933931](#) DOI: [10.1055/s-2005-861444](#)]
- 3 Krafft MR, Hsueh W, James TW, Runge TM, Baron TH, Khashab MA, Irani SS, Nasr JY. The EDGI new take on EDGE: EUS-directed transgastric intervention (EDGI), other than ERCP, for Roux-en-Y gastric

- bypass anatomy: a multicenter study. *Endosc Int Open* 2019; 7: E1231-E1240 [PMID: 31579704 DOI: 10.1055/a-0915-2192]
- 4 **Coblign UK**, Lagarde SM, Tuynman JB, van Meyel JJ, van Wagenveld BA. Delayed massive bleeding two years after Roux-en-Y gastric bypass. *JSLS* 2013; 17: 476-480 [PMID: 24018091 DOI: 10.4293/108680813x13693422518470]
 - 5 **Iskandar ME**, Chory FM, Goodman ER, Surick BG. Diagnosis and Management of Perforated Duodenal Ulcers following Roux-En-Y Gastric Bypass: A Report of Two Cases and a Review of the Literature. *Case Rep Surg* 2015; 2015: 353468 [PMID: 25949843 DOI: 10.1155/2015/353468]
 - 6 **Ivanecz A**, Sremec M, CeraniĀ D, PotrĀ S, Skok P. Life threatening bleeding from duodenal ulcer after Roux-en-Y gastric bypass: Case report and review of the literature. *World J Gastrointest Endosc* 2014; 6: 625-629 [PMID: 25512773 DOI: 10.4253/wjge.v6.i12.625]
 - 7 **Ovaere S**, Tse WH, Schipper EE, Spanjersberg WR. Perforation of the gastric remnant in a patient post-Roux-en-Y gastric bypass. *BMJ Case Rep* 2016; 2016 [PMID: 26929225 DOI: 10.1136/bcr-2015-213862]
 - 8 **Macgregor AM**, Pickens NE, Thoburn EK. Perforated peptic ulcer following gastric bypass for obesity. *Am Surg* 1999; 65: 222-225 [PMID: 10075296]
 - 9 **Hakim S**, Reddy SRR, Batke M, Polidori G, Cappell MS. Two case reports of acute upper gastrointestinal bleeding from duodenal ulcers after Roux-en-Y gastric bypass surgery: Endoscopic diagnosis and therapy by single balloon or push enteroscopy after missed diagnosis by standard esophagogastrroduodenoscopy. *World J Gastrointest Endosc* 2017; 9: 521-528 [PMID: 29085563 DOI: 10.4253/wjge.v9.i10.521]
 - 10 **Pan A**, Sahni S, Khan R, Boulay B. "A Rare Cause of Bleeding After Roux-en-Y Gastric Bypass: 2020.". *Am J Gastroenterol* 2018; 113: S1151-S1152 [DOI: 10.14309/00000434-201810001-02020]
 - 11 **Painter TJ**, Teixeira AF, Jawad MA. Pyloric stenosis after a Roux-en-Y gastric bypass: a case report. *Surg Obes Relat Dis* 2015; 11: e9-10 [PMID: 25541110 DOI: 10.1016/j.soard.2014.09.009]
 - 12 **Xu MM**, Carames C, Novikov A, Saumoy M, Afaneh C, Kahaleh M, Sharaiha RZ. One-step endoscopic ultrasound-directed gastro-gastrostomy ERCP for treatment of bile leak. *Endoscopy* 2017; 49: 715-716 [PMID: 28525933 DOI: 10.1055/s-0043-104524]
 - 13 **Kedia P**, Tarnasky PR, Nieto J, Steele SL, Siddiqui A, Xu MM, Tyberg A, Gaidhane M, Kahaleh M. EUS-directed Transgastric ERCP (EDGE) Versus Laparoscopy-assisted ERCP (LA-ERCP) for Roux-en-Y Gastric Bypass (RYGB) Anatomy: A Multicenter Early Comparative Experience of Clinical Outcomes. *J Clin Gastroenterol* 2019; 53: 304-308 [PMID: 29668560 DOI: 10.1097/MCG.0000000000001037]
 - 14 **Tyberg A**, Nieto J, Salgado S, Weaver K, Kedia P, Sharaiha RZ, Gaidhane M, Kahaleh M. Endoscopic Ultrasound (EUS)-Directed Transgastric Endoscopic Retrograde Cholangiopancreatography or EUS: Mid-Term Analysis of an Emerging Procedure. *Clin Endosc* 2017; 50: 185-190 [PMID: 27642849 DOI: 10.5946/ce.2016.030]
 - 15 **Medina-Franco H**, Abarca-Pérez L, España-Gómez N, Salgado-Nesme N, Ortiz-López LJ, García-Alvarez MN. Morbidity-associated factors after gastrojejunostomy for malignant gastric outlet obstruction. *Am Surg* 2007; 73: 871-875 [PMID: 17939415 DOI: 10.2753/CSA0009-4625390103]
 - 16 **Tyberg A**, Perez-Miranda M, Sanchez-Ocaña R, Peñas I, de la Serna C, Shah J, Binmoeller K, Gaidhane M, Grimm I, Baron T, Kahaleh M. Endoscopic ultrasound-guided gastrojejunostomy with a lumen-apposing metal stent: a multicenter, international experience. *Endosc Int Open* 2016; 4: E276-E281 [PMID: 27004243 DOI: 10.1055/s-0042-101789]



Published by **Baishideng Publishing Group Inc**
7041 Koll Center Parkway, Suite 160, Pleasanton, CA 94566, USA

Telephone: +1-925-3991568

E-mail: bpgoffice@wjgnet.com

Help Desk: <https://www.f6publishing.com/helpdesk>

<https://www.wjgnet.com>

