

国内版

国际版



Endoscopic Retrograde Cholangiopancreatography in the Treatm



Q ALL

IMAGES

VIDEOS

30,300 Results

Any time ▾

## Endoscopic Management of Pancreaticopleural Fistula in a ...

<https://www.ncbi.nlm.nih.gov/pmc/articles/PMC6856503>

Endoscopic retrograde cholangiopancreatography (ERCP) was performed to further clarify the possible **duct anomaly** and subsequent **treatment**. The **pancreatic duct** was tortuous and dilated, and there was a filling defect due to the **pancreaticolith** (Fig. 3).

**Author:** Dahye Lee, Eun Joo Lee, Ju Whi Kim... **Publish Year:** 2019

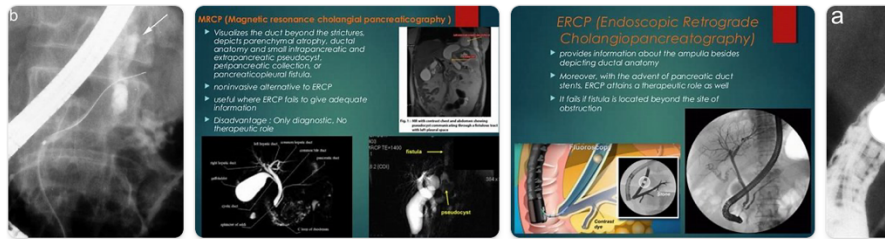
## Pancreaticopleural fistula in children with chronic ...

<https://bmcpediatr.biomedcentral.com/track/pdf/10.1186/s12887-020-02174-x> ▾

Endoscopic retrograde cholangiopancreatography in the **pediatric population** is safe and efficacious. J Pediatr Gastroenterol Nutr. 2013;57:649–54. 46. Kohoutova D, Tringali A, Papparella G, Perri V, Bošković I, Hamanaka J, et al. **Endoscopic treatment of chronic pancreatitis in pediatric population Long-term efficacy and safety.**

## Images of Endoscopic retrograde Cholangiopancreatography In The ...

<bing.com/images>



See more images of Endoscopic retrograde Cholangiopancreatography In The Treatment of Pancreaticopleural fistula In Children

## Pancreaticopleural Fistula - CHEST

[https://journal.chestnet.org/article/S0012-3692\(15\)32762-8/fulltext](https://journal.chestnet.org/article/S0012-3692(15)32762-8/fulltext)



Endoscopic retrograde cholangiopancreatography in the treatment



ALL IMAGES VIDEOS MAPS NEWS SHOPPING

32,100 Results Any time ▾

### Endoscopic Management of Pancreaticopleural Fistula in a ...

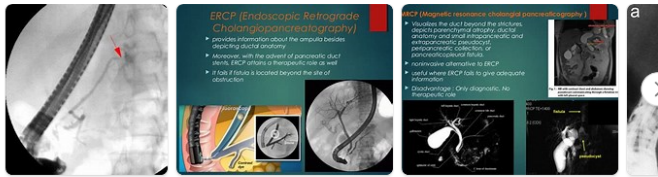<https://www.ncbi.nlm.nih.gov/pmc/articles/PMC6856503>

Endoscopic retrograde cholangiopancreatography (ERCP) was performed to further clarify the **possible duct anomaly and subsequent treatment**. The pancreatic duct was tortuous and dilated, and there was a filling defect due to the pancreaticolith (Fig. 3).

Cited by: 1 Author: Dahye Lee, Eun Joo Lee, Ju Whi Kim, Jin...  
Publish Year: 2019

### Images of Endoscopic retrograde cholangiopancreatography in th...

<bing.com/images>



See all Images >

### [PDF] Pancreaticopleural fistula in children with chronic ...

<https://bmcpediatr.biomedcentral.com/track/pdf/10.1186/s12887-020-02174-x>

PPF in children is mainly associated with chronic pancreatitis (CP); therefore, we highlight the importance of genetic testing. Endoscopic treatment is **recommended when conservative treatment is ineffective**.

Keywords: Pancreaticopleural fistula, Chronic pancreatitis, Child, Case report Background

Pancreaticopleural fistula (PPF) is a very rare critical

Author: Jia-yu Zhang, Zhao-hui Deng, Biao G... Publish Year: 2020

### Pancreaticopleural fistula in children with chronic ...

<https://pubmed.ncbi.nlm.nih.gov/32493290>


 PAGE 1 OF 19
 





 Text-Only Report

## Endoscopic Management of Pancreaticopleural Fistula in a ...

<https://www.ncbi.nlm.nih.gov/pmc/articles/PMC6856503>

Endoscopic retrograde cholangiopancreatography (ERCP) was performed to further clarify the **possible duct anomaly and subsequent treatment**. The pancreatic duct was tortuous and dilated, and there was a filling defect due to the pancreaticolith ( Fig. 3 ).

**Cited by: 1** **Author:** Dahye Lee, Eun Joo Lee, Ju Whi Kim, Ji...

**Publish Year:** 2019

## [PDF] Pancreaticopleural fistula in children with chronic ...

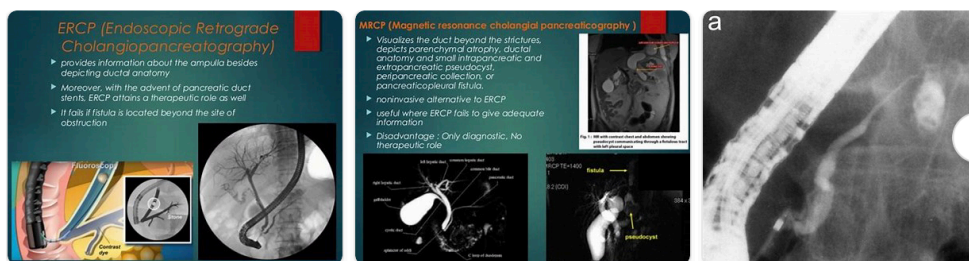
<https://bmcpediatr.biomedcentral.com/track/pdf/10.1186/s12887-020-02174-x>

PPF in children is mainly associated with chronic pancreatitis (CP); therefore, we highlight the importance of genetic testing. Endoscopic treatment is **recommended when conservative treatment is ineffective**. Keywords: Pancreaticopleural fistula, Chronic pancreatitis, Child, Case report Background Pancreaticopleural fistula (PPF) is a very rare critical

**Author:** Jia-yu Zhang, Zhao-hui Deng, Biao ... **Publish Year:** 2020

## Images of Endoscopic retrograde cholangiopancreatography in the ...

[bing.com/images](https://www.bing.com/images)



See all images >