

国内版 国际版



Osteochondral Lesion of Talus with Gout Tophi Deposit



ALL

IMAGES

VIDEOS

45,500 Results

Any time ▾

Intraosseous Gouty Tophus in the Talus: A Case Report ...

<https://www.sciencedirect.com/science/article/pii/S106725161400430X>

Most patients with **intraosseous lesions** have a history of gout before the lesions are found . Patients often complain of **pain** when walking without local **acute inflammatory symptoms** or signs, such as **redness**, **local heat**, **severe pain**, or **tenderness** 1, 2, 6, 9.

Cited by: 2

Author: Chin-Horng Su, Jui-Kuo Hung

Publish Year: 2016

Intraosseous Gouty Tophus at the Talus: A Case Report

https://www.researchgate.net/publication/267159840_Intraosseous_Gouty_Tophus_at_the...

A **34-year-old man** presents with a **cystic lesion** of the **talus** that has developed over the last 3 years and a history of a single first **metatarsophalangeal attack of gout**.

Simple bone cyst of the talus associated with tophaceous ...

<https://www.sciencedirect.com/science/article/pii/S2210794011000654>

Here, we **report** a **case** involving a **43-year-old man** with a simple **cystic lesion** of the **talus** accompanied by **deposition of gouty tophi** in the cyst. The **lesion** was treated with total curettage and filled with a bony substitute of calcium sulfate pellets impregnated with autogenous bone marrow. To the best of our knowledge, this is the first **report** of a simple bone cyst complicated by intracystic **gouty tophus deposition**...

Author: Kun-Yi Lin, Tsung-Ying Tsai, Hsain-...

Publish Year: 2011

Case Reports in Orthopedics - Hindawi

<https://www.hindawi.com/journals/crior/2019/9617184> ▾

We **report** one such **case** of **extra-articular deposition** of the CPPD crystals in a **65-year-old man** who presented with an asymptomatic swelling around the left ankle. **Radiographs** showed a dense homogeneous calcification, and EMAC revealed dense calcium deposits with numerous rhomboid



Osteochondral lesion of talus with gout tophi deposition: A case report



ALL IMAGES VIDEOS MAPS NEWS SHOPPING

12,100 Results Any time ▾

Intraosseous Gouty Tophus in the Talus: A Case Report ...

<https://www.sciencedirect.com/science/article/pii/S106725161400430X>

Mar 01, 2016 · Gout is a chronic form of arthritis caused by excess levels of uric acid in the blood. Although the disease normally results in the **deposition** of monosodium urate crystals in the connective tissue, kidney, and skin, intraosseous **deposition** of monosodium urate can occur in the clavicle, femoral condyle, metatarsal bone, sesamoid bone, phalanges, patella, calcaneus, vertebral body, and **talus** 1 ...

Cited by: 2 **Author:** Chin-Horng Su, Jui-Kuo Hung

Publish Year: 2016

Simple bone cyst of the talus associated with tophaceous ...

<https://www.sciencedirect.com/science/article/pii/S2210794011000654>

Nov 01, 2011 · Here, we **report a case** involving a **43-year-old man** with a simple **cystic lesion** of the **talus** accompanied by **deposition of gouty tophi** in the cyst. The **lesion** was treated with total curettage and filled with a bony substitute of calcium sulfate pellets impregnated with autogenous bone marrow. To the best of our knowledge, this is the first **report** of a simple bone cyst complicated by **intracystic gouty tophus deposition**...

Author: Kun-Yi Lin, Tsung-Ying Tsai, Hsain-Ch... **Publish Year:** 2011

Intraosseous Gouty Tophus at the Talus: A Case Report

<https://www.researchgate.net/publication/267159840...>

A **34-year-old man** presents with a **cystic lesion** of the **talus** that has developed over the last 3 years and a history of a single first **metatarsophalangeal attack** of **gout**. Radiodiagnostic studies...

The results of arthroscopic treatment for talus ...

bayrakol.org/en/2019/may2019/original-article-may... ▾

Transferring autologous **osteochondral** graft from the ipsilateral side into the talar dome **defect** [4] and open mosaicoplasty has been studied as an effective treatment modality in **lesions** larger than 1.5 cm in diameter with subchondral cyst formation [5].

CARTILAGE LESIONS OF THE TALUS | GEORGE D. GOUDELIS MD. ...

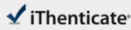
<https://www.goudelis.gr/en/content/cartilage-lesions-talus> ▾

<https://global.bing.com/?FORM=Z9FD1> Cartilage lesions of the talus are focal injuries of the articular cartilage and subjacent subchondral bone. These articular defects primarily occur as a result of acute and chronic trauma.

14 Aug 2020 03:48PM

2046 words • 12 matches • 9 sources

FAQ

iThenticate®

56573-Review-check.docx

Quotes Excluded
Bibliography Excluded
17%

Name of Journal: *World Journal of Clinical Cases*

Manuscript NO: 56573

Manuscript Type: CASE REPORT

Osteochondral lesion of talus with gout tophi deposition: A case report

Kim T *et al.* OLT with gout tophi deposition

Taeho Kim, Young-Rak Choi

Abstract

BACKGROUND

Osteochondral lesion of talus is a broad term used to describe an injury or abnormality of the talar articular cartilage and adjacent bone. It arises from diverse causes, and although trauma is implicated in many cases, it does not account for the etiology of every lesion. Gout is a chronic arthritic disease caused by excess levels of uric acid in blood. Intraosseous deposition of monosodium urate in the clavicle, femur, patella and calcaneus was reported previously. Gout is common disease but rare at a young age, especially during teenage years. Osteochondral lesion caused by intra-articular gouty

Match Overview

1

Internet 51 words
crawled on 19-Feb-2019
[www.artrosurface.com](#)

3%

2

Internet 49 words
crawled on 07-Sep-2017
[digitalcommons.wustl.edu](#)

3%

3

Crossref 42 words
Chin-Hong Su, Jui-Kuo Hung, "Intraosseous Gouty Tophus ...
the Talus: A Case Report", *The Journal of Foot and Ankle Sur*

3%

4

Crossref 26 words
Hong Chao, Teck Yew Chin, Wilfred C. G. Peh, "Dual-energy ...
CT in gout - A review of current concepts and applications", *J*

2%

5

Internet 23 words
crawled on 18-Jul-2020
[medRxiv.com](#)

1%

6

Crossref 20 words
Patrick J. McCutcheon, Stephen J. Pinney, "Current Concept F...
view: Osteochondral Lesions of the Talus", *Foot & Ankle Inter*

1%

7

Internet 18 words
crawled on 07-Aug-2019
[arthritis-research.biomedcentral.com](#)

1%

8

Crossref 16 words
Denise Pugash, "Fetal MRI of Normal Brain Development", *M*
edical Radiology, 2010

1%

9

Internet 16 words
crawled on 03-Jun-2016
[www.arthritis-research.com](#)

1%

PAGE 1 OF 3

Test Only Report



国内版

国际版

Osteochondral lesion of talus with gout tophi deposition: A case re



ALL

IMAGES

VIDEOS

12,300 Results

Any time ▾

Intraosseous Gouty Tophus in the Talus: A Case Report ...

<https://www.sciencedirect.com/science/article/pii/S106725161400430X>

Mar 01, 2016 · We **report** the 15-month outcome of a patient with **intraosseous gout** at the **talus** that was treated by curettage and artificial bone grafting. **Case Report A 42-year-old male** with a history of hypertension presented to a different clinic with a ...

Cited by: 2

Author: Chin-Horng Su, Jui-Kuo Hung

Publish Year: 2016

Simple bone cyst of the talus associated with tophaceous ...

<https://www.sciencedirect.com/science/article/pii/S2210794011000654>

Nov 01, 2011 · Rare **cases** of **intraosseous gouty tophus** have been **reported**, but the present **case** represents the first **report** of a simple **cystic lesion** involving the **talus** with **secondary intracystic gouty tophus deposition**. Additionally, the **lesion** contained highly viscous mucinous soft tissue material rather than the typical **chalky white material reported** in the literature.

Author: Kun-Yi Lin, Tsung-Ying Tsai, Hsain-...

Publish Year: 2011

Intraosseous Gouty Tophus at the Talus: A Case Report

https://www.researchgate.net/publication/267159840_Intraosseous_Gouty_Tophus_at_the...

A 34-year-old man presents with a cystic **lesion** of the **talus** that has developed over the last 3 years and a history of a single first metatarsophalangeal attack of **gout**.

PEOPLE ALSO ASK

What is osteochondral ankle defect?



What is etiology osteochondritis dissecans?

