

国内版

国际版

Idiopathic Multicentric Castleman Disease with Puir

Sign in

Chat with Bing

ALLIMAGESVIDEOS

12,800 ResultsAny time

Castleman's Disease with Cutaneous Involvement ...

<https://www.ncbi.nlm.nih.gov/pmc/articles/PMC3229057>

Oct 31, 2011 · INTRODUCTION. **Castleman's disease** (CD) is an angiofollicular lymphoid hyperplasia, or giant lymph node hyperplasia. It is characterized by lymph node hyperplasia and vascular proliferation 1, 2.It was first described in 1956 by **Castleman** et al. 3 as a localized lymphadenopathy that usually involves mediastinum or pulmonary hilus resembling thymoma. Keller et al. 2 divided CD ...

Cited by: 3Author: Hyeon-Young Park, Je-Jung Lee, Jee-Bu...Publish Year: 2011

Cutaneous castleman's disease responds to anti-interleukin ...

<https://www.researchgate.net/publication/6073361...>

The literature suggests that **Castleman's disease** is driven by interleukin-6 (IL-6). Based on these data, we hypothesized that suppression of IL-6 would have a salutary effect. Therefore, our...

International, evidence-based consensus treatment ...

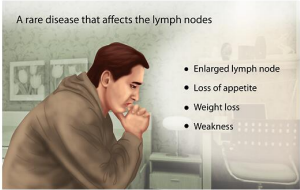
<https://www.ncbi.nlm.nih.gov/pubmed/30181172>

Nov 15, 2018 · International, evidence-based consensus treatment guidelines for idiopathic multicentric **Castleman disease**. ... review of treatment effectiveness for 344 cases, and expert

Castleman Disease

Medical Condition

A rare disease that affects the lymph nodes



- Enlarged lymph node
- Loss of appetite
- Weight loss
- Weakness

A disorder which leads to proliferation of cells in the lymphatic system.

Very rare (Fewer than 20,000 cases per year in US)

Requires lab test or imaging

Idiopathic multicentric Castleman disease with pulmonary and cuta...

ALLIMAGESVIDEOSMAPSNEWSSHOPPING

24,200 ResultsAny time

Idiopathic multicentric Castleman's disease: a systematic ...  
https://www.thelancet.com/journals/lanhae/article/PIIS2352-3026(16)00006-5/fulltext  
A case of multicentric Castleman's disease having lung lesion successfully treated with humanized anti-interleukin-6 receptor antibody, tocilizumab. J Korean Med Sci. 2010; 25 : 1364-1367 Crossref  
Cited by: 118Author: Amy Y Liu, Christopher S Nabel, Brian S ...  
Publish Year: 2016

Case Report: A comorbid case of multicentric Castleman's ...  
https://www.ncbi.nlm.nih.gov/pmc/articles/PMC3794123  
He was diagnosed with multicentric Castleman's disease complicated by pulmonary hyalinising granulomas, his symptoms improved by treatment with tocilizumab, which is a humanised antihuman IL-6 receptor monoclonal antibody and corticosteroid. This is the first report of a comorbid case successfully treated with tocilizumab and corticosteroid.  
Author: Naoko Takeuchi, Toru Arai, Masanori ...Publish Year: 2013

International, evidence-based consensus treatment ...  
https://www.ncbi.nlm.nih.gov/pmc/articles/PMC6238190  
Nov 15, 2018 : Introduction. Castleman described the first case of Castleman disease (CD) involving a single lymph node station, which is now referred to as unicentric CD. 1 Characteristic histopathological features observed in CD lymph nodes include hyaline vascular, plasmacytic, and mixed variants. 2,3 CD was later observed to affect multiple lymph node stations, which is known as multicentric Castleman ...  
Cited by: 54Author: Frits van Rhee, Peter Voorhees, Angela ...  
Publish Year: 2018

PEOPLE ALSO ASK

What is multicentric Castleman's disease?

What is the prognosis for Castleman disease?

What are the symptoms of unicentric Castleman disease?

What is inheritance of Castleman disease?

Castleman Disease

Medical Condition

A rare disease that affects the lymph nodes

Enlarged lymph node

Loss of appetite

Weight loss

Weakness

A disorder which leads to proliferation of cells in the lymphatic system.

Very rare (Fewer than 20,000 cases per year in US)

Requires lab test or imaging

Treatment from medical professional advised

Can last several years or be lifelong

The exact cause is not known. Possible causes include HHV8 viral infection and genetic mutations. It is associated with increased levels of interleukins. The main symptom is enlarged lymph node. Other symptoms include, weakness, loss of appetite, weight loss, and fever. Treatment includes, surgery, antiviral therapy, corticosteroids, and chemotherapy.

Symptoms

The main symptom is one or more enlarged lymph nodes. Symptoms vary depending on whether the condition is unicentric (often asymptomatic), or multicentric. Further, some symptoms may be specific to the location of the

62-Sep-2020 11:22AM

3632 words • 22 matches • 13 sources

FAQ

iThenticate

56691-Review-check.docx

Quotes Excluded  
Bibliography Excluded

14%

10

**Name of Journal:** *World Journal of Clinical Cases*

**Manuscript NO:** 56691

**Manuscript Type:** CASE REPORT

**Idiopathic multicentric Castleman disease with pulmonary and cutaneous lesions treated with tocilizumab: A case report**

Han PY *et al.* Pulmonary and cutaneous lesions of iMCD

Ping-Yang Han, Hui-Hui Chi, Yu-Tong Su

**Abstract**

**BACKGROUND**

Human herpes virus-8 (HHV-8)-negative, idiopathic multicentric Castleman disease (iMCD) is a rare and life-threatening disorder driven by proinflammatory cytokines, which is still poorly understood. Pulmonary parenchyma lesion is a rare condition in iMCD, which mainly manifests as lymphocytic interstitial pneumonia (LIP) and is an indicator of severe iMCD. Cutaneous lesion is also very rare and mainly occurs in Asians. There were few reports of iMCD patients with both skin and lung parenchyma

Match Overview

1

Internet 108 words  
crawled on 62-Aug-2020  
[www.ncbi.nlm.nih.gov](#)

4%

2

Crossref 46 words  
Tennay S, Panchabhai, Carol Farver, Kristin B. Highland, "Lymphocytic Interstitial Pneumonia", *Clinics in Chest Medi*

2%

3

Internet 42 words  
crawled on 15-Apr-2020  
[journals.lww.com](#)

1%

4

Crossref 36 words  
R. Okuyama "Indurated nodules and plaques showing a dense plasma cell infiltrate as a cutaneous manifestation o...

1%

5

Internet 34 words  
crawled on 21-Jul-2020  
[www.imal.upenn.edu](#)

1%

6

Internet 29 words  
crawled on 24-Mar-2010  
[repository.kulib.kyoto-u.ac.jp](#)

1%

7

Internet 29 words  
crawled on 08-Oct-2016  
[old.biomedcentral.com](#)

1%

8

Internet 28 words  
crawled on 02-Jul-2014  
[online.library.wiley.com](#)

1%

9

Internet 18 words  
crawled on 22-Apr-2016  
[www.bloodjournal.org](#)

1%

10

Internet 16 words  
crawled on 27-Apr-2020  
[ispublishing.bbb.com.windows.net](#)

1%

PAGE: 1 OF 14

Task Only Report



国内版

国际版

Idiopathic multicentric Castleman disease with pulmonary and cut



ALL

IMAGES

VIDEOS

27,400 Results

Any time ▾

### Case Report: A comorbid case of multicentric Castleman's ...

<https://www.ncbi.nlm.nih.gov/pmc/articles/PMC3794123>

He was **diagnosed with multicentric Castleman's disease** complicated by **pulmonary hyalinising granulomas**; his symptoms improved by **treatment with tocilizumab**, which is a humanised antihuman IL-6 **receptor monoclonal antibody and corticosteroid**. This is the first report of a comorbid case successfully **treated with tocilizumab and corticosteroid**.

**Author:** Naoko Takeuchi, Toru Arai, Masanori... **Publish Year:** 2013

### Idiopathic multicentric Castleman's disease: a systematic ...

[https://www.thelancet.com/journals/lanhae/article/PIIS2352-3026\(16\)00006-5/fulltext](https://www.thelancet.com/journals/lanhae/article/PIIS2352-3026(16)00006-5/fulltext)

A case of **multicentric Castleman's disease** having **lung lesion** successfully **treated with humanized anti-interleukin-6 receptor antibody, tocilizumab**. J Korean Med Sci. 2010; 25 : 1364-1367 Crossref

**Cited by:** 118

**Author:** Amy Y Liu, Christopher S Nabel, Brian S...

**Publish Year:** 2016

### Case report: HHV-8-negative multicentric Castleman disease ...

<https://www.ncbi.nlm.nih.gov/pmc/articles/PMC6954780>

Jan 06, 2020 · Background. **Castleman disease** is a rare 1 2 polyclonal lymphoproliferative disorder characterised by three histological patterns: hyaline vascular, plasma cell and plasmablastic. 2 Clinical presentation is heterogeneous 2 and classified into unicentric or **multicentric disease**. 1 2 Unicentric **Castleman disease** is the most frequent type. 3 It involves ...

**Author:** Maria Brito Nunes, Samuel Rotman, ... **Publish Year:** 2020

#### PEOPLE ALSO ASK

What is multicentric Castleman's disease?

