

Match Overview

1 Internet 15 words
crawled on 20-Jul-2020
pubs.rsc.org

1%

Name of Journal: *World Journal of Clinical Cases*

Manuscript NO: 56694

Manuscript Type: CASE REPORT

Huge encrusted ureteral stent forgotten for over 25 years

Dong Soo Kim, Sang Hyub Lee

Abstract

BACKGROUND

Ureteral stent insertion is a relatively non-invasive procedure commonly used in the field of urology to resolve urinary obstruction. However, they are sometimes forgotten

Huge encrusted ureteral stent forgotten for over 25 years; A case re



ALL

IMAGES

VIDEOS

39,500 Results

Any time ▼

Management of forgotten double J stent and severe multiple ...

<https://www.ncbi.nlm.nih.gov/pmc/articles/PMC3921802>

Dec 11, 2012 - This **case** represents a preventable complication of **forgotten ureteral stents** and the multimodal option for managing such complex cases. One should always consider the presence of severe encrustations when dealing with a **forgotten stent**. A combined urologic approach can achieve a safe and successful outcome in the treatment of **forgotten stents**.

Cited by: 3**Author:** Vidhyadhar Kelkar, Deepak Patil**Publish Year:** 2012

Forgotten ureteral stents: Risk factors, complications and ...

<https://www.sciencedirect.com/science/article/pii/S111057041730098X>

Mar 01, 2018 - Results. The study included 68 patients with mean age 49.3 ± 12.6 **years** 80.9% were males. Mean stenting duration 17.3 ± 12.7 months. A total of 29% of patients received urine acidifier while the **stent** was indwelling, 92% were stone formers, 60% presented with UTI and **25%** presented with elevated creatinine.

Cited by: 5**Author:** A.Y. Abdelaziz, W.B. Fouda, A.A. Moshar...**Publish Year:** 2018

Fragmentation of a forgotten ureteric stent: case report ...

[https://www.thefreelibrary.com/Fragmentation+of+a... ▼](https://www.thefreelibrary.com/Fragmentation+of+a...)

May 12, 2014 - (4) **Forgotten stent** refers to an overlooked **stent** (5, 6) that is generally associated with significant complications such as sepsis, renal decompensation, massive encrustation and **stent** fragmentation. **CASE REPORT:** A **25 years** old male presented with dribbling of urine and hematuria. On abdominal examination bladder was palpable.

Huge encrusted ureteral stent forgotten for over 25 years



ALL

IMAGES

VIDEOS

9,750 Results

Any time ▾

[How long is too long? "I forgot that I had a ureteral stent"](https://www.kidneystoners.org/surgery/how-long-is-too-long-i-forgot-that-i)

<https://www.kidneystoners.org/surgery/how-long-is-too-long-i-forgot-that-i> ▾

Oct 24, 2011 · One study found that 9.2% of **stents** became **encrusted** when in place for less than 6 weeks, while 47.5% of **stents** that remained in place for 6 to 12 weeks were **encrusted** and 76.3% of **stents** were **encrusted** after 12 weeks (El-Faqih et al, 1991). The length of time a **stent** remains in place is in fact the greatest risk factor for **stent** encrustation.

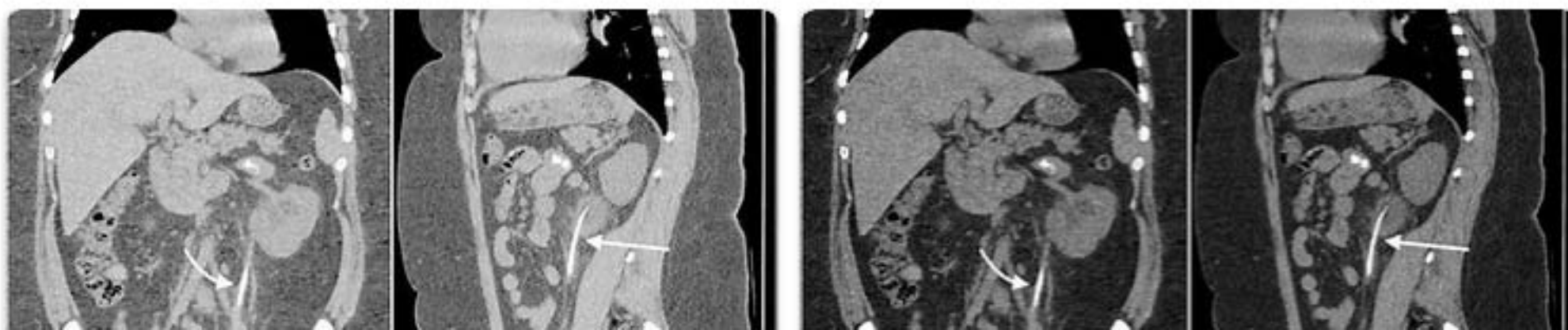
[Challenges in treatment and diagnosis of forgotten ...](https://pubmed.ncbi.nlm.nih.gov/27089423)

<https://pubmed.ncbi.nlm.nih.gov/27089423>

The average age of the patients was 38.2 ± 25.06 (2-86) **years**. The average indwelling time of the **ureteral stents** was 22.6 ± 30.3 (6-144) months. Six of the patients with **forgotten stents** had solitary kidneys. The double-J **stent** (DJS) was fragmented in four (7.4%) patients. A urinary system infection was present in 15 (27.7%) of the patients.

Cited by: 8**Author:** Senol Adanur, Fatih Ozkaya**Publish Year:** 2016

[Images of Huge Encrusted Ureteral Stent Forgotten For Over ...](bing.com/images)

<bing.com/images>

ALL

IMAGES

VIDEOS

MAPS

NEWS

SHOPPING

46,700 Results

Any time ▼

Forgotten ureteral stents: Risk factors, complications and ...

<https://www.sciencedirect.com/science/article/pii/S111057041730098X>

Mar 01, 2018 · Results. The study included 68 patients with mean age 49.3 ± 12.6 years 80.9% were males. Mean stenting duration 17.3 ± 12.7 months. A total of 29% of patients received urine acidifier while the **stent** was indwelling, 92% were stone formers, 60% presented with UTI and **25%** presented with elevated creatinine.

Cited by: 5

Author: A.Y. Abdelaziz, W.B. Fouda, A.A. Moshar...

Publish Year: 2018

Challenges in treatment and diagnosis of forgotten ...

<https://pubmed.ncbi.nlm.nih.gov/27089423>

The average age of the patients was 38.2 ± 25.06 (2-86) years. The average indwelling time of the **ureteral stents** was 22.6 ± 30.3 (6-144) months. Six of the patients with **forgotten stents** had solitary kidneys. The double-J **stent** (DJS) was fragmented in four (7.4%) patients. A urinary system infection was present in 15 (27.7%) of the patients.

Cited by: 8

Author: Senol Adanur, Fatih Ozkaya

Publish Year: 2016

An Indwelling Ureteral Stent Forgotten for Over 12 Years ...

<https://www.liebertpub.com/doi/10.1089/cren.2016.0073>

Jul 15, 2016 · Prolonged **stent** dwell time is associated with a greater degree of these complications. We present the **case** of a 36-year-old man who presented with a severely **encrusted ureteral stent** that had been placed 12.5 years prior for an obstructive left-sided **ureteral** stone and was lost to follow-up.

Cited by: 3

Author: Samir Bidnur, Melissa Huynh, Nathan Ho...

Publish Year: 2016

Ureteroscopic removal of forgotten ureteral stent | BMJ ...

<https://casereports.bmj.com/content/2012/bcr.02.2012.5736> ▼

Jun 15, 2012 · A 69-year-old female had a right **ureteral stent** placed due to **ureteral** stricture resulting from cervical cancer in March 2008. The **ureteral stent** migrated to the ureter and was not exchanged. A new **ureteral stent** was inserted, and was exchanged every 3 months. The patient was referred to our