

# World Journal of *Clinical Cases*

*World J Clin Cases* 2020 November 6; 8(21): 5070-5495



## Contents

Semimonthly Volume 8 Number 21 November 6, 2020

## REVIEW

- 5070** Strategies and challenges in the treatment of chronic venous leg ulcers  
*Ren SY, Liu YS, Zhu GJ, Liu M, Shi SH, Ren XD, Hao YG, Gao RD*
- 5086** Peripheral nerve tumors of the hand: Clinical features, diagnosis, and treatment  
*Zhou HY, Jiang S, Ma FX, Lu H*

## MINIREVIEWS

- 5099** Treatment strategies for gastric cancer during the COVID-19 pandemic  
*Kang WZ, Zhong YX, Ma FH, Liu H, Ma S, Li Y, Hu HT, Li WK, Tian YT*

## ORIGINAL ARTICLE

## Retrospective Cohort Study

- 5104** Oncological impact of different distal ureter managements during radical nephroureterectomy for primary upper urinary tract urothelial carcinoma  
*Lai SC, Wu PJ, Liu JY, Seery S, Liu SJ, Long XB, Liu M, Wang JY*
- 5116** Clinical characteristics and survival of patients with normal-sized ovarian carcinoma syndrome: Retrospective analysis of a single institution 10-year experiment  
*Yu N, Li X, Yang B, Chen J, Wu MF, Wei JC, Li KZ*

## Retrospective Study

- 5128** Assessment of load-sharing thoracolumbar injury: A modified scoring system  
*Su QH, Li YC, Zhang Y, Tan J, Cheng B*
- 5139** Accuracy of endoscopic ultrasound-guided needle aspiration specimens for molecular diagnosis of non-small-cell lung carcinoma  
*Su W, Tian XD, Liu P, Zhou DJ, Cao FL*
- 5149** Application of hybrid operating rooms for clipping large or giant intracranial carotid-ophthalmic aneurysms  
*Zhang N, Xin WQ*
- 5159** Magnetic resonance imaging findings of carcinoma arising from anal fistula: A retrospective study in a single institution  
*Zhu X, Zhu TS, Ye DD, Liu SW*
- 5172** Efficacy and safety of S-1 maintenance therapy in advanced non-small-cell lung cancer patients  
*Cheng XW, Leng WH, Mu CL*

- 5180** Analysis of 234 cases of colorectal polyps treated by endoscopic mucosal resection  
*Yu L, Li N, Zhang XM, Wang T, Chen W*
- 5188** Epidemiological and clinical characteristics of fifty-six cases of COVID-19 in Liaoning Province, China  
*Wang JB, Wang HT, Wang LS, Li LP, Xu J, Xu C, Li XH, Wu YH, Liu HY, Li BJ, Yu H, Tian X, Zhang ZY, Wang Y, Zhao R, Liu JY, Wang W, Gu Y*
- 5203** Radiomics model for distinguishing tuberculosis and lung cancer on computed tomography scans  
*Cui EN, Yu T, Shang SJ, Wang XY, Jin YL, Dong Y, Zhao H, Luo YH, Jiang XR*
- 5213** Influence of transitional nursing on the compliance behavior and disease knowledge of children with purpura nephritis  
*Li L, Huang L, Zhang N, Guo CM, Hu YQ*
- Randomized Controlled Trial**
- 5221** Wavelet and pain rating index for inhalation anesthesia: A randomized controlled trial  
*Zhang JW, Lv ZG, Kong Y, Han CF, Wang BG*

**SYSTEMATIC REVIEWS**

- 5235** Essential phospholipids for nonalcoholic fatty liver disease associated with metabolic syndrome: A systematic review and network meta-analysis  
*Dajani AI, Popovic B*
- 5250** Cardiovascular impact of COVID-19 with a focus on children: A systematic review  
*Rodriguez-Gonzalez M, Castellano-Martinez A, Cascales-Poyatos HM, Perez-Reviriego AA*
- 5284** Anterior bone loss after cervical disc replacement: A systematic review  
*Wang XF, Meng Y, Liu H, Hong Y, Wang BY*

**CASE REPORT**

- 5296** Submicroscopic 11p13 deletion including the elongator acetyltransferase complex subunit 4 gene in a girl with language failure, intellectual disability and congenital malformations: A case report  
*Toral-Lopez J, González Huerta LM, Messina-Baas O, Cuevas-Covarrubias SA*
- 5304** Pancreatic panniculitis and elevated serum lipase in metastasized acinar cell carcinoma of the pancreas: A case report and review of literature  
*Miksch RC, Schiergens TS, Weniger M, Ilmer M, Kazmierczak PM, Guba MO, Angele MK, Werner J, D'Haese JG*
- 5313** Diffusion-weighted imaging might be useful for reactive lymphoid hyperplasia diagnosis of the liver: A case report  
*Tanaka T, Saito K, Yunaiyama D, Matsubayashi J, Nagakawa Y, Tanigawa M, Nagao T*
- 5320** Nafamostat mesylate-induced hyperkalemia in critically ill patients with COVID-19: Four case reports  
*Okajima M, Takahashi Y, Kaji T, Ogawa N, Mouri H*

- 5326** Arthroscopic treatment of iliopsoas tendinitis after total hip arthroplasty with acetabular cup malposition: Two case reports  
*Won H, Kim KH, Jung JW, Kim SY, Baek SH*
- 5334** Successful treatment of a high-risk nonseminomatous germ cell tumor using etoposide, methotrexate, actinomycin D, cyclophosphamide, and vincristine: A case report  
*Yun J, Lee SW, Lim SH, Kim SH, Kim CK, Park SK*
- 5341** Donepezil-related inadequate neuromuscular blockade during laparoscopic surgery: A case report  
*Jang EA, Kim TY, Jung EG, Jeong S, Bae HB, Lee S*
- 5347** Successful treatment of relapsed acute promyelocytic leukemia with arsenic trioxide in a hemodialysis-dependent patient: A case report  
*Lee HJ, Park SG*
- 5353** Treatment of afferent loop syndrome using fluoroscopic-guided nasointestinal tube placement: Two case reports  
*Hu HT, Ma FH, Wu ZM, Qi XH, Zhong YX, Xie YB, Tian YT*
- 5361** Emergency surgical workflow and experience of suspected cases of COVID-19: A case report  
*Wu D, Xie TY, Sun XH, Wang XX*
- 5371** Seven-year follow-up of the nonsurgical expansion of maxillary and mandibular arches in a young adult: A case report  
*Yu TT, Li J, Liu DW*
- 5380** Pancreatic cancer with ovarian metastases: A case report and review of the literature  
*Wang SD, Zhu L, Wu HW, Dai MH, Zhao YP*
- 5389** Early ultrasound diagnosis of conjoined twins at eight weeks of pregnancy: A case report  
*Liang XW, Cai YY, Yang YZ, Chen ZY*
- 5394** Supermicroscopy and arterio-venolization for digit replantation in young children after traumatic amputation: Two case reports  
*Chen Y, Wang ZM, Yao JH*
- 5401** Candidal periprosthetic joint infection after primary total knee arthroplasty combined with ipsilateral intertrochanteric fracture: A case report  
*Xin J, Guo QS, Zhang HY, Zhang ZY, Talmy T, Han YZ, Xie Y, Zhong Q, Zhou SR, Li Y*
- 5409** Aspiration pneumonia during general anesthesia induction after esophagectomy: A case report  
*Tang JX, Wang L, Nian WQ, Tang WY, Xiao JY, Tang XX, Liu HL*
- 5415** Large and unusual presentation of gallbladder adenoma: A case report  
*Cao LL, Shan H*
- 5420** Rare narrow QRS tachycardia with atrioventricular dissociation: A case report  
*Zhu C, Chen MX, Zhou GJ*

- 5426** Synchronous parathyroid adenoma, papillary thyroid carcinoma and thyroid adenoma in pregnancy: A case report  
*Li Q, Xu XZ, Shi JH*
- 5432** Pseudohyperkalemia caused by essential thrombocythemia in a patient with chronic renal failure: A case report  
*Guo Y, Li HC*
- 5439** Acute leukemic phase of anaplastic lymphoma kinase-anaplastic large cell lymphoma: A case report and review of the literature  
*Zhang HF, Guo Y*
- 5446** Chinese patient with cerebrotendinous xanthomatosis confirmed by genetic testing: A case report and literature review  
*Cao LX, Yang M, Liu Y, Long WY, Zhao GH*
- 5457** Incomplete Kawasaki disease complicated with acute abdomen: A case report  
*Wang T, Wang C, Zhou KY, Wang XQ, Hu N, Hua YM*
- 5467** Fanconi-Bickel syndrome in an infant with cytomegalovirus infection: A case report and review of the literature  
*Xiong LJ, Jiang ML, Du LN, Yuan L, Xie XL*
- 5474** Benign symmetric lipomatosis (Madelung's disease) with concomitant incarcerated femoral hernia: A case report  
*Li B, Rang ZX, Weng JC, Xiong GZ, Dai XP*
- 5480** Potential protection of indocyanine green on parathyroid gland function during near-infrared laparoscopic-assisted thyroidectomy: A case report and literature review  
*Peng SJ, Yang P, Dong YM, Yang L, Yang ZY, Hu XE, Bao GQ*
- 5487** New treatment of patellar instability after total knee arthroplasty: A case report and review of literature  
*Shen XY, Zuo JL, Gao JP, Liu T, Xiao JL, Qin YG*

**CORRECTION**

- 5494** Erratum: Author's Affiliation Correction. Type II human epidermal growth factor receptor heterogeneity is a poor prognosticator for type II human epidermal growth factor receptor positive gastric cancer (World J Clin Cases 2019; Aug 6; 7 (15): 1964-1977)  
*Kaito A, Kuwata T, Tokunaga M, Shitara K, Sato R, Akimoto T, Kinoshita T*



**ABOUT COVER**

Peer-reviewer for *World Journal of Clinical Cases*, Dr. Karayiannakis is Professor of Surgery at the Medical School of Democritus University of Thrace. He received his MD from the Medical Academy, Sofia, Bulgaria (1985), an MSc in Surgical Science from University of London (1996), and a PhD from National and Kapodistrian University of Athens (NKUA) (1993). After completing training at the NKUA Medical School in 1993, Dr. Karayiannakis undertook postgraduate training at St George's and Hammersmith Hospitals (London), the Institute for Digestive Diseases (Serbia), the University of Verona (Italy), and the Technical University of Munich (Germany). His clinical practice interests and research emphasis are in the field of hepato-pancreato-biliary diseases and gastrointestinal tract surgery, surgical oncology and laparoscopic surgery. (L-Editor: Filipodia)

**AIMS AND SCOPE**

The primary aim of *World Journal of Clinical Cases* (*WJCC*, *World J Clin Cases*) is to provide scholars and readers from various fields of clinical medicine with a platform to publish high-quality clinical research articles and communicate their research findings online.

*WJCC* mainly publishes articles reporting research results and findings obtained in the field of clinical medicine and covering a wide range of topics, including case control studies, retrospective cohort studies, retrospective studies, clinical trials studies, observational studies, prospective studies, randomized controlled trials, randomized clinical trials, systematic reviews, meta-analysis, and case reports.

**INDEXING/ABSTRACTING**

The *WJCC* is now indexed in Science Citation Index Expanded (also known as SciSearch®), Journal Citation Reports/Science Edition, PubMed, and PubMed Central. The 2020 Edition of Journal Citation Reports® cites the 2019 impact factor (IF) for *WJCC* as 1.013; IF without journal self cites: 0.991; Ranking: 120 among 165 journals in medicine, general and internal; and Quartile category: Q3.

**RESPONSIBLE EDITORS FOR THIS ISSUE**

Production Editor: Yan-Xia Xing; Production Department Director: Yun-Xiaojuan Wu; Editorial Office Director: Jin-Lai Wang.

**NAME OF JOURNAL**

*World Journal of Clinical Cases*

**ISSN**

ISSN 2307-8960 (online)

**LAUNCH DATE**

April 16, 2013

**FREQUENCY**

Semimonthly

**EDITORS-IN-CHIEF**

Dennis A Bloomfield, Sandro Vento, Bao-Gan Peng

**EDITORIAL BOARD MEMBERS**

<https://www.wjgnet.com/2307-8960/editorialboard.htm>

**PUBLICATION DATE**

November 6, 2020

**COPYRIGHT**

© 2020 Baishideng Publishing Group Inc

**INSTRUCTIONS TO AUTHORS**

<https://www.wjgnet.com/bpg/gerinfo/204>

**GUIDELINES FOR ETHICS DOCUMENTS**

<https://www.wjgnet.com/bpg/GerInfo/287>

**GUIDELINES FOR NON-NATIVE SPEAKERS OF ENGLISH**

<https://www.wjgnet.com/bpg/gerinfo/240>

**PUBLICATION ETHICS**

<https://www.wjgnet.com/bpg/GerInfo/288>

**PUBLICATION MISCONDUCT**

<https://www.wjgnet.com/bpg/gerinfo/208>

**ARTICLE PROCESSING CHARGE**

<https://www.wjgnet.com/bpg/gerinfo/242>

**STEPS FOR SUBMITTING MANUSCRIPTS**

<https://www.wjgnet.com/bpg/GerInfo/239>

**ONLINE SUBMISSION**

<https://www.f6publishing.com>



## Donepezil-related inadequate neuromuscular blockade during laparoscopic surgery: A case report

Eun-A Jang, Tae-Young Kim, Eu-Gen Jung, Seongtae Jeong, Hong-Beom Bae, Seongheon Lee

**ORCID number:** Eun-A Jang 0000-0003-1465-7831; Tae-Young Kim 0000-0002-4546-5587; Eu-Gen Jung 0000-0003-1883-5746; Seongtae Jeong 0000-0002-6245-9779; Hong-Beom Bae 0000-0002-0358-6807; Seongheon Lee 0000-0002-2675-2521.

**Author contributions:** Jang EA and Lee S wrote the manuscript; Kim TY and Jung EG performed literature analysis; Jeong S was the anesthesiologist in charge of the patient; Bae HB revised the manuscript for important intellectual content; all authors approved the final version of the manuscript to be submitted.

### Informed consent statement:

Written informed consent was obtained from the patient for the publication of this case.

**Conflict-of-interest statement:** The authors have no funding and conflicts of interest to disclose.

### CARE Checklist (2016) statement:

The authors have read the CARE Checklist (2016), and the manuscript was prepared and revised according to the CARE Checklist (2016).

**Open-Access:** This article is an open-access article that was selected by an in-house editor and fully peer-reviewed by external reviewers. It is distributed in

Eun-A Jang, Tae-Young Kim, Eu-Gen Jung, Seongtae Jeong, Hong-Beom Bae, Seongheon Lee, Department of Anesthesiology and Pain Medicine, Chonnam National University Medical School, Chonnam National University Hospital, Gwangju 61469, South Korea

**Corresponding author:** Seongheon Lee, MD, PhD, Assistant Professor, Department of Anesthesiology and Pain Medicine, Chonnam National University Medical School, Chonnam National University Hospital, 160, Baekseo-ro, Dong-gu, Gwangju 61469, South Korea. [aneshead@gmail.com](mailto:aneshead@gmail.com)

## Abstract

### BACKGROUND

Donepezil is an acetylcholinesterase inhibitor used to improve cognition and delay disease progression in dementia patients by increasing acetylcholine levels. This drug may potentially interact with neuromuscular blocking agents (NMBAs) that act on muscular acetylcholine receptors during general anesthesia. Herein, we present a case of inadequate neuromuscular blockade with rocuronium, a nondepolarizing NMBA, in a dementia patient who had taken donepezil.

### CASE SUMMARY

A 71-year-old man was scheduled for laparoscopic gastrectomy. He had been taking donepezil 5 mg for dementia. General anesthesia was induced with propofol and remifentanyl. The depth of neuromuscular blockade was monitored by train-of-four (TOF) stimulation. After the administration of rocuronium, the TOF ratio decreased at an unusually slow rate, and a TOF count of 0 was detected 7 min later. After intubation, a TOF count of 1 was detected within 1 min, and a TOF ratio of 12% was detected within 2 min. The TOF count remained at 4 even with an additional bolus and continuous infusion of rocuronium, suggesting resistance to this NMBA. Instead of propofol, an inhalation anesthetic was administered alongside another NMBA (cisatracurium). Then, the quality of neuromuscular blockade improved, and the TOF count remained at 0-1 for the next 70 min. No further problems were encountered with respect to surgery or anesthesia.

### CONCLUSION

Donepezil may be responsible for inadequate neuromuscular blockade during anesthesia, especially when total intravenous anesthesia is used.

**Key Words:** Donepezil; Dementia; General anesthesia; Rocuronium; Neuromuscular

accordance with the Creative Commons Attribution NonCommercial (CC BY-NC 4.0) license, which permits others to distribute, remix, adapt, build upon this work non-commercially, and license their derivative works on different terms, provided the original work is properly cited and the use is non-commercial. See: <http://creativecommons.org/licenses/by-nc/4.0/>

**Manuscript source:** Unsolicited manuscript

**Specialty type:** Medicine, research and experimental

**Country/Territory of origin:** South Korea

**Peer-review report's scientific quality classification**

Grade A (Excellent): 0  
Grade B (Very good): B  
Grade C (Good): C  
Grade D (Fair): 0  
Grade E (Poor): 0

**Received:** May 12, 2020

**Peer-review started:** May 12, 2020

**First decision:** September 14, 2020

**Revised:** September 27, 2020

**Accepted:** October 12, 2020

**Article in press:** October 12, 2020

**Published online:** November 6, 2020

**P-Reviewer:** Higa K

**S-Editor:** Gao CC

**L-Editor:** A

**P-Editor:** Xing YX



blocking agents; Case report

©The Author(s) 2020. Published by Baishideng Publishing Group Inc. All rights reserved.

**Core Tip:** In the present case of a 71-year-old patient taking donepezil for dementia, we collected peripheral nerve stimulation data that showed objective evidence of inadequate neuromuscular blockade during total intravenous anesthesia. The goal of this case report is to draw attention to the need to carefully review potential drug interactions between donepezil and neuromuscular blocking agents during general anesthesia. As the number of elderly patients with dementia is increasing and total intravenous anesthesia has become more popular, there is a possibility that this drug interaction may be observed more frequently in the future.

**Citation:** Jang EA, Kim TY, Jung EG, Jeong S, Bae HB, Lee S. Donepezil-related inadequate neuromuscular blockade during laparoscopic surgery: A case report. *World J Clin Cases* 2020; 8(21): 5341-5346

**URL:** <https://www.wjgnet.com/2307-8960/full/v8/i21/5341.htm>

**DOI:** <https://dx.doi.org/10.12998/wjcc.v8.i21.5341>

## INTRODUCTION

As a result of an increasing life expectancy, it is likely that anesthesiologists will encounter an increasing number of elderly patients with dementia in the operating room. As most types of dementia are associated with profound cholinergic deficits, acetylcholinesterase inhibitors have been used to improve cognition and delay disease progression in dementia patients by increasing cerebral acetylcholine levels<sup>[1]</sup>. Due to this mechanism, these anti-dementia drugs may potentially interact with neuromuscular blocking agents (NMBAs), which act on muscular nicotinic acetylcholine receptors during general anesthesia. Donepezil is an acetylcholinesterase inhibitor approved by the United States Food and Drug Administration for the treatment of Alzheimer's disease. A few case reports have described donepezil-related resistance to nondepolarizing NMBAs, rocuronium and atracurium, through subjective observations of train-of-four (TOF) stimulation or respiratory effort<sup>[2-5]</sup>. Herein, we present a case of inadequate neuromuscular blockade with rocuronium during total intravenous anesthesia (TIVA) with propofol-remifentanyl in a dementia patient who had taken donepezil. Furthermore, we demonstrate the objective time course of TOF responses. In this case, adequate neuromuscular blockade was achieved with the subsequent administration of an inhalational anesthetic (desflurane) and another NMBA (cisatracurium). Written informed consent was obtained from the patient for the publication of this case.

## CASE PRESENTATION

### Chief complaints

A 71-year-old man (55 kg, 149 cm) was admitted to the hospital for total laparoscopic distal gastrectomy under general anesthesia. During surgery, insufficient muscle relaxation was reported repeatedly by surgical team.

### History of present illness

General anesthesia was induced and maintained with 2% propofol and remifentanyl using target-controlled infusion. When the patient became unconscious, TOF stimulation of the right ulnar nerve was initiated using a peripheral nerve stimulator (NMT module of the Carescape monitor B850; GE Healthcare, Madison, WI, United States). The initial TOF ratio was 0.98, and the patient then received a bolus injection of rocuronium 50 mg (0.9 mg/kg). According to routine practice, we waited to perform intubation until a TOF count of 0 was observed. The TOF ratio decreased at an unusually slow rate, and a TOF count of 0 was detected approximately 7 min after the



administration of rocuronium (**Figure 1**). After successful endotracheal intubation, however, a TOF count of 1 was detected within 1 min, and a TOF ratio of 12% was detected within 2 min. Rocuronium 5 mg was then injected followed by a continuous infusion at a rate of 9 µg/kg/min for deep neuromuscular blockade (post-tetanic count of 1-2). However, a TOF count of 4 (TOF ratio < 10%) was continuously recorded and visually detected. The surgical team noted insufficient muscle relaxation 20 min after the start of the laparoscopic procedure.

### **History of past illness**

The patient had previously been diagnosed with dementia and mild parkinsonism with tremor and had been taking donepezil 5 mg, quetiapine 25 mg, and pregabalin 75 mg twice a day for 16 mo. He had been taking anti-hypertensive medication for 11 years and had undergone diaphragm surgery in our hospital 7 and 10 years prior. During these two surgeries, he required rocuronium 50 mg during 195 min of balanced anesthesia with sevoflurane-remifentanyl and rocuronium 60 mg during 225 min of TIVA with propofol-remifentanyl. No specific events or comments regarding insufficient muscle relaxation were identified from a review of his anesthesia records of previous surgeries.

### **Personal and family history**

The patient had no history of smoking or alcohol abuse. He had no family history of cancer or any other hereditary diseases.

### **Physical examination**

During general anesthesia, vascular access for intravenous anesthetics and NMBAs was well secured, and the patient's vital signs and state entropy (Entropy module of the Carescape monitor B850; GE Healthcare, Madison, WI, United States) were within the normal ranges, which indicated adequate depth of anesthesia. Using forced-air warming blankets, the central core temperature and skin temperature over the adductor pollicis muscle were maintained above 35.5 °C and 32 °C, respectively. The preoperative physical examination was unremarkable.

### **Laboratory examinations**

The results of preoperative laboratory tests and electrocardiography were normal.

### **Imaging examinations**

The preoperative chest X-ray showed elevation of the left diaphragm, which was considered evidence of previous diaphragm surgeries.

---

## **FINAL DIAGNOSIS**

The etiology was considered donepezil-related resistance to nondepolarizing NMBAs based on donepezil's mechanism and previous case reports.

---

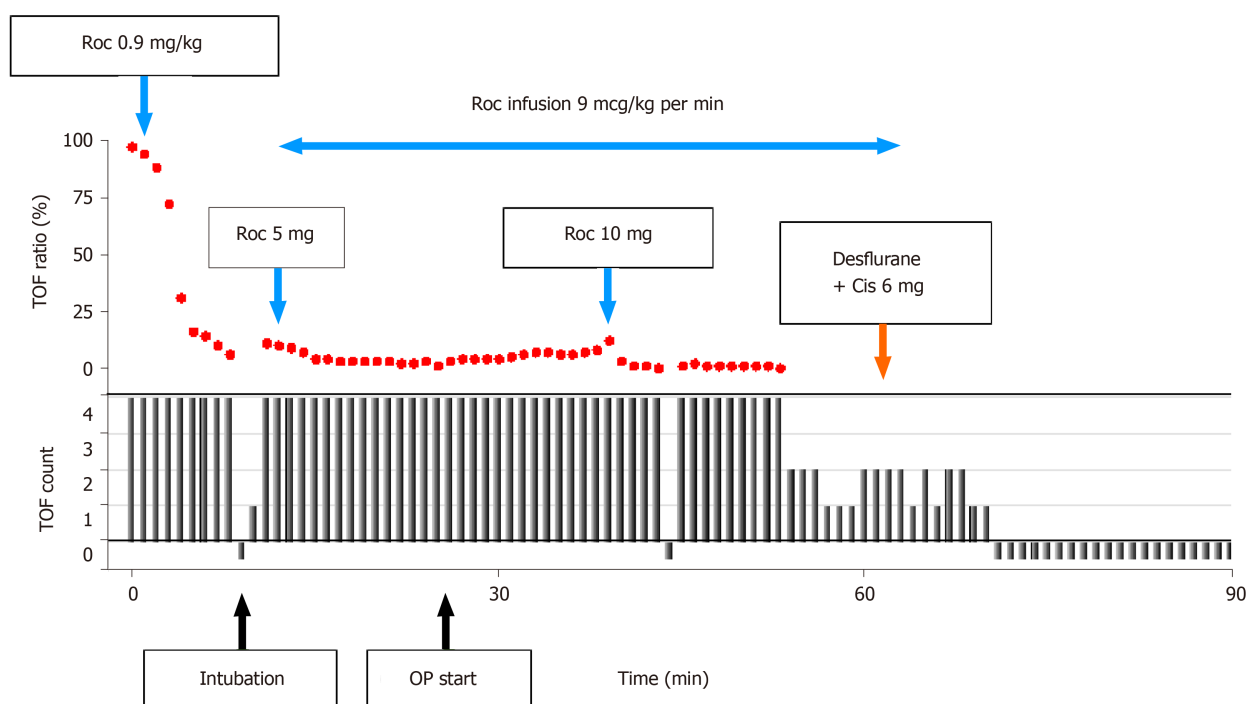
## **TREATMENT**

An additional bolus injection of rocuronium 10 mg (0.18 mg/kg) from different batches of drug product was administered, but the TOF count remained at 1-2 for the next 15 min, and the surgical team requested additional relaxation for optimal surgical conditions. We decided to use an inhalational anesthetic (desflurane) instead of propofol. Therefore, we administered desflurane at an end-tidal concentration of 4-6 vol% while stopping the infusion of propofol and rocuronium. We also administered a bolus dose of cisatracurium 6 mg (0.1 mg/kg) instead of rocuronium.

---

## **OUTCOME AND FOLLOW-UP**

Adequate neuromuscular blockade was achieved with the subsequent administration of desflurane and cisatracurium. The TOF count remained at 0-1 for the next 70 min without further complaints from the surgical team. At the end of surgery, the TOF ratio was 0.78, and spontaneous respiratory efforts returned soon after all anesthetic



**Figure 1** Progress of the train-of-four ratios and counts from the start of total intravenous anesthesia with propofol and remifentanyl. After a bolus injection of rocuronium 50 mg (0.9 mg/kg), the train-of-four (TOF) ratio decreased at an unusually slow rate. When a TOF count of 0 was detected approximately 7 min later, endotracheal intubation was performed. A TOF count of 1 was detected within 1 min, and a TOF ratio of 12% was detected within 2 min. A TOF count of 4 was continuously detected even with an additional bolus and continuous infusion of rocuronium. A TOF count of 0 was achieved after the conversion of total intravenous anesthesia to inhalation anesthesia with cisatracurium 6 mg. Solid black lines represent TOF count (0-4); red dots represent TOF ratio (%). Roc: Rocuronium; Cis: Cisatracurium; TOF: Train-of-four; OP: Operation.

drugs were stopped. Residual neuromuscular blockade was reversed with neostigmine 2.5 mg and glycopyrrolate 0.4 mg. When the TOF ratio increased to 0.91 and consciousness returned, extubation was performed successfully. There were no significant problems with the patient's vital signs in the operating room or recovery room. The patient was transferred to the ward 1 h after the end of surgery. He was discharged from the hospital after 9 d without any complications.

## DISCUSSION

Surgical patients sometimes exhibit resistance to nondepolarizing NMBA during anesthesia. This manifests as an increased NMBA dose required to abolish the twitch response, a prolonged time to maximum effect, and a shortened duration of neuromuscular blockade after the administration of a bolus<sup>[6]</sup>, as seen in this case.

Resistance to NMBA has been reported in patients with burns<sup>[7,8]</sup> and cerebral palsy<sup>[9]</sup>, immobilized patients<sup>[10]</sup>, and patients taking anticonvulsants<sup>[11,12]</sup>. However, all of these conditions were excluded in this patient. Moreover, no specific problems were described in his anesthesia records from two diaphragm surgeries performed 7 and 10 years prior. During these two surgeries, he required rocuronium 50 mg during 195 min and rocuronium 60 mg during 225 min. In the present case, however, the dose of rocuronium administered during the first 60 min of anesthesia (83 mg) was higher than that administered during two previous surgeries. Therefore, individual variability in NMBA sensitivity may not explain the inadequate neuromuscular blockade observed in this case.

We suspected the existence of a drug-drug interaction between the NMBA and the patient's current medications. Donepezil was considered to be the drug most likely to be responsible for the observed inadequate neuromuscular blockade, as it is an acetylcholinesterase inhibitor and thus theoretically antagonizes the effects of nondepolarizing NMBA. We also identified four case reports (two in English) of donepezil-related resistance to nondepolarizing NMBA. Baruah *et al*<sup>[2]</sup> reported that four twitches were continuously observed in response to TOF stimulation after the administration of a single intubating dose of atracurium 30 mg and a supplemental

dose of 10 mg in an Alzheimer's disease patient who had been taking donepezil for 14 mo. Bhardwaj *et al.*<sup>[3]</sup> reported the case of an Alzheimer's disease patient who had been taking donepezil (5 mg daily) for 4 mo. Spontaneous respiratory efforts reappeared while attempting intubation after the administration of a single intubation dose of rocuronium 0.6 mg/kg, and repeated administrations of rocuronium and vecuronium could not inhibit the return of spontaneous respiratory efforts. Inadequate neuromuscular blockade with atracurium or rocuronium in Alzheimer's disease patients taking donepezil (10 mg daily) was also described in the abstracts of two non-English articles<sup>[4,5]</sup>. In addition, donepezil is known to produce prolonged neuromuscular blockade with depolarizing NMBAs such as succinylcholine<sup>[5,13]</sup>.

Donepezil is a new generation of acetylcholinesterase inhibitors that are considered the first-choice drugs for the pharmacological treatment of dementia, usually of the Alzheimer type<sup>[14]</sup>. This therapy targets elevated acetylcholine levels in the brain. However, acetylcholine levels at the neuromuscular junction may also increase, resulting in potential interactions between donepezil and NMBAs. The manufacturer of this drug and a few previous articles have recommended that donepezil should be discontinued 2-4 wk before elective surgery due to its long half-life (70 h in healthy volunteers and even longer in elderly patients)<sup>[2,13,15]</sup>. However, this long withdrawal period may cause irreversible cognitive decline such that cognitive function becomes even worse than that before treatment was initiated<sup>[16]</sup>. To date, there are no clear guidelines on whether this drug should be discontinued before elective surgery.

In this case, inadequate neuromuscular blockade was noted even at doses higher than those indicated for the patient's weight. The quality of neuromuscular blockade improved when desflurane inhalation was initiated and a single bolus of cisatracurium was administered. Inhalation anesthetics such as desflurane and sevoflurane cause a slight reduction in neuromuscular transmission and enhance the neuromuscular blocking effects of nondepolarizing NMBAs<sup>[17,18]</sup>. Therefore, the improved muscle relaxation might be associated with the use of desflurane.

Meanwhile, we could not exclude the possibility that cisatracurium might also have contributed to the observed improvement of neuromuscular blockade. Although cisatracurium is a commonly used, intermediate duration, nondepolarizing NMBA just like as rocuronium, the chemical structures of cisatracurium and rocuronium are quite different (benzylisoquinolinium *vs* steroidal). Mixtures of structurally different NMBAs are considered to produce a synergistic response<sup>[19,20]</sup>. Thus, the additional administration of cisatracurium might have enhanced the quality of neuromuscular blockade synergistically. In addition, further studies are required to investigate whether cisatracurium has a relatively weak interaction with donepezil.

## CONCLUSION

As the number of elderly patients with dementia is increasing, it is essential that anesthesiologists carefully review the current medications of these patients prior to surgery. In situations when an acetylcholinesterase inhibitor is not discontinued sufficiently long before surgery, the use of a peripheral nerve stimulator and inhalation anesthetics may help achieve adequate neuromuscular blockade for surgery and avoid residual neuromuscular blockade after surgery.

## REFERENCES

- 1 Noufi P, Khoury R, Jeyakumar S, Grossberg GT. Use of Cholinesterase Inhibitors in Non-Alzheimer's Dementias. *Drugs Aging* 2019; **36**: 719-731 [PMID: 31201687 DOI: 10.1007/s40266-019-00685-6]
- 2 Baruah J, Easby J, Kessell G. Effects of acetylcholinesterase inhibitor therapy for Alzheimer's disease on neuromuscular block. *Br J Anaesth* 2008; **100**: 420 [PMID: 18276655 DOI: 10.1093/bja/aen010]
- 3 Bhardwaj A, Dharmavaram S, Wadhawan S, Sethi A, Bhadoria P. Donepezil: A cause of inadequate muscle relaxation and delayed neuromuscular recovery. *J Anaesthesiol Clin Pharmacol* 2011; **27**: 247-248 [PMID: 21772691 DOI: 10.4103/0970-9185.81833]
- 4 Pautola L, Reinikainen M. [Interaction of donepezil with rocuronium]. *Duodecim* 2012; **128**: 1031-1032 [PMID: 22724318]
- 5 Sánchez Morillo J, Demartini Ferrari A, Roca de Togores López A. [Interaction of donepezil and muscular blockers in Alzheimer's disease]. *Rev Esp Anestesiol Reanim* 2003; **50**: 97-100 [PMID: 12712872]
- 6 Jung KT, An TH. Updated review of resistance to neuromuscular blocking agents. *Anesth Pain Med* 2018; **13**: 122-127 [DOI: 10.17085/apm.2018.13.2.122]
- 7 Martyn JA, Goudsouzian NG, Chang Y, Szyfelbein SK, Schwartz AE, Patel SS. Neuromuscular effects of mivacurium in 2- to 12-yr-old children with burn injury. *Anesthesiology* 2000; **92**: 31-37 [PMID: 10638896]

- DOI: [10.1097/00000542-200001000-00011](https://doi.org/10.1097/00000542-200001000-00011)]
- 8 **Han T**, Kim H, Bae J, Kim K, Martyn JA. Neuromuscular pharmacodynamics of rocuronium in patients with major burns. *Anesth Analg* 2004; **99**: 386-392, table of contents [PMID: [15271712](https://pubmed.ncbi.nlm.nih.gov/15271712/) DOI: [10.1213/01.ANE.0000129992.07527.4B](https://doi.org/10.1213/01.ANE.0000129992.07527.4B)]
  - 9 **Moorthy SS**, Krishna G, Dierdorf SF. Resistance to vecuronium in patients with cerebral palsy. *Anesth Analg* 1991; **73**: 275-277 [PMID: [1678256](https://pubmed.ncbi.nlm.nih.gov/1678256/) DOI: [10.1213/00000539-199109000-00008](https://doi.org/10.1213/00000539-199109000-00008)]
  - 10 **Hepağuşlar H**, Uyar M, Uğur G, Balcioglu T. Resistance to vecuronium after immobilization. *Paediatr Anaesth* 1999; **9**: 94-95 [PMID: [10712725](https://pubmed.ncbi.nlm.nih.gov/10712725/) DOI: [10.1046/j.1460-9592.1999.00341.x](https://doi.org/10.1046/j.1460-9592.1999.00341.x)]
  - 11 **Soriano SG**, Sullivan LJ, Venkatakrishnan K, Greenblatt DJ, Martyn JA. Pharmacokinetics and pharmacodynamics of vecuronium in children receiving phenytoin or carbamazepine for chronic anticonvulsant therapy. *Br J Anaesth* 2001; **86**: 223-229 [PMID: [11573664](https://pubmed.ncbi.nlm.nih.gov/11573664/) DOI: [10.1093/bja/86.2.223](https://doi.org/10.1093/bja/86.2.223)]
  - 12 **Gray HS**, Slater RM, Pollard BJ. The effect of acutely administered phenytoin on vecuronium-induced neuromuscular blockade. *Anaesthesia* 1989; **44**: 379-381 [PMID: [2568098](https://pubmed.ncbi.nlm.nih.gov/2568098/) DOI: [10.1111/j.1365-2044.1989.tb11331.x](https://doi.org/10.1111/j.1365-2044.1989.tb11331.x)]
  - 13 **Crowe S**, Collins L. Suxamethonium and donepezil: a cause of prolonged paralysis. *Anesthesiology* 2003; **98**: 574-575 [PMID: [12552219](https://pubmed.ncbi.nlm.nih.gov/12552219/) DOI: [10.1097/00000542-200302000-00040](https://doi.org/10.1097/00000542-200302000-00040)]
  - 14 **Birks JS**, Harvey RJ. Donepezil for dementia due to Alzheimer's disease. *Cochrane Database Syst Rev* 2018; **6**: CD001190 [PMID: [29923184](https://pubmed.ncbi.nlm.nih.gov/29923184/) DOI: [10.1002/14651858.CD001190.pub3](https://doi.org/10.1002/14651858.CD001190.pub3)]
  - 15 **Dooley M**, Lamb HM. Donepezil: a review of its use in Alzheimer's disease. *Drugs Aging* 2000; **16**: 199-226 [PMID: [10803860](https://pubmed.ncbi.nlm.nih.gov/10803860/) DOI: [10.2165/00002512-200016030-00005](https://doi.org/10.2165/00002512-200016030-00005)]
  - 16 **Alcorn S**, Foo I. Perioperative management of patients with dementia. *BJA Education* 2016; **17**: 94-98 [DOI: [10.1093/bjaed/mkw038](https://doi.org/10.1093/bjaed/mkw038)]
  - 17 **Kelly RE**, Lien CA, Savarese JJ, Belmont MR, Hartman GS, Russo JR, Hollmann C. Depression of neuromuscular function in a patient during desflurane anesthesia. *Anesth Analg* 1993; **76**: 868-871 [PMID: [8466031](https://pubmed.ncbi.nlm.nih.gov/8466031/) DOI: [10.1213/00000539-199304000-00031](https://doi.org/10.1213/00000539-199304000-00031)]
  - 18 **Rupp SM**, Miller RD, Gencarelli PJ. Vecuronium-induced neuromuscular blockade during enflurane, isoflurane, and halothane anesthesia in humans. *Anesthesiology* 1984; **60**: 102-105 [PMID: [6141748](https://pubmed.ncbi.nlm.nih.gov/6141748/) DOI: [10.1097/00000542-198402000-00004](https://doi.org/10.1097/00000542-198402000-00004)]
  - 19 **Naguib M**, Samarkandi AH, Ammar A, Elfaqih SR, Al-Zahrani S, Turkistani A. Comparative clinical pharmacology of rocuronium, cisatracurium, and their combination. *Anesthesiology* 1998; **89**: 1116-1124 [PMID: [9821999](https://pubmed.ncbi.nlm.nih.gov/9821999/) DOI: [10.1097/00000542-199811000-00011](https://doi.org/10.1097/00000542-199811000-00011)]
  - 20 **Paul M**, Kindler CH, Fokt RM, Dipp NC, Yost CS. Isobolographic analysis of non-depolarising muscle relaxant interactions at their receptor site. *Eur J Pharmacol* 2002; **438**: 35-43 [PMID: [11906708](https://pubmed.ncbi.nlm.nih.gov/11906708/) DOI: [10.1016/s0014-2999\(02\)01271-2](https://doi.org/10.1016/s0014-2999(02)01271-2)]



Published by **Baishideng Publishing Group Inc**  
7041 Koll Center Parkway, Suite 160, Pleasanton, CA 94566, USA

**Telephone:** +1-925-3991568

**E-mail:** [bpgoffice@wjgnet.com](mailto:bpgoffice@wjgnet.com)

**Help Desk:** <https://www.f6publishing.com/helpdesk>

<https://www.wjgnet.com>

