



Name of Journal: *World Journal of Clinical Cases*

Manuscript NO: 56908

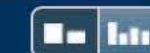
Manuscript Type: CASE REPORT

Gastric plexiform fibromyxoma: A case report

Pei JY *et al.* Gastric plexiform fibromyxoma

Jin-Yu Pei, Bin Tan, Peng Liu, Guang-Hua Cao, Zu-Sen Wang, Lin-lin Qu

Match Overview



1 **Crossref** 14 words
Laura L. Gonzalez, Karin Garrie, Mark D. Turner. "Role of S ...
0 proteins in health and disease", *Biochimica et Biophysica* 1%

2 **Internet** 13 words
crawled on 25-Jul-2020
www.lib.kobe-u.ac.jp 1%



国内版

国际版

Chat with Bing

Gastric Plexiform Fibromyxoma: A case report



Sign in



ALL

IMAGES

VIDEOS

33,700 Results

Any time ▾

Imaging findings of gastric plexiform fibromyxoma with a ...

<https://www.ncbi.nlm.nih.gov/pmc/articles/PMC6392900>

Plexiform fibromyxoma (PF) is an extremely rare mesenchymal tumor of the stomach, and its radiological findings have not been well described. Here, we analyzed the imaging features of a **case** of **PF**. To our knowledge, this is a rare **reported case** with ...

Cited by: 2

Author: Min-Xia Yang, Zhen-Hua Zhao, Jian-Feng...

Publish Year: 2017

Plexiform Fibromyxoma: A Rare Gastric Tumor

<https://www.hindawi.com/journals/crigm/2017/4014565> ▾

Plexiform fibromyxoma is a rare and distinctive benign mesenchymal neoplasm that occurs in the **gastric antrum**. This **tumor** has a potential for misdiagnosis as gastrointestinal stromal tumor (GIST). It causes mucosa and vascular ulcerations without advancement of the tumor.

Cited by: 2

Author: Casmir Wambura, Salim Surani

Publish Year: 2017

Gastric plexiform fibromyxoma tumor in a child – Case ...

<https://www.sciencedirect.com/science/article/pii/S2213576615300427>

Related searches

plexiform fibromyxoma **pathology outlines**

plexiform **fibrohistiocytic tumor**

plexiform **tumor**

plexiform **neurofibroma pathology**

plexiform **neurofibroma**

plexiform **schwannoma pathology**

plexiform **schwannoma**

plexiform **neurofibroma radiology**

Search Tools

Turn off Hover Translation (关闭取词)

Gastric plexiform fibromyxoma: A case report



ALL

IMAGES

VIDEOS

33,300 Results

Any time ▾

This is the first report to describe a case of gastric plexiform fibromyxoma, a rare gastric submucosal tumor, that was successfully resected by laparoscopic endoscopic cooperative surgery. A **36-year-old Japanese woman presented with epigastric pain and anemia.**

Author: Yoshikage Inoue, Shutaro Gunji, Kazutaka Obama, Hiroshi Okabe, Yoshiharu Sakai

Cited by: 1

Publish Year: 2016

[Laparoscopy endoscopy cooperative surgery for gastric ...](#)

 surgicalcasereports.springeropen.com/articles/10.1186/s40792-016-0249-z

Was this helpful?



[PDF] [Case Report Plexiform fibromyxoma of the stomach: a case ...](#)

www.ijcem.com/files/ijcem0065629.pdf

Most commonly the presenting symptoms include abdominal discomfort and pain, **anemia, and upper gastrointestinal bleeding.** Other symptoms are also reported, such as weight loss, ulcer, nausea, chest pain, melena, and even hematemesis. PF has occurred in the antrum of the stomach in 88.6% (39/44) of reported cases.

[Laparoscopy endoscopy cooperative surgery for gastric ...](#)

<https://www.ncbi.nlm.nih.gov/pmc/articles/PMC5085966>

Laparoscopic endoscopic cooperative surgery has been developed to overcome these problems.

This is the first report to describe a case of gastric plexiform fibromyxoma, a rare gastric submucosal tumor, that was successfully resected by ...

Cited by: 1

Author: Yoshikage Inoue, Shutaro Gunji, Kazuta...

Publish Year: 2016

[Imaging findings of gastric plexiform fibromyxoma with a](#)



33,300 Results Any time ▾

This is the first report to describe a case of gastric plexiform fibromyxoma, a rare gastric submucosal tumor, that was successfully resected by laparoscopic endoscopic cooperative surgery. A **36-year-old Japanese woman presented with epigastric pain and anemia.**

Author: Yoshikage Inoue, Shutaro Gunji, Kazutaka Obama, Hiroshi Okabe, Yoshiharu Sakai

Cited by: 1

Publish Year: 2016

Laparoscopy endoscopy cooperative surgery for gastric ...
[surgicalcasereports.springeropen.com/articles/10.1186/s40792-016-0249-z](https://www.surgicalcasereports.springeropen.com/articles/10.1186/s40792-016-0249-z)

Was this helpful?

Laparoscopy endoscopy cooperative surgery for gastric ...
<https://www.ncbi.nlm.nih.gov/pmc/articles/PMC5085966>

This is the first report to describe a case of gastric plexiform fibromyxoma, a rare gastric submucosal tumor, that was successfully resected by laparoscopic endoscopic cooperative surgery. Case presentation. A **36-year-old Japanese woman presented with epigastric pain and anemia.**

Cited by: 1

Author: Yoshikage Inoue, Shutaro Gunji, Kazutak...

Publish Year: 2016

[PDF] Case Report Plexiform fibromyxoma of the stomach: a case ...
www.ijcem.com/files/ijcem0065629.pdf

Gastric plexiform fibromyxoma (PF) is a **rare type of mesenchymal tumor with a peculiar plexiform growth pattern, myxoid stroma, and spindle-shaped myofibroblastic cells** [1]. The name of this entity has been controversial since Takahashi et al. first reported this unique gastric mesenchymal tumor as "plexiform angi -

Plexiform Fibromyxoma: A Rare Gastric Tumor
<https://www.hindawi.com/journals/crigm/2017/4014565> ▾

Related searches

plexiform fibromyxoma **pathology outlines**

digital fibromyxoma

superficial acral fibromyxoma **pathology**

plexiform **tumor**

plexiform **neurofibroma pathology**

plexiform **schwannoma pathology**

plexiform **neurofibroma radiology**

plexiform **neurofibroma pathology outlines**