

A large lingual heterotopic gastrointestinal cyst in a newborn: A case report

Newborn tongue heterotopic gastrointestinal cyst

Abstract

BACKGROUND

Heterotopic gastrointestinal cysts have gastrointestinal epithelium in the cyst wall and rarely occur in the oral cavity. Most are found in the neonatal period. However, heterotopic gastrointestinal cysts that are diagnosed as a congenital tongue cyst by routine ultrasonography are extremely rare.

CASE SUMMARY

A 12-day-old female presented with swelling of the anterior tongue. The obstetrician had detected significant tongue swelling on fetal ultrasonography in the 35th gestational week. The female was born by cesarean delivery at gestational week 39. She soon became dyspneic, and the cyst was aspirated. After the aspiration, her breathing recovered and she started breastfeeding. The cyst was excised under general anesthesia on the 67th day. Histopathologic examination showed that that cyst wall consisted of a lining of columnar gastrointestinal-type epithelium and pseudostratified ciliated epithelium. The patient restarted breastfeeding 3 hours after surgery. The postoperative course was uneventful.

CONCLUSION

Airway distress and feeding difficulty were successfully avoided by cyst aspiration, and

Match Overview

- | | | |
|---|---|----|
| 1 | Crossref 31 words
Takahiro Kaneko, Norio Horie, Tetsuo Shimoyama. "Congenital Mucocoele in the Tongue: Report of a Case", Journal of Oral | 2% |
| 2 | Crossref 20 words
Nasser Said-Al-Naief, John E. Fantasia, James J. Sciubba, Salvatore Ruggiero, Stephen Sachs. "Heterotopic oral gastroint | 1% |
| 3 | Crossref 16 words
Carlos-Bregni, R.. "Lingual cyst with gastric epithelium: A clinicopathological and immunohistochemical analysis", Internatio | 1% |
| 4 | Crossref 12 words
Gantwerker, Eric A., Amy Lawrason Hughes, V. Michelle Silveira, Sara O. Vargas, and Reza Rahbar. "Management of a Lar | 1% |



ALL

IMAGES

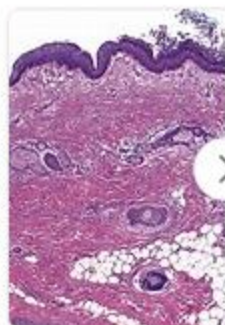
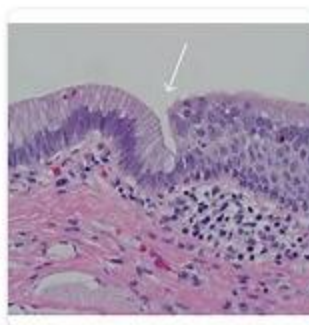
VIDEOS

809,000 Results

Any time ▾

Images of a Large lingual Heterotopic Gastrointestinal ...

[bing.com/images](https://www.bing.com/images)

[See all images >](#)

Lingual Gastric Duplication Cyst in a New Born

<https://www.ncbi.nlm.nih.gov/pmc/articles/PMC3227841>

Case Details. A term baby boy was admitted with a large sublingual cyst. Child was able to breathe well but was unable to suck well. Antenatal maternal USG detected **intraoral cyst**. Examination revealed a cyst 4 × 6 × 4 cm (Fig. 1) stretching the tongue to that extent that it was barely visible. The tongue was pushed dorsally and was stretched side wards.

Cited by: 2

Author: E. Vimalakar Reddy, G. Ram Mohan, G. ...

Publish Year: 2011

Heterotopic Intestinal Cyst of the Submandibular Gland: A ...

<https://www.ncbi.nlm.nih.gov/pmc/articles/PMC3701825>

Heterotopic gastrointestinal cysts are rarely found in the oral cavity. Most of these cysts are lined with gastric mucosa and involve the tongue. There have been no reported **heterotopic intestinal cysts** of the **submandibular gland** that are completely lined with colonic mucosa.

Author: Mi Jung Kwon, Dong Hoon Kim, Hye-...

Publish Year: 2013

Foregut duplication cyst presenting as lingual swelling ...

<https://www.ncbi.nlm.nih.gov/pmc/articles/PMC3304225>



国内版

国际版

A large lingual heterotopic gastrointestinal cyst in a newborn: A cas



Sign in



ALL

IMAGES

VIDEOS

839,000 Results

Any time ▼

Lingual Gastric Duplication Cyst in a New Born

<https://www.ncbi.nlm.nih.gov/pmc/articles/PMC3227841>

Case Details. A term **baby boy** was admitted with a large sublingual cyst. Child was able to breathe well but was unable to suck well. Antenatal maternal USG detected intraoral cyst. Examination revealed a cyst $4 \times 6 \times 4$ cm 3 (Fig. 1) stretching the tongue to that extent that it was barely visible. The tongue was pushed dorsally and was stretched side wards.

Cited by: 2

Author: E. Vimalakar Reddy, G. Ram Mohan, G. Rag...

Publish Year: 2011

Search Tools

Turn off Hover Translation (关闭取词)

(PDF) Congenital Heterotopic Gastrointestinal Cyst of the ...

https://www.researchgate.net/publication/261949441_Congenital_Heterotopic...

It is a rare cyst in the oral cavity containing gastric or intestinal mucosa. We report a case of **heterotopic gastrointestinal cyst of the tongue in a Nigerian male neonate** who presented with a...

[Heterotopic Gastric Cyst of the Tongue in a Newborn](#)

[Heterotopic Gastrointestinal Cyst of the Tongue: Case Report](#)

[See more results](#)

Foregut duplication cyst presenting as lingual swelling ...

<https://www.ncbi.nlm.nih.gov/pmc/articles/PMC3304225>

A cystic mass in the anterior two-thirds of the tongue in a newborn can represent **ranula**, **lymphangima**, haemangioma, and **dermoid cyst**. [4,10,11] Since first reported by Duncan and Daniel in 1942, cysts lined with gastric and/or intestinal mucosa have rarely been seen in the tongue or the floor of the mouth.

Cited by: 9

Author: Sandeep Hambarde, Pradnya Bendre, Deve...



ALL

IMAGES

VIDEOS

MAPS

NEWS

SHOPPING

813,000 Results

Any time ▼

[Lingual Gastric Duplication Cyst in a New Born](#)

<https://www.ncbi.nlm.nih.gov/pmc/articles/PMC3227841>

Macroglossia, lymphangioma & hemangiomas of tongue and **lymphatic cyst** of floor of mouth, tumours arising from hard & soft palate, teratodermoids are anecdotal cases of tumours of the mouth presenting in the new born [1–5]. GI duplications of **tongue** are a rare entity. A rare case of lingual gastric duplication cyst is being reported.

Cited by: 2

Author: E. Vimalakar Reddy, G. Ram Mohan, G. ...

Publish Year: 2011

[\(PDF\) Lingual Gastric Duplication Cyst in a New Born](#)

<https://www.researchgate.net/publication/231614574...>

Enteric duplication describes heterotopy of the gastrointestinal mucosa, which is a rare congenital malformation that may vary greatly in presentation, size, location, and symptoms. Duplication...

[Heterotopic Gastric Cyst of the Tongue in a Newborn](#)

<https://www.researchgate.net/publication/14875216...>

Gastrointestinal heterotopia in the tongue is a rare condition. A male newborn was noted to have **a cystic swelling in the anterior part of the dorsum of the tongue**. This was surgically excised....

[Heterotopic Gastrointestinal Cyst of the Tongue: Case Report](#)

[\(PDF\) Congenital Heterotopic Gastrointestinal Cyst of the ...](#)

[See more results](#)

[Congenital heterotopic gastrointestinal cyst of the oral ...](#)

<https://www.sciencedirect.com/science/article/pii/0165587696013316>

Jun 01, 1996 · Heterotopic gastrointestinal cysts of the oral cavity are rare **benign lesions** which may mimic both benign and malignant neoplasms. These cysts are usually discovered during infancy, but may not appear until well into adulthood. This lesion involves the tongue and floor of the mouth in 97% of cases and has a male predilection.

Cited by: 32

Author: Warren E. Morgan, John K. Jones, Cathe...

Publish Year: 1996