

**2**  
**Name of Journal:** *World Journal of Clinical Cases*

**Manuscript NO:** 57038

**Manuscript Type:** CASE REPORT

**Three localized primary gastric amyloidosis: Three case reports**

Liu XM *et al.* Localized primary gastric amyloidosis

Xue-Mei Liu, Lian-Jun Di, Jia-Xing Zhu, Xing-Long Wu, Hong-Ping Li, Hui-Chao Wu, Bi-Guang Tuo

**1**  
**Abstract**

**BACKGROUND**

Localized primary gastric amyloidosis is a rare disorder characterized by the extracellular deposition of insoluble fibrillary protein in the stomach and can mimic various diseases on endoscopic examination, including gastrointestinal stromal tumors, gastric cancer and

## Match Overview

1	<b>Internet</b> 2007 words crawled on 30-Jul-2020 <a href="http://www.researchsquare.com">www.researchsquare.com</a>	73%
2	<b>Internet</b> 62 words crawled on 01-Aug-2020 <a href="http://f6publishing.blob.core.windows.net">f6publishing.blob.core.windows.net</a>	2%
3	<b>Internet</b> 49 words crawled on 01-Jul-2020 <a href="http://www.wjgnet.com">www.wjgnet.com</a>	2%

Different outcomes of one disease: three localized primary gastr



Q ALL

IMAGES

VIDEOS

169,000 Results

Any time ▾

## A case report of localized gastric amyloidosis

<https://www.ncbi.nlm.nih.gov/pmc/articles/PMC4656558>

Nov 15, 2003 · CONCLUSION: Localized gastric amyloidosis, being rare in incidence, should be considered in the differentiation of **gastric tumors**, in which **biopsy** is the only means to confirm the diagnosis. Currently, **surgical resection** of **pathological tissue** and **circumambient lymph nodes** may be a preferable therapeutic strategy for the localized amyloidosis to prevent possible ...

Cited by: 31

Author: Dan Wu, Jian-Ying Lou, Jian Chen, Lun ...

Publish Year: 2003

## Primary localized cutaneous amyloidosis - Genetics Home ...

<https://ghr.nlm.nih.gov/condition/primary-localized-cutaneous-amyloidosis> ▾

Mar 31, 2020 · **Primary localized** cutaneous **amyloidosis** (PLCA) is a condition in which clumps of abnormal proteins called amyloids build up in the skin, specifically in the wave-like projections (dermal papillae) between the top two layers of skin (the dermis and the epidermis). The **primary** feature of PLCA is patches of skin with abnormal texture or color. The appearance of these patches defines **three** ...

## Amyloidosis of the gastrointestinal tract: a 13-year ...

<https://www.ncbi.nlm.nih.gov/pmc/articles/PMC3533676>

AL amyloidosis was the most common cause of **GI amyloid involvement**, occurring in 50 patients as **systemic disease** and in 11 patients with localized disease. Thus, overall, among 76 patients with **biopsy-proven GI amyloidosis**, 61 (80%) cases were due to light chain deposition.

Cited by: 87

Author: Andrew J. Cowan, Martha Skinner, Davi...

Publish Year: 2013

### PEOPLE ALSO ASK

What is primary localized cutaneous amyloidosis?





Three localized primary gastric amyloidosis: Three case reports



ALL

IMAGES

VIDEOS

334,000 Results

Any time ▼

## Different Outcomes of Three Localized Primary Gastric ...

<https://www.researchgate.net/publication/342142614...>

**Case presentation:** Here, we **report** a series of **3 cases** of **localized gastric amyloidosis** mimicking **gastric mucosa-associated lymphoid tissue (MALT) lymphoma** by endoscopic examination that were...

## A case report of localized gastric amyloidosis

<https://www.ncbi.nlm.nih.gov/pmc/articles/PMC4656558>

Nov 15, 2003 · As for **localized gastric amyloidosis**, a variety of common **gastrointestinal symptoms** such as epigastric discomfort, poor appetite, hematemesis, hematochezia and **gastric perforation** might occur in the process of this disease because of involvement of **local autonomic nervous system** and **gastric wall structure damage**.

**Cited by:** 31

**Author:** Dan Wu, Jian-Ying Lou, Jian Chen, Lun Fei, ...

**Publish Year:** 2003

## Localized amyloidosis of the stomach: A case report

<https://www.ncbi.nlm.nih.gov/pmc/articles/PMC4149972>

Mar 28, 2007 · The clinical manifestations of **gastric amyloidosis** are often uncharacteristic and subclinical. **CASE REPORT** A 55-year old Caucasian male was referred to our open-access Digestive





Three localized primary gastric amyloidosis: Three case reports



ALL IMAGES VIDEOS MAPS NEWS SHOPPING

634,000 Results Any time ▾

### [Different Outcomes of Three Localized Primary Gastric ...](https://www.researchgate.net/publication/342142614...)

<https://www.researchgate.net/publication/342142614...>

**Case presentation:** Here, we **report** a series of **3 cases** of **localized gastric amyloidosis** mimicking **gastric mucosa-associated lymphoid tissue (MALT) lymphoma** by endoscopic examination that were...

### [A case report of localized gastric amyloidosis](https://www.ncbi.nlm.nih.gov/pmc/articles/PMC4656558)

<https://www.ncbi.nlm.nih.gov/pmc/articles/PMC4656558>

Nov 15, 2003 - As for **localized gastric amyloidosis**, a variety of common **gastrointestinal symptoms** such as epigastric discomfort, poor appetite, hematemesis, hematochezia and **gastric perforation** might occur in the process of this disease because of involvement of **local autonomic nervous system** and **gastric wall structure damage**.

**Cited by:** 31 **Author:** Dan Wu, Jian-Ying Lou, Jian Chen, Lun F...

**Publish Year:** 2003

### [Localized amyloidosis of the stomach: A case report](https://www.ncbi.nlm.nih.gov/pmc/articles/PMC4149972)

<https://www.ncbi.nlm.nih.gov/pmc/articles/PMC4149972>

Mar 28, 2007 - The clinical manifestations of **gastric amyloidosis** are often uncharacteristic and subclinical. **CASE REPORT** A 55-year old Caucasian male was referred to our open-access Digestive Endoscopy Unit by his family physician due to epigastric pain, heartburn and mild weight loss (< 3 kg).

**Cited by:** 11 **Author:** Gianluca Rotondano, Raffaele Salerno, F...

**Publish Year:** 2007

### [Localized amyloidosis of the stomach: A case report ...](https://www.researchgate.net/publication/6365338...)

<https://www.researchgate.net/publication/6365338...>

In **primary amyloidosis** (light chain **amyloidosis**), **localized gastric** involvement is a rare finding which can mimic malignancy. We **report** the **case** of a 56-year-old man, admitted with upper digestive ...

### [\[PDF\] CASE REPORT Open Access Localized gastric amyloidosis ...](https://jmedicalcasereports.biomedcentral.com/track/pdf/10.1186/1752-1947-6-231)

<https://jmedicalcasereports.biomedcentral.com/track/pdf/10.1186/1752-1947-6-231>

**Conclusions:** We **report** an unusual **case** of **primary amyloidosis** of the stomach resembling scirrhous **gastric carcinoma**. This **case** of **localized gastric amyloidosis** was differentiated from scirrhous **gastric** ...

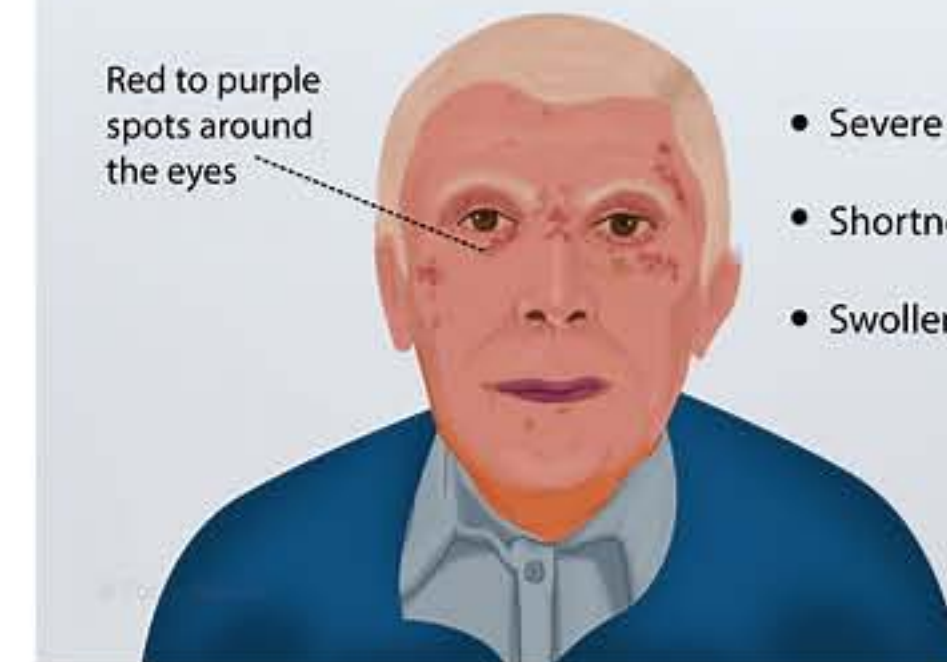
<https://global.bing.com/?FORM=Z9ED1> performing endoscopic mucosal resection without an invasive surgical resection, as

## Amyloidosis

Medical Condition

### Excess protein deposition

Red to purple spots around the eyes



- Severe fatigue
- Shortness of breath
- Swollen ankles and legs

A condition in which amyloid proteins build up on organs like heart, kidney and liver.

- 🏠 Very rare (Fewer than 20,000 cases per year in US)
- 🧪 Requires lab test or imaging
- 💊 Treatments can help manage condition, no known cure
- 🕒 Can be lifelong

An abnormal protein named amyloid, is produced in the bone marrow. It can get deposited on various organs like heart, kidney, liver, spleen, digestive tract, and nervous system. Specific causes depend on the type of amyloidosis. It has few symptoms at an early stage and more symptoms can be seen at an advanced stage. It cannot be cured but can be controlled with the help of medical treatment.

## Symptoms