

Name of Journal: *World Journal of Clinical Cases*

Manuscript NO: 57040

Manuscript Type: CASE REPORT

Incomplete Kawasaki disease complicated with acute abdomen: A case report

Revascularization of patients with KD

Wang Tao, Chuan Wang, Kai-Yu Zhou, Xiao-Qin Wang, Na Hu, Yi-Min Hua

Abstract

BACKGROUND

Kawasaki disease (KD) is an acute systemic vasculitis characterized by unknown etiology.

Match Overview

1	Crossref 42 words Etsuko Tsuda, Manphool Singhal. "Role of imaging studies in Kawasaki disease", International Journal of Rheumatic	1%
2	Crossref 23 words Luisa Berenise Gámez-González, Chiharu Murata, Mireya Muñoz-Ramírez, Marco Yamazaki-Nakashimada. "Clinical	1%
3	Internet 20 words crawled on 11-Feb-2016 europepmc.org	1%
4	Internet 12 words crawled on 12-Jun-2020 vpjournal.net	<1%



Revascularization in patients with incomplete kawas



Sign in



ALL

IMAGES

VIDEOS

8,420 Results

Any time ▾

Cardiovascular involvement in Kawaski Disease

<https://www.ncbi.nlm.nih.gov/pmc/articles/PMC3232573>

In **patients** with stenotic lesions or **giant** aneurysms, the stenosis is frequently progressive in nature and may result in **myocardial infarction**, which is the principal cause of death in KD. 5 Ischemic heart **disease** develops in < 3% of cases and usually occurs within the first year but fatal infarctions have been reported more than 6 years after ...

Coronary Revascularization in Patients with Kawasaki ...

<https://www.researchgate.net/publication/44601459...>

We **report a case** of a 28-year-old white man **presenting** with ST elevation **myocardial infarction** and later found to have triple vessel **coronary artery** aneurysmal **disease**, probably **secondary** to ...

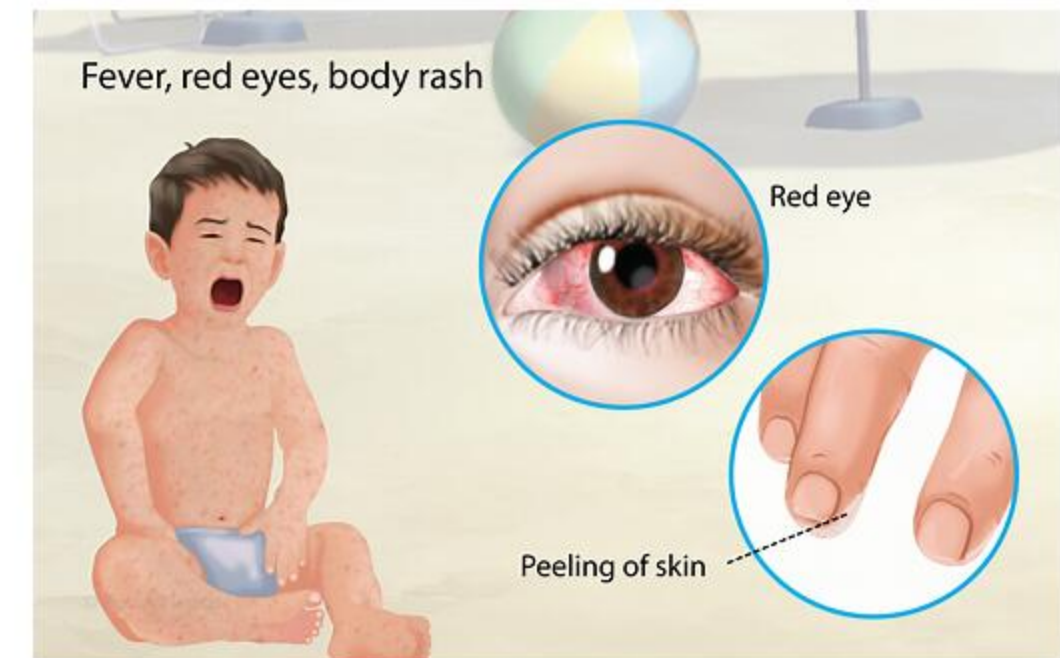
Perioperative Considerations of Kawasaki Disease

<https://www.ncbi.nlm.nih.gov/pmc/articles/PMC3684330>

However, **coronary artery aneurysm** (CAA) or ectasia can develop in 15%-20% of untreated children and may lead to long-term consequences such as **myocardial infarction**, sudden death, and congestive heart failure. 2 Surgery on **patients** with a history of KD or on **patients** with a current onset of KD presents anesthesia challenges.

Kawasaki Disease

Medical Condition



A rare disease that affects the blood vessels.

Rare (Fewer than 200,000 cases per year in US)

Requires lab test or imaging



Incomplete kawasaki disease complicated with acute abdomen: a ca



ALL

IMAGES

VIDEOS

74,100 Results

Any time ▾

Incomplete Kawasaki disease associated with complicated ...

<https://www.ncbi.nlm.nih.gov/pmc/articles/PMC3476559>

The patient was diagnosed with **incomplete Kawasaki disease** and treated with intravenous immunoglobulin and high-dose acetylsalicylic acid. The fever subsided within 48 h. To the authors' knowledge, the present **report** is the first **report** of **Kawasaki disease** associated with **complicated S pyogenes pneumonia**.

Cited by: 10

Author: Timothy Ronan Leahy, Eyal Cohen, Upto...

Publish Year: 2012

Incomplete Kawasaki Disease as Presentation of COVID-19 ...

<https://academic.oup.com/tropej/advance-article/...> ▾

Aug 05, 2020 · This condition defined by WHO as multisystem **inflammatory disorder** in children and adolescents has a wide spectrum of manifestations ranging from **incomplete KD**, **Kawasaki shock syndrome**, **toxic shock syndrome** to multiorgan failure [2]. We are presenting **case report** of a 5-month-old **infant** with **incomplete KD** and concomitant COVID-19 infection.

Kawasaki Disease Complicated by Gallbladder Hydrops ...

<https://pubmed.ncbi.nlm.nih.gov/2700275>

Kawasaki Disease Complicated by Gallbladder Hydrops Mimicking Acute Abdomen: A Report of Three Cases Three cases of **gallbladder hydrops** associated with **Kawasaki disease** are presented. The initial manifestations were **high fever**, **jaundice** and **distended abdomen** with guarding.

Cited by: 11

Author: Jia-Woei Hou, Mei-Hwei Chang, Mei-Hwa...

Publish Year: 1989

Kawasaki Disease Presenting as Acute Acalculous Cholecystitis

<https://www.ncbi.nlm.nih.gov/pmc/articles/PMC6861022>

Oct 14, 2019 · INTRODUCTION. **Kawasaki disease (KD)** is a pediatric vasculitis that typically presents with a set of non-specific symptoms, such as **abdominal pain**, vomiting, diarrhea, rash, cough, rhinorrhea, and irritability, which can obscure a correct diagnosis.¹ Rarely, KD may present with an **acute surgical abdomen** caused by conditions such as **acute acalculous cholecystitis (AAC)**, gallbladder ...

Cited by: 2

Author: Demis N Lipe, Lindsey C Bridges

Publish Year: 2019



Incomplete Kawasaki disease complicated with acute abdomen: A c



ALL IMAGES VIDEOS MAPS NEWS SHOPPING

79,100 Results

Any time ▾

Incomplete Kawasaki disease associated with complicated ...

<https://www.ncbi.nlm.nih.gov/pmc/articles/PMC3476559>

The patient was diagnosed with **incomplete Kawasaki disease** and treated with intravenous immunoglobulin and high-dose acetylsalicylic acid. The fever subsided within 48 h. To the authors' knowledge, the present **report** is the first **report** of **Kawasaki disease** associated with **complicated S pyogenes pneumonia**.

Cited by: 10

Author: Timothy Ronan Leahy, Eyal Cohen, Upto...

Publish Year: 2012

Kawasaki Disease Complicated by Gallbladder Hydrops ...

<https://pubmed.ncbi.nlm.nih.gov/2700275>

Kawasaki Disease Complicated by Gallbladder Hydrops Mimicking Acute Abdomen: A Report of Three Cases Three cases of **gallbladder hydrops** associated with **Kawasaki disease** are presented. The initial manifestations were **high fever**, **jaundice** and **distended abdomen** with guarding.

Cited by: 11

Author: Jia-Woei Hou, Mei-Hwei Chang, Mei-Hwa...

Publish Year: 1989

Incomplete Refractory Kawasaki Disease in an Infant—A Case ...

<https://www.ncbi.nlm.nih.gov/pmc/articles/PMC6074057>

Jul 27, 2018 · Introduction. **Kawasaki disease** (KD) or mucocutaneous lymph node syndrome was named after Tomisaku **Kawasaki**, a Japanese pediatrician who described this febrile vasculitis for the first time in 1967 (). Therefore, common KD involves fever for more than 5 days along with at least four of the following clinical features: erythema of the lips and oral mucosa, bilateral nonexudative ...

Cited by: 3

Author: Cristina O. Mărginean, Lorena E. Meliț, Li...

Publish Year: 2018

Incomplete Kawasaki Disease as Presentation of COVID-19 ...

<https://academic.oup.com/tropej/advance-article/...> ▾

This condition defined by WHO as multisystem **inflammatory disorder** in children and adolescents has a wide spectrum of manifestations ranging from **incomplete KD**, **Kawasaki shock syndrome**, **toxic shock syndrome** to multiorgan failure [2]. We are presenting **case report** of a 5-month-old **infant** with **incomplete KD** and concomitant COVID-19 infection.

Kawasaki Disease

Medical Condition

A rare disease that affects the blood vessels.

Rare (Fewer than 200,000 cases per year in US)

Requires lab test or imaging

Treatment from medical professional advised

Can last several days or weeks

Exact cause is not known; bacteria, virus and environmental factors may play a role. Red eyes, fever and skin peeling are the common symptoms. In case of heart complications, medication and angioplasty are the treatment option.

Symptoms

Symptoms include -

- Joint pain
- Diarrhea
- Vomiting
- Abdominal pain
- Fever
- Red eyes without any discharge
- A rash on the trunk and in the genital area
- Cracked lips
- An extremely red and swollen tongue
- Red skin on the palms of the hands and the soles of the feet
- Swollen lymph nodes in the neck
- Irritability
- Peeling of the skin on the hands and feet

Treatments

Treatment depends on the conditions and complications.

Medication