

# World Journal of *Gastrointestinal Endoscopy*

*World J Gastrointest Endosc* 2020 October 16; 12(10): 323-407



### REVIEW

- 323** Endoscopic retrograde cholangiopancreatography guided interventions in the management of pancreatic cancer  
*Yousaf MN, Ehsan H, Wahab A, Muneeb A, Chaudhary FS, Williams R, Haas CJ*

### ORIGINAL ARTICLE

#### Retrospective Cohort Study

- 341** Assessing the yield and safety of endoscopy in acute graft-*vs*-host disease after hematopoietic stem cell transplant  
*Rajan AV, Trieu H, Chu P, Lin J, Kidambi TD*

#### Retrospective Study

- 355** Role of endoscopic ultrasound in pediatric patients: A single tertiary center experience and review of the literature  
*Altonbary AY, Hakim H, Elkashef W*

#### Observational Study

- 365** Defining the advantages and exposing the limitations of endoscopic variceal ligation in controlling acute bleeding and achieving complete variceal eradication  
*Krige J, Jonas E, Kotze U, Kloppers C, Gandhi K, Allam H, Bernon M, Burmeister S, Setshedi M*
- 378** Predictor of respiratory disturbances during gastric endoscopic submucosal dissection under deep sedation  
*Aikawa M, Uesato M, Urahama R, Hayano K, Kunii R, Kawasaki Y, Isono S, Matsubara H*

### SYSTEMATIC REVIEWS

- 388** Fluorescence guided intraluminal endoscopy in the gastrointestinal tract: A systematic review  
*Mortensen OE, Nerup N, Thorsteinsson M, Svendsen MBS, Shiwa H, Achiam MP*

### LETTER TO THE EDITOR

- 401** Real-world clinical data of endoscopy-based cancer detection during the emergency declaration for COVID-19 in Japan  
*Yoshida S, Nishizawa T, Toyoshima O*
- 404** Endotracheal intubation in patients with COVID-19 using an ultrathin flexible gastrointestinal endoscope  
*Masaki S, Yamada C, Kawamoto T*

**ABOUT COVER**

Editor-in-Chief of *World Journal of Gastrointestinal Endoscopy*, Dr. Koulaouzidis is currently with the Centre for Liver & Digestive Disorders at the Royal Infirmary of Edinburgh, United Kingdom. He obtained his Medical Degree in 1995 from the Medical School of the Aristotle University of Thessaloniki, Greece. He subsequently earned a Doctorate in Medicine from the Medical School of the University of Edinburgh, United Kingdom and a Doctorate in Philosophy from Lunds Universitet, Sweden. He has published extensively on capsule endoscopy and has co-authored several books chapters. His PubMed-indexed record of articles numbers > 200. He has developed a niche as an international Key Opinion Leader in clinical capsule endoscopy and an advocate of minimally-invasive/precision gastrointestinal diagnosis. He is also the co-founder of a promising MedTech start-up and holds other specialty interests, including colonoscopy, colorectal cancer, and microscopic colitis. (L-Editor: Filipodia)

**AIMS AND SCOPE**

The primary aim of *World Journal of Gastrointestinal Endoscopy* (WJGE, *World J Gastrointest Endosc*) is to provide scholars and readers from various fields of gastrointestinal endoscopy with a platform to publish high-quality basic and clinical research articles and communicate their research findings online.

WJGE mainly publishes articles reporting research results and findings obtained in the field of gastrointestinal endoscopy and covering a wide range of topics including capsule endoscopy, colonoscopy, double-balloon enteroscopy, duodenoscopy, endoscopic retrograde cholangiopancreatography, endosonography, esophagoscopy, gastrointestinal endoscopy, gastroscopy, laparoscopy, natural orifice endoscopic surgery, proctoscopy, and sigmoidoscopy.

**INDEXING/ABSTRACTING**

The WJGE is now abstracted and indexed in Emerging Sources Citation Index (Web of Science), PubMed, PubMed Central, China National Knowledge Infrastructure (CNKI), and Superstar Journals Database.

**RESPONSIBLE EDITORS FOR THIS ISSUE**

Production Editor: Li-Li Wang; Production Department Director: Yun-Xiaojian Wu; Editorial Office Director: Jia-Ping Yan.

**NAME OF JOURNAL**

*World Journal of Gastrointestinal Endoscopy*

**ISSN**

ISSN 1948-5190 (online)

**LAUNCH DATE**

October 15, 2009

**FREQUENCY**

Monthly

**EDITORS-IN-CHIEF**

Anastasios Koulaouzidis, Bing Hu, Sang Chul Lee

**EDITORIAL BOARD MEMBERS**

<https://www.wjgnet.com/1948-5190/editorialboard.htm>

**PUBLICATION DATE**

October 16, 2020

**COPYRIGHT**

© 2020 Baishideng Publishing Group Inc

**INSTRUCTIONS TO AUTHORS**

<https://www.wjgnet.com/bpg/gerinfo/204>

**GUIDELINES FOR ETHICS DOCUMENTS**

<https://www.wjgnet.com/bpg/GerInfo/287>

**GUIDELINES FOR NON-NATIVE SPEAKERS OF ENGLISH**

<https://www.wjgnet.com/bpg/gerinfo/240>

**PUBLICATION ETHICS**

<https://www.wjgnet.com/bpg/GerInfo/288>

**PUBLICATION MISCONDUCT**

<https://www.wjgnet.com/bpg/gerinfo/208>

**ARTICLE PROCESSING CHARGE**

<https://www.wjgnet.com/bpg/gerinfo/242>

**STEPS FOR SUBMITTING MANUSCRIPTS**

<https://www.wjgnet.com/bpg/GerInfo/239>

**ONLINE SUBMISSION**

<https://www.f6publishing.com>



## Endotracheal intubation in patients with COVID-19 using an ultrathin flexible gastrointestinal endoscope

Shigenori Masaki, Chizuko Yamada, Takashi Kawamoto

**ORCID number:** Shigenori Masaki 0000-0003-2608-599X; Chizuko Yamada 0000-0001-7927-0107; Takashi Kawamoto 0000-0002-8298-1775.

**Author contributions:** Masaki S, Yamada C, and Kawamoto T designed, conducted the study, and revised the manuscript critically; Masaki S and Yamada C collected and interpreted data; Masaki S drafted the manuscript; all authors approved the final version of the manuscript.

**Conflict-of-interest statement:** All authors have nothing to disclose.

**Open-Access:** This article is an open-access article that was selected by an in-house editor and fully peer-reviewed by external reviewers. It is distributed in accordance with the Creative Commons Attribution NonCommercial (CC BY-NC 4.0) license, which permits others to distribute, remix, adapt, build upon this work non-commercially, and license their derivative works on different terms, provided the original work is properly cited and the use is non-commercial. See: <http://creativecommons.org/licenses/by-nc/4.0/>

**Manuscript source:** Unsolicited manuscript

**Shigenori Masaki**, Department of Surgery and Gastroenterology, Miyanomori Memorial Hospital, Sapporo 064-0953, Hokkaido, Japan

**Chizuko Yamada**, Department of Safety Management, Miyanomori Memorial Hospital, Sapporo 064-0953, Hokkaido, Japan

**Takashi Kawamoto**, Department of Neurosurgery, Miyanomori Memorial Hospital, Sapporo 064-0953, Hokkaido, Japan

**Corresponding author:** Shigenori Masaki, MD, Chief Doctor, Department of Surgery and Gastroenterology, Miyanomori Memorial Hospital, 3-7-5-25 Miyanomori, Chuo-ku, Sapporo 064-0953, Hokkaido, Japan. [ayukkyjp@yahoo.co.jp](mailto:ayukkyjp@yahoo.co.jp)

### Abstract

Pneumonia caused by severe acute respiratory syndrome coronavirus 2 occasionally becomes severe and requires endotracheal intubation. Endotracheal intubation is usually performed using a laryngoscope; however, the operator needs to be in close proximity to the patient's face during the procedure, which increases the risk of droplet exposure. Therefore, we simulated fiberoptic endotracheal intubation on a mannequin representing the patient, using an ultrathin flexible gastrointestinal endoscope as an alternative to the bronchoscope, in order to maintain distance from the patient during the procedure. We performed this procedure 10 times and measured the time required; the median procedure time was 6.4 s (interquartile range, 5.7-8.1 s). The advantage of this method is the short procedure time and distance maintained from the patients. The flexible tip-steerable control and length of the gastrointestinal endoscope contributed to shortening the procedure time and maintaining distance from the patients. In addition, this method can handle difficult airways without risk of misplacement of the endotracheal tube. However, it is necessary to consider the risk of aerosol generation associated with this procedure. In the pandemic setting of coronavirus disease 2019, this approach may be useful when a gastrointestinal endoscopist is in charge of endotracheal intubation of patients with coronavirus disease 2019.

**Key Words:** Endotracheal intubation; SARS-CoV-2; COVID-19; Laryngoscopes; Bronchoscopes; Gastrointestinal endoscopes

©The Author(s) 2020. Published by Baishideng Publishing Group Inc. All rights reserved.

**Received:** May 27, 2020**Peer-review started:** May 27, 2020**First decision:** September 11, 2020**Revised:** September 19, 2020**Accepted:** September 25, 2020**Article in press:** September 25, 2020**Published online:** October 16, 2020**P-Reviewer:** Friedel D, Rawat K**S-Editor:** Zhang L**L-Editor:** A**P-Editor:** Wang LL

**Core Tip:** Proximity of the operators to the patient is inevitable with conventional endotracheal intubation procedures. In this endotracheal intubation method, the gastrointestinal endoscope is used as an alternative to the bronchoscope. Thus, endotracheal intubation can be performed while keeping a relatively safe distance from the patient, as the gastrointestinal endoscope has a long effective length. Furthermore, the flexible tip-steerable control of the gastrointestinal endoscope enables quick and reliable endotracheal intubation.

**Citation:** Masaki S, Yamada C, Kawamoto T. Endotracheal intubation in patients with COVID-19 using an ultrathin flexible gastrointestinal endoscope. *World J Gastrointest Endosc* 2020; 12(10): 404-407

**URL:** <https://www.wjgnet.com/1948-5190/full/v12/i10/404.htm>

**DOI:** <https://dx.doi.org/10.4253/wjge.v12.i10.404>

## TO THE EDITOR

Endotracheal intubation is performed in patients with severe respiratory failure induced by severe acute respiratory syndrome coronavirus 2<sup>[1]</sup>. These patients are usually intubated using a laryngoscope<sup>[2]</sup>. Coronavirus disease 2019 (COVID-19) is highly contagious; thus, preventing the propagation of infection requires maintaining a safe distance and avoiding direct exposure to droplets from infected patients<sup>[3]</sup>. However, it is difficult for healthcare professionals to maintain distance while intubating patients using a laryngoscope because operators need to stand in close proximity to patients' faces.

Here, we report the use of an ultrathin flexible gastrointestinal endoscope with a tip outer diameter of 5.0 mm (GIF-XP260N; Olympus, Tokyo, Japan) to perform endotracheal intubation on a mannequin representing the patient. The purpose of this simulation-based study was to evaluate the feasibility and usefulness of using a gastrointestinal endoscope as an alternative to the bronchoscope in endotracheal intubation. This procedure included four steps (Figures 1 and 2) as follows: First, the operator holding an endoscope over which a 7.0 mm endotracheal tube was mounted stood to the left of the supine patient; second, the endoscope was inserted into the trachea; third, we ensured instant insertion of the endotracheal tube into the trachea using the endoscope as a guide; and finally, the endoscope was withdrawn. We repeatedly performed the procedure 10 times and recorded the corresponding time taken for each procedure. The procedure time was defined as the total time elapsed between the insertion of the endoscope into the mouth and the final withdrawal of the endoscope. The median procedure time was 6.4 s (interquartile range, 5.7-8.1 s; Table 1).


Bronchoscope-guided endotracheal intubation in patients with COVID-19 has already been reported<sup>[4,5]</sup>. In our method, an ultrathin gastrointestinal endoscope was used as an alternative to the bronchoscope. This method is advantageous owing to the short procedure time. This can be attributed to the flexible tip-steerable control of the gastrointestinal endoscope because the gastrointestinal endoscope has angulation control knobs for up, down, left, and right movements, whereas the bronchoscope has an angulation control knob only for up and down movements<sup>[6]</sup>. Hence, the gastrointestinal endoscope may serve as a better alternative to the bronchoscope for endotracheal intubation. This technique will also be useful in patients with difficult airways in order to avoid the risk of misplacement of the endotracheal tube<sup>[7]</sup>. Furthermore, the effective length of the gastrointestinal endoscope used was 1.1 meters allowing the operator to maintain a relatively safe distance by standing to the left of the patient, minimizing direct exposure to droplets from patients.

However, our method has a few limitations. Conventionally, endotracheal intubation is performed by anesthesiologists familiar with techniques used in intubation<sup>[1]</sup>. Notably, gastrointestinal endoscopes are not usually available in the emergency room or intensive care unit where endotracheal intubation is often performed. Furthermore, owing to the potential for generating aerosols, it is unlikely that flexible bronchoscope-guided intubation will be the first choice in conscious patients with COVID-19<sup>[1,2]</sup>.

During this COVID-19 pandemic, there may be occasions when a gastrointestinal endoscopist is in charge of endotracheal intubation in patients with confirmed or

**Table 1** The procedure time

	Time (s)
1 <sup>st</sup>	10.2
2 <sup>nd</sup>	7.9
3 <sup>rd</sup>	8.1
4 <sup>th</sup>	10.0
5 <sup>th</sup>	6.5
6 <sup>th</sup>	5.6
7 <sup>th</sup>	4.5
8 <sup>th</sup>	5.8
9 <sup>th</sup>	5.6
10 <sup>th</sup>	6.2
Median, 6.4 (interquartile range, 5.7–8.1)	

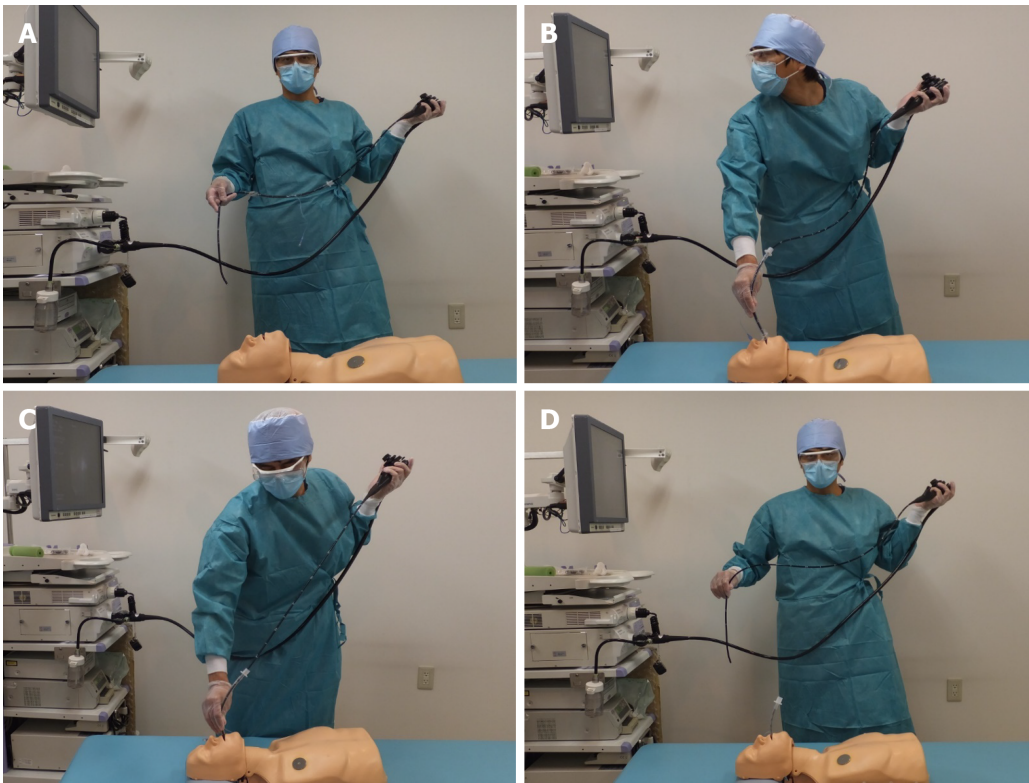
**Figure 1** The ultrathin gastrointestinal endoscope mounted into an endotracheal tube.

suspected COVID-19. If the gastrointestinal endoscopist is not familiar with endotracheal intubation using a laryngoscope, the intubation procedure is expected to be time-consuming, thus increasing the risk of direct exposure to droplets from patients. Therefore, endotracheal intubation using this method may be useful in reducing the risk of exposure to severe acute respiratory syndrome coronavirus 2.

## CONCLUSION

Endotracheal intubation using an ultrathin flexible gastrointestinal endoscope is a quick and reliable procedure that can be performed while maintaining distance from the patient. Therefore, this method may be useful in endotracheal intubation in patients with COVID-19.





**Figure 2** Gastrointestinal endoscope-guided endotracheal intubation. A: The operator standing to the left of the patient; B: Inserts the endoscope into the trachea; C: Endoscope-guided endotracheal intubation is performed; and D: The endoscope is withdrawn.

## REFERENCES

- 1 **Yao W**, Wang T, Jiang B, Gao F, Wang L, Zheng H, Xiao W, Yao S, Mei W, Chen X, Luo A, Sun L, Cook T, Behringer E, Huitink JM, Wong DT, Lane-Fall M, McNarry AF, McGuire B, Higgs A, Shah A, Patel A, Zuo M, Ma W, Xue Z, Zhang LM, Li W, Wang Y, Hagberg C, O'Sullivan EP, Fleisher LA, Wei H; collaborators. Emergency tracheal intubation in 202 patients with COVID-19 in Wuhan, China: lessons learnt and international expert recommendations. *Br J Anaesth* 2020; **125**: e28-e37 [PMID: [32312571](#) DOI: [10.1016/j.bja.2020.03.026](#)]
- 2 **Cook TM**, El-Boghdady K, McGuire B, McNarry AF, Patel A, Higgs A. Consensus guidelines for managing the airway in patients with COVID-19: Guidelines from the Difficult Airway Society, the Association of Anaesthetists the Intensive Care Society, the Faculty of Intensive Care Medicine and the Royal College of Anaesthetists. *Anaesthesia* 2020; **75**: 785-799 [PMID: [32221970](#) DOI: [10.1111/anae.15054](#)]
- 3 **Canelli R**, Connor CW, Gonzalez M, Nozari A, Ortega R. Barrier Enclosure during Endotracheal Intubation. *N Engl J Med* 2020; **382**: 1957-1958 [PMID: [32243118](#) DOI: [10.1056/NEJMc2007589](#)]
- 4 **Cai SJ**, Wu LL, Chen DF, Li YX, Liu YJ, Fan YQ, Du SH, Huang H, Liu N, Cheng LL, Deng XL, Li SY. [Analysis of bronchoscope-guided tracheal intubation in 12 cases with coronavirus disease 2019 under the personal protective equipment with positive pressure protective hood]. *Zhonghua Jie He He Hu Xi Za Zhi* 2020; **43**: 332-334 [PMID: [32133829](#) DOI: [10.3760/cma.j.cn112147-20200222-00153](#)]
- 5 **Wu CN**, Xia LZ, Li KH, Ma WH, Yu DN, Qu B, Li BX, Cao Y. High-flow nasal-oxygenation-assisted fiberoptic tracheal intubation in critically ill patients with COVID-19 pneumonia: a prospective randomised controlled trial. *Br J Anaesth* 2020; **125**: e166-e168 [PMID: [32200994](#) DOI: [10.1016/j.bja.2020.02.020](#)]
- 6 **Garg N**, Sindwani G, Suri A, Shamim R, Pandey CK. Flexible gastroendoscope as a rescue device for an anaesthetist. *J Clin Anesth* 2018; **45**: 73-74 [PMID: [29291470](#) DOI: [10.1016/j.jclinane.2017.12.026](#)]
- 7 **Jamil LH**, Bucobo JC, Nakamura M, Kadar A. Flexible Scope Endotracheal Intubation Using a Gastroscope. *Am J Gastroenterol* 2017; **112**: 535 [PMID: [28381842](#) DOI: [10.1038/ajg.2016.470](#)]



Published by **Baishideng Publishing Group Inc**  
7041 Koll Center Parkway, Suite 160, Pleasanton, CA 94566, USA

**Telephone:** +1-925-3991568

**E-mail:** [bpgoffice@wjgnet.com](mailto:bpgoffice@wjgnet.com)

**Help Desk:** <https://www.f6publishing.com/helpdesk>

<https://www.wjgnet.com>

