

World Journal of *Clinical Cases*

World J Clin Cases 2021 January 6; 9(1): 1-290



Contents

Semimonthly Volume 9 Number 1 January 6, 2021

OPINION REVIEW

- 1 Necessary problems in re-emergence of COVID-19
Chen S, Ren LZ, Ouyang HS, Liu S, Zhang LY

REVIEW

- 8 COVID-19: An overview and a clinical update
Krishnan A, Hamilton JP, Alqahtani SA, Woreta TA

ORIGINAL ARTICLE

Retrospective Cohort Study

- 24 Log odds of positive lymph nodes is a better prognostic factor for oesophageal signet ring cell carcinoma than N stage
Wang F, Gao SG, Xue Q, Tan FW, Gao YS, Mao YS, Wang DL, Zhao J, Li Y, Yu XY, Cheng H, Zhao CG, Mu JW
- 36 Modified procedure for prolapse and hemorrhoids: Lower recurrence, higher satisfaction
Chen YY, Cheng YF, Wang QP, Ye B, Huang CJ, Zhou CJ, Cai M, Ye YK, Liu CB
- 47 Angiotensin converting enzymes inhibitors or angiotensin receptor blockers should be continued in COVID-19 patients with hypertension
Tian C, Li N, Bai Y, Xiao H, Li S, Ge QG, Shen N, Ma QB

Retrospective Study

- 61 Massively prolapsed intervertebral disc herniation with interlaminar endoscopic spine system Delta endoscope: A case series
Meng SW, Peng C, Zhou CL, Tao H, Wang C, Zhu K, Song MX, Ma XX
- 71 Primary lung cancer with radioiodine avidity: A thyroid cancer cohort study
Lu YL, Chen ST, Ho TY, Chan WH, Wong RJ, Hsueh C, Lin SF
- 81 Is traumatic meniscal lesion associated with acute fracture morphology changes of tibia plateau? A series of arthroscopic analysis of 67 patients
Chen YD, Chen SX, Liu HG, Zhao XS, Ou WH, Li HX, Huang HX

Observational Study

- 91 Role of relaxin in diastasis of the pubic symphysis peripartum
Wang Y, Li YQ, Tian MR, Wang N, Zheng ZC

SYSTEMATIC REVIEWS

- 102 Chinese medicine formulas for nonalcoholic fatty liver disease: Overview of systematic reviews
Dai L, Zhou WJ, Zhong LLD, Tang XD, Ji G

- 118 Comparative profile for COVID-19 cases from China and North America: Clinical symptoms, comorbidities and disease biomarkers

Badawi A, Vasileva D

META-ANALYSIS

- 133 Polymerase chain reaction-based tests for detecting *Helicobacter pylori* clarithromycin resistance in stool samples: A meta-analysis

Gong RJ, Xu CX, Li H, Liu XM

CASE REPORT

- 148 Surgery-first for a patient with mild hemifacial microsomia: A case report and review of literature

Song JY, Yang H, He X, Gao S, Wu GM, Hu M, Zhang Y

- 163 Late-onset non-islet cell tumor hypoglycemia: A case report

Matsumoto S, Yamada E, Nakajima Y, Yamaguchi N, Okamura T, Yajima T, Yoshino S, Horiguchi K, Ishida E, Yoshikawa M, Nagaoka J, Sekiguchi S, Sue M, Okada S, Fukuda I, Shirabe K, Yamada M

- 170 Risk of group aggregative behavior during COVID-19 outbreak: A case report

Zuo H, Hu ZB, Zhu F

- 175 Low-grade fibromyxoid sarcoma of the liver: A case report

Dugalic V, Ignjatovic II, Kovac JD, Ilic N, Sopta J, Ostojic SR, Vasin D, Bogdanovic MD, Dumic I, Milovanovic T

- 183 Treatment of Stanford type A aortic dissection with triple pre-fenestration, reduced diameter, and three-dimensional-printing techniques: A case report

Zhang M, Tong YH, Liu C, Li XQ, Liu CJ, Liu Z

- 190 Hyperprolactinemia due to pituitary metastasis: A case report

Liu CY, Wang YB, Zhu HQ, You JL, Liu Z, Zhang XF

- 197 Pulmonary thromboembolism after distal ulna and radius fractures surgery: A case report and a literature review

Lv B, Xue F, Shen YC, Hu FB, Pan MM

- 204 Myeloid neoplasm with eosinophilia and rearrangement of platelet-derived growth factor receptor beta gene in children: Two case reports

Wang SC, Yang WY

- 211 Sclerosing angiomatoid nodular transformation of the spleen: A case report and literature review

Li SX, Fan YH, Wu H, Lv GY

- 218 Late recurrence of papillary thyroid cancer from needle tract implantation after core needle biopsy: A case report

Kim YH, Choi IH, Lee JE, Kim Z, Han SW, Hur SM, Lee J

- 224** Atypical adult-onset Still's disease with an initial and sole manifestation of liver injury: A case report and review of literature
Yu F, Qin SY, Zhou CY, Zhao L, Xu Y, Jia EN, Wang JB
- 232** Type A aortic dissection developed after type B dissection with the presentation of shoulder pain: A case report
Yin XB, Wang XK, Xu S, He CY
- 236** Hemosuccus pancreaticus caused by gastroduodenal artery pseudoaneurysm associated with chronic pancreatitis: A case report and review of literature
Cui HY, Jiang CH, Dong J, Wen Y, Chen YW
- 245** Endoscopic treatment for acute appendicitis with coexistent acute pancreatitis: Two case reports
Du ZQ, Ding WJ, Wang F, Zhou XR, Chen TM
- 252** Residual tumor and central lymph node metastasis after thermal ablation of papillary thyroid carcinoma: A case report and review of literature
Hua Y, Yang JW, He L, Xu H, Huo HZ, Zhu CF
- 262** Endoscopic salvage treatment of histoacryl after stent application on the anastomotic leak after gastrectomy: A case report
Kim HS, Kim Y, Han JH
- 267** Immunosuppressant treatment for IgG4-related sclerosing cholangitis: A case report
Kim JS, Choi WH, Lee KA, Kim HS
- 274** Intraparenchymal hemorrhage after surgical decompression of an epencephalon arachnoid cyst: A case report
Wang XJ
- 278** Krukenberg tumor with concomitant ipsilateral hydronephrosis and spermatic cord metastasis in a man: A case report
Tsao SH, Chuang CK
- 284** Simultaneous bilateral acromial base fractures after staged reverse total shoulder arthroplasty: A case report
Kim DH, Kim BS, Cho CH

ABOUT COVER

Editorial Board Member of *World Journal of Clinical Cases*, Dr. Antonio Corvino is a PhD in the Motor Science and Wellness Department of University of Naples "Parthenope". After obtaining his MD degree from the School of Medicine, Second University of Naples (2008), he completed a residency in Radiology at the University of Naples Federico II (2014). Following post-graduate training at the Catholic University of Rome, yielding a second level Master's degree in "Internal Ultrasound Diagnostic and Echo-Guided Therapies" (2015), he served on the directive board of Young Directive of Italian Society of Ultrasound in Medicine and Biology (2016-2018). His ongoing research interests involve ultrasound and ultrasound contrast media in abdominal and non-abdominal applications, mainly in gastrointestinal, hepatic, vascular, and musculoskeletal imaging. (L-Editor: Filipodia)

AIMS AND SCOPE

The primary aim of *World Journal of Clinical Cases* (*WJCC*, *World J Clin Cases*) is to provide scholars and readers from various fields of clinical medicine with a platform to publish high-quality clinical research articles and communicate their research findings online.

WJCC mainly publishes articles reporting research results and findings obtained in the field of clinical medicine and covering a wide range of topics, including case control studies, retrospective cohort studies, retrospective studies, clinical trials studies, observational studies, prospective studies, randomized controlled trials, randomized clinical trials, systematic reviews, meta-analysis, and case reports.

INDEXING/ABSTRACTING

The *WJCC* is now indexed in Science Citation Index Expanded (also known as SciSearch®), Journal Citation Reports/Science Edition, PubMed, and PubMed Central. The 2020 Edition of Journal Citation Reports® cites the 2019 impact factor (IF) for *WJCC* as 1.013; IF without journal self cites: 0.991; Ranking: 120 among 165 journals in medicine, general and internal; and Quartile category: Q3.

RESPONSIBLE EDITORS FOR THIS ISSUE

Production Editor: Yan-Xia Xing; Production Department Director: Yun-Xiaojuan Wu; Editorial Office Director: Jin-Lai Wang.

NAME OF JOURNAL

World Journal of Clinical Cases

ISSN

ISSN 2307-8960 (online)

LAUNCH DATE

April 16, 2013

FREQUENCY

Semimonthly

EDITORS-IN-CHIEF

Dennis A Bloomfield, Sandro Vento, Bao-gan Peng

EDITORIAL BOARD MEMBERS

<https://www.wjgnet.com/2307-8960/editorialboard.htm>

PUBLICATION DATE

January 6, 2021

COPYRIGHT

© 2021 Baishideng Publishing Group Inc

INSTRUCTIONS TO AUTHORS

<https://www.wjgnet.com/bpg/gerinfo/204>

GUIDELINES FOR ETHICS DOCUMENTS

<https://www.wjgnet.com/bpg/GerInfo/287>

GUIDELINES FOR NON-NATIVE SPEAKERS OF ENGLISH

<https://www.wjgnet.com/bpg/gerinfo/240>

PUBLICATION ETHICS

<https://www.wjgnet.com/bpg/GerInfo/288>

PUBLICATION MISCONDUCT

<https://www.wjgnet.com/bpg/gerinfo/208>

ARTICLE PROCESSING CHARGE

<https://www.wjgnet.com/bpg/gerinfo/242>

STEPS FOR SUBMITTING MANUSCRIPTS

<https://www.wjgnet.com/bpg/GerInfo/239>

ONLINE SUBMISSION

<https://www.f6publishing.com>

Pulmonary thromboembolism after distal ulna and radius fractures surgery: A case report and a literature review

Bo Lv, Feng Xue, Yu-Chun Shen, Fang-Bao Hu, Ming-Mang Pan

ORCID number: Bo Lv 0000-0002-2499-0948; Feng Xue 0000-0003-1416-1502; Yu-Chun Shen 0000-0003-2406-735X; Fang-Bao Hu 0000-0002-3109-1852; Ming-Mang Pan 0000-0002-6500-5553.

Author contributions: Xue F designed the case report; Lv B and Pan MM analyzed all the data and wrote the manuscript; Shen YC operated on the patient; Hu FB and Shen YC gave anticoagulant treatment to the patient. All authors read and approved the final manuscript.

Supported by Shanghai Fengxian District Osteoarthropathy Clinical Diagnosis and Treatment Center, China, No. fxlczlx-a-201704.

Informed consent statement: All study participants or their legal guardian provided informed written consent about personal and medical data collection prior to study enrolment.

Conflict-of-interest statement: All the authors have no conflict of interest related to the manuscript.

CARE Checklist (2016) statement: The authors have read the CARE Checklist (2016), and the manuscript was prepared and revised according to the CARE Checklist (2016).

Bo Lv, Feng Xue, Yu-Chun Shen, Ming-Mang Pan, Department of Orthopaedics, Shanghai Fengxian District Central Hospital, Shanghai Jiao Tong University Affiliated Sixth People's Hospital South Campus, Shanghai 201499, China

Fang-Bao Hu, Intensive Care Unit, Shanghai Fengxian District Central Hospital, Shanghai Jiao Tong University Affiliated Sixth People's Hospital South Campus, Shanghai 201499, China

Corresponding author: Feng Xue, MD, Doctor, Department of Orthopaedics, Shanghai Fengxian District Central Hospital, Shanghai Jiao Tong University Affiliated Sixth People's Hospital South Campus, No. 6600 Nanfeng Road, Fengxian District, Shanghai 201499, China. xuefengmd@163.com

Abstract

BACKGROUND

Pulmonary thromboembolism (PTE) is a serious postoperative complication that can occur after a fracture. Generally, PTE is caused by the falling off of lower extremity deep vein thrombosis (LEDVT) after lower limb fracture surgery. LEDVT and PTE after upper extremity fracture surgery are very rare. PTE is one of the most common clinical causes of sudden death. Venous thromboembolism includes PTE and DVT. We experienced one case of LEDVT and PTE after distal ulna and radius fracture surgery. The purpose of our report is to raise awareness for orthopedic surgeons that PTE can occur after distal ulna and radius fracture surgery, and patients with high risk factors should be considered for prevention and treatment of thrombosis in a timely manner.

CASE SUMMARY

We report a 51-year-old Chinese male who had severe fractures of the left distal ulna, radius and little finger after a motorcycle accident. The patient underwent external fixation, open reduction and internal fixation. On the third post-operative day, computed tomographic pulmonary angiography showed PTE. Doppler ultrasonography showed thrombus formation in the bilateral posterior tibial veins. After a period of anticoagulation therapy, on the 25th d after the PTE, computed tomographic pulmonary angiography showed that thrombus in both sides of the pulmonary artery disappeared. Furthermore, about 4 mo after the PTE, thrombosis in the deep veins of the lower limbs disappeared. About 1 year after the surgery, X-rays showed good fracture healing, and the function of the wrist joint recovered well.

CONCLUSION

Open-Access: This article is an open-access article that was selected by an in-house editor and fully peer-reviewed by external reviewers. It is distributed in accordance with the Creative Commons Attribution NonCommercial (CC BY-NC 4.0) license, which permits others to distribute, remix, adapt, build upon this work non-commercially, and license their derivative works on different terms, provided the original work is properly cited and the use is non-commercial. See: <http://creativecommons.org/licenses/by-nc/4.0/>

Manuscript source: Unsolicited manuscript

Specialty type: Medicine, research and experimental

Country/Territory of origin: China

Peer-review report's scientific quality classification

Grade A (Excellent): 0
Grade B (Very good): 0
Grade C (Good): C
Grade D (Fair): 0
Grade E (Poor): 0

Received: May 27, 2020

Peer-review started: May 27, 2020

First decision: November 25, 2020

Revised: November 25, 2020

Accepted: December 6, 2020

Article in press: December 6, 2020

Published online: January 6, 2021

P-Reviewer: Nava-Zavala AH

S-Editor: Zhang L

L-Editor: Filipodia

P-Editor: Ma YJ



Though rare, PTE can occur after distal ulna and radius fracture surgery and patients with high risk factors should be considered for prevention and treatment of thrombosis in a timely manner.

Key Words: Distal ulna and radius fracture; Pulmonary thromboembolism; Deep venous thrombosis; External fixation; Open reduction and internal fixation; Case report

©The Author(s) 2021. Published by Baishideng Publishing Group Inc. All rights reserved.

Core Tip: We report a 51-year-old Chinese male who had severe fractures in the left distal ulna, radius and little finger after a motorcycle accident. The patient underwent external fixation, open reduction and internal fixation. On the third postoperative day after the second surgery, he was diagnosed with pulmonary thromboembolism and lower extremity deep vein thrombosis. After 25 d of anticoagulation therapy, computed tomographic pulmonary angiography showed that the thrombus in the pulmonary artery disappeared. This case raises awareness for orthopedics that pulmonary thromboembolism can occur after upper extremity surgery, and that patients with high risk factors should be considered for prevention and treatment of thrombosis in a timely manner.

Citation: Lv B, Xue F, Shen YC, Hu FB, Pan MM. Pulmonary thromboembolism after distal ulna and radius fractures surgery: A case report and a literature review. *World J Clin Cases* 2021; 9(1): 197-203

URL: <https://www.wjgnet.com/2307-8960/full/v9/i1/197.htm>

DOI: <https://dx.doi.org/10.12998/wjcc.v9.i1.197>

INTRODUCTION

There are three main predisposing factors that can lead to deep vein thrombosis (DVT): damage to the lining of the vein, slow movement of blood in the circulation and a high blood coagulation state^[1]. If pulmonary thromboembolism (PTE) is not diagnosed and treated promptly, it is associated with a mortality rate as high as 30% and accounts for 5%-10% of inpatient hospital deaths in the United States^[2]. DVT is more common in the lower extremity after lower extremity fracture surgery. The incidence of venous thromboembolism (VTE) after upper extremity fracture is about 1.3%; the incidence of VTE after mid- and/or distal ulna and/or radius fracture is about 0.95%^[3]. We present the case of a 51-year-old man who was diagnosed with a lower extremity DVT and PTE after distal ulna and radius fracture surgery. Our patient was informed that data concerning the case would be submitted for publication.

CASE PRESENTATION

Chief complaints

A 51-year-old male was admitted to our hospital on August 28, 2013 after a motorcycle accident. The patient complained of pain, swelling and bleeding in the left upper limb for 2 h.

History of present illness

The patient had a motorcycle accident on August 28, 2013. The left little finger landed first, then the left wrist flexed and landed and the dorsal skin of the left forearm was punctured by ulna and radius fractures causing pain, swelling and bleeding of the left upper limb. The skin of the left hand felt normal after the trauma, and finger activity was normal. He was sent to our hospital for emergency treatment for debridement, and his left arm was fixed with long arm plaster. The X-ray radiography showed fractures of the left distal ulna, radius and little finger as well as wrist joint dislocation (Figure 1A). The injury occurred only in the left upper limb, and no other organs or

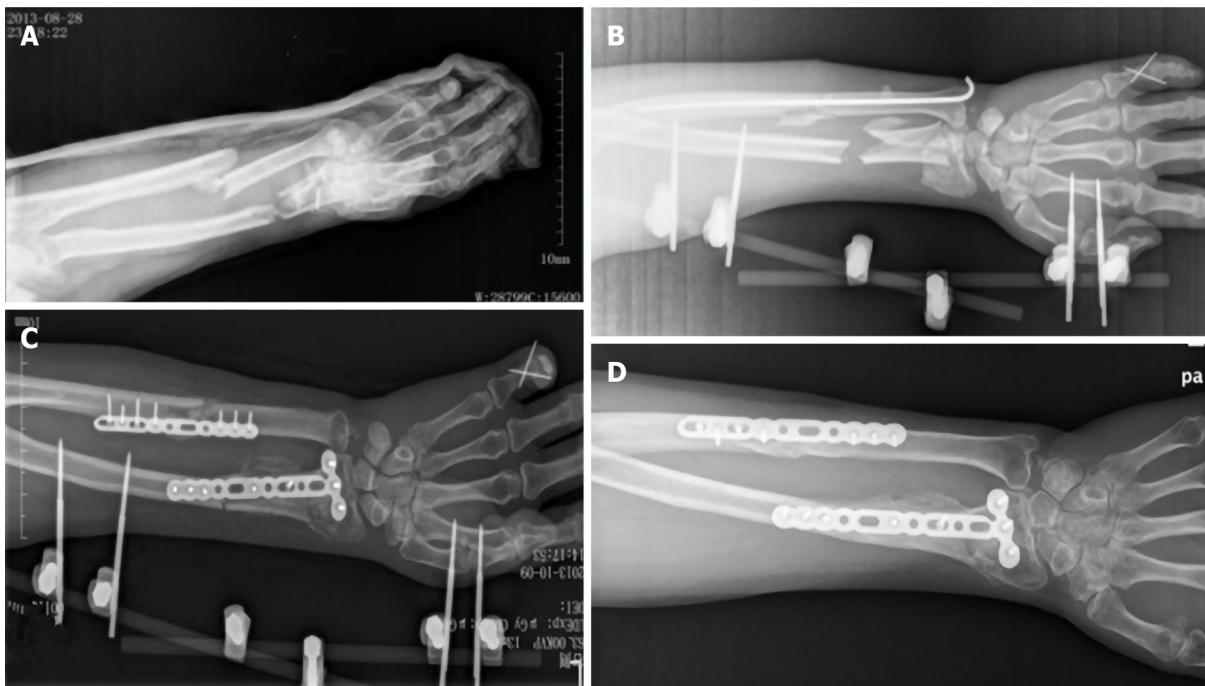


Figure 1 X-ray radiography. A: The same day after a motorcycle accident; B: One day after the first operation; C: Twenty-eight days after the second operation; D: One year after the operation.

tissues were injured.

The patient was hospitalized for further surgical treatment. External fixation and Kirschner wire were used to stabilize the left distal ulna, radius and little finger (Figure 1B). The patient walked every day after the operation. The swelling of the left forearm was reduced 12 d after the first surgery. Open reduction and internal fixation were performed under general anesthesia to stabilize the left distal ulna and radius. Because some of the bone in the distal radius was lost due to compression, we took about 10 g of bone from the left ilium to fill (Figure 1C). The operation continued for 4 h. Broad-spectrum antibiotic was used to prevent infection, and drugs were used to promote blood flow and microcirculation. After the anesthesia recovery period, the patient told us that he suffered severe pain and could hear the noise from the electric drill during the operation, but he was unable to communicate this during the operation. This led to psychological trauma. The patient became very sensitive to pain and remained in bed until the third postoperative day.

On the third postoperative morning, when he got out of bed and was going to the toilet, he was unable to stand, owing to double lower limb weakness and pain. The double lower limbs were not tumid, and the skin color was normal. When he received a shot for the intravenous infusion, he was very nervous and suddenly felt chest pain and asthma and had breathing difficulty. Additionally, his double lung breaths sounded thick and had a large number of dry and wet rales. The partial pressure of arterious blood oxygen was 7.2 kPa (normal range 11-13 kPa), arterial oxygen saturation was 88.8% (normal range 91.9%-99.0%), and central venous pressure was 11 cmH₂O (normal range 5-10 cmH₂O). After oxygen therapy, peripheral capillary hemoglobin oxygen saturation was 92%, blood pressure was 158/110 mmHg, heart rate was 110 bpm, and respiratory rate was 30 bpm. The brain natriuretic peptide troponin I was negative. The serum D-dimer level was 17.48 µg/mL. The bedside electrocardiograph showed sinus tachycardia. Wells and revised Geneva scores were 9 and 11, respectively. The patient was diagnosed with high clinical probability of PTE based on these Wells and revised Geneva scoring systems^[4,5]. We first considered PTE.

History of past illness

The patient had no previous surgery or medical problems or family history of blood clotting disorders. Previously, the patient had no respiratory or circulatory problems.

Personal and family history

The patient was a 51-year-old male, weighed 90 kg and was 175 cm tall. His body mass index (BMI) was 29.4 kg/m². He started drinking heavily around age 17 (about 500 mL

of wine a day). He did not smoke. None of his family has suffered from VTE.

Physical examination

Left forearm dorsal skin was pricked by ulna and radius fracture ends, swelling deformity, bleeding, left wrist activity limitations. The skin of the left hand felt normal after the trauma, and finger activity was normal.

Laboratory examinations

On the morning of the first day after the motorcycle accident, the serum D-dimer level was 0.80 $\mu\text{g/mL}$ (the reference range $< 1.00 \mu\text{g/mL}$). When pulmonary embolism occurred, the serum D-dimer level was 17.48 $\mu\text{g/mL}$. The routine blood and biochemical indicators were not significantly abnormal.

Imaging examinations

Computed tomographic pulmonary angiography (CTPA) showed intravascular wirelike, sheet filling defects in both sides of the pulmonary artery trunks and its branches; the large shadow in the right pulmonary trunk was about 56 mm \times 16 mm (Figure 2). Doppler ultrasonography showed no significant anomalies in the upper extremity deep vein within the bilateral posterior tibial veins of the lower limb thrombus formation. Echocardiography did not show patent foramen ovale and a right to left shunt.

FINAL DIAGNOSIS

Based on the clinical findings, along with the serum D-dimer, CTPA and upper and lower extremity Doppler ultrasonography, the patient was diagnosed with PTE, LEDVT after distal ulna and radius fracture surgery.

TREATMENT

The patient was immediately given oxygen therapy and transferred to the intensive care unit. The patient's body position remained in one place to prevent deep vein thrombosis of the lower limbs breaking off and increasing pulmonary embolism. Low molecular weight heparin sodium and warfarin sodium were used for anticoagulation. The drugs were used to promote local blood flow, and antibiotics were used to prevent lung infection. On the same day, subcutaneous injections of low molecular weight heparin sodium (17500 IU) was administered. In the first 9 days after PTE, low molecular weight heparin sodium (10000 IU) was administered subcutaneously every day in the morning and at night. On the ninth day after PTE, re-examination of the CTPA showed that the thrombus in both sides of the pulmonary artery was not significantly reduced (Figure 3). Reexamination of the deep venous vascular ultrasound showed thrombosis in both the superficial femoral and deep femoral veins and intravascular thrombosis of the bilateral soleus. The anticoagulation effect was not ideal, as there was a need to adjust anticoagulation. The 10th to 31st days after PTE, low molecular weight heparin sodium (15000 IU) was administered subcutaneously every day at morning, noon and night. From the 32nd day after PTE, we stopped using low molecular heparin sodium.

On the sixth day after PTE, the patient said his right lower limb was painful, and an additional 2.5 mg of warfarin sodium was used every day. On the 14th and 15th day after PTE, the dose of warfarin sodium was increased to 3.125 mg. On the 16th to 18th day after PTE, the dose of warfarin sodium was increased to 3.75 mg. On the 19th to 22nd day after PTE, the dose of warfarin sodium was increased to 5 mg. On the 23rd to 35th day after PTE, the dose of warfarin sodium was increased to 6.25 mg. On the 31st d after PTE, the international normalized ratio (INR) was 1.47 (normal range 0.69-1.33, INR should be controlled in the 2-3 range, according to the guidelines). On the 40th day after PTE, the INR was 2.74, and the warfarin sodium was reduced to 5 mg. On the 43rd day after PTE, the INR was 2.96, and the warfarin sodium was reduced to 4.375 mg. We continued to administer 4.375 mg of warfarin sodium every night for 1 yr.

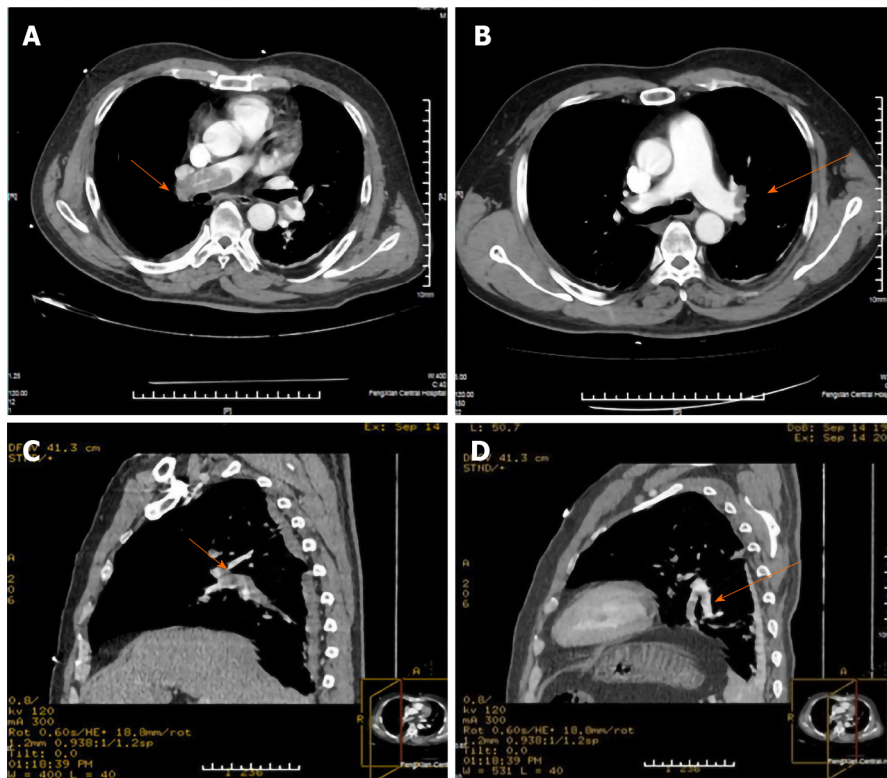


Figure 2 Computed tomographic pulmonary angiography at the onset of pulmonary embolism. A: Horizontal plane showed filling defect in the right pulmonary artery; B: Horizontal plane showed filling defect in the left and right pulmonary arteries; C: Sagittal plane showed filling defect in the right pulmonary artery and its branches; D: Sagittal plane showed filling defect in the left pulmonary artery and its branches.

OUTCOME AND FOLLOW-UP

After 25 d of anticoagulant treatment, CTPA showed the thrombus in both sides of the pulmonary artery had disappeared. About 4 mo after PTE, thrombosis in the deep veins of the lower limbs had disappeared. On the 44th d after the PTE, the patient was discharged and continued oxygen therapy for about 3–4 mo. About 7 mo after PTE, the patient's respiratory function returned to near the previous level. About 2 mo after the second surgery, the external fixation was dismantled. About 1 year after the second surgery, radiographs showed good fracture healing (Figure 1D), and the left wrist function recovered.

DISCUSSION

PTE after upper extremity fracture is rare. There are no common guidelines for PTE after upper extremity fractures. Common clinical manifestations of DVT include swelling, redness, tenderness, and the presence of collateral superficial veins. Common clinical manifestations of PTE comprise a sudden onset of dyspnea, chest pain, syncope, hemoptysis, tachycardia and tachypnoea. Because the above clinical manifestations are not specific, further auxiliary examinations are necessary in time. D-dimer has high sensitivity, low specificity and a high negative predictive value in predicting VTE^[6]. If the plasma D-dimer is negative, VTE can be largely excluded. Doppler ultrasonography has high sensitivity and specificity in the diagnosis of DVT, which is the preferred method for the diagnosis of DVT at present^[7]. CTPA has a high sensitivity for PTE, which is currently the preferred test for diagnosing PTE^[8,9]. The treatment of PTE mainly includes anticoagulation and thrombolysis.

For patients with hemodynamic instability, thrombolytic therapy is preferred to restore pulmonary reperfusion in time. In contrast, for patients with hemodynamic stability, anticoagulant therapy is generally preferred^[10,11]. The patient reported suffered from severe pain during the operation. This led to psychological trauma. The patient became very sensitive to pain and remained in bed until the third postoperative day. Upper limb fractures and surgical trauma led to a high blood coagulation state. The patient was bedridden for three consecutive days after surgery,

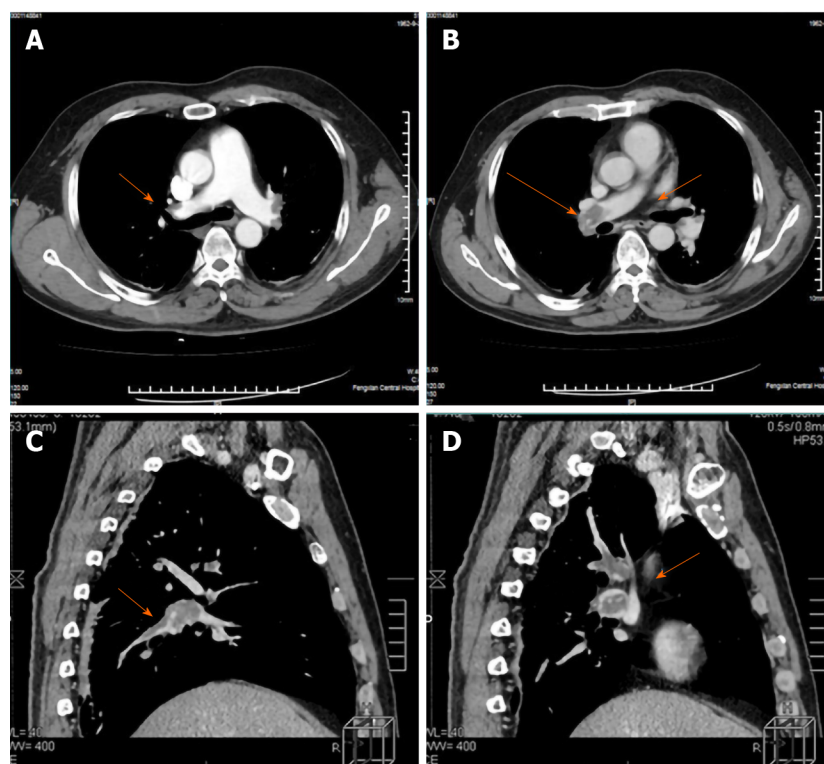


Figure 3 The ninth day after pulmonary thromboembolism, computed tomographic pulmonary angiography showed that the thrombus in both sides of the pulmonary artery did not significantly reduce. A: Horizontal plane showed filling defect in the left and right pulmonary arteries; B: Horizontal plane showed filling defect in the right pulmonary artery; C: Sagittal plane showed filling defect in the right pulmonary artery and its branches; D: Sagittal plane showed filling defect in the left pulmonary artery and its branches.

and the activity of both lower limbs was significantly reduced, resulting in slow movement of the blood in the circulation of both lower limbs.

The patient was a 51-year-old male who weighed 90 kg and was 175 cm tall. His BMI was 29.4 kg/m². Asians and the west people belong to different races. The BMI obesity standard of WHO is not very suitable for Chinese people, so the reference standard of BMI obesity in China is established as BMI ≥ 28 kg/m². The patient was obese. Combined with the above factors, LEDVT and PTE occurred. The case we reported did not have shock symptoms, so we immediately transferred him to the intensive care unit to monitor his vital signs. At the same time, we immediately gave anticoagulant treatment and adjusted the dosage of anticoagulant drugs according to the treatment results. The patient ultimately recovered. For patients with decreased activity of daily living and depression after operation, clinicians should encourage patients to get out of bed early after fracture surgery and give anticoagulation therapy in time if necessary.

CONCLUSION

PTE can occur after distal ulna and radius fracture surgery, and patients with high risk factors should be considered for the prevention and treatment of thrombosis.

REFERENCES

- 1 Wolberg AS, Aleman MM, Leiderman K, Machlus KR. Procoagulant activity in hemostasis and thrombosis: Virchow's triad revisited. *Anesth Analg* 2012; **114**: 275-285 [PMID: 22104070 DOI: 10.1213/ANE.0b013e31823a088c]
- 2 Schleyer AM, Schreuder AB, Jarman KM, Logerfo JP, Goss JR. Adherence to guideline-directed venous thromboembolism prophylaxis among medical and surgical inpatients at 33 academic medical centers in the United States. *Am J Med Qual* 2011; **26**: 174-180 [PMID: 21490270 DOI: 10.1177/1062860610382289]
- 3 Nayar SK, Kuwabara AM, Flores JM, Osgood GM, LaPorte DM, Shafiq B. Venous

- Thromboembolism in Upper Extremity Fractures. *J Hand Surg Asian Pac Vol* 2018; **23**: 320-329 [PMID: [30282549](#) DOI: [10.1142/S2424835518500303](#)]
- 4 **Wells PS**, Ginsberg JS, Anderson DR, Kearon C, Gent M, Turpie AG, Bormanis J, Weitz J, Chamberlain M, Bowie D, Barnes D, Hirsh J. Use of a clinical model for safe management of patients with suspected pulmonary embolism. *Ann Intern Med* 1998; **129**: 997-1005 [PMID: [9867786](#) DOI: [10.7326/0003-4819-129-12-199812150-00002](#)]
 - 5 **Le Gal G**, Righini M, Roy PM, Sanchez O, Aujesky D, Bounameaux H, Perrier A. Prediction of pulmonary embolism in the emergency department: the revised Geneva score. *Ann Intern Med* 2006; **144**: 165-171 [PMID: [16461960](#) DOI: [10.7326/0003-4819-144-3-200602070-00004](#)]
 - 6 **Philbrick JT**, Heim S. The d-dimer test for deep venous thrombosis: gold standards and bias in negative predictive value. *Clin Chem* 2003; **49**: 570-574 [PMID: [12651808](#) DOI: [10.1373/49.4.570](#)]
 - 7 **Johnson SA**, Stevens SM, Woller SC, Lake E, Donadini M, Cheng J, Labarère J, Douketis JD. Risk of deep vein thrombosis following a single negative whole-leg compression ultrasound: a systematic review and meta-analysis. *JAMA* 2010; **303**: 438-445 [PMID: [20124539](#) DOI: [10.1001/jama.2010.43](#)]
 - 8 **van Beek EJ**, Brouwerst EM, Song B, Stein PD, Oudkerk M. Clinical validity of a normal pulmonary angiogram in patients with suspected pulmonary embolism--a critical review. *Clin Radiol* 2001; **56**: 838-842 [PMID: [11895301](#) DOI: [10.1053/crad.2001.0778](#)]
 - 9 **Moore LK**, Jackson WL Jr, Shorr AF, Jackson JL. Meta-analysis: outcomes in patients with suspected pulmonary embolism managed with computed tomographic pulmonary angiography. *Ann Intern Med* 2004; **141**: 866-874 [PMID: [15583229](#) DOI: [10.7326/0003-4819-141-11-200412070-00011](#)]
 - 10 **Konstantinides SV**. 2014 ESC Guidelines on the diagnosis and management of acute pulmonary embolism. *Eur Heart J* 2014; **35**: 3145-3146 [PMID: [25452462](#) DOI: [10.1093/eurheartj/ehu393](#)]
 - 11 **Kearon C**, Akl EA, Ornelas J, Blaivas A, Jimenez D, Bounameaux H, Huisman M, King CS, Morris TA, Sood N, Stevens SM, Vintch JRE, Wells P, Woller SC, Moore L. Antithrombotic Therapy for VTE Disease: CHEST Guideline and Expert Panel Report. *Chest* 2016; **149**: 315-352 [PMID: [26867832](#) DOI: [10.1016/j.chest.2015.11.026](#)]



Published by **Baishideng Publishing Group Inc**
7041 Koll Center Parkway, Suite 160, Pleasanton, CA 94566, USA

Telephone: +1-925-3991568

E-mail: bpgoffice@wjgnet.com

Help Desk: <https://www.f6publishing.com/helpdesk>

<https://www.wjgnet.com>

