

# World Journal of *Clinical Cases*

*World J Clin Cases* 2021 August 6; 9(22): 6178-6581



## Contents

Thrice Monthly Volume 9 Number 22 August 6, 2021

## REVIEW

- 6178** COVID-19 infection and liver injury: Clinical features, biomarkers, potential mechanisms, treatment, and management challenges

*Sivandzadeh GR, Askari H, Safarpour AR, Ejtehad F, Raeis-Abdollahi E, Vaez Lari A, Abazari MF, Tarkesh F, Bagheri Lankarani K*

- 6201** Gastrointestinal manifestations of systemic sclerosis: An updated review

*Luquez-Mindiola A, Atuesta AJ, Gómez-Aldana AJ*

## MINIREVIEWS

- 6218** Mesenchymal stem cell-derived exosomes: An emerging therapeutic strategy for normal and chronic wound healing

*Zeng QL, Liu DW*

- 6234** Role of autophagy in cholangiocarcinoma: Pathophysiology and implications for therapy

*Ninfolle E, Pinto C, Benedetti A, Marziani M, Maroni L*

## ORIGINAL ARTICLE

## Case Control Study

- 6244** Risk factors for intussusception in children with Henoch-Schönlein purpura: A case-control study

*Zhao Q, Yang Y, He SW, Wang XT, Liu C*

## Retrospective Study

- 6254** Sequential therapy with combined trans-papillary endoscopic naso-pancreatic and endoscopic retrograde pancreatic drainage for pancreatic pseudocysts

*He YG, Li J, Peng XH, Wu J, Xie MX, Tang YC, Zheng L, Huang XB*

- 6268** Retrospective study of effect of whole-body vibration training on balance and walking function in stroke patients

*Xie L, Yi SX, Peng QF, Liu P, Jiang H*

- 6278** Risk factors for preoperative carcinogenesis of bile duct cysts in adults

*Wu X, Li BL, Zheng CJ, He XD*

- 6287** Diagnostic and prognostic value of secreted protein acidic and rich in cysteine in the diffuse large B-cell lymphoma

*Pan PJ, Liu JX*

- 6300** Jumbo cup in hip joint renovation may cause the center of rotation to increase

*Peng YW, Shen JM, Zhang YC, Sun JY, Du YQ, Zhou YG*

**Clinical Trials Study**

- 6308** Effect of exercise training on left ventricular remodeling in patients with myocardial infarction and possible mechanisms  
*Cai M, Wang L, Ren YL*

**Observational Study**

- 6319** Analysis of sleep characteristics and clinical outcomes of 139 adult patients with infective endocarditis after surgery  
*Hu XM, Lin CD, Huang DY, Li XM, Lu F, Wei WT, Yu ZH, Liao HS, Huang F, Huang XZ, Jia FJ*
- 6329** Health-related risky behaviors and their risk factors in adolescents with high-functioning autism  
*Sun YJ, Xu LZ, Ma ZH, Yang YL, Yin TN, Gong XY, Gao ZL, Liu YL, Liu J*
- 6343** Selection of internal fixation method for femoral intertrochanteric fractures using a finite element method  
*Mu JX, Xiang SY, Ma QY, Gu HL*

**META-ANALYSIS**

- 6357** Neoadjuvant chemotherapy for patients with resectable colorectal cancer liver metastases: A systematic review and meta-analysis  
*Zhang Y, Ge L, Weng J, Tuo WY, Liu B, Ma SX, Yang KH, Cai H*

**CASE REPORT**

- 6380** Ruptured intracranial aneurysm presenting as cerebral circulation insufficiency: A case report  
*Zhao L, Zhao SQ, Tang XP*
- 6388** Prostatic carcinosarcoma seven years after radical prostatectomy and hormonal therapy for prostatic adenocarcinoma: A case report  
*Huang X, Cai SL, Xie LP*
- 6393** Pyogenic arthritis, pyoderma gangrenosum, and acne syndrome in a Chinese family: A case report and review of literature  
*Lu LY, Tang XY, Luo GJ, Tang MJ, Liu Y, Yu XJ*
- 6403** Malaria-associated secondary hemophagocytic lympho-histiocytosis: A case report  
*Zhou X, Duan ML*
- 6410** Ileal hemorrhagic infarction after carotid artery stenting: A case report and review of the literature  
*Xu XY, Shen W, Li G, Wang XF, Xu Y*
- 6418** Inflammatory myofibroblastic tumor of the pancreatic neck: A case report and review of literature  
*Chen ZT, Lin YX, Li MX, Zhang T, Wan DL, Lin SZ*
- 6428** Management of heterotopic cesarean scar pregnancy with preservation of intrauterine pregnancy: A case report  
*Chen ZY, Zhou Y, Qian Y, Luo JM, Huang XF, Zhang XM*

- 6435** Manifestation of severe pneumonia in anti-PL-7 antisynthetase syndrome and B cell lymphoma: A case report  
*Xu XL, Zhang RH, Wang YH, Zhou JY*
- 6443** Disseminated infection by *Fusarium solani* in acute lymphocytic leukemia: A case report  
*Yao YF, Feng J, Liu J, Chen CF, Yu B, Hu XP*
- 6450** Primary hepatic neuroendocrine tumor – <sup>18</sup>F-fluorodeoxyglucose positron emission tomography/computed tomography findings: A case report  
*Rao YY, Zhang HJ, Wang XJ, Li MF*
- 6457** Malignant peripheral nerve sheath tumor in an elderly patient with superficial spreading melanoma: A case report  
*Yang CM, Li JM, Wang R, Lu LG*
- 6464** False positive anti-hepatitis A virus immunoglobulin M in autoimmune hepatitis/primary biliary cholangitis overlap syndrome: A case report  
*Yan J, He YS, Song Y, Chen XY, Liu HB, Rao CY*
- 6469** Successful totally laparoscopic right trihepatectomy following conversion therapy for hepatocellular carcinoma: A case report  
*Zhang JJ, Wang ZX, Niu JX, Zhang M, An N, Li PF, Zheng WH*
- 6478** Primary small cell esophageal carcinoma, chemotherapy sequential immunotherapy: A case report  
*Wu YH, Zhang K, Chen HG, Wu WB, Li XJ, Zhang J*
- 6485** Subdural fluid collection rather than meningitis contributes to hydrocephalus after cervical laminoplasty: A case report  
*Huang HH, Cheng ZH, Ding BZ, Zhao J, Zhao CQ*
- 6493** Phlegmonous gastritis developed during chemotherapy for acute lymphocytic leukemia: A case report  
*Saito M, Morioka M, Izumiyama K, Mori A, Ogasawara R, Kondo T, Miyajima T, Yokoyama E, Tanikawa S*
- 6501** Spinal epidural hematoma after spinal manipulation therapy: Report of three cases and a literature review  
*Liu H, Zhang T, Qu T, Yang CW, Li SK*
- 6510** Abdominal hemorrhage after peritoneal dialysis catheter insertion: A rare cause of luteal rupture: A case report  
*Gan LW, Li QC, Yu ZL, Zhang LL, Liu Q, Li Y, Ou ST*
- 6515** Concealed mesenteric ischemia after total knee arthroplasty: A case report  
*Zhang SY, He BJ, Xu HH, Xiao MM, Zhang JJ, Tong PJ, Mao Q*
- 6522** Chylothorax following posterior low lumbar fusion surgery: A case report  
*Huang XM, Luo M, Ran LY, You XH, Wu DW, Huang SS, Gong Q*
- 6531** Non-immune hydrops fetalis: Two case reports  
*Maranto M, Cigna V, Orlandi E, Cucinella G, Lo Verso C, Duca V, Picciotto F*

- 6538** Bystander effect and abscopal effect in recurrent thymic carcinoma treated with carbon-ion radiation therapy: A case report  
*Zhang YS, Zhang YH, Li XJ, Hu TC, Chen WZ, Pan X, Chai HY, Ye YC*
- 6544** Management of an intracranial hypotension patient with diplopia as the primary symptom: A case report  
*Wei TT, Huang H, Chen G, He FF*
- 6552** Spontaneous rupture of adrenal myelolipoma as a cause of acute flank pain: A case report  
*Kim DS, Lee JW, Lee SH*
- 6557** Neonatal necrotizing enterocolitis caused by umbilical arterial catheter-associated abdominal aortic embolism: A case report  
*Huang X, Hu YL, Zhao Y, Chen Q, Li YX*
- 6566** Primary mucosa-associated lymphoid tissue lymphoma in the midbrain: A case report  
*Zhao YR, Hu RH, Wu R, Xu JK*
- 6575** Extensive cutaneous metastasis of recurrent gastric cancer: A case report  
*Chen JW, Zheng LZ, Xu DH, Lin W*

**ABOUT COVER**

Editorial Board Member of *World Journal of Clinical Cases*, Salma Ahi, MD, Assistant Professor, Research Center for Noncommunicable Diseases, Jahrom University of Medical Sciences, Jahrom 193, Iran. salmaahi.61@gmail.com

**AIMS AND SCOPE**

The primary aim of *World Journal of Clinical Cases* (WJCC, *World J Clin Cases*) is to provide scholars and readers from various fields of clinical medicine with a platform to publish high-quality clinical research articles and communicate their research findings online.

WJCC mainly publishes articles reporting research results and findings obtained in the field of clinical medicine and covering a wide range of topics, including case control studies, retrospective cohort studies, retrospective studies, clinical trials studies, observational studies, prospective studies, randomized controlled trials, randomized clinical trials, systematic reviews, meta-analysis, and case reports.

**INDEXING/ABSTRACTING**

The WJCC is now indexed in Science Citation Index Expanded (also known as SciSearch®), Journal Citation Reports/Science Edition, Scopus, PubMed, and PubMed Central. The 2021 Edition of Journal Citation Reports® cites the 2020 impact factor (IF) for WJCC as 1.337; IF without journal self cites: 1.301; 5-year IF: 1.742; Journal Citation Indicator: 0.33; Ranking: 119 among 169 journals in medicine, general and internal; and Quartile category: Q3. The WJCC's CiteScore for 2020 is 0.8 and Scopus CiteScore rank 2020: General Medicine is 493/793.

**RESPONSIBLE EDITORS FOR THIS ISSUE**

Production Editor: Yan-Xia Xing; Production Department Director: Yun-Jie Ma; Editorial Office Director: Jin-Lei Wang.

**NAME OF JOURNAL**

*World Journal of Clinical Cases*

**ISSN**

ISSN 2307-8960 (online)

**LAUNCH DATE**

April 16, 2013

**FREQUENCY**

Thrice Monthly

**EDITORS-IN-CHIEF**

Dennis A Bloomfield, Sandro Vento, Bao-Gan Peng

**EDITORIAL BOARD MEMBERS**

<https://www.wjgnet.com/2307-8960/editorialboard.htm>

**PUBLICATION DATE**

August 6, 2021

**COPYRIGHT**

© 2021 Baishideng Publishing Group Inc

**INSTRUCTIONS TO AUTHORS**

<https://www.wjgnet.com/bpg/gerinfo/204>

**GUIDELINES FOR ETHICS DOCUMENTS**

<https://www.wjgnet.com/bpg/GerInfo/287>

**GUIDELINES FOR NON-NATIVE SPEAKERS OF ENGLISH**

<https://www.wjgnet.com/bpg/gerinfo/240>

**PUBLICATION ETHICS**

<https://www.wjgnet.com/bpg/GerInfo/288>

**PUBLICATION MISCONDUCT**

<https://www.wjgnet.com/bpg/gerinfo/208>

**ARTICLE PROCESSING CHARGE**

<https://www.wjgnet.com/bpg/gerinfo/242>

**STEPS FOR SUBMITTING MANUSCRIPTS**

<https://www.wjgnet.com/bpg/GerInfo/239>

**ONLINE SUBMISSION**

<https://www.f6publishing.com>

# Ruptured intracranial aneurysm presenting as cerebral circulation insufficiency: A case report

Long Zhao, Shuang-Quan Zhao, Xiao-Ping Tang

**ORCID number:** Long Zhao 0000-0002-2209-2810; Shuang-Quan Zhao 0000-0003-4020-8132; Xiao-Ping Tang 0000-0002-7630-4735.

**Author contributions:** Zhao L, Zhao SQ contributed equally to this work. Zhao L and Zhao SQ designed this work, analyzed the data, and wrote the manuscript; Zhao SQ collected the patient's clinical data; Tang XP and Zhao L performed the surgery; Tang XP designed and reviewed this paper; all authors have read and approved the final version of this manuscript.

**Supported by** the Science and Technology Planning Project of Sichuan, No. 2011JY0062.

**Informed consent statement:** Written informed consent was obtained from the patient for publication of this case report and any accompanying images.

**Conflict-of-interest statement:** The authors declare that they have no conflict of interest to report.

**CARE Checklist (2016) statement:** The authors have read the CARE Checklist (2016), and the manuscript was prepared and revised according to the CARE Checklist (2016).

**Open-Access:** This article is an

**Long Zhao, Xiao-Ping Tang,** Department of Neurosurgery, The Affiliated Hospital of North Sichuan Medical College, Nanchong 637000, Sichuan Province, China

**Shuang-Quan Zhao,** Department of Emergency Medicine, The Affiliated Hospital of North Sichuan Medical College, Nanchong 637000, Sichuan Province, China

**Corresponding author:** Xiao-Ping Tang, MD, Chief Doctor, Department of Neurosurgery, The Affiliated Hospital of North Sichuan Medical College, No. 63 Wenhua Road, Nanchong 637000, Sichuan Province, China. [nsmc\\_txping1971@163.com](mailto:nsmc_txping1971@163.com)

## Abstract

### BACKGROUND

Rupture of an intracranial aneurysm is a type of acute stroke that is a serious threat to human health. Misdiagnosis of ruptured intracranial aneurysms is a serious clinical event that may have disastrous consequences in some patients. To date, ruptured intracranial aneurysms have been misdiagnosed as meningitis, tumors, stroke, or trauma, among other conditions. Here, we report what appears to be the first case of a ruptured intracranial aneurysm that presented as cerebral circulation insufficiency.

### CASE SUMMARY

A middle-aged man was admitted to our hospital because of a parasellar lesion identified on a noncontrast computed tomography (CT) image after a mild traffic accident that was caused by a brief loss of consciousness. Notably, he was diagnosed with cerebral circulation insufficiency after two unexplained episodes of a transient loss of consciousness within the past 8 mo. The patient was diagnosed with right internal carotid artery aneurysm based on CT angiography and completely recovered after a craniotomy at our hospital. A few clots and severe adhesions around the aneurysm were observed in the subarachnoid space during the operation, suggesting that the aneurysm had ruptured and may have been misdiagnosed as cerebral circulation insufficiency.

### CONCLUSION

Ruptured intracranial aneurysms may show negative imaging results and present as cerebral circulation insufficiency, which should be recognized as soon as possible to ensure timely management.

**Key Words:** Intracranial aneurysm; Misdiagnosis; Cerebral circulation insufficiency; Case

open-access article that was selected by an in-house editor and fully peer-reviewed by external reviewers. It is distributed in accordance with the Creative Commons Attribution NonCommercial (CC BY-NC 4.0) license, which permits others to distribute, remix, adapt, build upon this work non-commercially, and license their derivative works on different terms, provided the original work is properly cited and the use is non-commercial. See: <http://creativecommons.org/licenses/by-nc/4.0/>

**Manuscript source:** Unsolicited manuscript

**Specialty type:** Clinical neurology

**Country/Territory of origin:** China

**Peer-review report's scientific quality classification**

Grade A (Excellent): 0  
Grade B (Very good): B  
Grade C (Good): 0  
Grade D (Fair): 0  
Grade E (Poor): 0

**Received:** February 6, 2021

**Peer-review started:** February 6, 2021

**First decision:** April 25, 2021

**Revised:** May 5, 2021

**Accepted:** May 27, 2021

**Article in press:** May 27, 2021

**Published online:** August 6, 2021

**P-Reviewer:** Matowicka-Karna J

**S-Editor:** Gong ZM

**L-Editor:** Wang TQ

**P-Editor:** Liu JH



report

©The Author(s) 2021. Published by Baishideng Publishing Group Inc. All rights reserved.

**Core Tip:** This paper reports a case of ruptured intracranial aneurysm presenting as cerebral circulation insufficiency. Furthermore, the causes of misdiagnosis and experiences about the diagnosis and management are discussed by literature review. To the best of our knowledge, this is the first report of intracranial aneurysmal rupture presenting as cerebral circulation insufficiency. Our report also demonstrates a rare case of short-term dilated intracranial cystic aneurysm.

**Citation:** Zhao L, Zhao SQ, Tang XP. Ruptured intracranial aneurysm presenting as cerebral circulation insufficiency: A case report. *World J Clin Cases* 2021; 9(22): 6380-6387

**URL:** <https://www.wjgnet.com/2307-8960/full/v9/i22/6380.htm>

**DOI:** <https://dx.doi.org/10.12998/wjcc.v9.i22.6380>

## INTRODUCTION

Subarachnoid hemorrhage (SAH) is the most common form of ruptured intracranial aneurysm and has clinical presentations that range from a simple headache to obvious neurological deficits. SAH is easily suspected and diagnosed based on imaging findings in patients who present with sudden severe headaches, vomiting, disturbance of consciousness, and other typical clinical manifestations. However, a small number of patients may have extremely rare clinical or imaging manifestations, leading to a difficulty in determining the diagnosis or even misdiagnosis. Due to atypical clinical or imaging manifestations, ruptured intracranial aneurysms have been reported to be misdiagnosed as meningitis, tumors, stroke, or trauma, among other conditions[1-3]. Here, we report what appears to be the first case of a ruptured intracranial aneurysm presenting as cerebral circulation insufficiency. The literature on the misdiagnosis of intracranial aneurysms with atypical clinical manifestations is reviewed.

## CASE PRESENTATION

### Chief complaints

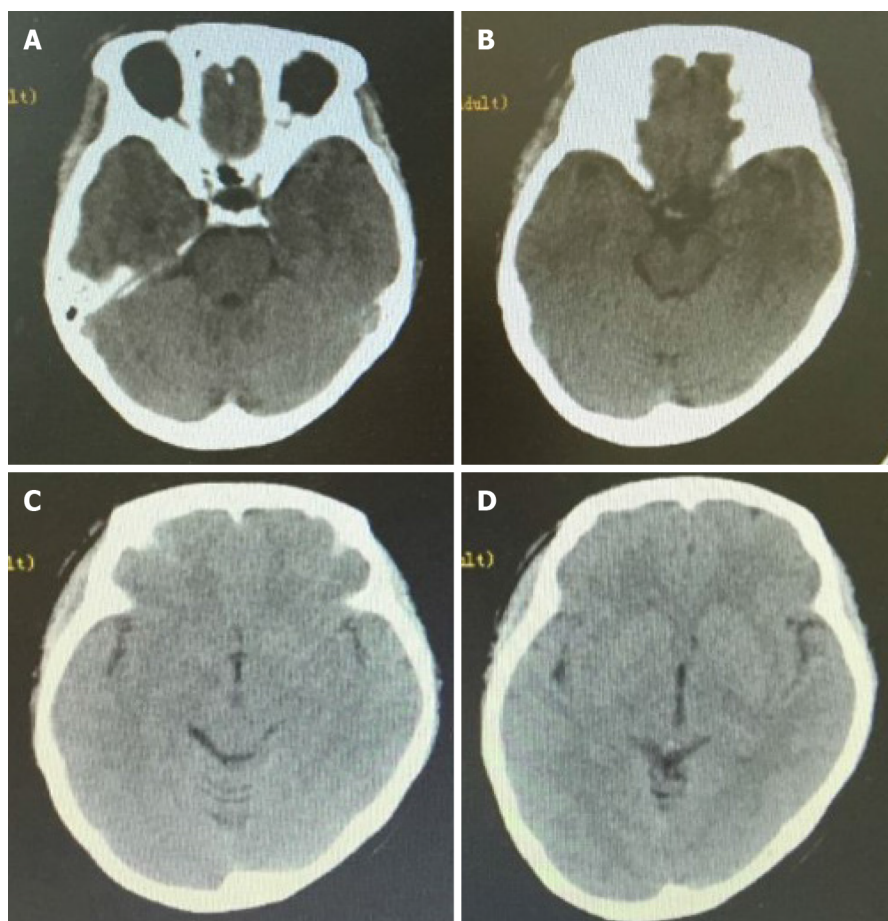
A 45-year-old man was admitted to our hospital with recurrent transient losses of consciousness and a serendipitous parasellar lesion.

### History of present illness

According to his account, the patient had suffered three brief periods (tens of seconds) of an unexplained loss of consciousness within 8 mo. No attack was accompanied by headaches, vomiting, or convulsions. On the first two occasions, he was admitted to two local hospitals and underwent repeated noncontrast computed tomography (CT) scans (Figure 1), electroencephalograms, electrocardiograms, carotid ultrasound, cardiac ultrasound, transcranial Doppler, and measurements of blood glucose, blood lipid, and hemoglobin levels. Since no abnormality was detected in the previous examinations, he was diagnosed with and treated for cerebral circulation insufficiency twice. During the last event, the patient had suddenly lost consciousness for tens of seconds while riding a motorcycle and caused an accident. An emergency CT scan did not reveal subarachnoid hemorrhage (SAH), but unexpectedly showed an abnormal density on the right side of the sella while the patient received trauma-related treatment at the nearest emergency center (Figure 2). Therefore, he was advised to go to a superior hospital.

### History of past illness

This patient did not have a history of cardio-cerebrovascular diseases or neurological diseases.



**Figure 1** First head computed tomography images. A: No abnormal density lesion was found near the parasellar region; B: No abnormal density lesion or subarachnoid hemorrhage was observed in the suprasellar cistern and annular cistern; C and D: No obvious subarachnoid hemorrhage was observed in any sulci or cistern.

### **Personal and family history**

The patient denied a family history of hypertension, stroke, or psychiatric disorders.

### **Physical examination**

Upon admission, no abnormalities in the central nervous system were identified.

### **Laboratory examinations**

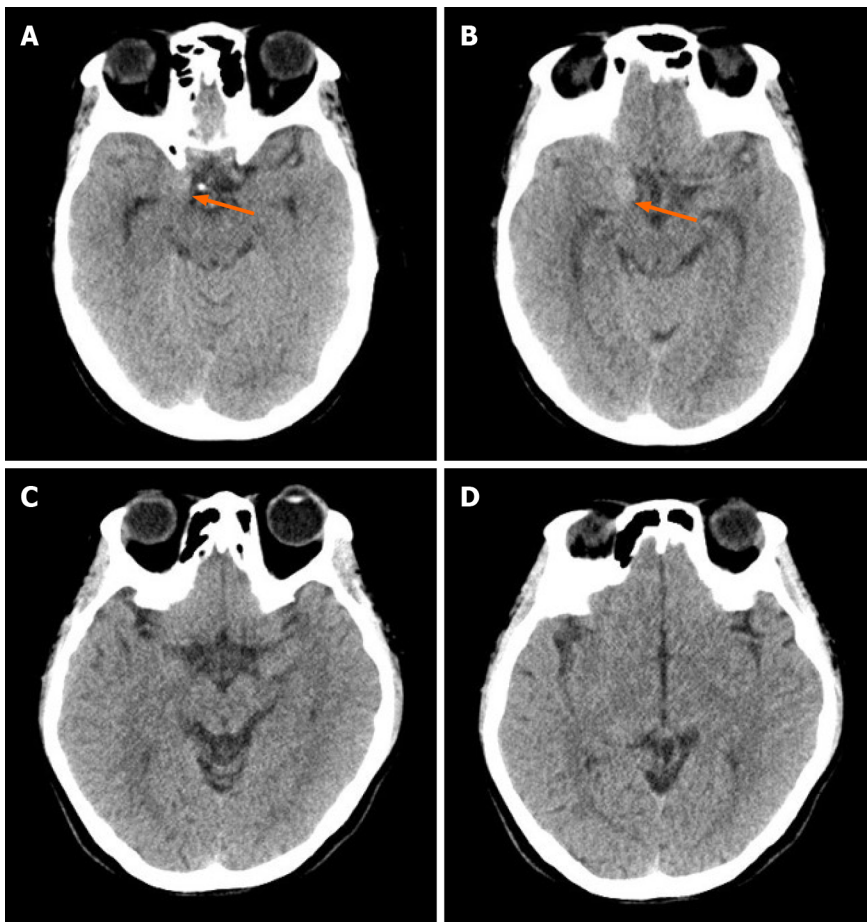
Upon admission, the patient underwent a blood cell analysis and examinations of blood electrolyte, blood glucose, blood lipid, liver function, renal function, and adenohipophysial hormone levels. The test results were all normal, except for a slight increase in the white blood cell count ( $11.56 \times 10^9/L$ ) and neutrophil count ( $6.65 \times 10^9/L$ ).

### **Imaging examinations**

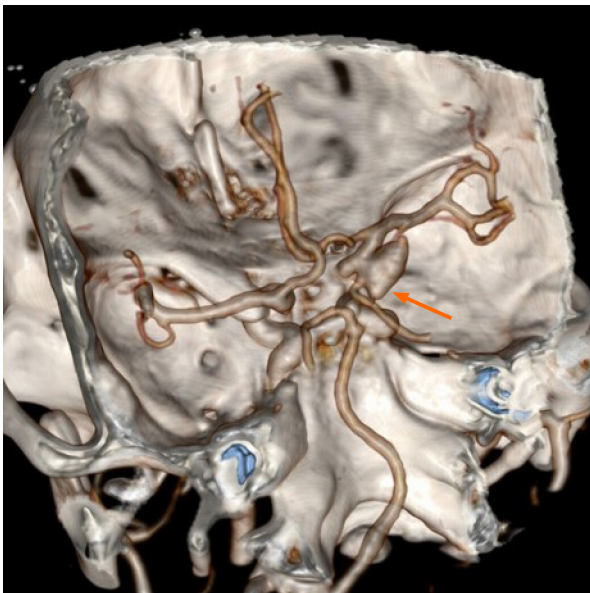
CT angiography (CTA) was performed immediately and revealed a morphologically irregular cystic aneurysm of the right internal carotid artery. The aneurysm had multiple sacs pointing in different directions, and the longest diameter of the aneurysm was approximately 11 mm (Figure 3).

## **FINAL DIAGNOSIS**

The patient was ultimately diagnosed with an aneurysm in the right internal carotid artery. According to the characteristics of aneurysmal images, the aneurysm was judged to be prone to bleeding.



**Figure 2 Head computed tomography at admission.** A and B: A lesion with an abnormal density (orange arrow) was observed on the right side of the parasellar region; C and D: No obvious subarachnoid hemorrhage was observed in any sulci or cistern.



**Figure 3 Preoperative computed tomography angiogram.** A 5 mm × 11 mm aneurysm in the right internal carotid artery (orange arrow) was detected.

## TREATMENT

The patient was treated by a pterional craniotomy and clipping of the aneurysm neck under general anesthesia on the fifth day after the accident. During the operation, we observed a few scattered blood clots in the subarachnoid space, obvious adhesions

around the aneurysm neck and sac, and a definite crevasse at the location of the aneurysmal apex. After the aneurysm neck was carefully separated and exposed, an arc-shaped aneurysm clip was used to close the aneurysmal neck away from the internal carotid artery. We temporarily blocked the internal carotid artery and adjusted the clip many times to completely clip the aneurysm neck and protect the posterior communicating artery, but the aneurysm did not rupture. Therefore, we confirmed that the aneurysm was a saccular “true” aneurysm that had ruptured before.

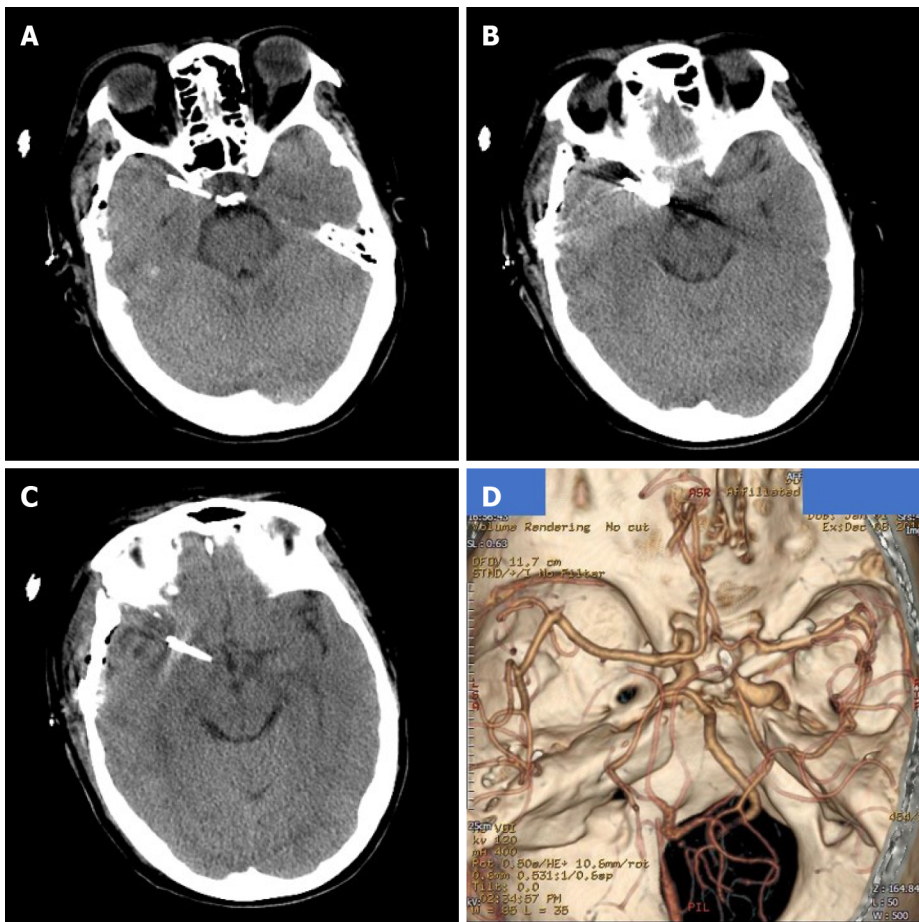
## OUTCOME AND FOLLOW-UP

The patient completely recovered and was discharged without neurological deficits after 14 d. Both noncontrast CT (Figure 4A-C) and CTA images (Figure 4D) recorded before discharge showed satisfactory results. The 6-mo telephone follow-up revealed a good prognosis.

## DISCUSSION

The rate of aneurysmal misdiagnosis reported in the literature has decreased from as high as 25% 20 years ago to 1.14% recently[4,5]. However, once misdiagnosed, aneurysmal rebleeding may cause very serious consequences and even death, and clinicians should therefore still focus on the occurrence of an aneurysmal misdiagnosis. Regarding the reasons for the misdiagnosis of ruptured intracranial aneurysms, a retrospective analysis of 2898 patients with aneurysmal SAH performed by Oh *et al*[5] showed that patients who presented with an initially good Hunt-Hess grade and a lower Fisher’s grade who were visiting non-teaching hospital for their initial contact were at risk of being misdiagnosed. The conclusions of the studies by Takagi *et al*[6] and Inagawa *et al*[7] are also consistent with this hypothesis. In addition, ruptured intracranial aneurysms are often misdiagnosed and missed because they are combined with craniocerebral trauma. Between 2.8% and 28% of ruptured aneurysms may be associated with a traumatic brain injury, and in a large series, SAH was detected in 39% of 753 patients with a severe head injury[8,9]. However, the relationship between trauma and the rupture of the aneurysm is controversial, and a causal relationship might be difficult to ascertain. The relationships between head injury and pre-existing aneurysms are summarized below. First, the rupture of the aneurysm causes the trauma. Second, a head impact causes the rupture of the aneurysm. Third, an unruptured aneurysm is incidentally discovered during the evaluation of head trauma. Kim *et al*[10] suggested that from the perspective of CT findings, SAH in the basal cisterns extended into the bilateral sylvian fissures and anterior interhemispheric fissure, and SAH in the unilateral sylvian fissure or associated with intraparenchymal hemorrhage identified on the initial CT scan might predict the rupture of a pre-existing cerebral aneurysm.

In our case, no obvious SAH was observed on either CT scan after the first two episodes, and the patient was misdiagnosed with cerebral circulatory dysfunction twice. However, according to the intraoperative conditions and the final diagnosis, the possibility of aneurysm rupture should have been considered in the first two attacks. Another hypothesis is that the patient experienced premonitory symptoms of the rupture of intracranial aneurysms twice. We were unable to clearly determine whether SAH was not present on these CT scans. According to the literature, in addition to equipment factors, some minor signs of SAH may be ignored by inexperienced clinical or imaging doctors who may, for example, misread the presence of a low level of hemorrhaging, fissure or sulci obliteration, or both low levels of hemorrhaging and fissure obliteration[5]. After the third episode, a lesion with an abnormal density was observed on the right side of the sella that had not been detected on the previous two CT scans. We speculate that the patient may have experienced a rare sudden enlargement of the aneurysm after the second onset of symptoms, as previously described by Miller *et al*[11] and Khan *et al*[12]. Previous reports of the rapid growth of cystic aneurysms show that this condition often occurs in patients with atrial myxoma, inflammatory aneurysms, drug abuse, and blood vesicular aneurysms[13-16], and its causes have been reported to be related to pregnancy, surgery, hypertension, and sex [17,18]. However, all of the aforementioned factors were excluded based on the patient’s medical history, except a suspicious history of trauma. Moreover, the relationship between the rapid growth of the aneurysms and trauma is uncertain.



**Figure 4 Postoperative imaging data.** A-C: Noncontrast computed tomography (CT) images showing normal postoperative appearance; D: CT angiogram showing that the previous aneurysm is no longer visible.

Based on the available information, we were unable to clearly determine whether the sudden enlargement of the aneurysm was caused by trauma or led to the trauma.

In general, the possibility of traumatic aneurysms should be considered when intracranial aneurysms are detected after head trauma in patients with no positive results on previous CT scans. However, in our patient, an intracranial aneurysm was detected on a CT examination performed within 24 h, and no clinical symptoms or imaging findings indicating a skull base fracture were identified after injury. In addition, we observed a gap between the aneurysm, the cavernous sinus, and the anterior bed process on the CTA scan. None of the information presented above supported a preoperative diagnosis of a traumatic aneurysm. The intraoperative findings also confirmed our diagnosis. Traumatic aneurysms account for less than 1% of all intracranial aneurysms, and its incidence is slightly higher in adolescent and infant patients than in adults[19]. Traumatic pseudoaneurysms are usually associated with blunt or shearing forces on a vessel lying against a fixed surface, such as the skull base, or due to a direct injury over the convex surface of the skull, and always present a unique challenge during both the diagnosis and treatment phases. The average time from the initial trauma to the onset of traumatic aneurysm bleeding is approximately 3 wk[20]. Due to the absence of a neck, the presence of a poorly defined wall, and the association of arachnoid adhesions in the former, traumatic aneurysms are more likely to rupture during surgical clipping than a congenital aneurysm[21]. Surgical intervention is needed as soon as a traumatic aneurysm is diagnosed. Surgery has been shown to reduce the mortality rate of patients with posttraumatic aneurysms from 40-50% to 18%[22]. To our knowledge, very few studies have compared the outcomes of surgical clipping with endovascular occlusion in patients with these aneurysms. Due to the atypical characteristics of these aneurysms, treatment should be individualized.

## CONCLUSION

To the best of our knowledge, this case study is the first to report a patient with an intracranial aneurysmal rupture presenting as cerebral circulation insufficiency. Our report also describes a rare case of short-term dilated intracranial cystic aneurysm. Consistent with previous reports, mild clinical symptom is an important cause of misdiagnosis and missed diagnosis, while a combined history of trauma increases the difficulty of determining a differential diagnosis. A detailed understanding of the trauma process and imaging data is very important to achieve a timely and correct diagnosis. In addition, active CTA screening in patients with suspected SAH is helpful to avoid missing intracranial aneurysms.

## REFERENCES

- 1 **Michael PG**, Jamkhandikar RM, Memon IK, Al-Saadi T, Al-Aghbari S, Al-Muqaimi M, Ansari M, Al-Shamakhi A, Ahmad A. Unusual Case of an Intracranial Aneurysm Misdiagnosed as Focal Basal Meningitis. *Sultan Qaboos Univ Med J* 2017; **17**: e363-e365 [PMID: [29062565](#) DOI: [10.18295/squmj.2017.17.03.020](#)]
- 2 **Song SY**, Kim DW, Park JT, Kang SD. Delayed Rebleeding of Cerebral Aneurysm Misdiagnosed as Traumatic Subarachnoid Hemorrhage. *J Cerebrovasc Endovasc Neurosurg* 2016; **18**: 253-257 [PMID: [27847770](#) DOI: [10.7461/jcen.2016.18.3.253](#)]
- 3 **Xu K**, Yuan Y, Zhou J, Yu J. Pituitary adenoma apoplexy caused by rupture of an anterior communicating artery aneurysm: case report and literature review. *World J Surg Oncol* 2015; **13**: 228 [PMID: [26220796](#) DOI: [10.1186/s12957-015-0653-z](#)]
- 4 **Mayer PL**, Awad IA, Todor R, Harbaugh K, Varnavas G, Lansen TA, Dickey P, Harbaugh R, Hopkins LN. Misdiagnosis of symptomatic cerebral aneurysm. Prevalence and correlation with outcome at four institutions. *Stroke* 1996; **27**: 1558-1563 [PMID: [8784130](#) DOI: [10.1161/01.str.27.9.1558](#)]
- 5 **Oh SY**, Lim YC, Shim YS, Song J, Park SK, Sim SY, Kim MJ, Shin YS, Chung J. Initial misdiagnosis of aneurysmal subarachnoid hemorrhage: associating factors and its prognosis. *Acta Neurochir (Wien)* 2018; **160**: 1105-1113 [PMID: [29675720](#) DOI: [10.1007/s00701-018-3552-6](#)]
- 6 **Takagi Y**, Hadeishi H, Mineharu Y, Yoshida K, Ogasawara K, Ogawa A, Miyamoto S. Initially Missed or Delayed Diagnosis of Subarachnoid Hemorrhage: A Nationwide Survey of Contributing Factors and Outcomes in Japan. *J Stroke Cerebrovasc Dis* 2018; **27**: 871-877 [PMID: [29217366](#) DOI: [10.1016/j.jstrokecerebrovasdis.2017.10.024](#)]
- 7 **Inagawa T**. Delayed diagnosis of aneurysmal subarachnoid hemorrhage in patients: a community-based study. *J Neurosurg* 2011; **115**: 707-714 [PMID: [21682568](#) DOI: [10.3171/2011.5.JNS102157](#)]
- 8 **Hsieh CT**, Lin EY, Tsai TH, Chiang YH, Ju DT. Delayed rupture of pre-existing cerebral aneurysm in a young patient with minor head trauma. *J Clin Neurosci* 2007; **14**: 1120-1122 [PMID: [17954376](#) DOI: [10.1016/j.jocn.2006.03.014](#)]
- 9 **Eisenberg HM**, Gary HE Jr, Aldrich EF, Saydjari C, Turner B, Foulkes MA, Jane JA, Marmarou A, Marshall LF, Young HF. Initial CT findings in 753 patients with severe head injury. A report from the NIH Traumatic Coma Data Bank. *J Neurosurg* 1990; **73**: 688-698 [PMID: [2213158](#) DOI: [10.3171/jns.1990.73.5.0688](#)]
- 10 **Kim YO**, Kim GT, Choi HJ. Prediction of Rupture of Pre-existing Cerebral Aneurysm by CT Findings in Patients with Traumatic Brain Injury. *J Korean Soc Emerg Med* 2014; **25**: 602-610
- 11 **Miller NR**, Savino PJ, Schneider T. Rapid growth of an intracranial aneurysm causing apparent retrobulbar optic neuritis. *J Neuroophthalmol* 1995; **15**: 212-218 [PMID: [8748557](#)]
- 12 **Khan RB**, Laster RE, Bertorini TE. Rapid growth of a basilar aneurysm. *Am J Med Sci* 2000; **320**: 281-285 [PMID: [11061355](#) DOI: [10.1097/00000441-200010000-00010](#)]
- 13 **Suzuki T**, Nagai R, Yamazaki T, Shiojima I, Maemura K, Yamaoki K, Tanaka N, Machida T, Kotsuka Y, Furuse A. Rapid growth of intracranial aneurysms secondary to cardiac myxoma. *Neurology* 1994; **44**: 570-571 [PMID: [8145937](#) DOI: [10.1212/wnl.44.3\\_part\\_1.570](#)]
- 14 **Lee CC**, Hsieh TC, Wang YC, Lo YL, Lee ST, Yang TC. Ruptured symptomatic internal carotid artery dorsal wall aneurysm with rapid configurational change. Clinical experience and management outcome: an original article. *Eur J Neurol* 2010; **17**: 1277-1284 [PMID: [20831774](#) DOI: [10.1111/j.1468-1331.2010.03029.x](#)]
- 15 **Koffie RM**, Stapleton CJ, Torok CM, Yoo AJ, Leslie-Mazwi TM, Codd PJ. Rapid growth of an infectious intracranial aneurysm with catastrophic intracranial hemorrhage. *J Clin Neurosci* 2015; **22**: 603-605 [PMID: [25455738](#) DOI: [10.1016/j.jocn.2014.09.007](#)]
- 16 **Fowler J**, Fiani B, Quadri SA, Cortez V, Frooqui M, Zafar A, Ahmed FS, Ikram A, Ramachandran A, Siddiqi J. Impact of Methamphetamine Abuse: A Rare Case of Rapid Cerebral Aneurysm Growth with Review of Literature. *Case Rep Neurol Med* 2018; **2018**: 1879329 [PMID: [30402309](#) DOI: [10.1155/2018/1879329](#)]
- 17 **Anda T**, Yonekura M, Baba H, Suyama K, Toda K, Kamada K, Ono T, Yoshida K, Baba S, Onizuka M. Factors affecting rapid growth of unruptured cerebral aneurysms during the acute stage of subarachnoid hemorrhage. *Neurol Res* 2006; **28**: 165-171 [PMID: [16551434](#) DOI: [10.1185/095026880600000100](#)]

- 10.1179/016164105X48806]
- 18 **Prandini MN**, Lacanna SN, Tella OI, Bonatelli AP. Aneurysm growth after brain tumor removal: case report. *Arg Neuropsiquiatr* 2004; **62**: 722-724 [PMID: [15334238](#) DOI: [10.1590/s0004-282x2004000400029](#)]
- 19 **Bhaisora KS**, Behari S, Godbole C, Phadke RV. Traumatic aneurysms of the intracranial and cervical vessels: A review. *Neurol India* 2016; **64** Suppl: S14-S23 [PMID: [26954962](#) DOI: [10.4103/0028-3886.178032](#)]
- 20 **Holmes B**, Harbaugh RE. Traumatic intracranial aneurysms: A contemporary review. *J Trauma* 1993; **35**: 855-860 [PMID: [8263982](#)]
- 21 **Levy ML**, Rezai A, Masri LS, Litofsky SN, Giannotta SL, Apuzzo ML, Weiss MH. The significance of subarachnoid hemorrhage after penetrating craniocerebral injury: correlations with angiography and outcome in a civilian population. *Neurosurgery* 1993; **32**: 532-540 [PMID: [8474643](#) DOI: [10.1227/00006123-199304000-00007](#)]
- 22 **Mao Z**, Wang N, Hussain M, Li M, Zhang H, Zhang Q, Zhang P, Zhi X, Ling F. Traumatic intracranial aneurysms due to blunt brain injury-a single center experience. *Acta Neurochir (Wien)* 2012; **154**: 2187-2193; discussion 2193 [PMID: [22975866](#) DOI: [10.1007/s00701-012-1487-x](#)]



Published by **Baishideng Publishing Group Inc**  
7041 Koll Center Parkway, Suite 160, Pleasanton, CA 94566, USA

**Telephone:** +1-925-3991568

**E-mail:** [bpgoffice@wjgnet.com](mailto:bpgoffice@wjgnet.com)

**Help Desk:** <https://www.f6publishing.com/helpdesk>

<https://www.wjgnet.com>

