

16

Name of Journal: *World Journal of Clinical Cases***Manuscript NO:** 57767**Manuscript Type:** CASE REPORT**Endoscopic resection of benign esophageal schwannoma; A case report and review of literature**

Bin Li, Xue Wang, Wen-Lu Zou, Shu-Xia Yu, Yong Chen, Hong-Wei Xu

Match Overview

1

Internet 93 words
www.ncbi.nlm.nih.gov

3%

2

Crossref 77 words
Bin Li, Juan Liu, Yingju Lu, Jinghua Hao, Hui Liu, Junmei Ji ang, Ying Jiang, Chengyong Qin, Hongwei Xu. "Submucos

2%

3

Crossref 56 words
Hong-wei Xu, Qi Zhao, Shu-xia Yu, Ying Jiang, Jing-hua H ao, Bin Li. "Comparison of different endoscopic resection te

2%

4

Internet 55 words
crawled on 05-Jul-2020
surgicalcasereports.springeropen.com

2%

5

Internet 37 words
crawled on 26-Jun-2016
www.pagepress.org

1%

6

Internet 22 words
crawled on 05-May-2016

1%



ALL

IMAGES

VIDEOS

182,000 Results

Any time ▾

Resection of an esophageal schwannoma with thoracoscopic ...

<https://www.ncbi.nlm.nih.gov/pmc/articles/PMC5099309>

The incidence of **benign** primary tumors of the **esophagus** is low. The most common histological type is leiomyoma; the incidence of **schwannoma** among **benign** tumors is low [1–5]. **Esophageal schwannomas** are difficult to definitively diagnose by biopsy because they are located in ...

Cited by: 8

Author: Takayoshi Watanabe, Tatsuya Miyazaki, ...

Publish Year: 2016

Resection of an esophageal schwannoma with thoracoscopic ...

<https://surgicalcasereports.springeropen.com/articles/10.1186/s40792-016-0256-0> ▾

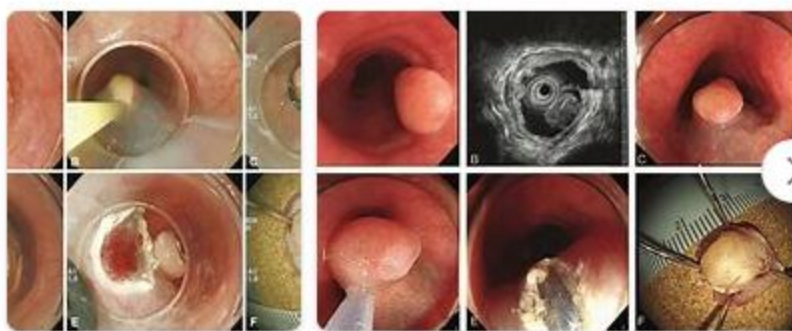
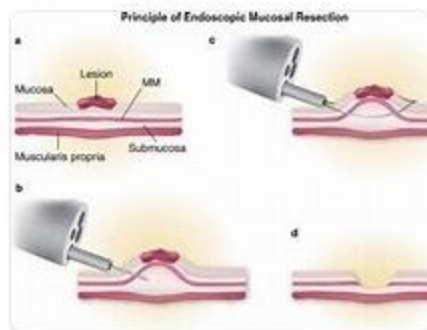
Nov 07, 2016 · **Esophageal schwannomas** are rare primary submucosal **esophageal** tumors. We herein report a case of an **esophageal schwannoma** that was difficult to diagnose. A 39-year-old woman presented with chief complaints of difficulty swallowing and epigastric pain. Enhanced computed tomography of her chest revealed a tumor mass at the upper thoracic **esophagus** with internal ...

Cited by: 8

Author: Takayoshi Watanabe, Tatsuya Miyazaki, ...

Publish Year: 2016

Images of Endoscopic resection of Benign esophageal schwa...

<bing.com/images>[See all images >](#)

Endoscopic resection of benign esophageal schwannoma; A case r



ALL

IMAGES

VIDEOS

41,000 Results

Any time ▼

[Benign esophageal schwannoma: A case report and review ...](#)

www.njcponline.com/article.asp?issn=1119-3077;year=...

The incidence of **benign** primary tumors of the **esophagus** is low and accounting for ~2% of all **esophageal** tumors. More than 80% of **benign esophageal** tumors are leiomyomas and schwannomas and are extremely rare. We **report** a **case** of a 55-year-old woman with **benign esophageal** schwannoma successfully treated with subtotal esophagectomy.

Cited by: 2

Author: L Zhu, W Li, Z Zhu, Y Chai

Publish Year: 2019

[Resection of an esophageal schwannoma with thoracoscopic ...](#)

<https://www.ncbi.nlm.nih.gov/pmc/articles/PMC5099309>

The most common **benign** submucosal **esophageal** tumor is leiomyoma. According to previous reports, leiomyoma accounts for more than half of all **benign esophageal** tumors [1, 2]. **Benign** submucosal **esophageal** tumors also include lipomas, granular cell tumors, and schwannomas. A GIST is an **esophageal** submucosal tumor with malignant potential.

Cited by: 8

Author: Takayoshi Watanabe, Tatsuya Miyazaki, ...

Publish Year: 2016

ALL

IMAGES

VIDEOS

MAPS

NEWS

SHOPPING

91,600 Results

Any time ▾

Benign esophageal schwannoma: A case report and review of ...

<https://www.njcponline.com/article.asp?issn=1119...>

The incidence of **benign** primary tumors of the **esophagus** is low and accounting for ~2% of all **esophageal** tumors. More than 80% of **benign esophageal** tumors are leiomyomas and schwannomas and are extremely rare. We **report** a **case** of a 55-year-old woman with **benign esophageal schwannoma** successfully treated with subtotal esophagectomy.

A report of three cases of surgical removal of esophageal ...

<https://www.ncbi.nlm.nih.gov/pmc/articles/PMC4842818>

Benign primary tumors of the **esophagus** are uncommon; most cases of **benign esophageal** tumors include leiomyomas and cases of **esophageal** schwannomas are extremely rare. We **report three** cases that were diagnosed with a leiomyoma pre-operatively, but all the tumors were identified as a **schwannoma** on post-operative pathology (Table 1).

Cited by: 3

Author: Xiankai Chen, Yin Li, Xianben Liu, Huaipi...

Publish Year: 2016

Resection of an esophageal schwannoma with thoracoscopic ...

<https://www.ncbi.nlm.nih.gov/pmc/articles/PMC5099309>

The authors stated that even if the max SUV is >6.0, a **benign schwannoma** cannot be excluded. Our **case** does not conflict with their **report** in that our **benign schwannoma** showed a max SUV of 5.5 and MIB-1 labeling index of 10 %. Therefore, FDG-PET could not reveal whether the hypermetabolic appearance indicated a **benign** or malignant tumor.

Cited by: 8

Author: Takayoshi Watanabe, Tatsuya Miyazaki, ...

Publish Year: 2016

(PDF) A case of esophageal schwannoma and literature ...

<https://www.researchgate.net/publication/226025858...>

The current study **reports** a **case of benign esophageal schwannoma** and re-evaluates **esophageal**