

# World Journal of *Clinical Cases*

*World J Clin Cases* 2020 November 6; 8(21): 5070-5495



## Contents

Semimonthly Volume 8 Number 21 November 6, 2020

## REVIEW

- 5070** Strategies and challenges in the treatment of chronic venous leg ulcers  
*Ren SY, Liu YS, Zhu GJ, Liu M, Shi SH, Ren XD, Hao YG, Gao RD*
- 5086** Peripheral nerve tumors of the hand: Clinical features, diagnosis, and treatment  
*Zhou HY, Jiang S, Ma FX, Lu H*

## MINIREVIEWS

- 5099** Treatment strategies for gastric cancer during the COVID-19 pandemic  
*Kang WZ, Zhong YX, Ma FH, Liu H, Ma S, Li Y, Hu HT, Li WK, Tian YT*

## ORIGINAL ARTICLE

## Retrospective Cohort Study

- 5104** Oncological impact of different distal ureter managements during radical nephroureterectomy for primary upper urinary tract urothelial carcinoma  
*Lai SC, Wu PJ, Liu JY, Seery S, Liu SJ, Long XB, Liu M, Wang JY*
- 5116** Clinical characteristics and survival of patients with normal-sized ovarian carcinoma syndrome: Retrospective analysis of a single institution 10-year experiment  
*Yu N, Li X, Yang B, Chen J, Wu MF, Wei JC, Li KZ*

## Retrospective Study

- 5128** Assessment of load-sharing thoracolumbar injury: A modified scoring system  
*Su QH, Li YC, Zhang Y, Tan J, Cheng B*
- 5139** Accuracy of endoscopic ultrasound-guided needle aspiration specimens for molecular diagnosis of non-small-cell lung carcinoma  
*Su W, Tian XD, Liu P, Zhou DJ, Cao FL*
- 5149** Application of hybrid operating rooms for clipping large or giant intracranial carotid-ophthalmic aneurysms  
*Zhang N, Xin WQ*
- 5159** Magnetic resonance imaging findings of carcinoma arising from anal fistula: A retrospective study in a single institution  
*Zhu X, Zhu TS, Ye DD, Liu SW*
- 5172** Efficacy and safety of S-1 maintenance therapy in advanced non-small-cell lung cancer patients  
*Cheng XW, Leng WH, Mu CL*

- 5180** Analysis of 234 cases of colorectal polyps treated by endoscopic mucosal resection  
*Yu L, Li N, Zhang XM, Wang T, Chen W*
- 5188** Epidemiological and clinical characteristics of fifty-six cases of COVID-19 in Liaoning Province, China  
*Wang JB, Wang HT, Wang LS, Li LP, Xu J, Xu C, Li XH, Wu YH, Liu HY, Li BJ, Yu H, Tian X, Zhang ZY, Wang Y, Zhao R, Liu JY, Wang W, Gu Y*
- 5203** Radiomics model for distinguishing tuberculosis and lung cancer on computed tomography scans  
*Cui EN, Yu T, Shang SJ, Wang XY, Jin YL, Dong Y, Zhao H, Luo YH, Jiang XR*
- 5213** Influence of transitional nursing on the compliance behavior and disease knowledge of children with purpura nephritis  
*Li L, Huang L, Zhang N, Guo CM, Hu YQ*
- Randomized Controlled Trial**
- 5221** Wavelet and pain rating index for inhalation anesthesia: A randomized controlled trial  
*Zhang JW, Lv ZG, Kong Y, Han CF, Wang BG*

### SYSTEMATIC REVIEWS

- 5235** Essential phospholipids for nonalcoholic fatty liver disease associated with metabolic syndrome: A systematic review and network meta-analysis  
*Dajani AI, Popovic B*
- 5250** Cardiovascular impact of COVID-19 with a focus on children: A systematic review  
*Rodriguez-Gonzalez M, Castellano-Martinez A, Cascales-Poyatos HM, Perez-Reviriego AA*
- 5284** Anterior bone loss after cervical disc replacement: A systematic review  
*Wang XF, Meng Y, Liu H, Hong Y, Wang BY*

### CASE REPORT

- 5296** Submicroscopic 11p13 deletion including the elongator acetyltransferase complex subunit 4 gene in a girl with language failure, intellectual disability and congenital malformations: A case report  
*Toral-Lopez J, González Huerta LM, Messina-Baas O, Cuevas-Covarrubias SA*
- 5304** Pancreatic panniculitis and elevated serum lipase in metastasized acinar cell carcinoma of the pancreas: A case report and review of literature  
*Miksch RC, Schiergens TS, Weniger M, Ilmer M, Kazmierczak PM, Guba MO, Angele MK, Werner J, D'Haese JG*
- 5313** Diffusion-weighted imaging might be useful for reactive lymphoid hyperplasia diagnosis of the liver: A case report  
*Tanaka T, Saito K, Yunaiyama D, Matsubayashi J, Nagakawa Y, Tanigawa M, Nagao T*
- 5320** Nafamostat mesylate-induced hyperkalemia in critically ill patients with COVID-19: Four case reports  
*Okajima M, Takahashi Y, Kaji T, Ogawa N, Mouri H*

- 5326** Arthroscopic treatment of iliopsoas tendinitis after total hip arthroplasty with acetabular cup malposition: Two case reports  
*Won H, Kim KH, Jung JW, Kim SY, Baek SH*
- 5334** Successful treatment of a high-risk nonseminomatous germ cell tumor using etoposide, methotrexate, actinomycin D, cyclophosphamide, and vincristine: A case report  
*Yun J, Lee SW, Lim SH, Kim SH, Kim CK, Park SK*
- 5341** Donepezil-related inadequate neuromuscular blockade during laparoscopic surgery: A case report  
*Jang EA, Kim TY, Jung EG, Jeong S, Bae HB, Lee S*
- 5347** Successful treatment of relapsed acute promyelocytic leukemia with arsenic trioxide in a hemodialysis-dependent patient: A case report  
*Lee HJ, Park SG*
- 5353** Treatment of afferent loop syndrome using fluoroscopic-guided nasointestinal tube placement: Two case reports  
*Hu HT, Ma FH, Wu ZM, Qi XH, Zhong YX, Xie YB, Tian YT*
- 5361** Emergency surgical workflow and experience of suspected cases of COVID-19: A case report  
*Wu D, Xie TY, Sun XH, Wang XX*
- 5371** Seven-year follow-up of the nonsurgical expansion of maxillary and mandibular arches in a young adult: A case report  
*Yu TT, Li J, Liu DW*
- 5380** Pancreatic cancer with ovarian metastases: A case report and review of the literature  
*Wang SD, Zhu L, Wu HW, Dai MH, Zhao YP*
- 5389** Early ultrasound diagnosis of conjoined twins at eight weeks of pregnancy: A case report  
*Liang XW, Cai YY, Yang YZ, Chen ZY*
- 5394** Supermicroscopy and arterio-venolization for digit replantation in young children after traumatic amputation: Two case reports  
*Chen Y, Wang ZM, Yao JH*
- 5401** Candidal periprosthetic joint infection after primary total knee arthroplasty combined with ipsilateral intertrochanteric fracture: A case report  
*Xin J, Guo QS, Zhang HY, Zhang ZY, Talmy T, Han YZ, Xie Y, Zhong Q, Zhou SR, Li Y*
- 5409** Aspiration pneumonia during general anesthesia induction after esophagectomy: A case report  
*Tang JX, Wang L, Nian WQ, Tang WY, Xiao JY, Tang XX, Liu HL*
- 5415** Large and unusual presentation of gallbladder adenoma: A case report  
*Cao LL, Shan H*
- 5420** Rare narrow QRS tachycardia with atrioventricular dissociation: A case report  
*Zhu C, Chen MX, Zhou GJ*

- 5426** Synchronous parathyroid adenoma, papillary thyroid carcinoma and thyroid adenoma in pregnancy: A case report  
*Li Q, Xu XZ, Shi JH*
- 5432** Pseudohyperkalemia caused by essential thrombocythemia in a patient with chronic renal failure: A case report  
*Guo Y, Li HC*
- 5439** Acute leukemic phase of anaplastic lymphoma kinase-anaplastic large cell lymphoma: A case report and review of the literature  
*Zhang HF, Guo Y*
- 5446** Chinese patient with cerebrotendinous xanthomatosis confirmed by genetic testing: A case report and literature review  
*Cao LX, Yang M, Liu Y, Long WY, Zhao GH*
- 5457** Incomplete Kawasaki disease complicated with acute abdomen: A case report  
*Wang T, Wang C, Zhou KY, Wang XQ, Hu N, Hua YM*
- 5467** Fanconi-Bickel syndrome in an infant with cytomegalovirus infection: A case report and review of the literature  
*Xiong LJ, Jiang ML, Du LN, Yuan L, Xie XL*
- 5480** Potential protection of indocyanine green on parathyroid gland function during near-infrared laparoscopic-assisted thyroidectomy: A case report and literature review  
*Peng SJ, Yang P, Dong YM, Yang L, Yang ZY, Hu XE, Bao GQ*
- 5487** New treatment of patellar instability after total knee arthroplasty: A case report and review of literature  
*Shen XY, Zuo JL, Gao JP, Liu T, Xiao JL, Qin YG*

**CORRECTION**

- 5494** Erratum: Author's Affiliation Correction. Type II human epidermal growth factor receptor heterogeneity is a poor prognosticator for type II human epidermal growth factor receptor positive gastric cancer (World J Clin Cases 2019; Aug 6; 7 (15): 1964-1977)  
*Kaito A, Kuwata T, Tokunaga M, Shitara K, Sato R, Akimoto T, Kinoshita T*

**ABOUT COVER**

Peer-reviewer for *World Journal of Clinical Cases*, Dr. Karayiannakis is Professor of Surgery at the Medical School of Democritus University of Thrace. He received his MD from the Medical Academy, Sofia, Bulgaria (1985), an MSc in Surgical Science from University of London (1996), and a PhD from National and Kapodistrian University of Athens (NKUA) (1993). After completing training at the NKUA Medical School in 1993, Dr. Karayiannakis undertook postgraduate training at St George's and Hammersmith Hospitals (London), the Institute for Digestive Diseases (Serbia), the University of Verona (Italy), and the Technical University of Munich (Germany). His clinical practice interests and research emphasis are in the field of hepato-pancreato-biliary diseases and gastrointestinal tract surgery, surgical oncology and laparoscopic surgery. (L-Editor: Filipodia)

**AIMS AND SCOPE**

The primary aim of *World Journal of Clinical Cases* (*WJCC*, *World J Clin Cases*) is to provide scholars and readers from various fields of clinical medicine with a platform to publish high-quality clinical research articles and communicate their research findings online.

*WJCC* mainly publishes articles reporting research results and findings obtained in the field of clinical medicine and covering a wide range of topics, including case control studies, retrospective cohort studies, retrospective studies, clinical trials studies, observational studies, prospective studies, randomized controlled trials, randomized clinical trials, systematic reviews, meta-analysis, and case reports.

**INDEXING/ABSTRACTING**

The *WJCC* is now indexed in Science Citation Index Expanded (also known as SciSearch®), Journal Citation Reports/Science Edition, PubMed, and PubMed Central. The 2020 Edition of Journal Citation Reports® cites the 2019 impact factor (IF) for *WJCC* as 1.013; IF without journal self cites: 0.991; Ranking: 120 among 165 journals in medicine, general and internal; and Quartile category: Q3.

**RESPONSIBLE EDITORS FOR THIS ISSUE**

Production Editor: Yan-Xia Xing; Production Department Director: Yun-Xiaojuan Wu; Editorial Office Director: Jin-Lai Wang.

**NAME OF JOURNAL**

*World Journal of Clinical Cases*

**ISSN**

ISSN 2307-8960 (online)

**LAUNCH DATE**

April 16, 2013

**FREQUENCY**

Semimonthly

**EDITORS-IN-CHIEF**

Dennis A Bloomfield, Sandro Vento, Bao-Gan Peng

**EDITORIAL BOARD MEMBERS**

<https://www.wjgnet.com/2307-8960/editorialboard.htm>

**PUBLICATION DATE**

November 6, 2020

**COPYRIGHT**

© 2020 Baishideng Publishing Group Inc

**INSTRUCTIONS TO AUTHORS**

<https://www.wjgnet.com/bpg/gerinfo/204>

**GUIDELINES FOR ETHICS DOCUMENTS**

<https://www.wjgnet.com/bpg/GerInfo/287>

**GUIDELINES FOR NON-NATIVE SPEAKERS OF ENGLISH**

<https://www.wjgnet.com/bpg/gerinfo/240>

**PUBLICATION ETHICS**

<https://www.wjgnet.com/bpg/GerInfo/288>

**PUBLICATION MISCONDUCT**

<https://www.wjgnet.com/bpg/gerinfo/208>

**ARTICLE PROCESSING CHARGE**

<https://www.wjgnet.com/bpg/gerinfo/242>

**STEPS FOR SUBMITTING MANUSCRIPTS**

<https://www.wjgnet.com/bpg/GerInfo/239>

**ONLINE SUBMISSION**

<https://www.f6publishing.com>

# Potential protection of indocyanine green on parathyroid gland function during near-infrared laparoscopic-assisted thyroidectomy: A case report and literature review

Shu-Jia Peng, Ping Yang, Yan-Ming Dong, Lin Yang, Zhen-Yu Yang, Xi-E Hu, Guo-Qiang Bao

**ORCID number:** Shu-Jia Peng 0000-0002-0454-6890; Ping Yang 0000-0002-1641-9389; Yan-Ming Dong 0000-0002-8579-0042; Lin Yang 0000-0002-6100-6540; Zhen-Yu Yang 0000-0003-1458-6834; Xi-E Hu 0000-0003-2960-3182; Guo-Qiang Bao 0000-0002-7399-9420.

**Author contributions:** Bao GQ contributed to the conception; Bao GQ, Yang P, and Peng SJ performed the operation; Bao GQ and Peng SJ handled the imaging; Yang P and Dong YM collected the data; Yang L, Yang ZY, and Hu XE drafted the manuscript; Bao GQ reviewed and revised the manuscript.

**Informed consent statement:** Informed content was obtained from the patient.

**Conflict-of-interest statement:** The authors declare no conflict of interest.

**CARE Checklist (2016) statement:** The authors have read the CARE Checklist (2016), and the manuscript was prepared and revised according to the CARE Checklist (2016).

**Open-Access:** This article is an open-access article that was selected by an in-house editor and

**Shu-Jia Peng, Ping Yang, Yan-Ming Dong, Lin Yang, Zhen-Yu Yang, Xi-E Hu, Guo-Qiang Bao,** Department of General Surgery, Tangdu Hospital, Air Force Military Medical University, Xi'an 710032, Shannxi Province, China

**Corresponding author:** Guo-Qiang Bao, MD, Assistant Professor, Associate Chief Physician, Doctor, Surgeon, Department of General Surgery, Tangdu Hospital, Air Force Military Medical University, No. 569 Xinsi Road, Xi'an 710032, Shannxi Province, China.  
[guoqiang@fmmu.edu.cn](mailto:guoqiang@fmmu.edu.cn)

## Abstract

### BACKGROUND

In recent decades, significant advances have been made in protecting the parathyroid glands and recurrent laryngeal nerves during thyroidectomy. However, reliable and convenient technical means are still lacking. In this study, the reliability, safety and feasibility of near-infrared (NIR) laparoscopy-assisted thyroid lobectomy with isthmectomy and prophylactic central lymph node dissection (CLND) were reported.

### CASE SUMMARY

A 63-year-old female patient with a free previous medical history, was admitted to our department due to multiple thyroid nodules. Ultrasonic examination suggested diffuse thyroid changes and one thyroid nodule in the right upper lobe with the largest diameter of 1.5 cm adjacent to the trachea and Breast Imaging Reporting and Data System grade 4B. Imaging examination of the neck showed no obvious enlarged lymph nodes. Fine needle aspiration biopsy suggested a papillary thyroid carcinoma. Combined with thyroid function examination, the patient was diagnosed with papillary thyroid carcinoma and Hashimoto's thyroiditis. Considering the risk of invading the capsule and the patient's extreme anxiety, a right thyroid lobectomy with isthmectomy and prophylactic CLND was planned. No significant abnormalities were found during preoperative examinations, except for an increased thyroid stimulating hormone level. The patient underwent NIR laparoscopy-assisted thyroid lobectomy with isthmectomy and prophylactic CLND. During the operation, two right parathyroid glands (PGs) adjacent to the thyroid gland capsule and the right recurrent laryngeal nerve (RLN) were examined by indocyanine green (ICG) fluorescence using a NIR fluorescence camera, and the PGs and RLN were

fully peer-reviewed by external reviewers. It is distributed in accordance with the Creative Commons Attribution NonCommercial (CC BY-NC 4.0) license, which permits others to distribute, remix, adapt, build upon this work non-commercially, and license their derivative works on different terms, provided the original work is properly cited and the use is non-commercial. See: <http://creativecommons.org/licenses/by-nc/4.0/>

**Manuscript source:** Unsolicited manuscript

**Specialty type:** Medicine, research and experimental

**Country/Territory of origin:** China

**Peer-review report's scientific quality classification**

Grade A (Excellent): A

Grade B (Very good): 0

Grade C (Good): 0

Grade D (Fair): 0

Grade E (Poor): 0

**Received:** June 28, 2020

**Peer-review started:** June 28, 2020

**First decision:** July 24, 2020

**Revised:** August 5, 2020

**Accepted:** August 29, 2020

**Article in press:** August 29, 2020

**Published online:** November 6, 2020

**P-Reviewer:** Spartalis E

**S-Editor:** Gao CC

**L-Editor:** Filipodia

**P-Editor:** Zhang YL



reliably preserved. Considering the ICG-positive PG, prophylactic CLND was performed. The postoperative parathyroid hormone level was in the normal range and no significant hypocalcemia symptoms were observed.

## CONCLUSION

During NIR laparoscopy-assisted thyroidectomy, ICG fluorescence may aid PG identification and protection.

**Key Words:** Indocyanine green; Near-infrared laparoscopy; Carbon nanoparticles; Hypoparathyroidism; Thyroidectomy; Case report

©The Author(s) 2020. Published by Baishideng Publishing Group Inc. All rights reserved.

**Core tip:** A female patient was admitted to our department due to thyroid nodules. Fine needle aspiration biopsy suggested a papillary thyroid carcinoma. The patient underwent near-infrared (NIR) laparoscopy-assisted thyroid lobectomy with isthmectomy and prophylactic central lymph node dissection. During the operation, two right parathyroid glands (PGs) adjacent to the thyroid gland capsule and the right recurrent laryngeal nerve were examined by indocyanine green fluorescence using a NIR fluorescence camera, and the PGs and recurrent laryngeal nerve were reliably preserved. The postoperative parathyroid hormone level was in the normal range and no significant hypocalcemia symptoms were observed. During NIR laparoscopy-assisted thyroidectomy, indocyanine green fluorescence may aid PG identification and protection.

**Citation:** Peng SJ, Yang P, Dong YM, Yang L, Yang ZY, Hu XE, Bao GQ. Potential protection of indocyanine green on parathyroid gland function during near-infrared laparoscopic-assisted thyroidectomy: A case report and literature review. *World J Clin Cases* 2020; 8(21): 5480-5486

**URL:** <https://www.wjgnet.com/2307-8960/full/v8/i21/5480.htm>

**DOI:** <https://dx.doi.org/10.12998/wjcc.v8.i21.5480>

## INTRODUCTION

Differentiated thyroid cancer, which includes papillary and follicular cancer, is becoming increasingly prevalent<sup>[1]</sup>. The incidence of thyroid cancer is increasing partly due to improved diagnostic methods such as ultrasound and other imaging methods, and the early detection of small papillary thyroid carcinomas (PTCs)<sup>[2,3]</sup>. There is no consensus on the surgical indications and surgical methods for PTCs. However, surgery is the optimum treatment for PTCs with high-risk factors. In addition, many patients choose surgical treatment due to fear and the inconvenience of follow-up. According to current practice and various guidelines, hemithyroidectomy is recommended for a tumor less than 4 cm and minor extrathyroidal extension (T2 stage)<sup>[4]</sup>. Prophylactic central lymph node dissection (CLND) may reduce lymph node (LN) recurrences, and the probability of reoperation<sup>[5]</sup>. With strict control of surgical indications and contraindications, endoscopic surgery is safe and feasible in selected patients<sup>[6]</sup>. Injury to the parathyroid glands (PGs) and recurrent laryngeal nerve (RLN) are the main postoperative complications of thyroidectomy. Due to their small size and close proximity to thyroid tissue, even though with clear anatomical background and careful dissection, it is hard to avoid inadvertent injury to the PGs. Disruption of parathyroid vasculature, direct trauma, or removal of PGs may result in symptomatic hypoparathyroidism and hypocalcemia<sup>[7-10]</sup>. A retrospective analysis of patients who underwent minimally invasive video-assisted thyroidectomy showed that the occurrence rate of transient hypoparathyroidism was 7% and definitive hypoparathyroidism was 0.4%<sup>[11]</sup>. The basis of parathyroid preservation in thyroid surgery is the identification of as many PGs as possible. Thus, accurate identification of PGs could reduce the risk of complications and influence management strategies. Several techniques, such as the use of intravenous methylene blue, indocyanine green (ICG), carbon nanoparticles (CNs), and colloidal gold immunochromatography, have been developed to aid in the identification of PGs<sup>[12]</sup>. In recent years, near-infrared

(NIR) fluorescence imaging with ICG has become a useful tool to identify and preserve PGs. ICG fluorescence imaging is a simple, rapid and repeatable method capable of visualizing and assessing the function of PGs intraoperatively<sup>[13]</sup>. Besides standard endoscopic magnification using video-assisted approach, enhanced visualization of parathyroid tissue can be confirmed by NIR. Furthermore, ICG injection was used to confirm the vascular supply of preserved PGs at the end of the operation<sup>[14]</sup>. In recent decades, significant advances have been made in protecting PGs and RLNs during thyroidectomy. However, reliable and convenient technical means are still lacking.

In this study, the reliability, safety, and feasibility of NIR laparoscopy-assisted thyroid lobectomy with isthmectomy and prophylactic CLND were reported.

---

## CASE PRESENTATION

---

### ***Chief complaints***

A 63-year-old woman was admitted to our department due to multiple thyroid nodules.

### ***History of present illness***

The patient had no discomfort. Imaging examination of the neck showed no obvious enlarged LNs. Fine needle aspiration biopsy suggested PTC.

### ***History of past illness***

The patient had no history of other diseases.

### ***Physical examination***

On admission, her body temperature was 36.2°C, heart rate was 87 bpm, breathing rate was 16 breaths/min, blood pressure was 128/76 mmHg, and room air oxygen saturation was 99%. A 1.5 cm sized hard nodule in the left neck was palpated, with a clear boundary and irregular shape, moving up and down with swallowing, and no obvious enlarged LNs were found. Other physical examinations showed no obvious abnormalities.

### ***Laboratory examinations***

No significant abnormalities were found during preoperative examinations, except for an increased thyroid stimulating hormone (= 6.8, reference range: 0.27-4.2  $\mu$ IU/mL) level. The level of parathyroid hormone was 52.3 pg/mL (reference range: 15-65 pg/mL), the level of  $\text{Ca}^{2+}$  was 2.55 mmol/L (reference range: 2.10-2.90 mmol/L), respectively.

### ***Imaging examinations***

Ultrasonic examination (The Endocrine Clinic, Singapore), suggested diffuse thyroid changes and one thyroid nodule in the right upper lobe with the largest diameter of 1.5 cm adjacent to the trachea and Breast Imaging Reporting and Data System grade 4B.

---

## FINAL DIAGNOSIS

---

PTC and Hashimoto's thyroiditis.

---

## TREATMENT

---

Considering the risk of invading the capsule and the patient's extreme anxiety, a right thyroid lobectomy with isthmectomy and prophylactic CLND was planned. Thyroid surgery was performed by three experienced surgeons. The surgical technique was based on a previously described procedure with slight modifications<sup>[15]</sup>. ICG (0.5 mg/kg) was intravenously administered 1 h before initiation of anesthesia after confirmation that the patient was not allergic to ICG. Under general anesthesia, the patient was placed in the supine position with her head hyperextended. A 10 mm incision was made on the superficial layer of the subcutaneous fascia of the anterior chest wall at the level of the nipple. About 50 mL normal saline and adrenaline

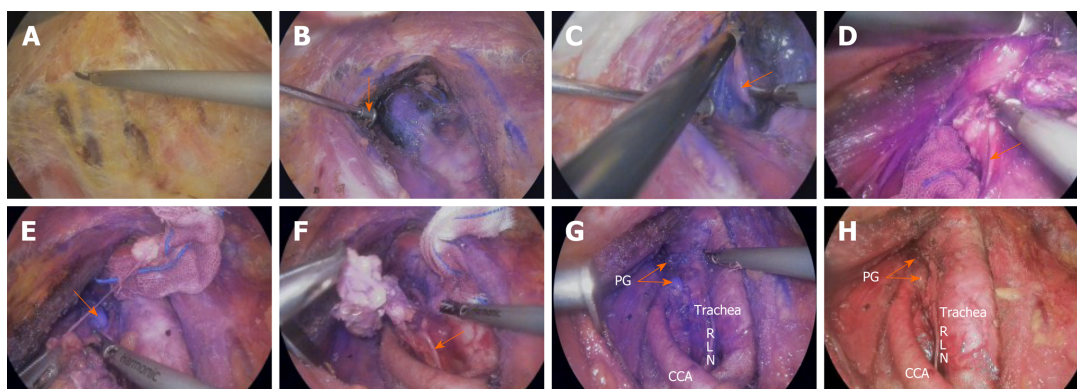
(1:200000) mixture was then injected to distend the subcutaneous tissues. A subcutaneous “Y”-shape tunnel was created in the subcutaneous plane of the anterior chest wall using a 10 mm trocar. A 10 mm, HD 30° NIR fluorescence camera (Smart Eye 101; Suzhou Caring Medical Co., Ltd., Suzhou, China) was then inserted and subcutaneous CO<sub>2</sub> insufflation was performed under the pressure of 6 mmHg. At the 11 o’clock position on the right and left edges of the areola, 5 and 10 mm arc-shaped incisions were made, respectively, and the right incision served as the main operational site, and two trocars were inserted *via* these incisions under the laparoscope. The operative space was created by a sharp subcutaneous dissection with the HARMONIC® scalpel. This dissection was continued in the subplatysmal plane of the neck beyond the clavicle (Figure 1A). The thyroid was approached through the midline between strap muscles and exposed with a modified detachable retractor (Figure 1B). The PG was identified using the NIR camera (Figure 1C). The right RLN was exposed and well protected *via* intraoperative neuromonitoring (Figure 1D). After identification of the normal PG and RLN, gentle dissection was performed, avoiding damage to the capsule and ICG leakage. Then the right thyroid lobe and isthmus were excised. CLND was performed under the guidance of fluorescence imaging (Figure 1E). During the operation, the right common carotid artery was found to originate from the left side of the trachea (Figure 1F). The lymphatic tissue and soft tissue surrounding the RLN were excised *en bloc* (Figure 1F). Finally, a right thyroid lobectomy with isthmectomy and prophylactic CLND were successfully performed using NIR fluorescence endoscopy (Figure 1G and Figure H). The operation time was 94 min and blood loss was approximately 8 mL.

## OUTCOME AND FOLLOW-UP

Postoperatively, the patient was given routine treatment and prophylactic oral calcium supplementation. There was no significant sound change after the operation. On postoperative day (POD) 3, the drainage fluid reduced to 10 mL from 70 mL seen on the 1<sup>st</sup> day, and the drainage tube was removed. The level of PTH on POD 1 was 45.6 pg/mL and 46.5 pg/mL on POD 3 (reference range: 15-65 pg/mL). The level of Ca<sup>2+</sup> was 2.24 mmol/L and 2.36 pg/mL on POD 1 and POD 3, respectively (reference range: 2.10-2.90 mmol/L). The level of Mg<sup>2+</sup> was 0.82 mmol/L and 0.91 mmol/mL on POD 1 and POD 3, respectively (reference range: 0.77-1.03 mmol/L). On POD 4, the patient was discharged with no symptoms of hypocalcemia and without additional calcium supplementation.

## DISCUSSION

Surgery is the basic treatment for PTC. Generally, nodules > 1 cm are potentially clinically significant cancers. Some nodules < 1 cm should also be evaluated due to presence of clinical symptom or swollen LNs. Many established guidelines advise doctors to avoid overtreatment in a majority of patients at low risk, while high-risk patients should be appropriately monitored and managed<sup>[16]</sup>. For small PTCs, previous studies have reported that patients who underwent total thyroidectomy had better prognosis than those who received other therapies<sup>[17]</sup>, including low-risk patients. However, lobectomy did not increase the loco-regional recurrence risk of the contralateral remnant lobe. As total thyroidectomy can safely manage recurrence of the contralateral remnant lobe, it is a safe option for selected patients with small PTCs with solitary focus<sup>[18]</sup>. In China, more patients with PTC choose surgical treatment. The extent of surgery for PTC significantly differs in different medical centers and by different surgeons. For low-risk patients, the more limited thyroidectomies, *e.g.*, lobectomy with isthmectomy, have been adopted, although prophylactic LN dissection has been performed. Although patients with T1N0M0 have an excellent prognosis following thyroidectomy without radioiodine therapy, hemithyroidectomy is adequate if a 1% risk of recurrence of the remnant thyroid is acceptable<sup>[19]</sup>. Morbidity due to PTC is mostly derived from LN metastases, which lead to reoperations and complications associated with these surgeries. Ultrasound is not the best method for determination of LN metastasis and routine central node dissection. Prophylactic CLND appears to reduce LN recurrences, and the probability of reoperation<sup>[5]</sup>. In a study, 96% of patients underwent prophylactic CLND, pathological examination showed positive LNs in 57% of patients. Many studies suggested that the sentinel node biopsy with removal of other LNs belonging to the sentinel node compartment, is a safe procedure<sup>[20]</sup>. In our



**Figure 1 The procedure for near-infrared endoscopy-assisted right thyroid lobectomy with isthmectomy and prophylactic central lymph node dissection.** A: Creating the operative space; B: Exposing the thyroid lobe (modified detachable retractor, orange arrow) in near-infrared (NIR) mode; C: Investigating the parathyroid gland (PG) in NIR mode (PG, orange arrow); D: Exposing the right recurrent laryngeal nerve (RLN) in NIR mode (RLN, orange arrow); E: Performing central lymph node dissection under the guidance of fluorescence imaging in NIR mode (PG, orange arrow); F: Excising the lymphatic tissue and soft tissue surrounding the RLN in NIR mode (RLN, orange arrow); G: The final operative field in NIR mode; H: The final operative field in white light mode. PT: Papillary thyroid; RLN: Recurrent laryngeal nerve; CCA: Common carotid artery.

department, we usually perform limited lobectomy with isthmectomy + prophylactic CLND for patients with low-risk single small PTC. Hypoparathyroidism, an ongoing and frequently underestimated complication after thyroid operation, leads to hypocalcemia and serious medical problems<sup>[9,21]</sup>. Comparing hemithyroidectomy with all other surgical procedures, prolonged surgery (total thyroidectomy) and the diagnosis of malignancy are predictors of transient and permanent hypoparathyroidism<sup>[22]</sup>. Careful separation by an experienced surgeon using capsular separation techniques can reduce the incidence. In addition, CLND is reported to be the most frequent risk factor of incidental parathyroidectomy<sup>[23]</sup>. Incidental parathyroidectomy is considered a minor finding in final histopathology, but it is important for the thyroid surgeon to be able to identify the factors that increase the risk of incidental parathyroidectomy during thyroidectomy and exercise appropriate caution in these patients<sup>[24]</sup>. Despite the risk of unavoidable incidental parathyroidectomy, careful dissection and meticulous intraoperative identification of PGs can reduce the incidence of incidental parathyroidectomy<sup>[25]</sup>. Although preservation of the surrounding vasculature and capsular dissection techniques are used to avoid incidental parathyroidectomy or disruption of the parathyroid vasculature, reliable tools to both identify and assess PGs during surgery, and to predict whether a patient will develop hypoparathyroidism, are limited<sup>[26]</sup>. In China, CNs have been widely used for the intraoperative identification of the sentinel LN in various cancers, which shows the highest detection rate and accuracy<sup>[27-29]</sup>. CNs have also been used to identify the PGs and trace the LNs in the initial surgery for thyroid cancer in recent years<sup>[30]</sup>. CNs application markedly improves LN detection rate and decreases the rate of incidental parathyroidectomy, which potentially improves the management of PTC patients<sup>[31]</sup>. CNs significantly decrease the incidence of permanent and transient hypoparathyroidism and reduce the mean recovery time for transient hypoparathyroidism, thus improving the postoperative quality of life of patients<sup>[32,33]</sup>. Recent studies have demonstrated the feasibility and effectiveness of ICG in thyroid surgery. NIR fluorescence imaging with intravenous ICG has been used for the identification of PGs during thyroid and parathyroid surgery. It can provide certainty on the location of PGs, especially to confirm the presence of a suspect PG. Intraoperative ICG fluorescence imaging is a simple, fast and reproducible method capable of visualizing and assessing the function of PGs intraoperatively<sup>[13,34]</sup>. Angiography with ICG has been performed in patients undergoing thyroid surgery, to visualize vascularization of identified PGs. ICG imaging during total thyroidectomy is feasible. ICG might be a useful adjunct to the identification of patients with hypothyroidism after thyroidectomy<sup>[35]</sup>. In a study that included 36 patients, at least one well vascularized PG was demonstrated by ICG angiography in 30 patients, and PTH levels on POD 1 were normal in all these patients, and none required treatment for hypoparathyroidism<sup>[26]</sup>. Three branches arise from the superior border of the aortic arch: The left subclavian artery, the left common carotid artery, and the brachiocephalic trunk. The brachiocephalic trunk divides into the right common carotid artery and the right subclavian artery. This branching type was first classified

as the normal pattern type A by the anatomist Buntaro Adachi (1865-1945) in 1928<sup>[36]</sup>. In this case, the right common carotid artery straddled the trachea. This variation is seen in about 1% of patients in our clinical practice. To some extent, this variation facilitates CLND in endoscopic thyroidectomy. In the present patient, NIR endoscopy was used for lobectomy with isthmectomy + prophylactic CLND. ICG fluorescence was helpful in the identification and protection of PGs. In NIR mode, the color difference between the PGs and the surrounding background effectively prevented incidental parathyroidectomy following CLND. In addition, since there is no fluorescence imaging of the RLN, the display is more obvious under the magnification of the endoscope, which may be beneficial in the protection of RLN function.

## CONCLUSION

In endoscopic thyroid surgery, NIR fluorescence endoscopy can be selected, which, combined with ICG, may contribute to functional protection in thyroid surgery. Of course, the application value of NIR endoscopy in thyroid surgery needs to be further studied and discussed.

## ACKNOWLEDGEMENTS

The authors thank the patient for granting permission to report the case.

## REFERENCES

- 1 **Davies L**, Welch HG. Current thyroid cancer trends in the United States. *JAMA Otolaryngol Head Neck Surg* 2014; **140**: 317-322 [PMID: 24557566 DOI: 10.1001/jamaoto.2014.1]
- 2 **Leenhardt L**, Bernier MO, Boin-Pineau MH, Conte Devolx B, Maréchaud R, Niccoli-Sire P, Nocaudie M, Orgiazzi J, Schlumberger M, Wémeau JL, Chérie-Challine L, De Vathaire F. Advances in diagnostic practices affect thyroid cancer incidence in France. *Eur J Endocrinol* 2004; **150**: 133-139 [PMID: 14763910 DOI: 10.1530/eje.0.1500133]
- 3 **Ahn HS**, Kim HJ, Welch HG. Korea's thyroid-cancer "epidemic"--screening and overdiagnosis. *N Engl J Med* 2014; **371**: 1765-1767 [PMID: 25372084 DOI: 10.1056/NEJMp1409841]
- 4 **Kang JG**, Kim YA, Choi JE, Lee SJ, Kang SH. Usefulness of 1-year of thyroid stimulating hormone suppression on additional levothyroxine in patients who underwent hemithyroidectomy with papillary thyroid microcarcinoma. *Gland Surg* 2019; **8**: 636-643 [PMID: 32042670 DOI: 10.21037/gs.2019.10.12]
- 5 **Yazici D**, Çolakoğlu B, Sağlam B, Sezer H, Kapran Y, Aydın Ö, Demirkol MO, Alagöl F, Terzioğlu T. Effect of prophylactic central neck dissection on the surgical outcomes in papillary thyroid cancer: experience in a single center. *Eur Arch Otorhinolaryngol* 2020; **277**: 1491-1497 [PMID: 32052141 DOI: 10.1007/s00405-020-05830-1]
- 6 **Sun P**, Chen W, Mak TK, Chong TH, Li J, Yang J, Wang C. Right Central Lymph Node Dissection in Thyroidectomy: Can Endoscopic Chest-Breast Approach Be Used? *J Laparoendosc Adv Surg Tech A* 2020; **30**: 308-314 [PMID: 31746665 DOI: 10.1089/lap.2019.0527]
- 7 **Chang YK**, Lang BHH. To identify or not to identify parathyroid glands during total thyroidectomy. *Gland Surg* 2017; **6**: S20-S29 [PMID: 29322019 DOI: 10.21037/gs.2017.06.13]
- 8 **Chadwick DR**. Hypocalcaemia and permanent hypoparathyroidism after total/bilateral thyroidectomy in the BAETS Registry. *Gland Surg* 2017; **6**: S69-S74 [PMID: 29322024 DOI: 10.21037/gs.2017.09.14]
- 9 **Edafe O**, Antakia R, Laskar N, Uttley L, Balasubramanian SP. Systematic review and meta-analysis of predictors of post-thyroidectomy hypocalcaemia. *Br J Surg* 2014; **101**: 307-320 [PMID: 24402815 DOI: 10.1002/bjs.9384]
- 10 **Özden S**, Erdoğan A, Simsek B, Saylam B, Yıldız B, Tez M. Clinical course of incidental parathyroidectomy: Single center experience. *Auris Nasus Larynx* 2018; **45**: 574-577 [PMID: 28807528 DOI: 10.1016/j.anl.2017.07.019]
- 11 **Miccoli P**, Fregoli L, Rossi L, Papini P, Ambrosini CE, Bakkar S, De Napoli L, Aghababian A, Matteucci V, Materazzi G. Minimally invasive video-assisted thyroidectomy (MIVAT). *Gland Surg* 2020; **9**: S1-S5 [PMID: 32055492 DOI: 10.21037/gs.2019.12.05]
- 12 **Zhang A**, Gao T, Wu S, You Z, Zhen J, Wan F. Feasibility of using colloidal gold immunochromatography for point-of-care identification of parathyroid glands during thyroidectomy. *Biochem Biophys Res Commun* 2018; **507**: 110-113 [PMID: 30420286 DOI: 10.1016/j.bbrc.2018.10.178]
- 13 **Spartalis E**, Ntokos G, Georgiou K, Zografos G, Tsourouflis G, Dimitroulis D, Nikiteas NI. Intraoperative Indocyanine Green (ICG) Angiography for the Identification of the Parathyroid Glands: Current Evidence and Future Perspectives. *In Vivo* 2020; **34**: 23-32 [PMID: 31882459 DOI: 10.21873/invivo.11741]
- 14 **Alesina PF**, Meier B, Hinrichs J, Mohmand W, Walz MK. Enhanced visualization of parathyroid glands during video-assisted neck surgery. *Langenbecks Arch Surg* 2018; **403**: 395-401 [PMID: 29536247 DOI: 10.1007/s00423-018-1665-2]
- 15 **Bhargav PR**, Amar V. Operative technique of endoscopic thyroidectomy: a narration of general principles.

- Indian J Surg* 2013; **75**: 216-219 [PMID: [24426430](#) DOI: [10.1007/s12262-012-0494-8](#)]
- 16 **Haugen BR**, Alexander EK, Bible KC, Doherty GM, Mandel SJ, Nikiforov YE, Pacini F, Randolph GW, Sawka AM, Schlumberger M, Schuff KG, Sherman SI, Sosa JA, Steward DL, Tuttle RM, Wartofsky L. 2015 American Thyroid Association Management Guidelines for Adult Patients with Thyroid Nodules and Differentiated Thyroid Cancer: The American Thyroid Association Guidelines Task Force on Thyroid Nodules and Differentiated Thyroid Cancer. *Thyroid* 2016; **26**: 1-133 [PMID: [26462967](#) DOI: [10.1089/thy.2015.0020](#)]
- 17 **Mazzaferri EL**, Kloos RT. Clinical review 128: Current approaches to primary therapy for papillary and follicular thyroid cancer. *J Clin Endocrinol Metab* 2001; **86**: 1447-1463 [PMID: [11297567](#) DOI: [10.1210/jcem.86.4.7407](#)]
- 18 **Kim SK**, Park I, Woo JW, Lee JH, Choe JH, Kim JH, Kim JS. Total thyroidectomy versus lobectomy in conventional papillary thyroid microcarcinoma: Analysis of 8,676 patients at a single institution. *Surgery* 2017; **161**: 485-492 [PMID: [27593085](#) DOI: [10.1016/j.surg.2016.07.037](#)]
- 19 **Ito Y**, Masuoka H, Fukushima M, Inoue H, Kihara M, Tomoda C, Higashiyama T, Takamura Y, Kobayashi K, Miya A, Miyauchi A. Excellent prognosis of patients with solitary T1N0M0 papillary thyroid carcinoma who underwent thyroidectomy and elective lymph node dissection without radioiodine therapy. *World J Surg* 2010; **34**: 1285-1290 [PMID: [20041244](#) DOI: [10.1007/s00268-009-0356-0](#)]
- 20 **Carcoforo P**, Sortini D, Zulian V, Blotta A, Rossi R, Feggi LM. Excellent prognosis of patients with solitary T1N0M0 papillary thyroid carcinoma who underwent thyroidectomy and elective lymph node dissection without radioiodine therapy. *World J Surg* 2011; **35**: 231-2; author reply 233 [PMID: [20556610](#) DOI: [10.1007/s00268-010-0675-1](#)]
- 21 **Gschwandtner E**, Seemann R, Bures C, Peldzic L, Szucsik E, Hermann M. How many parathyroid glands can be identified during thyroidectomy? *Eur Surg* 2018; **50**: 14-21 [PMID: [29445392](#) DOI: [10.1007/s10353-017-0502-0](#)]
- 22 **Coimbra C**, Monteiro F, Oliveira P, Ribeiro L, de Almeida MG, Condé A. Hypoparathyroidism following thyroidectomy: Predictive factors. *Acta Otorrinolaringol Esp* 2017; **68**: 106-111 [PMID: [27776803](#) DOI: [10.1016/j.otorri.2016.06.008](#)]
- 23 **Du W**, Fang Q, Zhang X, Cui M, Zhao M, Lou W. Unintentional parathyroidectomy during total thyroidectomy surgery: A single surgeon's experience. *Medicine (Baltimore)* 2017; **96**: e6411 [PMID: [28296787](#) DOI: [10.1097/MD.00000000000006411](#)]
- 24 **Lin YS**, Hsueh C, Wu HY, Yu MC, Chao TC. Incidental parathyroidectomy during thyroidectomy increases the risk of postoperative hypocalcemia. *Laryngoscope* 2017; **127**: 2194-2200 [PMID: [28121013](#) DOI: [10.1002/lary.26448](#)]
- 25 **Alraddadi T**, Aldahri S, Almayouf M, Alharbi J, Malas M, Nasrullah M, Al-Qahtani K. Risk Factors of Incidental Parathyroidectomy in Thyroid Surgery. *Cureus* 2019; **11**: e6517 [PMID: [32025436](#) DOI: [10.7759/cureus.6517](#)]
- 26 **Vidal Fortuny J**, Sadowski SM, Belfontali V, Guigard S, Poncet A, Ris F, Karenovics W, Triponez F. Randomized clinical trial of intraoperative parathyroid gland angiography with indocyanine green fluorescence predicting parathyroid function after thyroid surgery. *Br J Surg* 2018; **105**: 350-357 [PMID: [29405252](#) DOI: [10.1002/bjs.10783](#)]
- 27 **Lu Y**, Wei JY, Yao DS, Pan ZM, Yao Y. Application of carbon nanoparticles in laparoscopic sentinel lymph node detection in patients with early-stage cervical cancer. *PLoS One* 2017; **12**: e0183834 [PMID: [28873443](#) DOI: [10.1371/journal.pone.0183834](#)]
- 28 **Sun J**, Zhang J. Assessment of lymph node metastasis in elderly patients with colorectal cancer by sentinel lymph node identification using carbon nanoparticles. *J BUON* 2018; **23**: 68-72 [PMID: [29552762](#)]
- 29 **Hao RT**, Chen J, Zhao LH, Liu C, Wang OC, Huang GL, Zhang XH, Zhao J. Sentinel lymph node biopsy using carbon nanoparticles for Chinese patients with papillary thyroid microcarcinoma. *Eur J Surg Oncol* 2012; **38**: 718-724 [PMID: [22521260](#) DOI: [10.1016/j.ejso.2012.02.001](#)]
- 30 **Wang B**, Su AP, Xing TF, Luo H, Zhao WJ, Zhu JQ. The function of carbon nanoparticles to improve lymph node dissection and identification of parathyroid glands during thyroid reoperation for carcinoma. *Medicine (Baltimore)* 2018; **97**: e11778 [PMID: [30095634](#) DOI: [10.1097/MD.00000000000011778](#)]
- 31 **Liu Y**, Li L, Yu J, Fan YX, Lu XB. Carbon nanoparticle lymph node tracer improves the outcomes of surgical treatment in papillary thyroid cancer. *Cancer Biomark* 2018; **23**: 227-233 [PMID: [30198867](#) DOI: [10.3233/CBM-181386](#)]
- 32 **Long M**, Luo D, Diao F, Huang M, Huang K, Peng X, Lin S, Li H. A Carbon Nanoparticle Lymphatic Tracer Protected Parathyroid Glands During Radical Thyroidectomy for Papillary Thyroid Non-Microcarcinoma. *Surg Innov* 2017; **24**: 29-34 [PMID: [27634477](#) DOI: [10.1177/1553350616668088](#)]
- 33 **Gao B**, Tian W, Jiang Y, Zhang S, Guo L, Zhao J, Zhang G, Hao S, Xu Y, Luo D. Application of carbon nanoparticles for parathyroid protection in reoperation of thyroid diseases. *Int J Clin Exp Med* 2015; **8**: 22254-22261 [PMID: [26885201](#)]
- 34 **van den Bos J**, van Kooten L, Engelen SME, Lubbers T, Stassen LPS, Bouvy ND. Feasibility of indocyanine green fluorescence imaging for intraoperative identification of parathyroid glands during thyroid surgery. *Head Neck* 2019; **41**: 340-348 [PMID: [30536963](#) DOI: [10.1002/hed.25451](#)]
- 35 **Zaidi N**, Bucak E, Yazici P, Soundararajan S, Okoh A, Yigitbas H, Dural C, Berber E. The feasibility of indocyanine green fluorescence imaging for identifying and assessing the perfusion of parathyroid glands during total thyroidectomy. *J Surg Oncol* 2016; **113**: 775-778 [PMID: [27041628](#) DOI: [10.1002/jso.24237](#)]
- 36 **Panagoulis E**, Tsoucalas G, Papaioannou T, Fiska A, Venieratos D, Skandalakis P. Right and left common carotid arteries arising from the brachiocephalic, a rare variation of the aortic arch. *Anat Cell Biol* 2018; **51**: 215-217 [PMID: [30310716](#) DOI: [10.5115/acb.2018.51.3.215](#)]



Published by **Baishideng Publishing Group Inc**  
7041 Koll Center Parkway, Suite 160, Pleasanton, CA 94566, USA

**Telephone:** +1-925-3991568

**E-mail:** [bpgoffice@wjgnet.com](mailto:bpgoffice@wjgnet.com)

**Help Desk:** <https://www.f6publishing.com/helpdesk>

<https://www.wjgnet.com>

