

World Journal of *Clinical Cases*

World J Clin Cases 2020 November 6; 8(21): 5070-5495



Contents

Semimonthly Volume 8 Number 21 November 6, 2020

REVIEW

- 5070** Strategies and challenges in the treatment of chronic venous leg ulcers
Ren SY, Liu YS, Zhu GJ, Liu M, Shi SH, Ren XD, Hao YG, Gao RD
- 5086** Peripheral nerve tumors of the hand: Clinical features, diagnosis, and treatment
Zhou HY, Jiang S, Ma FX, Lu H

MINIREVIEWS

- 5099** Treatment strategies for gastric cancer during the COVID-19 pandemic
Kang WZ, Zhong YX, Ma FH, Liu H, Ma S, Li Y, Hu HT, Li WK, Tian YT

ORIGINAL ARTICLE

Retrospective Cohort Study

- 5104** Oncological impact of different distal ureter managements during radical nephroureterectomy for primary upper urinary tract urothelial carcinoma
Lai SC, Wu PJ, Liu JY, Seery S, Liu SJ, Long XB, Liu M, Wang JY
- 5116** Clinical characteristics and survival of patients with normal-sized ovarian carcinoma syndrome: Retrospective analysis of a single institution 10-year experiment
Yu N, Li X, Yang B, Chen J, Wu MF, Wei JC, Li KZ

Retrospective Study

- 5128** Assessment of load-sharing thoracolumbar injury: A modified scoring system
Su QH, Li YC, Zhang Y, Tan J, Cheng B
- 5139** Accuracy of endoscopic ultrasound-guided needle aspiration specimens for molecular diagnosis of non-small-cell lung carcinoma
Su W, Tian XD, Liu P, Zhou DJ, Cao FL
- 5149** Application of hybrid operating rooms for clipping large or giant intracranial carotid-ophthalmic aneurysms
Zhang N, Xin WQ
- 5159** Magnetic resonance imaging findings of carcinoma arising from anal fistula: A retrospective study in a single institution
Zhu X, Zhu TS, Ye DD, Liu SW
- 5172** Efficacy and safety of S-1 maintenance therapy in advanced non-small-cell lung cancer patients
Cheng XW, Leng WH, Mu CL

- 5180** Analysis of 234 cases of colorectal polyps treated by endoscopic mucosal resection
Yu L, Li N, Zhang XM, Wang T, Chen W
- 5188** Epidemiological and clinical characteristics of fifty-six cases of COVID-19 in Liaoning Province, China
Wang JB, Wang HT, Wang LS, Li LP, Xu J, Xu C, Li XH, Wu YH, Liu HY, Li BJ, Yu H, Tian X, Zhang ZY, Wang Y, Zhao R, Liu JY, Wang W, Gu Y
- 5203** Radiomics model for distinguishing tuberculosis and lung cancer on computed tomography scans
Cui EN, Yu T, Shang SJ, Wang XY, Jin YL, Dong Y, Zhao H, Luo YH, Jiang XR
- 5213** Influence of transitional nursing on the compliance behavior and disease knowledge of children with purpura nephritis
Li L, Huang L, Zhang N, Guo CM, Hu YQ
- Randomized Controlled Trial**
- 5221** Wavelet and pain rating index for inhalation anesthesia: A randomized controlled trial
Zhang JW, Lv ZG, Kong Y, Han CF, Wang BG

SYSTEMATIC REVIEWS

- 5235** Essential phospholipids for nonalcoholic fatty liver disease associated with metabolic syndrome: A systematic review and network meta-analysis
Dajani AI, Popovic B
- 5250** Cardiovascular impact of COVID-19 with a focus on children: A systematic review
Rodriguez-Gonzalez M, Castellano-Martinez A, Cascales-Poyatos HM, Perez-Reviriego AA
- 5284** Anterior bone loss after cervical disc replacement: A systematic review
Wang XF, Meng Y, Liu H, Hong Y, Wang BY

CASE REPORT

- 5296** Submicroscopic 11p13 deletion including the elongator acetyltransferase complex subunit 4 gene in a girl with language failure, intellectual disability and congenital malformations: A case report
Toral-Lopez J, González Huerta LM, Messina-Baas O, Cuevas-Covarrubias SA
- 5304** Pancreatic panniculitis and elevated serum lipase in metastasized acinar cell carcinoma of the pancreas: A case report and review of literature
Miksch RC, Schiergens TS, Weniger M, Ilmer M, Kazmierczak PM, Guba MO, Angele MK, Werner J, D'Haese JG
- 5313** Diffusion-weighted imaging might be useful for reactive lymphoid hyperplasia diagnosis of the liver: A case report
Tanaka T, Saito K, Yunaiyama D, Matsubayashi J, Nagakawa Y, Tanigawa M, Nagao T
- 5320** Nafamostat mesylate-induced hyperkalemia in critically ill patients with COVID-19: Four case reports
Okajima M, Takahashi Y, Kaji T, Ogawa N, Mouri H

- 5326** Arthroscopic treatment of iliopsoas tendinitis after total hip arthroplasty with acetabular cup malposition: Two case reports
Won H, Kim KH, Jung JW, Kim SY, Baek SH
- 5334** Successful treatment of a high-risk nonseminomatous germ cell tumor using etoposide, methotrexate, actinomycin D, cyclophosphamide, and vincristine: A case report
Yun J, Lee SW, Lim SH, Kim SH, Kim CK, Park SK
- 5341** Donepezil-related inadequate neuromuscular blockade during laparoscopic surgery: A case report
Jang EA, Kim TY, Jung EG, Jeong S, Bae HB, Lee S
- 5347** Successful treatment of relapsed acute promyelocytic leukemia with arsenic trioxide in a hemodialysis-dependent patient: A case report
Lee HJ, Park SG
- 5353** Treatment of afferent loop syndrome using fluoroscopic-guided nasointestinal tube placement: Two case reports
Hu HT, Ma FH, Wu ZM, Qi XH, Zhong YX, Xie YB, Tian YT
- 5361** Emergency surgical workflow and experience of suspected cases of COVID-19: A case report
Wu D, Xie TY, Sun XH, Wang XX
- 5371** Seven-year follow-up of the nonsurgical expansion of maxillary and mandibular arches in a young adult: A case report
Yu TT, Li J, Liu DW
- 5380** Pancreatic cancer with ovarian metastases: A case report and review of the literature
Wang SD, Zhu L, Wu HW, Dai MH, Zhao YP
- 5389** Early ultrasound diagnosis of conjoined twins at eight weeks of pregnancy: A case report
Liang XW, Cai YY, Yang YZ, Chen ZY
- 5394** Supermicroscopy and arterio-venolization for digit replantation in young children after traumatic amputation: Two case reports
Chen Y, Wang ZM, Yao JH
- 5401** Candidal periprosthetic joint infection after primary total knee arthroplasty combined with ipsilateral intertrochanteric fracture: A case report
Xin J, Guo QS, Zhang HY, Zhang ZY, Talmy T, Han YZ, Xie Y, Zhong Q, Zhou SR, Li Y
- 5409** Aspiration pneumonia during general anesthesia induction after esophagectomy: A case report
Tang JX, Wang L, Nian WQ, Tang WY, Xiao JY, Tang XX, Liu HL
- 5415** Large and unusual presentation of gallbladder adenoma: A case report
Cao LL, Shan H
- 5420** Rare narrow QRS tachycardia with atrioventricular dissociation: A case report
Zhu C, Chen MX, Zhou GJ

- 5426** Synchronous parathyroid adenoma, papillary thyroid carcinoma and thyroid adenoma in pregnancy: A case report
Li Q, Xu XZ, Shi JH
- 5432** Pseudohyperkalemia caused by essential thrombocythemia in a patient with chronic renal failure: A case report
Guo Y, Li HC
- 5439** Acute leukemic phase of anaplastic lymphoma kinase-anaplastic large cell lymphoma: A case report and review of the literature
Zhang HF, Guo Y
- 5446** Chinese patient with cerebrotendinous xanthomatosis confirmed by genetic testing: A case report and literature review
Cao LX, Yang M, Liu Y, Long WY, Zhao GH
- 5457** Incomplete Kawasaki disease complicated with acute abdomen: A case report
Wang T, Wang C, Zhou KY, Wang XQ, Hu N, Hua YM
- 5467** Fanconi-Bickel syndrome in an infant with cytomegalovirus infection: A case report and review of the literature
Xiong LJ, Jiang ML, Du LN, Yuan L, Xie XL
- 5474** Benign symmetric lipomatosis (Madelung's disease) with concomitant incarcerated femoral hernia: A case report
Li B, Rang ZX, Weng JC, Xiong GZ, Dai XP
- 5480** Potential protection of indocyanine green on parathyroid gland function during near-infrared laparoscopic-assisted thyroidectomy: A case report and literature review
Peng SJ, Yang P, Dong YM, Yang L, Yang ZY, Hu XE, Bao GQ
- 5487** New treatment of patellar instability after total knee arthroplasty: A case report and review of literature
Shen XY, Zuo JL, Gao JP, Liu T, Xiao JL, Qin YG

CORRECTION

- 5494** Erratum: Author's Affiliation Correction. Type II human epidermal growth factor receptor heterogeneity is a poor prognosticator for type II human epidermal growth factor receptor positive gastric cancer (World J Clin Cases 2019; Aug 6; 7 (15): 1964-1977)
Kaito A, Kuwata T, Tokunaga M, Shitara K, Sato R, Akimoto T, Kinoshita T

ABOUT COVER

Peer-reviewer for *World Journal of Clinical Cases*, Dr. Karayiannakis is Professor of Surgery at the Medical School of Democritus University of Thrace. He received his MD from the Medical Academy, Sofia, Bulgaria (1985), an MSc in Surgical Science from University of London (1996), and a PhD from National and Kapodistrian University of Athens (NKUA) (1993). After completing training at the NKUA Medical School in 1993, Dr. Karayiannakis undertook postgraduate training at St George's and Hammersmith Hospitals (London), the Institute for Digestive Diseases (Serbia), the University of Verona (Italy), and the Technical University of Munich (Germany). His clinical practice interests and research emphasis are in the field of hepato-pancreato-biliary diseases and gastrointestinal tract surgery, surgical oncology and laparoscopic surgery. (L-Editor: Filipodia)

AIMS AND SCOPE

The primary aim of *World Journal of Clinical Cases* (*WJCC*, *World J Clin Cases*) is to provide scholars and readers from various fields of clinical medicine with a platform to publish high-quality clinical research articles and communicate their research findings online.

WJCC mainly publishes articles reporting research results and findings obtained in the field of clinical medicine and covering a wide range of topics, including case control studies, retrospective cohort studies, retrospective studies, clinical trials studies, observational studies, prospective studies, randomized controlled trials, randomized clinical trials, systematic reviews, meta-analysis, and case reports.

INDEXING/ABSTRACTING

The *WJCC* is now indexed in Science Citation Index Expanded (also known as SciSearch®), Journal Citation Reports/Science Edition, PubMed, and PubMed Central. The 2020 Edition of Journal Citation Reports® cites the 2019 impact factor (IF) for *WJCC* as 1.013; IF without journal self cites: 0.991; Ranking: 120 among 165 journals in medicine, general and internal; and Quartile category: Q3.

RESPONSIBLE EDITORS FOR THIS ISSUE

Production Editor: Yan-Xia Xing; Production Department Director: Yun-Xiaojuan Wu; Editorial Office Director: Jin-Lai Wang.

NAME OF JOURNAL

World Journal of Clinical Cases

ISSN

ISSN 2307-8960 (online)

LAUNCH DATE

April 16, 2013

FREQUENCY

Semimonthly

EDITORS-IN-CHIEF

Dennis A Bloomfield, Sandro Vento, Bao-Gan Peng

EDITORIAL BOARD MEMBERS

<https://www.wjgnet.com/2307-8960/editorialboard.htm>

PUBLICATION DATE

November 6, 2020

COPYRIGHT

© 2020 Baishideng Publishing Group Inc

INSTRUCTIONS TO AUTHORS

<https://www.wjgnet.com/bpg/gerinfo/204>

GUIDELINES FOR ETHICS DOCUMENTS

<https://www.wjgnet.com/bpg/GerInfo/287>

GUIDELINES FOR NON-NATIVE SPEAKERS OF ENGLISH

<https://www.wjgnet.com/bpg/gerinfo/240>

PUBLICATION ETHICS

<https://www.wjgnet.com/bpg/GerInfo/288>

PUBLICATION MISCONDUCT

<https://www.wjgnet.com/bpg/gerinfo/208>

ARTICLE PROCESSING CHARGE

<https://www.wjgnet.com/bpg/gerinfo/242>

STEPS FOR SUBMITTING MANUSCRIPTS

<https://www.wjgnet.com/bpg/GerInfo/239>

ONLINE SUBMISSION

<https://www.f6publishing.com>

Chinese patient with cerebrotendinous xanthomatosis confirmed by genetic testing: A case report and literature review

Lan-Xiao Cao, Mi Yang, Ying Liu, Wen-Ying Long, Guo-Hua Zhao

ORCID number: Lan-Xiao Cao 0000-0002-1560-9463; Mi Yang 0000-0003-3920-8979; Ying Liu 0000-0003-3076-1479; Wen-Ying Long 0000-0002-4888-6176; Guo-Hua Zhao 0000-0001-7943-209X.

Author contributions: Cao LX analyzed the data and drafted the manuscript for intellectual content; Yang M played a major role in the acquisition of data; Liu Y interpreted the patient data; Zhao GH and Long WY revised the manuscript for intellectual content; All authors read and approved the final manuscript.

Supported by Zhejiang Province Medical Science and Technology Project, No. 2020RC061 and No. 2019ZD021; Jinhua Bureau of Science and Technology Project, No. 2020-3-004.

Informed consent statement: Informed written consent was obtained from the patient for publication of this report and any accompanying images.

Conflict-of-interest statement: The authors declare that they have no competing interests.

CARE Checklist (2016) statement: The authors have read the CARE Checklist (2016), and the manuscript was prepared and revised according to the CARE

Lan-Xiao Cao, Mi Yang, Guo-Hua Zhao, Department of Neurology, The Fourth Affiliated Hospital, Zhejiang University School of Medicine, Yiwu 322000, Zhejiang Province, China

Ying Liu, Wen-Ying Long, Central Laboratory, The Fourth Affiliated Hospital, Zhejiang University School of Medicine, Yiwu 322000, Zhejiang Province, China

Corresponding author: Guo-Hua Zhao, MD, Doctor, Department of Neurology, The Fourth Affiliated Hospital, Zhejiang University School of Medicine, N1 Shangcheng Avenue Yiwu, Yiwu 322000, Zhejiang Province, China. gzhao@zju.edu.cn

Abstract

BACKGROUND

Cerebrotendinous xanthomatosis (CTX) is a treatable autosomal recessive inherited metabolic disorder. It results from a deficiency of sterol 27-hydroxylase (CYP27A1), which is a mitochondrial cytochrome P450 enzyme that catalyzes the hydroxylation of cholesterol and modulates cholesterol homeostasis. Patients with CYP27A1 deficiency show symptoms related to excessive accumulation of cholesterol and cholestanol in lipophilic tissues such as the brain, eyes, tendons, and vessels, resulting in juvenile cataracts, tendon xanthoma, chronic diarrhea, cognitive impairment, ataxia, spastic paraplegia, and peripheral neuropathy. CTX is underdiagnosed as knowledge of the disorder is mainly based on case reports.

CASE SUMMARY

A Chinese family with CTX consisting of one patient and four heterozygous carriers was studied. The patient is a 47-year-old male, who mainly had psychiatric signs but without some cardinal features of CTX such as cataracts, cerebellar ataxia, pyramidal signs and chronic diarrhea. There was a significant increase in the concentration of free fatty acid compared to normal range. Doppler ultrasound of the urinary system showed multiple left kidney stones, a right kidney cyst, and a hypoechoic area in the bladder, which could move with body position. Sagittal and axial magnetic resonance imaging (MRI) of the right ankle joint showed apparent enlargement of the right Achilles tendon and upper medial malleolus flexor tendon, abnormal thickening of the plantar fat, and a small amount of exudation around the fascia in front of the Achilles tendon. Cerebral MRI suggested white matter (WM) demyelination and slight cerebral atrophy. The diagnosis was confirmed by targeted sequencing, which identified compound heterozygous mutations in exon 2 and intron 7 of the *CYP27A1* gene (c.435G>T, c.1263+1G>A). Treatment for 3 wk with a combination of lipid-lowering and

Checklist (2016).

Open-Access: This article is an open-access article that was selected by an in-house editor and fully peer-reviewed by external reviewers. It is distributed in accordance with the Creative Commons Attribution NonCommercial (CC BY-NC 4.0) license, which permits others to distribute, remix, adapt, build upon this work non-commercially, and license their derivative works on different terms, provided the original work is properly cited and the use is non-commercial. See: <http://creativecommons.org/licenses/by-nc/4.0/>

Manuscript source: Unsolicited manuscript

Specialty type: Medicine, research and experimental

Country/Territory of origin: China

Peer-review report's scientific quality classification

Grade A (Excellent): 0
Grade B (Very good): 0
Grade C (Good): 0
Grade D (Fair): 0
Grade E (Poor): 0

Received: July 15, 2020

Peer-review started: July 17, 2020

First decision: August 8, 2020

Revised: August 9, 2020

Accepted: September 23, 2020

Article in press: September 23, 2020

Published online: November 6, 2020

P-Reviewer: Wu ZY

S-Editor: Huang P

L-Editor: Filipodia

P-Editor: Li X



antipsychotic therapy improved his psychiatric symptoms and normalized the levels of serum free fatty acid. Sediments in the bladder disappeared after therapy.

CONCLUSION

CYP27A1 genetic analysis should be the definitive method for CTX diagnosis. This case suggests that urinary system diseases may be neglected in CTX patients. The clinical, biological, radiological, and genetic characteristics of CTX are summarized to promote early diagnosis and treatment of this disease.

Key Words: Cerebrotendinous xanthomatosis; CYP27A1; Clinical; Genetic; Cholesterol; Case report; Metabolic diseases

©The Author(s) 2020. Published by Baishideng Publishing Group Inc. All rights reserved.

Core Tip: Cerebrotendinous xanthomatosis (CTX) is a metabolic disorder inherited in an autosomal recessive manner. A total of 520 CTX case reports published in the literature worldwide are reviewed to promote a better understanding of the clinical and genetic characteristics of CTX. Cataract is the most common symptom with a frequency of 80.37%, and xanthoma is the second most common systemic symptom of CTX. In all, 56.57% of patients showed electroencephalogram abnormalities including diffuse slowing, and 76.72% had abnormal magnetic resonance images. Bilateral hyperintensity of the dentate nuclei and surrounding white matter on T2 and fluid-attenuated inversion recovery sequences is considered a representative radiological feature of CTX.

Citation: Cao LX, Yang M, Liu Y, Long WY, Zhao GH. Chinese patient with cerebrotendinous xanthomatosis confirmed by genetic testing: A case report and literature review. *World J Clin Cases* 2020; 8(21): 5446-5456

URL: <https://www.wjgnet.com/2307-8960/full/v8/i21/5446.htm>

DOI: <https://dx.doi.org/10.12998/wjcc.v8.i21.5446>

INTRODUCTION

Cerebrotendinous xanthomatosis (CTX) is a metabolic disorder inherited in an autosomal recessive manner. It is caused by mutations of the CYP27A1 gene, which encodes sterol 27-hydroxylase^[1]. Sterol 27-hydroxylase is a cytochrome P450 enzyme which converts cholesterol into polar metabolites that can leave cells rapidly, leading to excessive accumulation of cholesterol and cholesterol in lipophilic tissues like the brain, eyes, tendons and blood vessels, and also increasing the risk of premature atherosclerosis^[2-4]. The core clinical manifestations are juvenile cataracts, tendon xanthoma, chronic diarrhea, and neurological symptoms such as intellectual disability, cognitive decline, ataxia, spastic paraplegia, peripheral neuropathy, Parkinsonism, and epilepsy. Other symptoms include psychiatric and behavioral disturbances, spinal xanthomatosis, oromandibular dystonia, osteoporosis with multiple fractures, neonatal cholestasis, pediatric hepatology, chronic renal failure and cardiovascular and cerebrovascular atherosclerosis^[5-11]. CTX is underdiagnosed as knowledge of the disorder is mainly based on case reports, and although several hundred of these exist the actual number of patients is likely to be much greater. In addition, prevalence of CTX varies in different ethnic groups. In Caucasian populations, the rate has been found to range from 1/70000^[12] to 5/100000^[13]. A worldwide epidemiological study calculated allele frequency of the 57 CTX-causing mutations in an ExAC cohort of approximately 60000 unrelated adults, placing the incidence of CTX at 1/36072-1/75601 in South Asians, 1/64247-1/64712 in East Asians, 1/71677-1/148914 in Americans, 1/134970-1/461358 in Europeans, and 1/263222-1/468624 in Africans^[14].

To date, at least 50 variants of the CYP27A1 gene have been identified^[15]. Molecular analysis is a widely used tool for confirming a CTX diagnosis. However, it is difficult to establish the genotype and phenotype relationships of this disorder due to clinical heterogeneity. In one study, even twins with same pathogenic CYP27A1 mutations

and similar lifestyles and diets presented with heterogeneous clinical features^[16]. CTX is a treatable disease, but the effect of therapy is heavily dependent on the age of the patient receiving medication. There may be a delay of 20-25 years between the first symptoms in childhood (for instance, diarrhea, cataracts, intellectual disability and epilepsy) and later symptoms including apparent neurological disturbances such as walking difficulties and cognitive impairment^[17]. The age at onset of symptoms is inevitably affected by recall bias and may not be accurate. Shortening the diagnostic delay should be given greater importance in clinical practice, not only for neurologists but also for pediatricians, psychiatrists and ophthalmologists.

Herein, we report the clinical, imaging and molecular characteristics of a Chinese patient with CTX confirmed by genetic testing. Meanwhile, 520 CTX case reports published in the past 30 years are reviewed to promote better understanding of the clinical and genetic characteristics of CTX.

CASE PRESENTATION

Chief complaints

A 47-year-old male was admitted to our institution with a history of intellectual disability for more than 30 years and behavioral abnormalities for the past 3 mo. He had a poor academic performance, having dropped out after completing elementary school. The patient could talk with others in daily life, but he was unable to do housework.

History of present illness

Three months ago, he underwent an operation for renal calculus, after which he showed progressive delusion (he believed unreasonably that he had a serious disease and was going to die), combined with slow response and speech reduction. At 1 wk before admission, he was unable to answer questions and developed an eating difficulty, incontinence, fever ($T \leq 38.2\text{ }^{\circ}\text{C}$) and severe weight loss. Chronic diarrhea was absent.

Personal and family history

The proband is the 4th child of 5 in a non-consanguineous Chinese family. His family history was negative for symptoms related to neurological disorders. He was divorced twice and had no children, and did not have a history of smoking or drinking. The proband's parents had died and his mother had a history of uremia. All of his four sisters are healthy (Figure 1A).

Physical examination

The patient had dark skin and a poor mental state (Figure 2A). Neurological examination indicated cervical rigidity and Kernig sign. Deep tendon reflexes and limb muscle strength were normal. Babinski sign was negative. Enlarged Achilles tendons and nodules on the bilateral tibial tubercles were observed (Figure 2B and C). There was no evidence of cataract or xanthomas at other sites such as the eyelids.

Laboratory examinations

The laboratory results (Table 1) were as follows: Increased leukocyte count, neutrophil ratio and high erythrocyte sedimentation rate. There was also a significant increase in concentration of free fatty acid compared to normal range. In contrast, levels of high-density lipoprotein cholesterol were low. Serum cholesterol, glucose, electrolytes, and adrenocorticotrophic hormone (ACTH) levels were all normal, as were the liver function tests. Doppler ultrasound of the urinary system showed multiple left kidney stones, a right kidney cyst, and a hypoechoic area in the bladder which could move with body position (Figure 2D). Cerebrospinal fluid protein was mildly elevated: 680.4 mg/L (normal range: 150-400 mg/L).

Imaging examinations

X-ray of the lower limbs showed soft tissue swelling above the tibial tuberosities bilaterally (Figure 2E). Sagittal and axial magnetic resonance imaging (MRI) of the right ankle joint showed apparent enlargement of the right Achilles tendon and upper medial malleolus flexor tendon (consisting of low signal intensity on both T1- and T2-weighted images), abnormal thickening of the plantar fat, and a small amount of exudation around the fascia in front of the Achilles tendon (Figure 2F). The

Table 1 Laboratory results in the index patient

	Value	Normal range		Value	Normal range		Value	Normal range
Leukocyte count ($10^9/L$)	10.7 ↑	4.0-10.0	Follicle stimulating hormone (IU/L)	19.75 ↑	1.27-19.26	Intracranial pressure (mmH ₂ O)	170	70-180
Neutrophil ratio (%)	81.6 ↑	50.0-70.0	Testosterone (nmol/L)	4.53 ↓	6.07-27.10	CSF Pandy test	+	-
Erythrocyte count ($10^{12}/L$)	6.06 ↑	4.09-5.74	ACTH 12am (ng/L)	9.49	< 46	CSF erythrocyte count ($10^6/L$)	0	0-1
Hb (g/L)	126 ↓	131-172	ACTH 8am (ng/L)	43.64	7.2-63.0	CSF karyocyte count ($10^6/L$)	2	6-10
ESR (mm/h)	26 ↑	0-15	ACTH 4pm (ng/L)	13.18	< 46	CSF protein (mg/L)	680.4 ↑	150-450
Free fatty acid ($\mu\text{mol}/L$)	1127.7 ↑	100-760	Serum cortisol 12am ($\mu\text{g}/L$)	165.92	None	CSF Cl ⁻ (mmol/L)	133.6 ↑	112-120
HDL-cholesterol (mmol/L)	0.73 ↓	0.90-2.19	Serum cortisol 8am ($\mu\text{g}/L$)	267.83	52.7-224.5	CSF glucose (mmol/L)	4.32	1.5-4.5
Prolactin (mIU/L)	335 ↑	55.96-278.35	Serum cortisol 4pm ($\mu\text{g}/L$)	85.45	34.4-167.6	CSF adenosine deaminase (U/L)	1	0-5
High sensitivity thyrotropin (mIU/L)	0.24 ↓	0.38-5.58						

ACTH: Adrenocorticotrophic hormone; CSF: Conventional cerebrospinal fluid; ESR: Erythrocyte sedimentation rate; HDL: High-density lipoprotein.

electroencephalogram (EEG) showed increased slow activities than normal and electrophysiological examination found mixed sensorimotor neuropathy of the upper and lower limbs. Cerebral MRI suggested white matter (WM) demyelination and slight cerebral atrophy (Figure 2G and H).

Genetic testing

Genomic DNA was isolated from blood samples of the patient and his four healthy sisters. Mutation screening of all exons and flanking regions was performed on the patient's sample by targeted sequencing as previously reported^[18]. Targeted sequencing revealed that the proband had compound heterozygous mutations in the *CYP27A1* gene and that his four sisters were mutation carriers (Figure 1B-E, and Table 2). Both of the variants found are known pathogenic mutations of CTX. The variant in exon 2 (c.435G>T, p.Gly145Gly), a functionally silent nucleotide substitution, has been reported to activate a 5' splice site, leading to alternative pre-mRNA splicing^[19]. The other variant (c.1263+1G>A) is a splice site mutation that disrupts normal mRNA splicing and results in exon 7 being skipped in the transcript^[20]. In Italian and Japanese patients, the variant has been found to cause loss of a heme binding domain, a vital part of hydroxylase, and to damage bile acid synthesis^[20,21].

FINAL DIAGNOSIS

On the basis of the clinical features and the results of supplemental studies, a diagnosis of CTX was the first conclusion. Addison's disease, listed as a differential diagnosis due to his skin pigmentation and intellectual disability, was excluded due to the normal level of serum cortisol and ACTH. The diagnosis of CTX was confirmed by genetic analysis, which showed compound pathogenic heterozygous mutations in the *CYP27A1* gene.

TREATMENT

The patient was treated with a combination of 10 mg rosuvastatin once per night, 10 mg of ezetimibe once per night, and paliperidone (1 mg in the morning and 2 mg at night). He was provided with 0.25 g chenodeoxycholic acid (CDCA) three times per day in our hospital. He was also provided enteral nutritional support through a

Table 2 Results of genetic analysis in this family						
Patient	Mutation	Exon/intron	Protein	Molecular consequence	Results	Ref.
II:2, II:4 and II:5	c.1263+1G>A	IVS7	-	Splice site mutation	Pathogenic	Shiga <i>et al</i> ^[20]
II:1,II:3 and II:4	c.435G>T	Exon 2	p.G145G	Splice site mutation	Pathogenic	Chen <i>et al</i> ^[19] (in homozygous state)

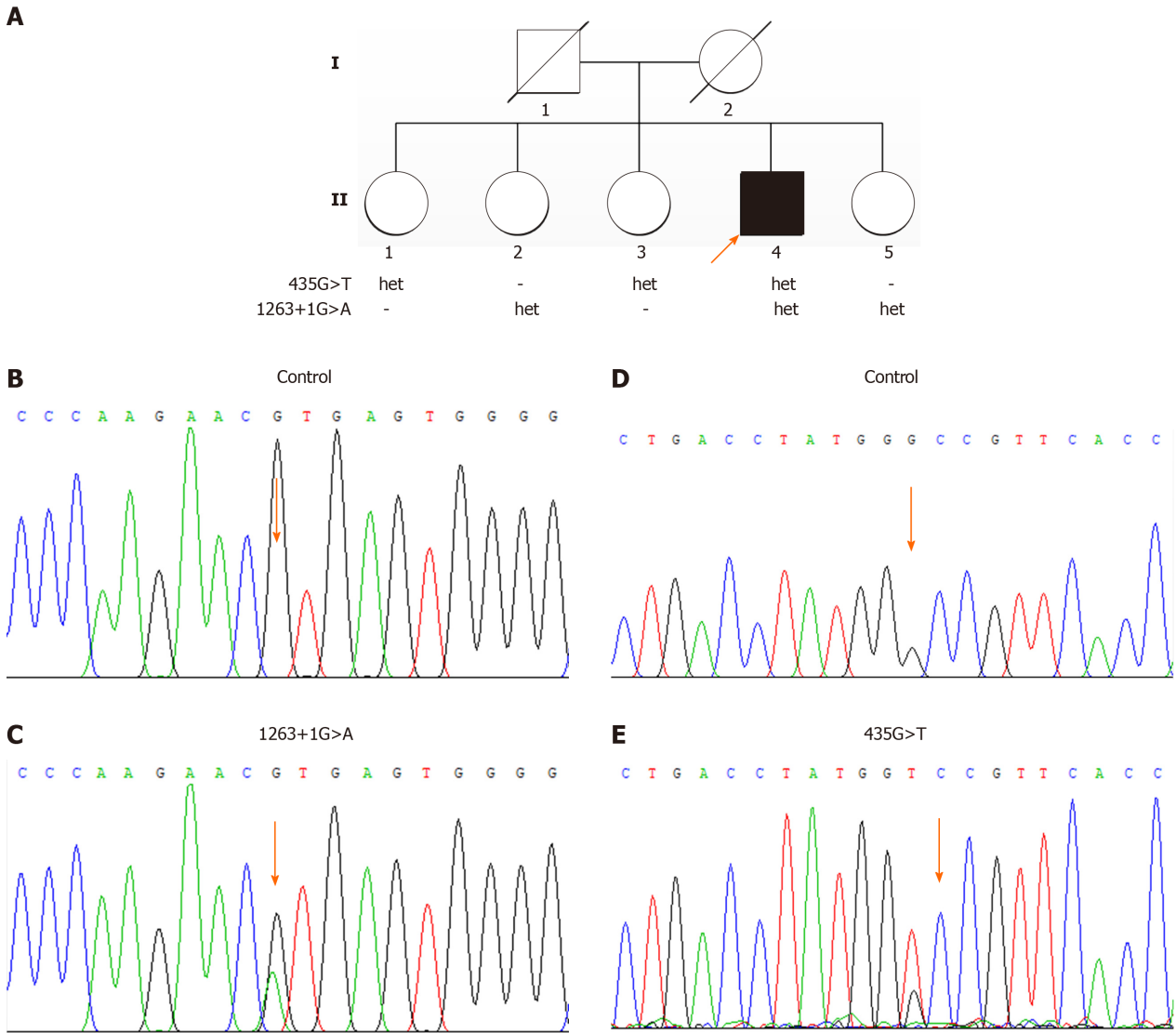


Figure 1 The pedigree of the family and the genetic test results. A: The pedigree of the family with compound heterozygous *CYP27A1* mutations; B and D: The normal control sequences; C: The variant in intron 7 (c.1263+1G>A); E: The variant in exon 2 (c.435G>T, p.Gly145Gly). Family members II:2 and II:5 were carriers of c.1263+1G>A and family members II:1 and II:3 were the carriers of c.435G>T. Family member II:4 carried the compound heterozygous *CYP27A1* mutations.

nasogastric feeding tube.

OUTCOME AND FOLLOW-UP

After a 3 wk treatment program, the patient’s skin became brighter, he showed an improvement of mental symptoms, and his psychiatric symptoms substantially improved. He could answer simple questions correctly and walk with help. The serum free fatty acid level decreased to less than half of the pretreatment level (from 1127.7 μmol/L to 523.1 μmol/L). The urinary system B-ultrasounds performed after treatment suggested sediments in the bladder had disappeared. After he was discharged, he persisted the medication of CDCA.

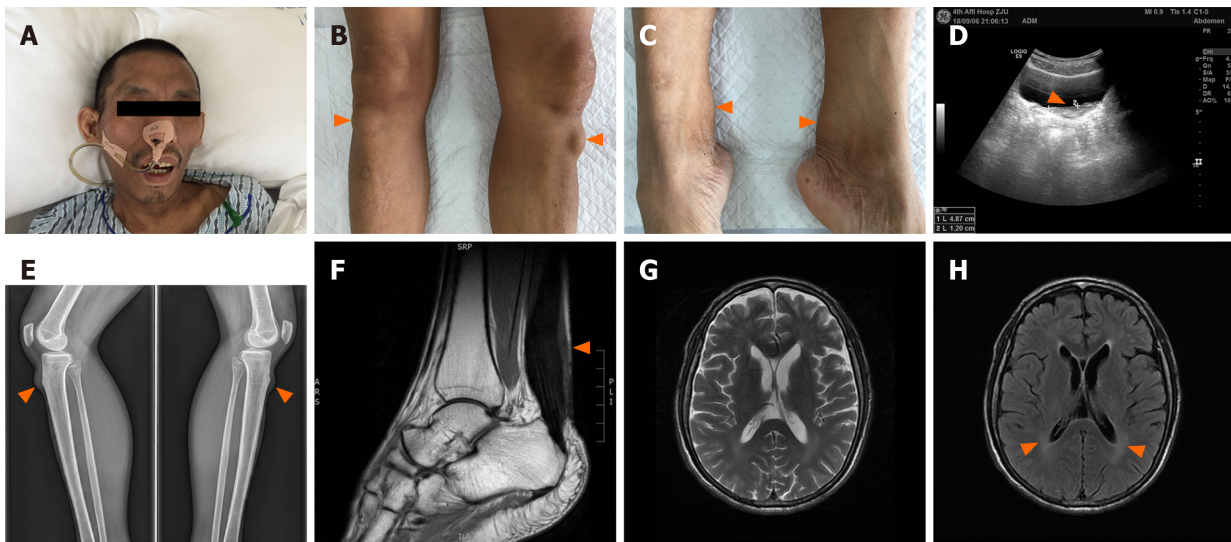


Figure 2 Clinical and imaging data of the patient. A: The dark skin and poor mental state of the patient; B: Arrowheads show the nodules on the bilateral tibial tubercles; C: Arrowheads show the enlarged Achilles tendons; D: B-ultrasound of the urinary system, showing the hypoechoic area (arrowhead) in the bladder which can move with body position; E: X-ray of the lower limbs showing swelling of the soft tissue below the bilateral tibial tuberosities (arrowheads); F: Sagittal T1-weighted magnetic resonance (MR) image showing fusiform swelling of the right Achilles tendon and upper medial malleolus flexor tendon, abnormal thickening of the plantar fat, and a small amount of exudation around the fascia in front of the Achilles tendon; G: Axial T2-weighted MR image suggesting mild ventricular enlargement and cerebral atrophy; H: Axial fluid-attenuated inversion recovery MR image showing an abnormal hyperintense signal around the ventricle posterior horn bilaterally (arrowheads).

DISCUSSION

CTX, MIM# 213700, is a rare hereditary lipid storage disease whose precise epidemiological features are unknown because findings largely depend on case reports^[11]. In the past 30 years, more than 500 CTX cases have been reported worldwide, with the highest frequencies reported in Italy, the Netherlands, Spain, Japan, and China (Figure 3). We have reviewed previous literature reporting CTX cases and summarize the clinical and genetic features of patients in Supplementary Table 1.

Clinical characteristics of CTX

CTX patients from all over the world share certain clinical features, which are shown in Figure 3. Also shown are features in Italian and Japanese populations as representatives for Caucasians and Asians, to highlight characteristics from different origins.

In 520 global CTX cases (Figure 3, Supplementary Table 1), cataract is the most common symptom with a frequency of 80.37%, and it is usually diagnosed in the second decade of life^[17]. However, its diagnostic role is less evident in Japan as only 60.00% of patients showed this sign^[11]. Xanthoma is the second most common systemic symptom of CTX, and it is notable that it has a much higher frequency in Japanese patients (95.0%)^[11]. Cognitive impairment is the most common neurological presentation, followed by pyramidal signs and cerebellar ataxia (72.95% and 63.89%, respectively). Peripheral neuropathy and chronic diarrhea are also very common, particularly in Italian patients, where the prevalence rates were 78.87% and 70.00%, respectively. Epilepsy is a relatively unusual presentation of CTX, but it sometimes appears as the initial symptom; thus CTX should be considered as a possible cause of seizure^[11]. Parkinsonism is less frequent and is usually seen at an older age^[11].

Awareness of psychiatric signs in CTX is growing in neurologists and psychiatrists, but these signs are rarely isolated in CTX^[22], as seen in the present case. They are characterized by learning difficulties/cognitive impairment in childhood or adolescence; and behavioral disturbance, affective/mood disorders, personality changes and psychotic disorders in the advanced stage of the disease^[23].

The multiple systematic features in patients indicate that almost every organ is involved in this disease. Other than the symptoms mentioned above, aberrant calcium deposits in the urinary system, nephrocalcinosis, nephrolithiasis and renal failure have been reported in CTX, although with a relatively low incidence^[11,24]. The patient in this paper had a history of renal calculus and sediments in the bladder, which disappeared

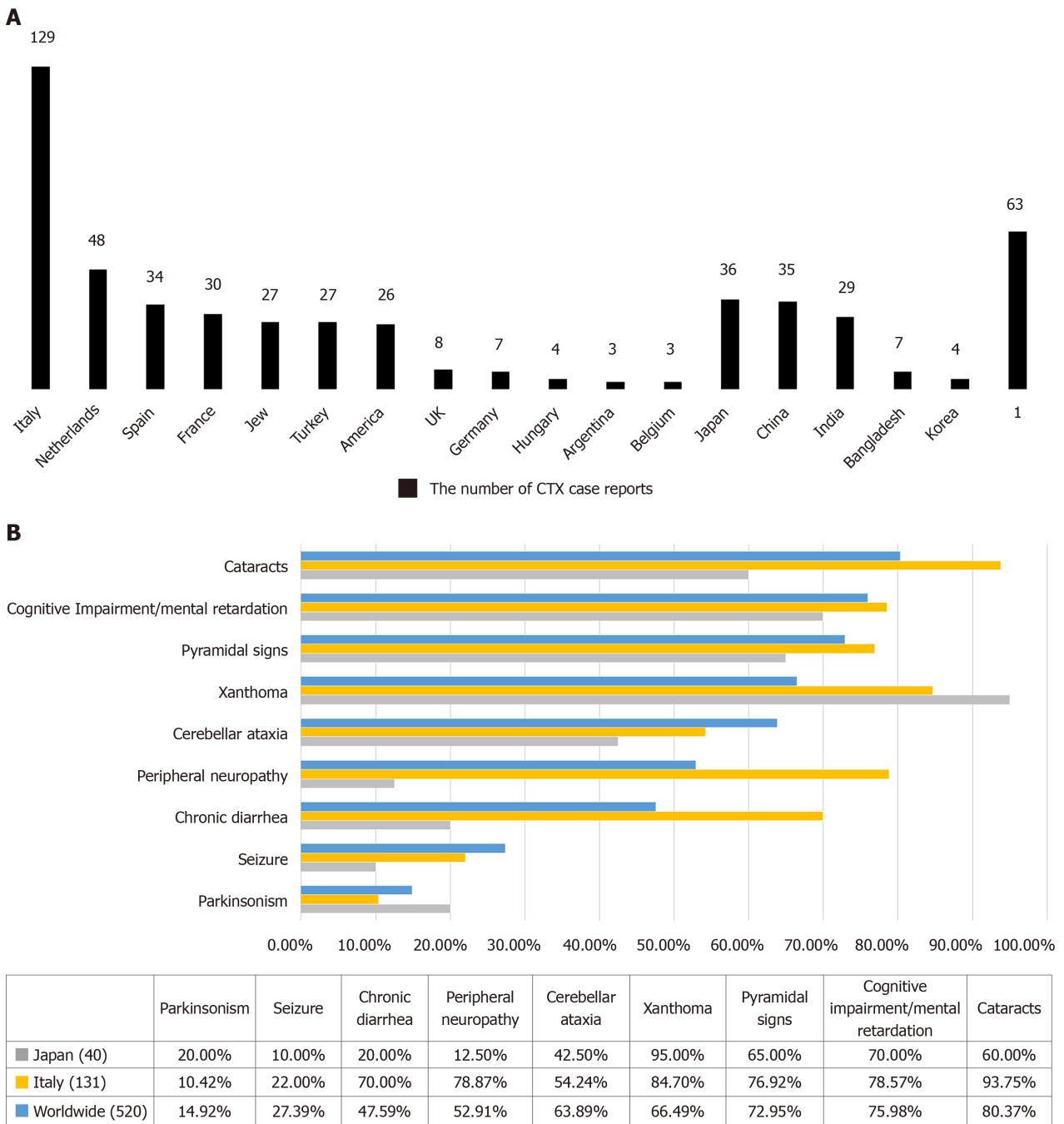


Figure 3 Main symptoms in cerebrotendinous xanthomatosis case reports from different ethnic groups. ¹Refers to other origins and unclassified cases. A: The number of cerebrotendinous xanthomatosis (CTX) case reports from different origins in the past 30 years; B: Comparison of the frequencies of the main symptoms in CTX patients from all over the world.

after treatment and might be associated with increased urinary bile alcohols. We cannot rule out the possibility that these urinary system diseases are neglected in CTX cases. More valuable clinical features are likely to be identified if complete examinations were performed in every CTX patient.

Phenotypes of CTX can vary considerably in intrafamilial cases, even in identical twins having similar lifestyles^[16,25]. Different phenotypes may be associated with certain genetic modifiers or epigenetic changes that are undiscovered today^[16]. Whether environmental factors play a role in the pathogenesis of CTX is still unclear. Mignarri *et al*^[17] developed a simple and effective diagnostic tool named the suspicion index. Using this tool, our patient received a total score of 225, which is a very strong indicator for CTX. However, these authors also recommended that *CYP27A1* genetic analysis should be the definitive method for diagnosis^[17].

Genetic features

The *CYP27A1* gene is located in chromosome locus 2q35 and consists of 9 exons and 8 introns that encode 531 amino acids. Known pathogenic mutations causing CTX are distributed in all exons and in introns 2, 4, 6, 7 and 8^[26,27], but nearly half of all mutations are found in exons 6-8^[26]. A genetic review in 2006 of 49 different mutations suggested that 45% are missense mutations, 20% are nonsense mutations, and 18% are splice site mutations. The remaining mutations were seven deletions (14%) and one insertion (2%)^[1]. Missense mutations could impair the stability and catalytic efficacy of the enzyme; splice site mutations cause abnormal splicing and exon skipping; and deletion, insertion and nonsense mutations lead to a truncation of the mRNA and an incomplete enzyme structure^[26]. It was reported that some mutations occurred more frequently in some ethnic groups, such as c.1214G>A (p.R405Q) in Japanese patients, c.1183C>T (p.R395C) in patients of Spanish origin and c.646G>C (p.A216P) in Italian patients^[1,11,15].

No published case report has yet identified mutations in genes other than *CYP27A1* in CTX patients^[28]. It is not yet certain if there are any correlations between phenotypes and genotypes in this rare disease^[1,29]. In 2018, Sekijima *et al*^[11] discovered that three mutations were associated with certain phenotypes in Japanese patients: c.1421G>A (p.R474Q) was associated with the classical form; c.1214G>A (p.R405Q) with the spinal form; and c.435G>T (p.G145G) with the non-neurological CTX form. In Chinese population, the most frequent CTX-causing variants were c.410G>A (p.R137Q) and c.379C>T (p.R127W)^[30,31]. *CYP27A1* is also considered a causative gene of coronary artery disease, possibly related to its effect on reverse cholesterol transport^[32].

Biological and imaging features

The biochemical abnormalities detected in CTX are significant for diagnosis. The lack of sterol 27-hydroxylase inhibits the conversion of cholesterol into cholic and chenodeoxycholic acids in the liver^[12]. The serum levels of cholesterol and triglyceride are usually normal while cholestanol levels are markedly high in the blood, bile and tendon xanthoma^[12]. Since cholesterol synthesis is systematically decreased, cholesterol precursors increase substantially; this could also be regarded as a hallmark of CTX^[33]. Although a high cholestanol level indicates CTX, it does not correlate with any symptoms or disability at diagnosis assessed by the Expanded Disability Status Scale^[34].

Fast atom bombardment mass spectrometry is a semiquantitative technique which can be applied to analyze urinary bile acids. It will strongly support a diagnosis of CTX if increased bile alcohol glucuronides and reduced primary bile acid are detected^[35]. However, when the urinary bile acid profile is consistent with CTX, propofol administration should be taken into account as another possible cause, to avoid misdiagnoses^[36]. The combination of extremely low levels of 27-hydroxycholesterol (< 5 ng/mL or lower than the detection limit) and extremely high serum levels of 7 alpha-hydroxycholesterol (7α-OH-C) or 7 alpha-hydroxy-4-cholesten-3-one (7αC4) is a distinctive feature of CTX^[36]. Both 7α-OH-C and 7αC4 have been suggested as ideal biomarkers for evaluating treatment effects^[37].

With respect to auxiliary examinations, 56.57% of patients showed EEG abnormalities including diffuse slowing, which is a common feature of CTX patients. In addition, 76.72% had abnormal magnetic resonance (MR) images ([Supplementary Table 1](#)). The main brain MRI abnormalities include supratentorial and infratentorial atrophy, as well as T2W/FLAIR (fluid-attenuated inversion recovery) hyperintensity involving the subcortical, periventricular and cerebellar WM and the brainstem^[38]. Bilateral hyperintensity of the dentate nuclei (DN) and surrounding WM on T2 and FLAIR sequences is considered a representative radiological feature of CTX^[39,40]. DN plays a critical role in saccade motor planning within a network that involves the frontal cortex and basal ganglia^[41]. Patients with DN lesions showed abnormal latency of reflexive and voluntary saccades, impaired precision and more uncorrected directional errors^[41]. There is a strong correlation between DN hyperintensity in brain MRI and neurological manifestations including ataxia, spasticity and cognitive impairment^[38]. Patients without DN hyperintensity are considered to have a better prognosis^[38].

A 6-year MR follow-up study revealed that cerebellar hyperintensity in T1-weighted and FLAIR images tend to be replaced by hypointense areas, suggesting vacuolation^[42]. Cerebellar hyperintensity on FLAIR images is probably due to lipid deposits, while hypointense areas may indicate cerebellar degeneration because of cholestanol-induced apoptosis or other mechanisms causing axonal injury^[42,43]. Cerebellar vacuolation and calcification have been observed in a large number of

patients. The former was positively related to the extent of DN hyperintensity in T1W and FLAIR images, and could be a useful indicator of disease progression and inadequate therapeutic response^[38]. Additionally, cerebral micro- and macro-angiopathies such as micro-hemorrhages, vascular dilatation and calcification are common in CTX patients^[44]. The xanthomas located within the ventricular region have also been observed in CTX cases^[45].

The main components of xanthoma are connective tissue and foam cells (foamy macrophages) bathed in cholestanol, cholesterol, cholesterol esters, triglycerides and phospholipids^[46]. The presence of Touton giant cells is a characteristic pathological finding^[47]. The development of tendon xanthomas may be associated with low-grade tendon inflammation^[48]. A tendon MRI study indicated that the enlargement of tendon xanthomas is primarily due to an increase in tendon water content, rather than in fat content^[49]. Tendinous xanthomas have different appearances on MR depending on the proportions of the following components: cholesterol, which does not produce a measurable signal; triglycerides, which produce a high signal on T1-weighted images; and associated inflammation, which causes high signal intensity regions in contrast-enhanced T1-weighted images^[46,50,51]. The diffuse reticulated pattern of xanthomas on axial images is a representative MRI feature of tendinous xanthoma^[52]. This patient's MRI showed enlargement of the Achilles tendon, which showed up as low signal intensity on both T1- and T2-weighted images. This fits well with previous reports and could be attributed to the low percentage of triglycerides^[46].

In conclusion, we described a 47-year-old patient displaying psychiatric and behavioral disturbances, cognitive decline, a history of renal calculus, bilateral xanthomas of the Achilles tendon and tibial tubercles, peripheral neuropathy, high signal intensity in the WM and mild cerebral atrophy on brain MRI. The diagnosis was confirmed by compound heterozygous mutations in exon 2 (c.435G>T, p.Gly145Gly) and intron 7 (c.1263+1G>A) of the *CYP27A1* gene. These lead to alternative pre-mRNA splicing and a skipping of exon 7 in the transcript, respectively. Three weeks' treatment with a combination of lipid-lowering and antipsychotic therapy improved his psychiatric symptoms and normalized levels of serum free fatty acid. Sediments in the bladder disappeared after therapy.

CONCLUSION

CTX is an underdiagnosed inherited metabolic disease, and has a good biological and clinical response to the treatment of CDCA supplementation initiated at an early age. The screening methods for CTX in newborns need to be improved and performed in larger populations. We believe that our work will familiarize readers with the clinical, biological, radiological, and genetic features of CTX. In the future, as physicians become more familiar with this disease, and as testing and treatment methods evolve, an increasing number of CTX patients will benefit from earlier diagnosis and better clinical outcomes.

ACKNOWLEDGEMENTS

We appreciate the family members for participating in our study.

REFERENCES

- 1 **Gallus GN**, Dotti MT, Federico A. Clinical and molecular diagnosis of cerebrotendinous xanthomatosis with a review of the mutations in the *CYP27A1* gene. *Neurol Sci* 2006; **27**: 143-149 [PMID: 16816916 DOI: 10.1007/s10072-006-0618-7]
- 2 **von Bahr S**, Movin T, Papadogiannakis N, Pikuleva I, Rönnow P, Diczfalussy U, Björkhem I. Mechanism of accumulation of cholesterol and cholestanol in tendons and the role of sterol 27-hydroxylase (*CYP27A1*). *Arterioscler Thromb Vasc Biol* 2002; **22**: 1129-1135 [PMID: 12117727 DOI: 10.1161/01.ATV.0000022600.61391.A5]
- 3 **Federico A**, Dotti MT. Cerebrotendinous xanthomatosis: clinical manifestations, diagnostic criteria, pathogenesis, and therapy. *J Child Neurol* 2003; **18**: 633-638 [PMID: 14572142 DOI: 10.1177/08830738030180091001]
- 4 **Kalidas K**, Behrouz R. Inherited metabolic disorders and cerebral infarction. *Expert Rev Neurother* 2008; **8**: 1731-1741 [PMID: 18986243 DOI: 10.1586/14737175.8.11.1731]
- 5 **Bartholdi D**, Zumsteg D, Verrips A, Wevers RA, Sistermans E, Hess K, Jung HH. Spinal phenotype of cerebrotendinous xanthomatosis--a pitfall in the diagnosis of multiple sclerosis. *J Neurol* 2004; **251**: 105-107

- [PMID: 14999499 DOI: 10.1007/s00415-004-0221-x]
- 6 **Valdivielso P**, Calandra S, Durán JC, Garuti R, Herrera E, González P. Coronary heart disease in a patient with cerebrotendinous xanthomatosis. *J Intern Med* 2004; **255**: 680-683 [PMID: 15147532 DOI: 10.1111/j.1365-2796.2004.01316.x]
 - 7 **von Bahr S**, Björkhem I, Van't Hooft F, Alvelius G, Nemeth A, Sjövall J, Fischler B. Mutation in the sterol 27-hydroxylase gene associated with fatal cholestasis in infancy. *J Pediatr Gastroenterol Nutr* 2005; **40**: 481-486 [PMID: 15795599 DOI: 10.1097/01.mpg.0000150419.23031.2a]
 - 8 **Kaneko H**, Hirose M, Katada S, Takahashi T, Naruse S, Tsuchiya M, Yoshida T, Nakagawa M, Onodera O, Nishizawa M, Ikeuchi T. Novel GFAP mutation in patient with adult-onset Alexander disease presenting with spastic ataxia. *Mov Disord* 2009; **24**: 1393-1395 [PMID: 19412928 DOI: 10.1002/mds.22556]
 - 9 **Gallus GN**, Dotti MT, Mignarri A, Rufa A, Da Pozzo P, Cardaioli E, Federico A. Four novel CYP27A1 mutations in seven Italian patients with CTX. *Eur J Neurol* 2010; **17**: 1259-1262 [PMID: 20402754 DOI: 10.1111/j.1468-1331.2010.03002.x]
 - 10 **Degos B**, Nadjar Y, Amador Mdel M, Lamari F, Sedel F, Roze E, Couvert P, Mochel F. Natural history of cerebrotendinous xanthomatosis: a paediatric disease diagnosed in adulthood. *Orphanet J Rare Dis* 2016; **11**: 41 [PMID: 27084087 DOI: 10.1186/s13023-016-0419-x]
 - 11 **Sekijima Y**, Koyama S, Yoshinaga T, Koinuma M, Inaba Y. Nationwide survey on cerebrotendinous xanthomatosis in Japan. *J Hum Genet* 2018; **63**: 271-280 [PMID: 29321515 DOI: 10.1038/s10038-017-0389-4]
 - 12 **Rafiq M**, Sharrack N, Shaw PJ, Hadjivassiliou M. A neurological rarity not to be missed: cerebrotendinous xanthomatosis. *Pract Neurol* 2011; **11**: 296-300 [PMID: 21921005 DOI: 10.1136/practneurol-2011-000003]
 - 13 **Lorincz MT**, Rainier S, Thomas D, Fink JK. Cerebrotendinous xanthomatosis: possible higher prevalence than previously recognized. *Arch Neurol* 2005; **62**: 1459-1463 [PMID: 16157755 DOI: 10.1001/archneur.62.9.1459]
 - 14 **Appadurai V**, DeBarber A, Chiang PW, Patel SB, Steiner RD, Tyler C, Bonnen PE. Apparent underdiagnosis of Cerebrotendinous Xanthomatosis revealed by analysis of ~60,000 human exomes. *Mol Genet Metab* 2015; **116**: 298-304 [PMID: 26643207 DOI: 10.1016/j.ymgme.2015.10.010]
 - 15 **Smalley SV**, Preiss Y, Suazo J, Vega JA, Angellotti I, Lagos CF, Rivera E, Kleinstein K, Campion J, Martinez JA, Maiz A, Santos JL. Novel splice-affecting variants in CYP27A1 gene in two Chilean patients with Cerebrotendinous Xanthomatosis. *Genet Mol Biol* 2015; **38**: 30-36 [PMID: 25983621 DOI: 10.1590/S1415-475738120140087]
 - 16 **Zádori D**, Szpisjak L, Madar L, Varga VE, Csányi B, Bencsik K, Balogh I, Harangi M, Kereszty É, Vécsei L, Klivényi P. Different phenotypes in identical twins with cerebrotendinous xanthomatosis: case series. *Neurol Sci* 2017; **38**: 481-483 [PMID: 27888347 DOI: 10.1007/s10072-016-2776-6]
 - 17 **Mignarri A**, Gallus GN, Dotti MT, Federico A. A suspicion index for early diagnosis and treatment of cerebrotendinous xanthomatosis. *J Inher Metab Dis* 2014; **37**: 421-429 [PMID: 24442603 DOI: 10.1007/s10545-013-9674-3]
 - 18 **Xu H**, Zhang C, Cao L, Song J, Xu X, Zhang B, Chen B, Zhao G. ATL3 gene mutation in a Chinese family with hereditary sensory neuropathy type 1F. *J Peripher Nerv Syst* 2019; **24**: 150-155 [PMID: 30680846 DOI: 10.1111/jns.12309]
 - 19 **Chen W**, Kubota S, Teramoto T, Nishimura Y, Yonemoto K, Seyama Y. Silent nucleotide substitution in the sterol 27-hydroxylase gene (CYP 27) leads to alternative pre-mRNA splicing by activating a cryptic 5' splice site at the mutant codon in cerebrotendinous xanthomatosis patients. *Biochemistry* 1998; **37**: 4420-4428 [PMID: 9521761 DOI: 10.1021/bi972940a]
 - 20 **Shiga K**, Fukuyama R, Kimura S, Nakajima K, Fushiki S. Mutation of the sterol 27-hydroxylase gene (CYP27) results in truncation of mRNA expressed in leucocytes in a Japanese family with cerebrotendinous xanthomatosis. *J Neurol Neurosurg Psychiatry* 1999; **67**: 675-677 [PMID: 10519880 DOI: 10.1136/jnnp.67.5.675]
 - 21 **Garuti R**, Lelli N, Barozzini M, Tiozzo R, Dotti MT, Federico A, Ottomano AM, Croce A, Bertolini S, Calandra S. Cerebrotendinous xanthomatosis caused by two new mutations of the sterol-27-hydroxylase gene that disrupt mRNA splicing. *J Lipid Res* 1996; **37**: 1459-1467 [PMID: 8827518]
 - 22 **Sedel F**, Baumann N, Turpin JC, Lyon-Caen O, Saudubray JM, Cohen D. Psychiatric manifestations revealing inborn errors of metabolism in adolescents and adults. *J Inher Metab Dis* 2007; **30**: 631-641 [PMID: 17694356 DOI: 10.1007/s10545-007-0661-4]
 - 23 **Fraidakis MJ**. Psychiatric manifestations in cerebrotendinous xanthomatosis. *Transl Psychiatry* 2013; **3**: e302 [PMID: 24002088 DOI: 10.1038/tp.2013.76]
 - 24 **Chang WN**, Cheng YF. Nephrolithiasis and nephrocalcinosis in cerebrotendinous xanthomatosis: report of three siblings. *Eur Neurol* 1995; **35**: 55-57 [PMID: 7737249 DOI: 10.1159/000117091]
 - 25 **Verrips A**, van Engelen BG, Wevers RA, van Geel BM, Cruysberg JR, van den Heuvel LP, Keyser A, Gabreëls FJ. Presence of diarrhea and absence of tendon xanthomas in patients with cerebrotendinous xanthomatosis. *Arch Neurol* 2000; **57**: 520-524 [PMID: 10768627 DOI: 10.1001/archneur.57.4.520]
 - 26 **Lorbek G**, Lewinska M, Rozman D. Cytochrome P450s in the synthesis of cholesterol and bile acids—from mouse models to human diseases. *FEBS J* 2012; **279**: 1516-1533 [PMID: 22111624 DOI: 10.1111/j.1742-4658.2011.08432.x]
 - 27 **Nie S**, Chen G, Cao X, Zhang Y. Cerebrotendinous xanthomatosis: a comprehensive review of pathogenesis, clinical manifestations, diagnosis, and management. *Orphanet J Rare Dis* 2014; **9**: 179 [PMID: 25424010 DOI: 10.1186/s13023-014-0179-4]
 - 28 **Jiao H**, Olin M, Hansson M, Eggertsen G, Eriksson M, Angelin B, Björkhem I. Unique case of cerebrotendinous xanthomatosis revisited: All the mutations responsible for this disease are present in the CYP27A1 gene. *J Intern Med* 2018; **283**: 604-606 [PMID: 29095540 DOI: 10.1111/joim.12709]
 - 29 **Pilo-de-la-Fuente B**, Jimenez-Escrig A, Lorenzo JR, Pardo J, Arias M, Ares-Luque A, Duarte J, Muñoz-Pérez S, Sobrido MJ. Cerebrotendinous xanthomatosis in Spain: clinical, prognostic, and genetic survey. *Eur J Neurol* 2011; **18**: 1203-1211 [PMID: 21645175 DOI: 10.1111/j.1468-1331.2011.03439.x]
 - 30 **Chen C**, Zhang Y, Wu H, Sun YM, Cai YH, Wu JJ, Wang J, Gong LY, Ding ZT. Clinical and molecular

- genetic features of cerebrotendinous xanthomatosis patients in Chinese families. *Metab Brain Dis* 2017; **32**: 1609-1618 [PMID: [28623566](#) DOI: [10.1007/s11011-017-0047-8](#)]
- 31 **Tao QQ**, Zhang Y, Lin HX, Dong HL, Ni W, Wu ZY. Clinical and genetic characteristics of Chinese patients with cerebrotendinous xanthomatosis. *Orphanet J Rare Dis* 2019; **14**: 282 [PMID: [31796091](#) DOI: [10.1186/s13023-019-1252-9](#)]
 - 32 **Inanloorahatloo K**, Zand Parsa AF, Huse K, Rasooli P, Davaran S, Platzer M, Fan JB, Amini S, Steemers F, Elahi E. Mutation in CYP27A1 identified in family with coronary artery disease. *Eur J Med Genet* 2013; **56**: 655-660 [PMID: [24080357](#) DOI: [10.1016/j.ejmg.2013.09.008](#)]
 - 33 **de Sain-van der Velden MG**, Verrips A, Prinsen BH, de Barse M, Berger R, Visser G. Elevated cholesterol precursors other than cholestanol can also be a hallmark for CTX. *J Inherit Metab Dis* 2008; **31** Suppl 2: S387-S393 [PMID: [18949577](#) DOI: [10.1007/s10545-008-0963-1](#)]
 - 34 **Wallon D**, Guyant-Maréchal L, Laquerrière A, Wevers RA, Martinaud O, Kluijtmans LA, Yntema HG, Saugier-Verber P, Hannequin D. Clinical imaging and neuropathological correlations in an unusual case of cerebrotendinous xanthomatosis. *Clin Neuropathol* 2010; **29**: 361-364 [PMID: [21073839](#) DOI: [10.5414/npp29361](#)]
 - 35 **Pierre G**, Setchell K, Blyth J, Preece MA, Chakrapani A, McKiernan P. Prospective treatment of cerebrotendinous xanthomatosis with cholic acid therapy. *J Inherit Metab Dis* 2008; **31** Suppl 2: S241-S245 [PMID: [19125350](#) DOI: [10.1007/s10545-008-0815-z](#)]
 - 36 **Claesen JLA**, Koomen E, Schene IF, Jans JJM, Mast N, Pikuleva IA, van der Ham M, de Sain-van der Velden MGM, Fuchs SA. Misdiagnosis of CTX due to propofol: The interference of total intravenous propofol anaesthesia with bile acid profiling. *J Inherit Metab Dis* 2020; **43**: 843-851 [PMID: [31990370](#) DOI: [10.1002/jimd.12219](#)]
 - 37 **Lütjohann D**, Stellaard F, Björkhem I. Levels of 7 α -hydroxycholesterol and/or 7 α -hydroxy-4-cholest-3-one are the optimal biochemical markers for the evaluation of treatment of cerebrotendinous xanthomatosis. *J Neurol* 2020; **267**: 572-573 [PMID: [31781930](#) DOI: [10.1007/s00415-019-09650-0](#)]
 - 38 **Mignarri A**, Dotti MT, Federico A, De Stefano N, Battaglini M, Grazzini I, Galluzzi P, Monti L. The spectrum of magnetic resonance findings in cerebrotendinous xanthomatosis: redefinition and evidence of new markers of disease progression. *J Neurol* 2017; **264**: 862-874 [PMID: [28324197](#) DOI: [10.1007/s00415-017-8440-0](#)]
 - 39 **Barkhof F**, Verrips A, Wesseling P, van Der Knaap MS, van Engelen BG, Gabreëls FJ, Keyser A, Wevers RA, Valk J. Cerebrotendinous xanthomatosis: the spectrum of imaging findings and the correlation with neuropathologic findings. *Radiology* 2000; **217**: 869-876 [PMID: [11110956](#) DOI: [10.1148/radiology.217.3.r00dc03869](#)]
 - 40 **De Stefano N**, Dotti MT, Mortilla M, Federico A. Magnetic resonance imaging and spectroscopic changes in brains of patients with cerebrotendinous xanthomatosis. *Brain* 2001; **124**: 121-131 [PMID: [11133792](#) DOI: [10.1093/brain/124.1.121](#)]
 - 41 **Rosini F**, Pretegeani E, Mignarri A, Optican LM, Serchi V, De Stefano N, Battaglini M, Monti L, Dotti MT, Federico A, Rufa A. The role of dentate nuclei in human oculomotor control: insights from cerebrotendinous xanthomatosis. *J Physiol* 2017; **595**: 3607-3620 [PMID: [28168705](#) DOI: [10.1113/JP273670](#)]
 - 42 **Mignarri A**, Dotti MT, Del Puppo M, Gallus GN, Giorgio A, Cerase A, Monti L. Cerebrotendinous xanthomatosis with progressive cerebellar vacuolation : six-year MRI follow-up. *Neuroradiology* 2012; **54**: 649-651 [PMID: [22415344](#) DOI: [10.1007/s00234-012-1026-8](#)]
 - 43 **Inoue K**, Kubota S, Seyama Y. Cholestanol induces apoptosis of cerebellar neuronal cells. *Biochem Biophys Res Commun* 1999; **256**: 198-203 [PMID: [10066446](#) DOI: [10.1006/bbrc.1998.9497](#)]
 - 44 **Androdias G**, Vukusic S, Gignoux L, Boespflug-Tanguy O, Acquaviva C, Zabot MT, Couvert P, Carrie A, Confavreux C, Labauge P. Leukodystrophy with a cerebellar cystic aspect and intracranial atherosclerosis: an atypical presentation of cerebrotendinous xanthomatosis. *J Neurol* 2012; **259**: 364-366 [PMID: [21769531](#) DOI: [10.1007/s00415-011-6167-x](#)]
 - 45 **Brienza M**, Fiermonte G, Cambieri C, Mignarri A, Dotti MT, Fiorelli M. Enlarging brain xanthomas in a patient with cerebrotendinous xanthomatosis. *J Inherit Metab Dis* 2015; **38**: 981-982 [PMID: [25567502](#) DOI: [10.1007/s10545-014-9805-5](#)]
 - 46 **Smithard A**, Lamyman MJ, McCarthy CL, Gibbons CL, Cooke PJ, Athanasou N. Cerebrotendinous xanthomatosis presenting with bilateral Achilles tendon xanthomata. *Skeletal Radiol* 2007; **36**: 171-175 [PMID: [16715243](#) DOI: [10.1007/s00256-006-0139-8](#)]
 - 47 **Pudhiavan A**, Agrawal A, Chaudhari S, Shukla A. Cerebrotendinous xanthomatosis--the spectrum of imaging findings. *J Radiol Case Rep* 2013; **7**: 1-9 [PMID: [23705046](#) DOI: [10.3941/jrcr.v7i4.1338](#)]
 - 48 **Abate M**, Schiavone C, Salini V, Andia I. Occurrence of tendon pathologies in metabolic disorders. *Rheumatology (Oxford)* 2013; **52**: 599-608 [PMID: [23315787](#) DOI: [10.1093/rheumatology/kes395](#)]
 - 49 **Griffith JF**, Hu M, Yeung DKW, Guo P, Lam SL, Xiao F, Wang D, Tomlinson B. Achilles Tendon Xanthomas: Fat-Water Separation at Baseline and after Treatment. *Radiology* 2017; **285**: 876-884 [PMID: [28825891](#) DOI: [10.1148/radiol.2017161435](#)]
 - 50 **Otake S**, Imagumbai N, Tajima A, Ohba S. Unusual high signal intensity on MR images in a patient with multiple tendinous xanthomas. *Eur Radiol* 1997; **7**: 1025-1027 [PMID: [9265667](#) DOI: [10.1007/s003300050245](#)]
 - 51 **Liem MS**, Leuven JA, Bloem JL, Schipper J. Magnetic resonance imaging of Achilles tendon xanthomas in familial hypercholesterolemia. *Skeletal Radiol* 1992; **21**: 453-457 [PMID: [1439898](#) DOI: [10.1007/BF00190990](#)]
 - 52 **Bude RO**, Adler RS, Bassett DR. Diagnosis of Achilles tendon xanthoma in patients with heterozygous familial hypercholesterolemia: MR vs sonography. *AJR Am J Roentgenol* 1994; **162**: 913-917 [PMID: [8141017](#) DOI: [10.2214/ajr.162.4.8141017](#)]



Published by **Baishideng Publishing Group Inc**
7041 Koll Center Parkway, Suite 160, Pleasanton, CA 94566, USA

Telephone: +1-925-3991568

E-mail: bpgoffice@wjgnet.com

Help Desk: <https://www.f6publishing.com/helpdesk>

<https://www.wjgnet.com>

