

World Journal of *Gastroenterology*

World J Gastroenterol 2020 September 21; 26(35): 5223-5386



REVIEW

- 5223 Stress granules in colorectal cancer: Current knowledge and potential therapeutic applications
Legrand N, Dixon DA, Sobolewski C

MINIREVIEWS

- 5248 Is artificial intelligence the final answer to missed polyps in colonoscopy?
Lui TKL, Leung WK
- 5256 Artificial intelligence-assisted esophageal cancer management: Now and future
Zhang YH, Guo LJ, Yuan XL, Hu B

ORIGINAL ARTICLE

Basic Study

- 5272 New approach of medicinal herbs and sulfasalazine mixture on ulcerative colitis induced by dextran sodium sulfate
Shin MR, Park HJ, Seo BI, Roh SS
- 5287 Immune infiltration-associated serum amyloid A1 predicts favorable prognosis for hepatocellular carcinoma
Zhang W, Kong HF, Gao XD, Dong Z, Lu Y, Huang JG, Li H, Yang YP

Retrospective Cohort Study

- 5302 Epidemiology of perforating peptic ulcer: A population-based retrospective study over 40 years
Dadfar A, Edna TH

Retrospective Study

- 5314 Investigation of immune escape-associated mutations of hepatitis B virus in patients harboring hepatitis B virus drug-resistance mutations
Huang BX, Liu Y, Fan ZP, Si LL, Chen RJ, Wang J, Luo D, Wang FS, Xu DP, Liu XG
- 5328 RBBP4 promotes colon cancer malignant progression *via* regulating Wnt/ β -catenin pathway
Li YD, Lv Z, Zhu WF

Observational Study

- 5343 Updated bone mineral density status in Saudi patients with inflammatory bowel disease
Ewid M, Al Mutiri N, Al Omar K, Shamsan AN, Rathore AA, Saquib N, Salaas A, Al Sarraj O, Nasri Y, Attal A, Tawfiq A, Sherif H
- 5354 Clinical features of cardiac nodularity-like appearance induced by *Helicobacter pylori* infection
Nishizawa T, Sakitani K, Suzuki H, Yoshida S, Kataoka Y, Nakai Y, Ebinuma H, Kanai T, Toyoshima O, Koike K

SYSTEMATIC REVIEWS

- 5362** Systematic review of the prevalence and development of osteoporosis or low bone mineral density and its risk factors in patients with inflammatory bowel disease

Kärnsund S, Lo B, Bendtsen F, Holm J, Burisch J

CASE REPORT

- 5375** Gastrointestinal tract injuries after thermal ablative therapies for hepatocellular carcinoma: A case report and review of the literature

Rogger TM, Michielan A, Sferrazza S, Pravadelli C, Moser L, Agugiaro F, Vettori G, Seligmann S, Merola E, Maida M, Ciarleglio FA, Brolese A, de Pretis G

ABOUT COVER

Editorial board of *World Journal of Gastroenterology*, Dr. Somashekar Krishna is an Associate Professor of Medicine in the Gastroenterology Division of the Ohio State University Wexner Medical Center in Columbus, OH, United States. He trained in advanced endoscopy at the University of Texas MD Anderson Cancer Center (Houston). Dr. Krishna has served on the American Society of Gastrointestinal Endoscopy Research Committee and the *Gastrointestinal Endoscopy* journal editorial board. He is a fellow of the ACG, AGA, and ASGE. Throughout his career, Dr. Krishna has published more than 125 peer-reviewed publications on his research, which encompass studies of advances in early and accurate detection of precancerous pancreatic lesions using novel endoscopic technologies, innovation in endoscopic ultrasound and novel imaging, endoscopy-guided ablation of pancreatic lesions, and large-database analyses and clinical outcomes with focus on acute pancreatitis. (L-Editor: Filipodia)

AIMS AND SCOPE

The primary aim of *World Journal of Gastroenterology* (WJG, *World J Gastroenterol*) is to provide scholars and readers from various fields of gastroenterology and hepatology with a platform to publish high-quality basic and clinical research articles and communicate their research findings online. WJG mainly publishes articles reporting research results and findings obtained in the field of gastroenterology and hepatology and covering a wide range of topics including gastroenterology, hepatology, gastrointestinal endoscopy, gastrointestinal surgery, gastrointestinal oncology, and pediatric gastroenterology.

INDEXING/ABSTRACTING

The WJG is now indexed in Current Contents®/Clinical Medicine, Science Citation Index Expanded (also known as SciSearch®), Journal Citation Reports®, Index Medicus, MEDLINE, PubMed, PubMed Central, and Scopus. The 2020 edition of Journal Citation Report® cites the 2019 impact factor (IF) for WJG as 3.665; IF without journal self cites: 3.534; 5-year IF: 4.048; Ranking: 35 among 88 journals in gastroenterology and hepatology; and Quartile category: Q2.

RESPONSIBLE EDITORS FOR THIS ISSUE

Production Editor: Yu-Jie Ma; Production Department Director: Xiang Li; Editorial Office Director: Ze-Mao Gong.

NAME OF JOURNAL

World Journal of Gastroenterology

ISSN

ISSN 1007-9327 (print) ISSN 2219-2840 (online)

LAUNCH DATE

October 1, 1995

FREQUENCY

Weekly

EDITORS-IN-CHIEF

Andrzej S Tarnawski, Subrata Ghosh

EDITORIAL BOARD MEMBERS

<http://www.wjgnet.com/1007-9327/editorialboard.htm>

PUBLICATION DATE

September 21, 2020

COPYRIGHT

© 2020 Baishideng Publishing Group Inc

INSTRUCTIONS TO AUTHORS

<https://www.wjgnet.com/bpg/gerinfo/204>

GUIDELINES FOR ETHICS DOCUMENTS

<https://www.wjgnet.com/bpg/GerInfo/287>

GUIDELINES FOR NON-NATIVE SPEAKERS OF ENGLISH

<https://www.wjgnet.com/bpg/gerinfo/240>

PUBLICATION ETHICS

<https://www.wjgnet.com/bpg/GerInfo/288>

PUBLICATION MISCONDUCT

<https://www.wjgnet.com/bpg/gerinfo/208>

ARTICLE PROCESSING CHARGE

<https://www.wjgnet.com/bpg/gerinfo/242>

STEPS FOR SUBMITTING MANUSCRIPTS

<https://www.wjgnet.com/bpg/GerInfo/239>

ONLINE SUBMISSION

<https://www.f6publishing.com>

Gastrointestinal tract injuries after thermal ablative therapies for hepatocellular carcinoma: A case report and review of the literature

Teresa Marzia Rogger, Andrea Michielan, Sandro Sferrazza, Cecilia Pravadelli, Luisa Moser, Flora Agugiaro, Giovanni Vettori, Sonia Seligmann, Elettra Merola, Marcello Maida, Francesco Antonio Ciarleglio, Alberto Brolese, Giovanni de Pretis

ORCID number: Teresa Marzia Rogger 0000-0002-0395-4219; Andrea Michielan 0000-0003-1353-0935; Sandro Sferrazza 0000-0002-7595-0129; Cecilia Pravadelli 0000-0003-1392-466X; Luisa Moser 0000-0003-4929-4030; Flora Agugiaro 0000-0003-4119-6014; Giovanni Vettori 0000-0002-6507-9317; Sonia Seligmann 0000-0002-5045-0013; Elettra Merola 0000-0001-9553-7684; Marcello Maida 0000-0002-4992-9289; Francesco Antonio Ciarleglio 0000-0001-9505-8181; Alberto Brolese 0000-0002-6362-9055; Giovanni de Pretis 0000-0001-7636-0422.

Author contributions: Pravadelli C, Michielan A and Sferrazza S contributed to study concept and design; Rogger TM, Michielan A, Sferrazza S, Pravadelli C, Maida M and Ciarleglio FA contributed to drafting of the manuscript; Moser L, Seligmann S, Vettori G, Agugiaro F and Merola E contributed to critical revision of the manuscript for important intellectual content; Brolese A and de Pretis G contributed to study supervision and final approval.

Informed consent statement: Informed consent was obtained from the patient for publication of this report and any accompanying images.

Teresa Marzia Rogger, Andrea Michielan, Sandro Sferrazza, Cecilia Pravadelli, Luisa Moser, Flora Agugiaro, Giovanni Vettori, Sonia Seligmann, Elettra Merola, Giovanni de Pretis, Department of Surgery, Gastroenterology and Digestive Endoscopy Unit, Santa Chiara Hospital, Trento 38122, Italy

Marcello Maida, Gastroenterology and Endoscopy Unit, S.Elia-Raimondi Hospital, Caltanissetta, Caltanissetta 93100, Italy

Francesco Antonio Ciarleglio, Alberto Brolese, Department of Surgery, Hepato-biliary Surgery Unit, Santa Chiara Hospital, Trento 38122, Italy

Corresponding author: Andrea Michielan, MD, Doctor, Department of Surgery, Gastroenterology and Digestive Endoscopy Unit, Santa Chiara Hospital, Largo Medaglie D'Oro 9, Trento 38122, Italy. andrea.michielan@apss.tn.it

Abstract

BACKGROUND

Radiofrequency ablation (RFA) and microwave ablation (MWA) represent the standard of care for patients with early hepatocellular carcinoma (HCC) who are unfit for surgery. The incidence of reported adverse events is low, ranging from 2.4% to 13.1% for RFA and from 2.6% to 7.5% for MWA. Gastrointestinal tract (GIT) injury is even more infrequent (0.11%), but usually requires surgery with an unfavourable prognosis. Due to its low incidence and the retrospective nature of the studies, the literature reporting this feared complication is heterogeneous and in many cases lacks information on tumour characteristics, comorbidities and treatment approaches.

CASE SUMMARY

A 77-year-old man who had undergone extended right hepatectomy for HCC was diagnosed with early disease recurrence with a small nodule compatible with HCC in the Sg4b segment of the liver with a subcapsular location. He was treated with percutaneous RFA and a few week later he was urgently admitted to the Surgery ward for abdominal pain and fever. A subcutaneous abscess was diagnosed and treated by percutaneous drainage. A fistulous tract was then documented by the passage of contrast material from the gastric antrum to the abdominal wall. The oesophagogastroduodenoscopy confirmed a circular wall

Conflict-of-interest statement: All authors declare no conflict of interest related to this publication.

CARE Checklist (2016) statement: The authors have read the CARE Checklist (2016), and the manuscript was prepared and revised according to the CARE Checklist (2016).

Open-Access: This article is an open-access article that was selected by an in-house editor and fully peer-reviewed by external reviewers. It is distributed in accordance with the Creative Commons Attribution NonCommercial (CC BY-NC 4.0) license, which permits others to distribute, remix, adapt, build upon this work non-commercially, and license their derivative works on different terms, provided the original work is properly cited and the use is non-commercial. See: <http://creativecommons.org/licenses/by-nc/4.0/>

Manuscript source: Invited manuscript

Received: June 28, 2020

Peer-review started: June 28, 2020

First decision: July 28, 2020

Revised: August 11, 2020

Accepted: September 1, 2020

Article in press: September 1, 2020

Published online: September 21, 2020

P-Reviewer: Sun JH, Tolga E

S-Editor: Yan JP

L-Editor: A

P-Editor: Ma YJ



defect at the lesser curvature of gastric antrum, leading directly to the purulent abdominal collection. An over-the-scope clip (OTSC) was used to successfully close the defect

CONCLUSION

This is the first reported case of RFA-related GIT injury to have been successfully treated with an OTSC, which highlights the role of this endoscopic treatment for the management of this complication.

Key Words: Gastrointestinal tract; Radiofrequency ablation; Hepatocellular carcinoma; Complications; Endoscopy; Over-the-scope clip; Case report

©The Author(s) 2020. Published by Baishideng Publishing Group Inc. All rights reserved.

Core Tip: Thermal ablative therapies have a key role in the treatment algorithm for hepatocellular carcinoma, and besides their efficacy and tolerability, several studies have proven their overall safety. Nevertheless, albeit rarely, a number of complications have been reported and awareness is crucial to proposing the best treatment for each patient. We report the unusual case of a gastric perforation that was treated in our division and how it was managed with an endoscopic over-the-scope clip for the first time. The literature review aims to discuss the most relevant published data on gastrointestinal tract injuries after thermal ablation therapies.

Citation: Rogger TM, Michielan A, Sferrazza S, Pravadelli C, Moser L, Agugiaro F, Vettori G, Seligmann S, Merola E, Maida M, Ciarleglio FA, Brolese A, de Pretis G. Gastrointestinal tract injuries after thermal ablative therapies for hepatocellular carcinoma: A case report and review of the literature. *World J Gastroenterol* 2020; 26(35): 5375-5386

URL: <https://www.wjnet.com/1007-9327/full/v26/i35/5375.htm>

DOI: <https://dx.doi.org/10.3748/wjg.v26.i35.5375>

INTRODUCTION

Hepatocellular carcinoma (HCC) represents about 90% of primary liver cancers and, with an ever-greater incidence, is the seventh most common malignant tumour and the fourth major cause of cancer death worldwide^[1]. Approximately 70%-90% of HCC cases occur in cirrhotic liver and the choice of the most appropriate treatment must take into account not only cancer staging, but also liver function assessment, evaluation of extrahepatic disease, patient comorbidities and performance status^[2-4]. All the available therapeutic options have drawbacks that can affect both safety and health-related quality of life. Clinicians have to choose those interventional procedures whose benefits outweigh the risks for each individual patient^[5,6].

Although liver transplantation and surgical resection remain the gold standard for HCC, only a small proportion of patients are eligible, making locoregional therapies valuable options with a good survival benefit and safety profile^[7,8]. Of these, according to the most widely accepted staging and treatment algorithm for HCC, the Barcelona Clinic Liver Cancer algorithm^[9,10], ablative modalities have earned a pivotal role, representing the first-line option with curative intent for unresectable Stage 0 (very early) or Stage A (early) HCC. In addition, they can represent an alternative to resection in single tumours with favourable locations or for those tumours < 3 cm in size^[11]. They can also be included in a multimodal approach for intermediate and advanced cases, or play a role as a bridging therapy prior to transplantation^[12,13]. Radiofrequency ablation (RFA) and microwave ablation (MWA) are the most extensively clinically-validated thermal ablative therapies^[14,15]. Using one or more electrodes that generate electrical current and electromagnetic energy respectively, they induce heat in the tumour tissue above a lethal threshold, leading to coagulative necrosis^[15,16]. Although they are less invasive than surgical resection, the complication rate ranges from 2.4% to 13.1% for RFA and from 2.6% to 7.5% for MWA^[8], with no significant difference between the two techniques^[14]. Direct mechanical injury caused by the passage of the electrode through the vessels or biliary tree may lead to bleeding or bile leakage^[17,18]. Heat damage represents the other mechanism that can complicate

these procedures causing gastrointestinal tract (GIT), diaphragm or gallbladder injury, pleural effusion, bile duct strictures, biloma, vascular injury with consequent liver infarction and grounding pad burns. Other possible adverse events include tumour seeding along the tract, septic complications with hepatic abscess or cholangitis, and vasovagal reflex^[12,19,20]. GIT haemorrhagic complications after thermal ablative therapies have also been reported and appear to be mostly associated with a worsening of pre-existing portal hypertension or portal vein thrombosis^[19,21,22].

Thermal damage with GIT injury is an uncommon yet severe complication. At the current time, there are a few reviews analysing the complications of thermal ablation treatments, none specifically investigating GIT injuries^[23-25].

We report the case of an RFA-related gastric perforation that was successfully managed using an over-the-scope clip (OTSC). To the best of our knowledge, this is the first reported endoscopic treatment for an RFA-related GIT complication. We also briefly review and discuss the most relevant published data on GIT injuries after thermal ablation therapies, with regard to their prevalence, risk factors and proposed treatment.

CASE PRESENTATION

Chief complaints

In March 2020, a 77-year-old man was urgently admitted to the Surgery ward for abdominal pain and fever.

History of present illness

In June 2019, he was diagnosed with a bulky hepatic mass with a maximum diameter of 28 cm involving the whole right lobe, with no evidence of pre-existing liver disease. The condition was diagnosed at another hospital and the patient was subsequently treated with combined extended right hepatectomy, hepatic pedicle lymphadenectomy and cholecystectomy. The histopathological study showed a moderately differentiated hepatocellular carcinoma and confirmed a healthy liver parenchyma. No lymph nodes were involved and the tumour resection margins were clear (staging pT3N0G2 – R0). The 6-mo follow-up total-body computed tomography scan showed early disease recurrence and progression with a small 27 mm nodule compatible with HCC in the Sg4b segment of the liver with a subcapsular location, on the edge of the previous partial resection site, and a 5 cm adrenal metastasis. A subsequent contrast-enhanced ultrasound (US) scan of the liver confirmed the diagnosis (Figure 1). In January 2020, the patient had a multidisciplinary consultation at our hospital and was deemed fit for locoregional treatments. In February 2020, he was admitted in our Surgery ward and, once written informed consent had been obtained, he was treated with chemoembolisation of the adrenal metastasis and percutaneous RFA of the small HCC in Sg4b. The ablation was performed with anaesthesiological support, and under real-time US guidance. The device used to apply the radiofrequency current was a 20 cm long, 17-Gauge electrode with an uninsulated 3 cm tip (RF-AMICA probe, HS Hospital Service, Aprilia, Italy). No immediate complications were reported after the procedure.

History of past illness

The patient's medical history included arterial hypertension, surgical resection of a parathyroid adenoma and radioactive iodine therapy for Plummer's disease.

Physical examination

The clinical abdominal examination revealed epigastric tenderness. The patient's temperature was 38.5 °C, blood pressure was 140/90 mmHg, heart rate was 100 bpm, respiratory rate was 15 breaths per min, and oxygen saturation in room air was 99%.

Laboratory examinations

The patient's biochemistry tests showed no clear evidence of systemic inflammation. White blood cells and serum C-reactive protein were at the upper limit of the normal range. Serum transaminases, liver function tests and routine blood biochemistry were normal.

Imaging examinations

A subcutaneous abscess was diagnosed by abdominal ultrasound and treated with

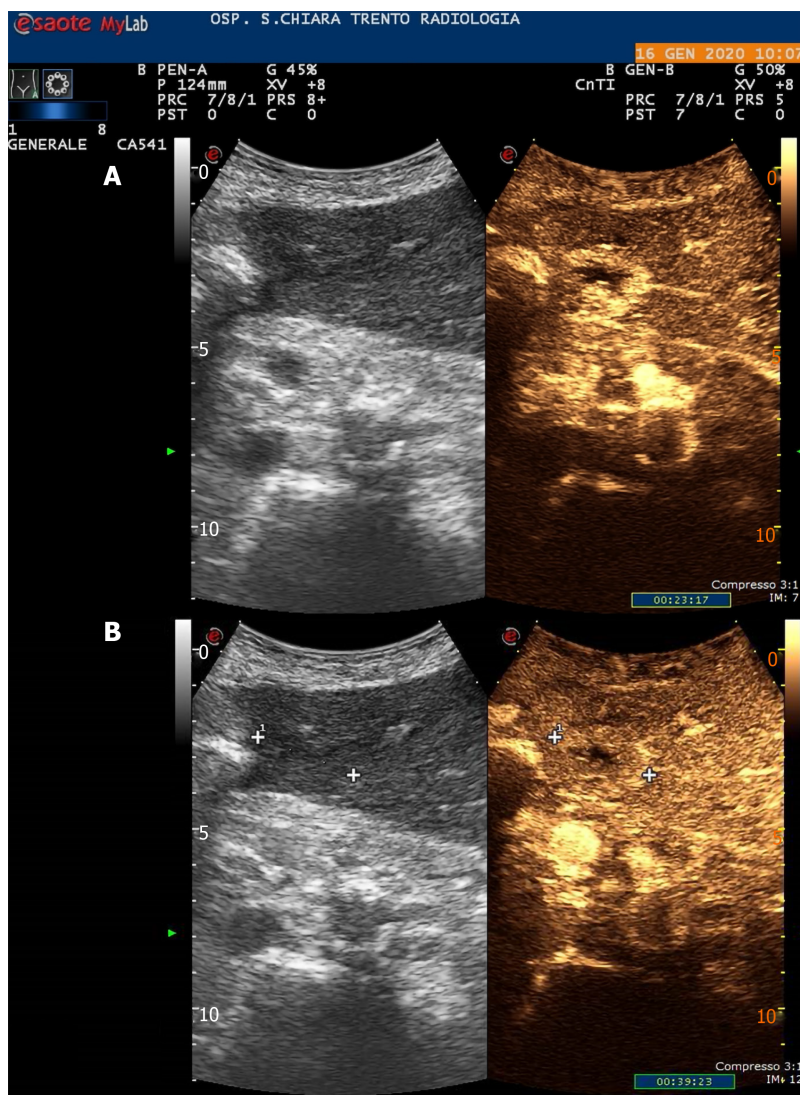


Figure 1 Contrast-enhanced ultrasonography showing the subcapsular 20 mm hepatocellular carcinoma at the 4th liver segment. A: During wash-in phase; B: During wash-out phase.

percutaneous drainage, observing necrotic and purulent secretion, together with air leak. Since no decrease in drain output was observed over the following d, an abdominal film with oral water-soluble contrast agent was performed. A fistulous tract was documented by the passage of contrast material from the gastric antrum to the abdominal wall (Figure 2).

FINAL DIAGNOSIS

The final diagnosis of the presented case was RFA-related gastric perforation.

TREATMENT

The patient was treated conservatively with fasting and broad-spectrum antibiotics; a prompt endoscopic assessment was planned. The oesophagogastroduodenoscopy confirmed a circular wall defect, approximately 15 mm in size, at the lesser curvature of gastric antrum, leading directly to the purulent abdominal collection (Figure 3). An OTSC was used to successfully close the defect (Figure 4) and there were no immediate complications. Technical success was confirmed after one week by an abdominal film with oral water-soluble contrast agent (Figure 5). The patient gradually resumed oral feeding and was finally discharged in good conditions.

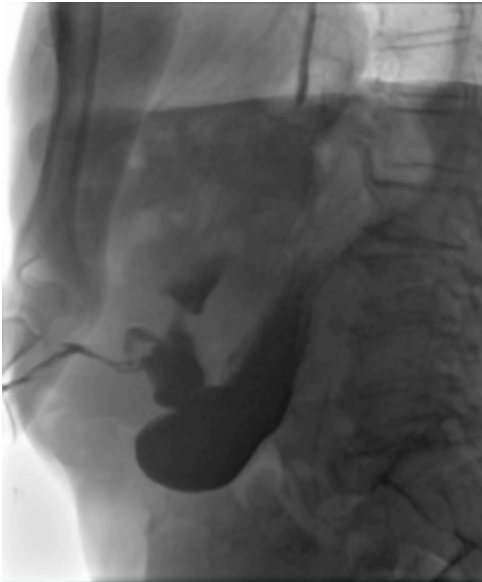

Figure 2 Abdominal film with oral water-soluble contrast agent showing a gastric perforation with a gastro-cutaneous fistulous tract (surgical drain in place).

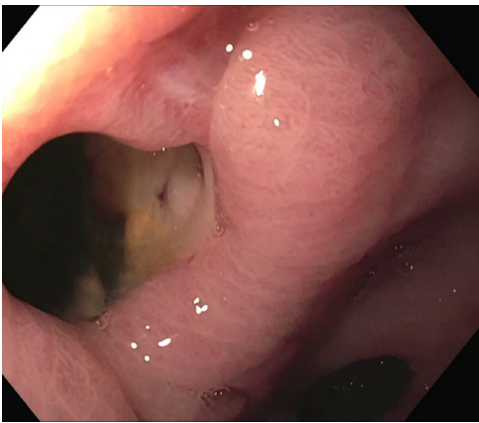


Figure 3 Endoscopic finding of the gastric perforation in communication with a purulent collection. Pylorus can be seen in the lower part of the picture.

OUTCOME AND FOLLOW-UP

A short time after the complete closure of the external fistula, recurrence of a mild cutaneous leakage (less than 40 mL/d) was observed for 40 d, followed by spontaneous closure. In June 2020, no signs of perforation recurrence were detected and the HCC was in remission in the remaining liver, according to mRECIST criteria^[26]. The case report timeline is showed in Supplementary Figure 1.

DISCUSSION

We performed a review of the literature reporting the largest series of GIT complications published to date, highlighting the features that may help clinicians in the detection and management of these feared events (Table 1). Published studies are mainly retrospective and extremely heterogeneous as regards information on tumour size and location, comorbidities and treatment approach, which are often missing, or otherwise include lesions other than HCC.

Epidemiology and outcome

The reported prevalence of GIT injuries ranges from 0.04% to 2.5%, particularly when

Table 1 Studies reporting gastrointestinal tract injuries after thermal ablation therapies for hepatocellular carcinoma

Ref.	Study design	Number of patients	Overall complication rate(%)	GIT injury rate (%)	Type of GIT injury	Thermoablative treatment	Timing of GIT injury	Management of GIT injury	Outcome	Associated conditions
Livraghi <i>et al</i> ^[29] , 2003	Multicentre, retrospective, questionnaire-based ¹	2320	7.1 (2.4 ²)	0.7 ²	5 colonic perforations; 1 jejunal perforation; 1 gastric perforation	Percutaneous RFA	2 d-4 d	Surgery (7/7)	2 deaths after colonic perforation	Gut wall distance < 1 cm (7/7); adherence due to previous abdominal surgery or inflammatory chronic cholecystitis (6/7); large superficial HCC in left lobe + aggressive treatment (1/7)
De Baere <i>et al</i> ^[31] , 2003	Multicentre, prospective ¹	312	12 (5.7 ²)	0.3 ²	1 colonic perforation	RFA ³	4 d	Surgery	Death	NA
Curley <i>et al</i> ^[57] , 2004	Multicentre, prospective ¹	608	9.5	0.16 ²	1 stomach wall necrosis	Open RFA	Immediate	Surgery	Recovery	Left lobe
Jansen <i>et al</i> ^[58] , 2005	Multicentre, prospective ¹	122	9.8 (6.3 ²)	2.5 (0 ²)	2 transient paralytic ileus	RFA ³	NA	Spontaneous resolution (2/2)	Recovery	NA
Casaril <i>et al</i> ^[32] , 2007	Single-centre, retrospective ¹	83	25 (7.2 ²)	0.7 ²	1 colonic perforation	Percutaneous RFA	36 d	NA	Death	Superficial HCC in Sg4; Child-Pugh B
Kasugai <i>et al</i> ^[22] , 2007	Multicentre, retrospective, questionnaire-based	2614	7.9 ²	0.2 ²	1 duodenum injury; 1 stomach injury; 1 colonic perforation	RFA ³	NA	External drainage (1/3)	Recovery	NA
Chen <i>et al</i> ^[34] , 2008	Single-centre, retrospective ¹	104	5.2 ²	0.6 ²	1 colonic perforation with fistula and abscess	Percutaneous RFA	3 wk	External drainage	Recovery	Superficial HCC in Sg4; previous surgery for Denver shunt
Liang <i>et al</i> ^[30] , 2009	Single-centre, retrospective ¹	1136	2.6 ²	0.2 ²	2 colonic perforations	Percutaneous MWA	3 d-5 d	Surgery (2/2)	Recovery	HCC located < 1 cm from colonic wall + prior right partial hepatectomy (2/2)
Livraghi <i>et al</i> ^[33] , 2012	Multicentre, retrospective, questionnaire-based ¹	736	10.2 (2.9 ²)	0.2 ²	1 ileal perforation; 1 colonic perforation	Percutaneous MWA	NA	Surgery (2/2)	Recovery	Superficial HCC in Sg4 + abdominal adhesions (2/2)
Koda <i>et al</i> ^[53] , 2012	Multicentre, retrospective, questionnaire-based	13283	3.5 ²	0.05 (0.04 ²)	1 colonic perforation; 3 stomach injuries; 2 duodenum injuries	RFA ³	NA	Surgery (3/6)	1 Death after colonic perforation	NA
Ding <i>et al</i> ^[19] , 2013	Single-centre, retrospective ¹	879	8.8-9.4 (3.1-3.5 ²)	0.3 ²	1 bowel perforation	Percutaneous RFA	Immediate	External drainage	Recovery	Previous Whipple procedure

Park <i>et al</i> ^[54] , 2017	Single-centre, retrospective	1211	6.8 (2 ²)	0.2 ²	1 colonic perforation	Percutaneous RFA	NA	NA	Recovery	NA
Jeong <i>et al</i> ^[28] , 2017	Single-centre, retrospective ¹	3933	NA	1.32 (0.05 ²)	28 stomach injuries; 16 colonic injuries; 6 small bowel injuries; 1 small bowel perforation; 1 colonic perforation	Percutaneous RFA	2 d-13 d (perforations)	Surgery (2/2 perforations)	Recovery	Subcapsular HCC (47/52); previous percutaneous treatments (7/52) or abdominal surgery (19/52)
Maeda <i>et al</i> ^[59] , 2020	Multicentre, retrospective, questionnaire based	9411	3.5 ²	0.04 ²	2 colonic perforations	NA	NA	NA	1 Death	NA

¹HCC and other liver tumors included;

²Major complications;

³Route approach not specified. GIT: Gastrointestinal tract; HCC: Hepatocellular carcinoma; RFA: Radiofrequency ablation; MWA: Microwave ablation; NA: Not available.

thermal ablative therapies were administered percutaneously.

The great variability in the GIT injury rate depends on whether minor injuries were included in the studies. Most literature concerns only major complications, strictly defined as those that increase the level of care, leading to significant morbidity and disability^[27]. This probably plays down the effect that thermal ablation may have on GIT. Two previous reviews on the complications of thermoablative treatments found an extremely low prevalence of GIT injuries (0.11%-0.5%)^[23,24]. However, a subsequent study on radiological predictors of major GIT injury reported a rate of 1.32%^[28] and in a review that included also minor injuries, this rate rose to 3.2%^[25].

Outcome is often unfavourable, as confirmed by previous studies. After sepsis and liver failure, GIT injuries were more frequently associated with death than other more commonly-observed complications^[24,29,30]. GIT complications accounted for two in six fatal adverse events in one Italian multicentre study^[29], one in five in the series from De Baère *et al*^[31], and the only lethal event observed by Casaril *et al*^[32].

Predisposing conditions

Associated conditions that may represent precipitating factors for GIT injury are HCC nodules or gut wall close to liver capsule (< 1 cm), previous abdominal surgery or percutaneous treatments.

It is well known that structures located within 0.5 cm-1 cm from the tumour margin are at-risk of heat-induced damage, since ablative treatment usually includes an area of healthy peritumoral tissue, in order to eradicate any microscopic satellites and prevent local recurrence^[12]. However, this is not the only factor involved, as stressed by Liang *et al*^[30] in their retrospective analysis, which did not identify any significant difference in tumour location between patients with *vs* without major complications^[30]. The association of an unfavourable location and a predisposing history is clearly shown by the data reported in the literature. In two studies analysing

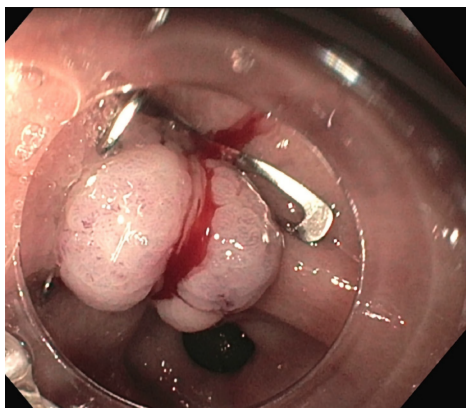


Figure 4 Endoscopic closure of the perforation using an over-the-scope clip.

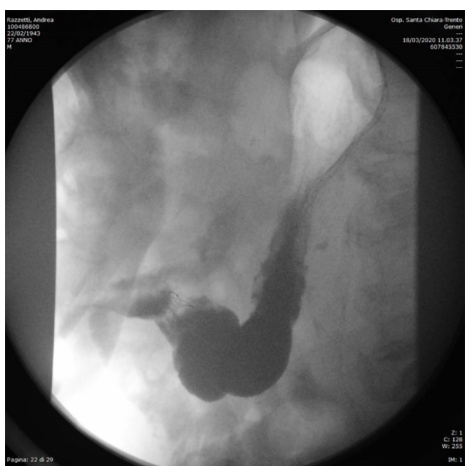


Figure 5 Abdominal film with oral water-soluble contrast agent showing no active leakage from the stomach. The over-the-scope clip can be seen in gastric antrum.

complications after both RFA and MWA, Livraghi *et al*^[29,33] reported nine major GIT complications. All occurred after the treatment of superficial lesions, mostly in patients who had had previous abdominal surgery or had inflammatory abdominal processes (89%, 8/9 patients). Other studies confirmed that GIT injuries exclusively followed the treatment of subcapsular tumours in a specific subset of patients, whose history included Whipple resection, right partial hepatectomy or peritoneovenous shunt^[19,30,34]. In line with these data, a more recent Korean study found that of 52 patients who experienced GIT complications 47 (90.4%) had a tumour located in a subcapsular portion of the liver and in half of these patients previous abdominal surgery or repeated percutaneous treatments were reported^[28].

Clinical presentation

In the majority of the studies examined, the colon appears the most commonly involved organ, with a delay in presentation of several days. Its vulnerability is associated with its thin wall and relatively stable position compared to the stomach's thick wall and to the small intestine's active peristalsis^[20,35]. In case of aggressive treatments with repeated or prolonged sessions, particularly in high-risk settings as previously discussed, caution is warranted as other organs than the colon may be involved^[36-38].

GIT injuries can be difficult to recognise because their clinical presentation is subtler than classic digestive perforation and they may be misdiagnosed as post-ablation syndrome. Unresolved or delayed-onset fever, pain or increase in white blood cell count several days after the procedure, should raise suspicions and careful patient assessment is warranted. The presence of an abscess, although more commonly related with other aetiologies, could be the result of a contaminating digestive tract perforation, and consequently close monitoring of GIT is also recommended in these

cases^[39].

Imaging

Some authors advocate using of imaging techniques soon after RFA. Gastrointestinal wall thickening, fat stranding and free fluid can be found around the injured area as a result of minimal insult^[39,40]. Similarly, the presence of free air does not always indicate a major perforation, as it is found in more than half of all patients with minor complications and usually subsides within one month^[41]. On the other hand, immediate post-treatment computed tomography, may show concentric bowel wall thickening with mucosal disruption, which significantly correlates with the risk of major GIT injury requiring surgery^[28]. However, immediate imaging is not routinely performed in all centres, as it is not always possible to make a distinction between transient hyperaemia and the residual unablated tumour, which hampers the evaluation of treatment efficacy^[41]. Nevertheless, in selected cases, when dealing with tumours with a high-risk location in high-risk patients, close imaging parallel to clinical follow-up could be advised.

Management

Few studies focused on the detailed course of these complications and their management, although the impact on patient morbidity and quality of life is non-negligible. Whenever possible, patients were treated minimally-invasively with fasting and percutaneous drain placement, but most required surgical intervention to repair the injured GIT^[39]. To the best of our knowledge, the case reported here is the first case of gastric perforation after thermal ablation therapies to be managed endoscopically with an OTSC.

OTSCs differ from traditional through-the-scope clips in several characteristics, namely higher compression force, larger diameter and grasping accessories that allow the closure of wall defects of up to 30 mm, including the muscle layer^[42-44]. They have been successfully used and validated in literature in different settings, *i.e.*, haemostasis in acute GI bleeding, closure of GI perforations, leaks and fistulas or as anchor to prevent stent migration^[45]. While clinical success is nearly 100% for haemostasis, it decreases to 40%-75% for GI defect closure, with best outcomes in acute perforations, which have fresh edges with less fibrosis^[44,46,47]. Nevertheless, their use has been increasingly reported in postoperative leakages or fistulas as well, owing to the attractive possibility of avoiding complex surgery^[48-50]. Clinicians must take into account that a multidisciplinary approach should always be taken, since surgical or radiological placement of a drain is often advisable to prevent abscess formation after defect closure.

Preventive measures

An interesting issue is whether preventive measures may reduce the incidence of GIT injuries caused by thermal ablation therapies. These lesions are mainly associated with the percutaneous route and surgical management showed the presence of fibrotic adhesions that affixed the GI wall to the liver. Thus, a laparoscopic or intraoperative thermal ablation approach may allow the mechanical separation of the GIT from the surface of the liver and protect it from subsequent thermal damage^[32,51]. Nevertheless, the rate of other complications of these invasive routes is higher than for the percutaneous route^[21].

One well-established, easy and safe procedure is the use of artificial ascites. This technique allows the displacement of the liver, with its considered high-risk ablation area, from the adjacent organs^[52]. Authors who routinely perform this procedure reported a lower incidence of GIT complications despite dealing with high-risk tumours^[53,54]. Nevertheless, the presence of perihepatic adhesions due to previous abdominal surgery, other locoregional treatments such as transarterial chemoembolization or intra-abdominal inflammation, represent a limit for technical success. Moreover, this technique may be of limited efficacy in tumours located in left liver, since the nearby stomach is not easy to displace^[55]. Two other tips to help minimise adjacent organ injury are the interposition of thermocouples that ensure controlled temperature increase^[30] and the use of straight needle electrodes, which are more appropriate for monitoring the distance from GIT than expandable devices^[56].

CONCLUSION

This is the first reported case of RFA-related GIT injury endoscopically treated with OTSC. OTSCs have become part of the endoscopist's armamentarium and are now widely used to treat GI defects. This application may help reduce the need for complex surgery for this rare yet severe complication.

Our review raises awareness on an overlooked but severe complication of thermal ablative treatments. Nowadays, following the expansion of ablation criteria for HCC, these therapeutic modalities are gaining wider application. Therefore, clinicians must consider possible complications and accurately weigh up the risks and benefits, choosing the best treatment option not only according to fixed algorithms for HCC, but also tailored to the specific patient.

Since GIT injuries are rare but have an unfavourable prognosis and outcome, careful patient evaluation may help detect the tumour-related (location < 1 cm from the GI tract) or patient-related (previous surgery or locoregional treatments) risk factors that may trigger this event. These features do not represent an absolute contraindication to thermal ablation therapies, since these treatments remain safe and have an acceptable complication rate. However, according to local expertise, a non-percutaneous (laparoscopic or intraoperative) route should be chosen or preventive measures such as artificial ascites should be used. Otherwise, other ablative methods for HCC should be preferred.

In the case of GIT injury occurrence, the initial subtle clinical presentation warrants a low threshold for GI imaging. Finally, prompt identification of the injury is mandatory to avoid diagnostic delay and provide timely management.

REFERENCES

- 1 **Bray F**, Ferlay J, Soerjomataram I, Siegel RL, Torre LA, Jemal A. Global cancer statistics 2018: GLOBOCAN estimates of incidence and mortality worldwide for 36 cancers in 185 countries. *CA Cancer J Clin* 2018; **68**: 394-424 [PMID: 30207593 DOI: 10.3322/caac.21492]
- 2 **Forner A**, Llovet JM, Bruix J. Hepatocellular carcinoma. *Lancet* 2012; **379**: 1245-1255 [PMID: 22353262 DOI: 10.1016/S0140-6736(11)61347-0]
- 3 **Gadsden MM**, Kaplan DE. Multidisciplinary Approach to HCC Management: How Can This Be Done? *Dig Dis Sci* 2019; **64**: 968-975 [PMID: 30887152 DOI: 10.1007/s10620-019-05593-8]
- 4 **Couri T**, Pillai A. Goals and targets for personalized therapy for HCC. *Hepatol Int* 2019; **13**: 125-137 [PMID: 30600478 DOI: 10.1007/s12072-018-9919-1]
- 5 **Fan SY**, Eiser C, Ho MC. Health-related quality of life in patients with hepatocellular carcinoma: a systematic review. *Clin Gastroenterol Hepatol* 2010; **8**: 559-64.e1-10 [PMID: 20304101 DOI: 10.1016/j.cgh.2010.03.008]
- 6 **Das A**, Gabr A, O'Brian DP, Riaz A, Desai K, Thornburg B, Kallini JR, Mouli S, Lewandowski RJ, Salem R. Contemporary Systematic Review of Health-Related Quality of Life Outcomes in Locoregional Therapies for Hepatocellular Carcinoma. *J Vasc Interv Radiol* 2019; **30**: 1924-1933.e2 [PMID: 31685362 DOI: 10.1016/j.jvir.2019.07.020]
- 7 **Dimitroulis D**, Damaskos C, Valsami S, Davakis S, Garmis N, Spartalis E, Athanasiou A, Moris D, Sakellariou S, Kykalos S, Tsourouflis G, Garmis A, Delladetsima I, Kontzoglou K, Kouraklis G. From diagnosis to treatment of hepatocellular carcinoma: An epidemic problem for both developed and developing world. *World J Gastroenterol* 2017; **23**: 5282-5294 [PMID: 28839428 DOI: 10.3748/wjg.v23.i29.5282]
- 8 **Habib A**, Desai K, Hickey R, Thornburg B, Lewandowski R, Salem R. Locoregional therapy of hepatocellular carcinoma. *Clin Liver Dis* 2015; **19**: 401-420 [PMID: 25921670 DOI: 10.1016/j.cld.2015.01.008]
- 9 **Maida M**, Orlando E, Cammà C, Cabibbo G. Staging systems of hepatocellular carcinoma: a review of literature. *World J Gastroenterol* 2014; **20**: 4141-4150 [PMID: 24764652 DOI: 10.3748/wjg.v20.i15.4141]
- 10 **Faria SC**, Szklaruk J, Kaseb AO, Hassabo HM, Elsayes KM. TNM/Okuda/Barcelona/UNOS/CLIP International Multidisciplinary Classification of Hepatocellular Carcinoma: concepts, perspectives, and radiologic implications. *Abdom Imaging* 2014; **39**: 1070-1087 [PMID: 24695938 DOI: 10.1007/s00261-014-0130-0]
- 11 **European Association for the Study of the Liver**. EASL Clinical Practice Guidelines: Management of hepatocellular carcinoma. *J Hepatol* 2018; **69**: 182-236 [PMID: 29628281 DOI: 10.1016/j.jhep.2018.03.019]
- 12 **Kim YS**, Lim HK, Rhim H, Lee MW. Ablation of hepatocellular carcinoma. *Best Pract Res Clin Gastroenterol* 2014; **28**: 897-908 [PMID: 25260316 DOI: 10.1016/j.bpg.2014.08.011]
- 13 **Nault JC**, Sutter O, Nahon P, Ganne-Carrié N, Sèror O. Percutaneous treatment of hepatocellular carcinoma: State of the art and innovations. *J Hepatol* 2018; **68**: 783-797 [PMID: 29031662 DOI: 10.1016/j.jhep.2017.10.004]
- 14 **Izzo F**, Granata V, Grassi R, Fusco R, Palaia R, Delrio P, Carrafiello G, Azoulay D, Petrillo A, Curley SA. Radiofrequency Ablation and Microwave Ablation in Liver Tumors: An Update. *Oncologist* 2019; **24**: e990-e1005 [PMID: 31217342 DOI: 10.1634/theoncologist.2018-0337]
- 15 **Facciorusso A**, Serviddio G, Muscatiello N. Local ablative treatments for hepatocellular carcinoma: An updated review. *World J Gastrointest Pharmacol Ther* 2016; **7**: 477-489 [PMID: 27867681 DOI: 10.4292/wjgpt.v7.i4.477]

- 16 **Poulou LS**, Botsa E, Thanou I, Ziakas PD, Thanos L. Percutaneous microwave ablation vs radiofrequency ablation in the treatment of hepatocellular carcinoma. *World J Hepatol* 2015; **7**: 1054-1063 [PMID: 26052394 DOI: 10.4254/wjh.v7.i8.1054]
- 17 **Llovet JM**, Vilana R, Brú C, Bianchi L, Salmeron JM, Boix L, Ganao S, Sala M, Pagès M, Ayuso C, Solé M, Rodés J, Bruix J; Barcelona Clinic Liver Cancer (BCLC) Group. Increased risk of tumor seeding after percutaneous radiofrequency ablation for single hepatocellular carcinoma. *Hepatology* 2001; **33**: 1124-1129 [PMID: 11343240 DOI: 10.1053/jhep.2001.24233]
- 18 **Livraghi T**, Lazzaroni S, Meloni F, Solbiati L. Risk of tumour seeding after percutaneous radiofrequency ablation for hepatocellular carcinoma. *Br J Surg* 2005; **92**: 856-858 [PMID: 15892154 DOI: 10.1002/bjs.4986]
- 19 **Ding J**, Jing X, Liu J, Wang Y, Wang F, Wang Y, Du Z. Complications of thermal ablation of hepatic tumours: comparison of radiofrequency and microwave ablative techniques. *Clin Radiol* 2013; **68**: 608-615 [PMID: 23399463 DOI: 10.1016/j.crad.2012.12.008]
- 20 **Poggi G**, Tosoratti N, Montagna B, Picchi C. Microwave ablation of hepatocellular carcinoma. *World J Hepatol* 2015; **7**: 2578-2589 [PMID: 26557950 DOI: 10.4254/wjh.v7.i25.2578]
- 21 **Kong WT**, Zhang WW, Qiu YD, Zhou T, Qiu JL, Zhang W, Ding YT. Major complications after radiofrequency ablation for liver tumors: analysis of 255 patients. *World J Gastroenterol* 2009; **15**: 2651-2656 [PMID: 19496197 DOI: 10.3748/wjg.15.2651]
- 22 **Kasugai H**, Osaki Y, Oka H, Kudo M, Seki T; Osaka Liver Cancer Study Group. Severe complications of radiofrequency ablation therapy for hepatocellular carcinoma: an analysis of 3,891 ablations in 2,614 patients. *Oncology* 2007; **72** Suppl 1: 72-75 [PMID: 18087185 DOI: 10.1159/000111710]
- 23 **Mulier S**, Mulier P, Ni Y, Miao Y, Dupas B, Marchal G, De Wever I, Michel L. Complications of radiofrequency coagulation of liver tumours. *Br J Surg* 2002; **89**: 1206-1222 [PMID: 12296886 DOI: 10.1046/j.1365-2168.2002.02168.x]
- 24 **Bertot LC**, Sato M, Tateishi R, Yoshida H, Koike K. Mortality and complication rates of percutaneous ablative techniques for the treatment of liver tumors: a systematic review. *Eur Radiol* 2011; **21**: 2584-2596 [PMID: 21858539 DOI: 10.1007/s00330-011-2222-3]
- 25 **Baker EH**, Thompson K, McKillop IH, Cochran A, Kirks R, Vrochides D, Martinie JB, Swan RZ, Iannitti DA. Operative microwave ablation for hepatocellular carcinoma: a single center retrospective review of 219 patients. *J Gastrointest Oncol* 2017; **8**: 337-346 [PMID: 28480072 DOI: 10.21037/jgo.2016.09.06]
- 26 **Maida M**, Cabibbo G, Brancatelli G, Genco C, Alessi N, Genova C, Romano P, Raineri M, Giarratano A, Midiri M, Cammà C. Assessment of treatment response in hepatocellular carcinoma: a review of the literature. *Future Oncol* 2013; **9**: 845-854 [PMID: 23718305 DOI: 10.2217/fon.13.33]
- 27 **Goldberg SN**, Grassi CJ, Cardella JF, Charboneau JW, Dodd GD 3rd, Dupuy DE, Gervais DA, Gillams AR, Kane RA, Lee FT Jr, Livraghi T, McGahan J, Phillips DA, Rhim H, Silverman SG, Solbiati L, Vogl TJ, Wood BJ, Vedantham S, Sacks D; Society of Interventional Radiology Technology Assessment Committee and the International Working Group on Image-guided Tumor Ablation. Image-guided tumor ablation: standardization of terminology and reporting criteria. *J Vasc Interv Radiol* 2009; **20**: S377-S390 [PMID: 19560026 DOI: 10.1016/j.jvir.2009.04.011]
- 28 **Jeong YS**, Kim SH, Lee JM, Lee JY, Kim JH, Lee DH, Kang HJ, Yoon CJ, Han JK. Gastrointestinal tract complications after hepatic radiofrequency ablation: CT prediction for major complications. *Abdom Radiol (NY)* 2018; **43**: 583-592 [PMID: 28676999 DOI: 10.1007/s00261-017-1239-8]
- 29 **Livraghi T**, Solbiati L, Meloni MF, Gazelle GS, Halpern EF, Goldberg SN. Treatment of focal liver tumors with percutaneous radio-frequency ablation: complications encountered in a multicenter study. *Radiology* 2003; **226**: 441-451 [PMID: 12563138 DOI: 10.1148/radiol.2262012198]
- 30 **Liang P**, Wang Y, Yu X, Dong B. Malignant liver tumors: treatment with percutaneous microwave ablation-complications among cohort of 1136 patients. *Radiology* 2009; **251**: 933-940 [PMID: 19304921 DOI: 10.1148/radiol.2513081740]
- 31 **de Baère T**, Risse O, Kuoch V, Dromain C, Sengel C, Smayra T, Gamal El Din M, Letoublon C, Elias D. Adverse events during radiofrequency treatment of 582 hepatic tumors. *AJR Am J Roentgenol* 2003; **181**: 695-700 [PMID: 12933462 DOI: 10.2214/ajr.181.3.1810695]
- 32 **Casari A**, Abu Hilal M, Harb A, Campagnaro T, Mansueto G, Nicoli N. The safety of radiofrequency thermal ablation in the treatment of liver malignancies. *Eur J Surg Oncol* 2008; **34**: 668-672 [PMID: 17681717 DOI: 10.1016/j.ejso.2007.05.003]
- 33 **Livraghi T**, Meloni F, Solbiati L, Zanusi G; Collaborative Italian Group using AMICA system. Complications of microwave ablation for liver tumors: results of a multicenter study. *Cardiovasc Intervent Radiol* 2012; **35**: 868-874 [PMID: 21833809 DOI: 10.1007/s00270-011-0241-8]
- 34 **Chen TM**, Huang PT, Lin LF, Tung JN. Major complications of ultrasound-guided percutaneous radiofrequency ablations for liver malignancies: single center experience. *J Gastroenterol Hepatol* 2008; **23**: e445-e450 [PMID: 17683478 DOI: 10.1111/j.1440-1746.2007.05078.x]
- 35 **Meloni MF**, Goldberg SN, Moser V, Piazza G, Livraghi T. Colonic perforation and abscess following radiofrequency ablation treatment of hepatoma. *Eur J Ultrasound* 2002; **15**: 73-76 [PMID: 12044857 DOI: 10.1016/s0929-8266(01)00171-9]
- 36 **Falco A**, Orlando D, Sciarra R, Sergiacomo L. A case of biliary gastric fistula following percutaneous radiofrequency thermal ablation of hepatocellular carcinoma. *World J Gastroenterol* 2007; **13**: 804-805 [PMID: 17278208 DOI: 10.3748/wjg.v13.i5.804]
- 37 **Frich L**, Edwin B, Brabrand K, Rosseland AR, Mala T, Mathisen O, Gladhaug I. Gastric perforation after percutaneous radiofrequency ablation of a colorectal liver metastasis in a patient with adhesions in the peritoneal cavity. *AJR Am J Roentgenol* 2005; **184**: S120-S122 [PMID: 15728002 DOI: 10.2214/ajr.184.3_supplement.0184s120]
- 38 **Yamane T**, Imai K, Umezaki N, Yamao T, Kaida T, Nakagawa S, Yamashita YI, Chikamoto A, Ishiko T, Baba H. Perforation of the esophagus due to thermal injury after laparoscopic radiofrequency ablation for hepatocellular carcinoma: a case for caution. *Surg Case Rep* 2018; **4**: 127 [PMID: 30315431 DOI: 10.1186/s40792-018-0534-0]
- 39 **Kwon HJ**, Kim PN, Byun JH, Kim KW, Won HJ, Shin YM, Lee MG. Various complications of

- percutaneous radiofrequency ablation for hepatic tumors: radiologic findings and technical tips. *Acta Radiol* 2014; **55**: 1082-1092 [PMID: [24277883](#) DOI: [10.1177/0284185113513893](#)]
- 40 **Akahane M**, Koga H, Kato N, Yamada H, Uozumi K, Tateishi R, Teratani T, Shiina S, Ohtomo K. Complications of percutaneous radiofrequency ablation for hepato-cellular carcinoma: imaging spectrum and management. *Radiographics* 2005; **25** Suppl 1: S57-S68 [PMID: [16227497](#) DOI: [10.1148/rg.25si055505](#)]
- 41 **Kim YS**, Rhim H, Lim HK. Imaging after radiofrequency ablation of hepatic tumors. *Semin Ultrasound CT MR* 2009; **30**: 49-66 [PMID: [19358437](#) DOI: [10.1053/j.sult.2008.12.004](#)]
- 42 **Baron TH**, Song LM, Ross A, Tokar JL, Irani S, Kozarek RA. Use of an over-the-scope clipping device: multicenter retrospective results of the first U.S. experience (with videos). *Gastrointest Endosc* 2012; **76**: 202-208 [PMID: [22726484](#) DOI: [10.1016/j.gie.2012.03.250](#)]
- 43 **Manta R**, Galloro G, Mangiavillano B, Conigliaro R, Pasquale L, Arezzo A, Masci E, Bassotti G, Frazzoni M. Over-the-scope clip (OTSC) represents an effective endoscopic treatment for acute GI bleeding after failure of conventional techniques. *Surg Endosc* 2013; **27**: 3162-3164 [PMID: [23436101](#) DOI: [10.1007/s00464-013-2871-1](#)]
- 44 **Lee HL**, Cho JY, Cho JH, Park JJ, Kim CG, Kim SH, Han JH. Efficacy of the Over-the-Scope Clip System for Treatment of Gastrointestinal Fistulas, Leaks, and Perforations: A Korean Multi-Center Study. *Clin Endosc* 2018; **51**: 61-65 [PMID: [28847073](#) DOI: [10.5946/ce.2017.027](#)]
- 45 **Donatelli G**, Cereatti F, Dhumane P, Vergeau BM, Tuszyński T, Marie C, Dumont JL, Meduri B. Closure of gastrointestinal defects with Ovesco clip: long-term results and clinical implications. *Therap Adv Gastroenterol* 2016; **9**: 713-721 [PMID: [27582884](#) DOI: [10.1177/1756283X16652325](#)]
- 46 **Goenka MK**, Rai VK, Goenka U, Tiwary IK. Endoscopic Management of Gastrointestinal Leaks and Bleeding with the Over-the-Scope Clip: A Prospective Study. *Clin Endosc* 2017; **50**: 58-63 [PMID: [27802375](#) DOI: [10.5946/ce.2016.028](#)]
- 47 **Verlaan T**, Voermans RP, van Berge Henegouwen MI, Bemelman WA, Fockens P. Endoscopic closure of acute perforations of the GI tract: a systematic review of the literature. *Gastrointest Endosc* 2015; **82**: 618-28.e5 [PMID: [26005015](#) DOI: [10.1016/j.gie.2015.03.1977](#)]
- 48 **Kim JS**, Kim BW, Kim JI, Kim JH, Kim SW, Ji JS, Lee BI, Choi H. Endoscopic clip closure versus surgery for the treatment of iatrogenic colon perforations developed during diagnostic colonoscopy: a review of 115,285 patients. *Surg Endosc* 2013; **27**: 501-504 [PMID: [22773239](#) DOI: [10.1007/s00464-012-2465-3](#)]
- 49 **Haito-Chavez Y**, Law JK, Kratt T, Arezzo A, Verra M, Morino M, Sharaiha RZ, Poley JW, Kahaleh M, Thompson CC, Ryan MB, Choksi N, Elmunzer BJ, Gosain S, Goldberg EM, Modayil RJ, Stavropoulos SN, Schembre DB, DiMaio CJ, Chandrasekhara V, Hasan MK, Varadarajulu S, Hawes R, Gomez V, Woodward TA, Rubel-Cohen S, Fluxa F, Vleggaar FP, Akshintala VS, Raju GS, Khashab MA. International multicenter experience with an over-the-scope clipping device for endoscopic management of GI defects (with video). *Gastrointest Endosc* 2014; **80**: 610-622 [PMID: [24908191](#) DOI: [10.1016/j.gie.2014.03.049](#)]
- 50 **Morrell DJ**, Winder JS, Johri A, Docimo S, Juza RM, Witte SR, Alli VV, Pauli EM. Over-the-scope clip management of non-acute, full-thickness gastrointestinal defects. *Surg Endosc* 2020; **34**: 2690-2702 [PMID: [31350610](#) DOI: [10.1007/s00464-019-07030-3](#)]
- 51 **Swan RZ**, Sindram D, Martinie JB, Iannitti DA. Operative microwave ablation for hepatocellular carcinoma: complications, recurrence, and long-term outcomes. *J Gastrointest Surg* 2013; **17**: 719-729 [PMID: [23404173](#) DOI: [10.1007/s11605-013-2164-y](#)]
- 52 **Song I**, Rhim H, Lim HK, Kim YS, Choi D. Percutaneous radiofrequency ablation of hepatocellular carcinoma abutting the diaphragm and gastrointestinal tracts with the use of artificial ascites: safety and technical efficacy in 143 patients. *Eur Radiol* 2009; **19**: 2630-2640 [PMID: [19557416](#) DOI: [10.1007/s00330-009-1463-x](#)]
- 53 **Koda M**, Murawaki Y, Hirooka Y, Kitamoto M, Ono M, Sakaeda H, Joko K, Sato S, Tamaki K, Yamasaki T, Shibata H, Shimoe T, Matsuda T, Toshikuni N, Fujioka S, Ohmoto K, Nakamura S, Kariyama K, Aikata H, Kobayashi Y, Tsutsui A. Complications of radiofrequency ablation for hepatocellular carcinoma in a multicenter study: An analysis of 16 346 treated nodules in 13 283 patients. *Hepatol Res* 2012; **42**: 1058-1064 [PMID: [22583706](#) DOI: [10.1111/j.1872-034X.2012.01025.x](#)]
- 54 **Park JG**, Park SY, Tak WY, Kweon YO, Jang SY, Lee YR, Hur K, Lee HJ, Lee HW. Early complications after percutaneous radiofrequency ablation for hepatocellular carcinoma: an analysis of 1,843 ablations in 1,211 patients in a single centre: experience over 10 years. *Clin Radiol* 2017; **72**: 692.e9-692.e15 [PMID: [28364952](#) DOI: [10.1016/j.crad.2017.03.001](#)]
- 55 **Kondo Y**, Yoshida H, Shiina S, Tateishi R, Teratani T, Omata M. Artificial ascites technique for percutaneous radiofrequency ablation of liver cancer adjacent to the gastrointestinal tract. *Br J Surg* 2006; **93**: 1277-1282 [PMID: [16783759](#) DOI: [10.1002/bjs.5374](#)]
- 56 **Rhim H**, Yoon KH, Lee JM, Cho Y, Cho JS, Kim SH, Lee WJ, Lim HK, Nam GJ, Han SS, Kim YH, Park CM, Kim PN, Byun JY. Major complications after radio-frequency thermal ablation of hepatic tumors: spectrum of imaging findings. *Radiographics* 2003; **23**: 123-34; discussion 134-6 [PMID: [12533647](#) DOI: [10.1148/rg.231025054](#)]
- 57 **Curley SA**, Marra P, Beaty K, Ellis LM, Vauthey JN, Abdalla EK, Scaife C, Raut C, Wolff R, Choi H, Loyer E, Vallone P, Fiore F, Scordino F, De Rosa V, Orlando R, Pignata S, Daniele B, Izzo F. Early and late complications after radiofrequency ablation of malignant liver tumors in 608 patients. *Ann Surg* 2004; **239**: 450-458 [PMID: [15024305](#) DOI: [10.1097/01.sla.00000118373.31781.f2](#)]
- 58 **Jansen MC**, van Duijnhoven FH, van Hillegersberg R, Rijken A, van Coevorden F, van der Sijp J, Prevoo W, van Gulik TM. Adverse effects of radiofrequency ablation of liver tumours in the Netherlands. *Br J Surg* 2005; **92**: 1248-1254 [PMID: [15997440](#) DOI: [10.1002/bjs.5059](#)]
- 59 **Maeda M**, Saeki I, Sakaida I, Aikata H, Araki Y, Ogawa C, Kariyama K, Nouse K, Kitamoto M, Kobashi H, Sato S, Shibata H, Joko K, Takaki S, Takabatake H, Tsutsui A, Takaguchi K, Tomonari T, Nakamura S, Nagahara T, Hiraoka A, Matono T, Koda M, Mandai M, Mannami T, Mitsuda A, Moriya T, Yabushita K, Tani J, Yagi T, Yamasaki T. Complications after Radiofrequency Ablation for Hepatocellular Carcinoma: A Multicenter Study Involving 9,411 Japanese Patients. *Liver Cancer* 2020; **9**: 50-62 [PMID: [32071909](#) DOI: [10.1159/000502744](#)]



Published by **Baishideng Publishing Group Inc**
7041 Koll Center Parkway, Suite 160, Pleasanton, CA 94566, USA

Telephone: +1-925-3991568

E-mail: bpgoffice@wjgnet.com

Help Desk: <https://www.f6publishing.com/helpdesk>

<https://www.wjgnet.com>

