



国内版 国际版

Mucinous adenocarcinoma of the buttock associated with hidraden



ALL

IMAGES

VIDEOS

28,800 Results

Any time ▾

### Mucinous adenocarcinoma associated with chronic ...

<https://www.ncbi.nlm.nih.gov/pmc/articles/PMC4949808>

Mucinous adenocarcinoma in patients with Chronic Suppurative Hidradenitis (CSH). The most common symptoms of the mucinous adenocarcinoma are **local pain** (58%), **rectal bleeding** (40%) and **perineal sense of mass** (37%).

Cited by: 1

Author: Natalia Mukai, Lilian Vital Pinheiro, Maria...

Publish Year: 2016

### Chronic hidradenitis suppurativa and perianal mucinous ...

[hidradenitissuppurativaawareness.org/hs/chronic...](http://hidradenitissuppurativaawareness.org/hs/chronic...) ▾

Nov 23, 2017 · When located in the genital and perianal regions, it may be associated with cancer. This is the first case report of hidradenitis suppurativa in the vulvar region associated with perianal mucinous adenocarcinoma. CASE: The patient was a 48-year-old woman who presented with extensive hidradenitis suppurativa in the vulvar and perianal regions. She had a 10-year history of hidradenitis suppurativa, ...

### [PDF] International Journal of Surgery Case Reports

<https://www.researchgate.net/profile/Carlos...>

Please cite this article in press as: N. Mukai, et al., Mucinous adenocarcinoma associated with chronic suppurative hidradenitis: Report of a case and review of the literature, Int J Surg Case Rep ...

### Cutaneous squamous cell carcinoma arising in hidradenitis ...

<https://www.ncbi.nlm.nih.gov/pmc/articles/PMC6537059>

May 17, 2019 · We present a case of a 64-year-old man who presented with a rapidly growing tumor in the left **buttock** and intergluteal cleft area, which was affected by **hidradenitis suppurativa**. The patient was on tumor necrosis factor-alpha inhibitors for **hidradenitis suppurativa** for 2 years prior to the development of the mass.

Author: Catherine F Roy, Simon F Roy, Feras ... Publish Year: 2019

### [PDF] International Journal of Surgery Case Reports

<https://core.ac.uk/download/pdf/81970314.pdf>

INTRODUCTION: Chronic suppurative hidradenitis (CSH) is a benign condition that can affect the **perineal** region and often leads to the formation of **abscesses** and **fistulas**. It is rare for CSH to undergo



Mucinous adenocarcinoma of the buttock associated with hidraden



ALL IMAGES VIDEOS MAPS NEWS SHOPPING

31,100 Results Any time ▾

### Mucinous adenocarcinoma associated with chronic ...

<https://www.ncbi.nlm.nih.gov/pmc/articles/PMC4949808>

Mucinous adenocarcinoma in patients with **Chronic Suppurative Hidradenitis (CSH)**. The most common symptoms of the mucinous adenocarcinoma are **local pain** (58%), **rectal bleeding** (40%) and **perineal sense of mass** (37%).

**Cited by:** 1 **Author:** Natalia Mukai, Lillian Vital Pinheiro, Maria ...

**Publish Year:** 2016

### Chronic hidradenitis suppurativa and perianal mucinous ...

[hidradenitissuppurativaawareness.org/hs/chronic...](https://hidradenitissuppurativaawareness.org/hs/chronic...)

Nov 23, 2017 · When located in the genital and perianal regions, it may be **associated with cancer**. This is the first **case report** of **hidradenitis suppurativa** in the vulvar region associated with **perianal mucinous adenocarcinoma**. **CASE:** The **patient** was a 48-year-old woman who presented with extensive **hidradenitis suppurativa** in the vulvar and perianal regions. She had a 10-year history of **hidradenitis suppurativa**...

### [PDF] International Journal of Surgery Case Reports

<https://www.researchgate.net/profile/Carlos...>

Please cite this article in press as: N. Mukai, et al., **Mucinous adenocarcinoma associated with chronic suppurative hidradenitis: Report of a case** and review of the literature, *Int J Surg Case Rep* ...

### (PDF) Mucinous Adenocarcinoma associated with Chronic ...

<https://www.researchgate.net/publication/305077464...>

**Mucinous Adenocarcinoma associated with Chronic Suppurative Hidradenitis: Report of a case** and review of the literature Article (PDF Available) in *International Journal of Surgery Case Reports* 26 ...

### [PDF] International Journal of Surgery Case Reports

<https://core.ac.uk/download/pdf/81970314.pdf>

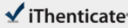
**Mucinous adenocarcinoma Chronic reconstruction. suppurative hidradenitis Case following report Colorectal surgery a b s t r a c t** **INTRODUCTION:** Chronic suppurative hidradenitis (CSH) is a benign condition that can affect the perineal region and often leads to the formation of abscesses and fistulas. It is rare for CSH to undergo malignant

[/www.ncbi.nlm.nih.gov/pmc/articles/PMC4949808/](https://www.ncbi.nlm.nih.gov/pmc/articles/PMC4949808/)

16-Aug-2020 05:17PM

2047 words - 3 matches - 3 sources

FAQ

 iThenticate®

58097-Review-check.docx

Quotes Included  
Bibliography Included

3%  
similarity

**Name of Journal:** *World Journal of Clinical Cases*

**Manuscript NO:** 58097

**Manuscript Type:** CASE REPORT

**Mucinous adenocarcinoma of the buttock associated with hidradenitis: A case report**

Kim SJ *et al.* Mucinous adenocarcinoma of the buttock

Sung Jin Kim, Tae Gon Kim, Mi Jin Gu, Sohyun Kim

**Abstract**

BACKGROUND

Mucinous adenocarcinomas of the buttock are rare and have an uncertain etiology and natural course. They are usually related to chronic anal fistulas, hidradenitis suppurativa, or Crohn's disease. Here, we report a case of mucinous adenocarcinoma associated with hidradenitis and contradictory immunochemistry results.

CASE SUMMARY

A 62-year-old man complained of recurrent abscesses of the buttock for 3 years. He had

Match Overview

1

Internet 31 words  
crawled on 27-Apr-2020  
[semalesforex.com](#)

2%

2

Internet 14 words  
crawled on 07-Jun-2020  
[lessera.spandidos-publications.com](#)

1%

3

Internet 14 words  
crawled on 27-Apr-2020  
[figpublishing.blob.core.windows.net](#)

1%

Page 1 of 11

Text Only Report

国内版

国际版



Mucinous adenocarcinoma of the buttock associated with hidrade



ALL

IMAGES

VIDEOS

29,900 Results

Any time ▾

### Mucinous adenocarcinoma associated with chronic ...

<https://www.ncbi.nlm.nih.gov/pmc/articles/PMC4949808>

Mucinous adenocarcinoma associated with chronic suppurative hidradenitis: Report of a case and review of the literature **Natalia Mukai** , a **Lílian Vital Pinheiro** , a **Maria de Lourdes Setsuko Ayrizono** , a **Guilherme Cardinali Barreiro** , **b Paulo Kharmandayan** , **b Mariana Hanayo Akinaga** , **b Adriano Mesquita Bento** , **b Carlos Augusto Real Martinez** , a **Rita Barbosa de Carvalho** , **c Marc Ward** , **d Cláudio Saddy Rodrigues Coy** , a and **Raquel Franco Leal a...**

Cited by: 1

Author: Natalia Mukai, Lílian Vital Pinheiro, Mari...

Publish Year: 2016

### Chronic hidradenitis suppurativa and perianal mucinous ...

[hidradenitissuppurativaawareness.org/hs/chronic-hidradenitis-suppurativa-and-perianal...](http://hidradenitissuppurativaawareness.org/hs/chronic-hidradenitis-suppurativa-and-perianal...) ▾

Author(s): do Val IC, Almeida Filho GL, Corrêa A, Neto N BACKGROUND: **Hidradenitis** is a chronic and suppurative inflammation of the **apocrine sudoriparous glands**. When located in the genital and perianal regions, it may be **associated** with cancer. This is the first **case report** ...

### [PDF] International Journal of Surgery Case Reports

[https://www.researchgate.net/profile/Carlos\\_Martinez24/publication/305077464\\_Mucinous...](https://www.researchgate.net/profile/Carlos_Martinez24/publication/305077464_Mucinous...)

**Journal of Surgery Case Reports** journal homepage: [www.casereports.com](http://www.casereports.com) **Mucinous adenocarcinoma associated with chronic suppurative hidradenitis: Report of a case** and review of the literature Natalia

### [PDF] International Journal of Surgery Case Reports

<https://core.ac.uk/download/pdf/81970314.pdf>

INTRODUCTION: **Chronic suppurative hidradenitis (CSH)** is a benign condition that can affect the **perineal** region and often leads to the formation of abscesses and fistulas. It is rare for CSH to undergo **malignant degeneration** into **mucinous adenocarcinoma**.