

World Journal of *Clinical Cases*

World J Clin Cases 2020 October 26; 8(20): 4688-5069



MINIREVIEWS

- 4688 Relationship between non-alcoholic fatty liver disease and coronary heart disease
Arslan U, Yenerçaz M

ORIGINAL ARTICLE

Retrospective Cohort Study

- 4700 Remission of hepatotoxicity in chronic pulmonary aspergillosis patients after lowering trough concentration of voriconazole
Teng GJ, Bai XR, Zhang L, Liu HJ, Nie XH

Retrospective Study

- 4708 Endoscopic submucosal dissection as alternative to surgery for complicated gastric heterotopic pancreas
Noh JH, Kim DH, Kim SW, Park YS, Na HK, Ahn JY, Jung KW, Lee JH, Choi KD, Song HJ, Lee GH, Jung HY
- 4719 Observation of the effects of three methods for reducing perineal swelling in children with developmental hip dislocation
Wang L, Wang N, He M, Liu H, Wang XQ
- 4726 Predictive value of serum cystatin C for risk of mortality in severe and critically ill patients with COVID-19
Li Y, Yang S, Peng D, Zhu HM, Li BY, Yang X, Sun XL, Zhang M
- 4735 Sleep quality of patients with postoperative glioma at home
Huang Y, Jiang ZJ, Deng J, Qi YJ
- 4743 Early complications of preoperative external traction fixation in the staged treatment of tibial fractures: A series of 402 cases
Yang JZ, Zhu WB, Li LB, Dong QR
- 4753 Retroperitoneal vs transperitoneal laparoscopic lithotripsy of 20-40 mm renal stones within horseshoe kidneys
Chen X, Wang Y, Gao L, Song J, Wang JY, Wang DD, Ma JX, Zhang ZQ, Bi LK, Xie DD, Yu DX
- 4763 Undifferentiated embryonal sarcoma of the liver: Clinical characteristics and outcomes
Zhang C, Jia CJ, Xu C, Sheng QJ, Dou XG, Ding Y
- 4773 Cerebral infarct secondary to traumatic internal carotid artery dissection
Wang GM, Xue H, Guo ZJ, Yu JL
- 4785 Home-based nursing for improvement of quality of life and depression in patients with postpartum depression
Zhuang CY, Lin SY, Cheng CJ, Chen XJ, Shi HL, Sun H, Zhang HY, Fu MA

Observational Study

- 4793** Cost-effectiveness of lutetium (^{177}Lu) oxodotreotide *vs* everolimus in gastroenteropancreatic neuroendocrine tumors in Norway and Sweden
Palmer J, Leeuwenkamp OR
- 4807** Factors related to improved American Spinal Injury Association grade of acute traumatic spinal cord injury
Tian C, Lv Y, Li S, Wang DD, Bai Y, Zhou F, Ma QB
- 4816** Intraoperative systemic vascular resistance is associated with postoperative nausea and vomiting after laparoscopic hysterectomy
Qu MD, Zhang MY, Wang GM, Wang Z, Wang X

META-ANALYSIS

- 4826** Underwater *vs* conventional endoscopic mucosal resection in treatment of colorectal polyps: A meta-analysis
Ni DQ, Lu YP, Liu XQ, Gao LY, Huang X

CASE REPORT

- 4838** Dehydrated patient without clinically evident cause: A case report
Palladino F, Fedele MC, Casertano M, Liguori L, Esposito T, Guarino S, Miraglia del Giudice E, Marzuillo P
- 4844** Intracranial malignant solitary fibrous tumor metastasized to the chest wall: A case report and review of literature
Usuda D, Yamada S, Izumida T, Sangen R, Higashikawa T, Nakagawa K, Iguchi M, Kasamaki Y
- 4853** End-of-life home care of an interstitial pneumonia patient supported by high-flow nasal cannula therapy: A case report
Goda K, Kenzaka T, Kuriyama K, Hoshijima M, Akita H
- 4858** Rupture of carotid artery pseudoaneurysm in the modern era of definitive chemoradiation for head and neck cancer: Two case reports
Kim M, Hong JH, Park SK, Kim SJ, Lee JH, Byun J, Ko YH
- 4866** Unremitting diarrhoea in a girl diagnosed anti-N-methyl-D-aspartate-receptor encephalitis: A case report
Onpoaree N, Veeravigrom M, Sanpavat A, Suratannon N, Sintusek P
- 4876** Paliperidone palmitate-induced facial angioedema: A case report
Srifuengfung M, Sukakul T, Liangcheep C, Viravan N
- 4883** Improvement of lenvatinib-induced nephrotic syndrome after adaptation to sorafenib in thyroid cancer: A case report
Yang CH, Chen KT, Lin YS, Hsu CY, Ou YC, Tung MC
- 4895** Adult metaplastic hutch diverticulum with robotic-assisted diverticulectomy and reconstruction: A case report
Yang CH, Lin YS, Ou YC, Weng WC, Huang LH, Lu CH, Hsu CY, Tung MC

- 4902** Thrombus straddling a patent foramen ovale and pulmonary embolism: A case report
Huang YX, Chen Y, Cao Y, Qiu YG, Zheng JY, Li TC
- 4908** Therapeutic experience of an 89-year-old high-risk patient with incarcerated cholecystolithiasis: A case report and literature review
Zhang ZM, Zhang C, Liu Z, Liu LM, Zhu MW, Zhao Y, Wan BJ, Deng H, Yang HY, Liao JH, Zhu HY, Wen X, Liu LL, Wang M, Ma XT, Zhang MM, Liu JJ, Liu TT, Huang NN, Yuan PY, Gao YJ, Zhao J, Guo XA, Liao F, Li FY, Wang XT, Yuan RJ, Wu F
- 4917** Woven coronary artery: A case report
Wei W, Zhang Q, Gao LM
- 4922** Idiopathic multicentric Castleman disease with pulmonary and cutaneous lesions treated with tocilizumab: A case report
Han PY, Chi HH, Su YT
- 4930** Perianorectal abscesses and fistula due to ingested jujube pit in infant: Two case reports
Liu YH, Lv ZB, Liu JB, Sheng QF
- 4938** Forniceal deep brain stimulation in severe Alzheimer's disease: A case report
Lin W, Bao WQ, Ge JJ, Yang LK, Ling ZP, Xu X, Jiang JH, Zuo CT, Wang YH
- 4946** Systemic autoimmune abnormalities complicated by cytomegalovirus-induced hemophagocytic lymphohistiocytosis: A case report
Miao SX, Wu ZQ, Xu HG
- 4953** Nasal mucosa pyoderma vegetans associated with ulcerative colitis: A case report
Yu SX, Cheng XK, Li B, Hao JH
- 4958** Amiodarone-induced hepatotoxicity — quantitative measurement of iodine density in the liver using dual-energy computed tomography: Three case reports
Lv HJ, Zhao HW
- 4966** Multisystem involvement Langerhans cell histiocytosis in an adult: A case report
Wang BB, Ye JR, Li YL, Jin Y, Chen ZW, Li JM, Li YP
- 4975** New mutation in EPCAM for congenital tufting enteropathy: A case report
Zhou YQ, Wu GS, Kong YM, Zhang XY, Wang CL
- 4981** Catastrophic vertebral artery and subclavian artery pseudoaneurysms caused by a fishbone: A case report
Huang W, Zhang GQ, Wu JJ, Li B, Han SG, Chao M, Jin K
- 4986** Anastomosing hemangioma arising from the left renal vein: A case report
Zheng LP, Shen WA, Wang CH, Hu CD, Chen XJ, Shen YY, Wang J
- 4993** Bladder perforation caused by long-term catheterization misdiagnosed as digestive tract perforation: A case report
Wu B, Wang J, Chen XJ, Zhou ZC, Zhu MY, Shen YY, Zhong ZX

- 4999** Primary pulmonary plasmacytoma accompanied by overlap syndrome: A case report and review of the literature
Zhou Y, Wang XH, Meng SS, Wang HC, Li YX, Xu R, Lin XH
- 5007** Gastrointestinal stromal tumor metastasis at the site of a totally implantable venous access port insertion: A rare case report
Yin XN, Yin Y, Wang J, Shen CY, Chen X, Zhao Z, Cai ZL, Zhang B
- 5013** Massive gastrointestinal bleeding caused by a Dieulafoy's lesion in a duodenal diverticulum: A case report
He ZW, Zhong L, Xu H, Shi H, Wang YM, Liu XC
- 5019** Plastic bronchitis associated with *Botrytis cinerea* infection in a child: A case report
Liu YR, Ai T
- 5025** Chest, pericardium, abdomen, and thigh penetrating injury by a steel rebar: A case report
Yang XW, Wang WT
- 5030** Monocular posterior scleritis presenting as acute conjunctivitis: A case report
Li YZ, Qin XH, Lu JM, Wang YP
- 5036** Choriocarcinoma with lumbar muscle metastases: A case report
Pang L, Ma XX
- 5042** Primary chondrosarcoma of the liver: A case report
Liu ZY, Jin XM, Yan GH, Jin GY
- 5049** Successful management of a tooth with endodontic-periodontal lesion: A case report
Alshawwa H, Wang JF, Liu M, Sun SF
- 5057** Rare imaging findings of hypersensitivity pneumonitis: A case report
Wang HJ, Chen XJ, Fan LX, Qi QL, Chen QZ
- 5062** Effective administration of cranial drilling therapy in the treatment of fourth degree temporal, facial and upper limb burns at high altitude: A case report
Shen CM, Li Y, Liu Z, Qi YZ

ABOUT COVER

Peer-reviewer of *World Journal of Clinical Cases*, Dr. Aleem Ahmed Khan is a Distinguished Scientist and Head of The Central Laboratory for Stem Cell Research and Translational Medicine, Centre for Liver Research and Diagnostics, Deccan College of Medical Sciences, Kanchanbagh, Hyderabad (India). Dr. Aleem completed his Doctorate from Osmania University, Hyderabad in 1998 and has since performed pioneering work in the treatment of acute liver failure and decompensated cirrhosis using hepatic stem cell transplantation. During his extensive research career he supervised 10 PhD students and published > 150 research articles, 7 book chapters, and 2 patents. His ongoing research involves developing innovative technologies for organ regeneration and management of advanced cancers. (L-Editor: Filipodia)

AIMS AND SCOPE

The primary aim of *World Journal of Clinical Cases* (*WJCC*, *World J Clin Cases*) is to provide scholars and readers from various fields of clinical medicine with a platform to publish high-quality clinical research articles and communicate their research findings online.

WJCC mainly publishes articles reporting research results and findings obtained in the field of clinical medicine and covering a wide range of topics, including case control studies, retrospective cohort studies, retrospective studies, clinical trials studies, observational studies, prospective studies, randomized controlled trials, randomized clinical trials, systematic reviews, meta-analysis, and case reports.

INDEXING/ABSTRACTING

The *WJCC* is now indexed in Science Citation Index Expanded (also known as SciSearch®), Journal Citation Reports/Science Edition, PubMed, and PubMed Central. The 2020 Edition of Journal Citation Reports® cites the 2019 impact factor (IF) for *WJCC* as 1.013; IF without journal self cites: 0.991; Ranking: 120 among 165 journals in medicine, general and internal; and Quartile category: Q3.

RESPONSIBLE EDITORS FOR THIS ISSUE

Production Editor: Ji-Hong Liu; Production Department Director: Xiang Li; Editorial Office Director: Jin-Lai Wang.

NAME OF JOURNAL

World Journal of Clinical Cases

ISSN

ISSN 2307-8960 (online)

LAUNCH DATE

April 16, 2013

FREQUENCY

Semimonthly

EDITORS-IN-CHIEF

Dennis A Bloomfield, Sandro Vento, Bao-Gan Peng

EDITORIAL BOARD MEMBERS

<https://www.wjgnet.com/2307-8960/editorialboard.htm>

PUBLICATION DATE

October 26, 2020

COPYRIGHT

© 2020 Baishideng Publishing Group Inc

INSTRUCTIONS TO AUTHORS

<https://www.wjgnet.com/bpg/gerinfo/204>

GUIDELINES FOR ETHICS DOCUMENTS

<https://www.wjgnet.com/bpg/GerInfo/287>

GUIDELINES FOR NON-NATIVE SPEAKERS OF ENGLISH

<https://www.wjgnet.com/bpg/gerinfo/240>

PUBLICATION ETHICS

<https://www.wjgnet.com/bpg/GerInfo/288>

PUBLICATION MISCONDUCT

<https://www.wjgnet.com/bpg/gerinfo/208>

ARTICLE PROCESSING CHARGE

<https://www.wjgnet.com/bpg/gerinfo/242>

STEPS FOR SUBMITTING MANUSCRIPTS

<https://www.wjgnet.com/bpg/GerInfo/239>

ONLINE SUBMISSION

<https://www.f6publishing.com>



Retrospective Study

Early complications of preoperative external traction fixation in the staged treatment of tibial fractures: A series of 402 cases

Jia-Zhao Yang, Wan-Bo Zhu, Liu-Bing Li, Qi-Rong Dong

ORCID number: Jia-Zhao Yang 0000-0002-7838-285X; Wan-Bo Zhu 0000-0003-3457-3432; Liu-Bing Li 0000-0002-4117-3819; Qi-Rong Dong 0000-0001-6833-1576.

Author contributions: Zhu WB and Yang JZ conceived and designed the study; Yang JZ collected the data and wrote the manuscript; Li LB and Dong QR read, revised, and approved the final manuscript; All authors read and approved the final manuscript.

Institutional review board

statement: This study was approved by the Ethics Committee of the First Affiliated Hospital of USTC (2020-P-061). As for this research, an optout of the informed consent, the information disclosure, and a negative opportunity are guaranteed in the Ethical approval.

Informed consent statement: All subjects participating in the study signed the informed consent statement form.

Conflict-of-interest statement: There is no conflict of interest issue related to this work.

Data sharing statement: Please contact author for data requests.

Open-Access: This article is an

Jia-Zhao Yang, Liu-Bing Li, Qi-Rong Dong, Department of Orthopedics, The Second Affiliated Hospital of Soochow University, Suzhou 215004, Jiangsu Province, China

Jia-Zhao Yang, Department of Traumatic Orthopedics, The First Affiliated Hospital of USTC, Hefei 230000, Anhui Province, China

Wan-Bo Zhu, Department of Traumatic Orthopedics, Affiliated Anhui Provincial Hospital of Anhui Medical University, Hefei 230000, Anhui Province, China

Corresponding author: Qi-Rong Dong, MD, Chief Doctor, Department of Orthopedics, The Second Affiliated Hospital of Soochow University, No. 1055 Sanxiang Road, Suzhou 215004, Jiangsu Province, China. dongqirong@suda.edu.cn

Abstract

BACKGROUND

Different external skeletal fixators have been widely used in preoperative traction of high-energy tibial fractures prior to a definitive surgical treatment. However, the early complications associated with this staged treatment for traction and soft tissue injury recovery have rarely been discussed.

AIM

To analyze the early complications associated with preoperative external traction fixation in the staged treatment of tibial fractures.

METHODS

A total of 402 patients with high-energy tibial fractures treated using preoperative external traction fixation at a Level 1 trauma center from 2014 to 2018 were enrolled in this retrospective study. Data regarding the demographic information, Tscherne soft tissue injury, fracture site, entry point placement, and duration of traction were recorded. Procedure-related complications such as movement and sensation disorder, vessel injury, discharge, infection, loosening, and iatrogenic fractures were analyzed.

RESULTS

The mean patient age was 42.5 (18-71) years, and the mean duration of traction was 7.5 (0-26) d. In total, 19 (4.7%) patients presented with procedure-related complications, including technique-associated complications in 6 patients and nursing-associated complications in 13. Differences in the incidence of

open-access article that was selected by an in-house editor and fully peer-reviewed by external reviewers. It is distributed in accordance with the Creative Commons Attribution NonCommercial (CC BY-NC 4.0) license, which permits others to distribute, remix, adapt, build upon this work non-commercially, and license their derivative works on different terms, provided the original work is properly cited and the use is non-commercial. See: <http://creativecommons.org/licenses/by-nc/4.0/>

Manuscript source: Unsolicited manuscript

Received: July 10, 2020

Peer-review started: July 10, 2020

First decision: August 8, 2020

Revised: August 20, 2020

Accepted: September 15, 2020

Article in press: September 15, 2020

Published online: October 26, 2020

P-Reviewer: Wu C

S-Editor: Gong ZM

L-Editor: Filipodia

P-Editor: Li JH



complications with respect to sex, affected side, soft tissue injury classification, and fracture sites were not observed. However, the number of complications due to hammer insertion was significantly reduced than those due to drill insertions (2.9% *vs* 7.4%).

CONCLUSION

We found a low incidence of early complications related to the fixation. Furthermore, the complications were not significantly associated with the severity of the soft tissue injury and fracture site. Although relatively rough and more likely to cause pain, the number of complications associated with hammer insertion was significantly smaller than that of complications associated with drill insertion.

Key Words: Tibial fracture; External fixation; Bone traction; Complications; Vessels injury; Nerve injury

©The Author(s) 2020. Published by Baishideng Publishing Group Inc. All rights reserved.

Core Tip: The safety of external traction fixation has not been well studied. This study included 402 patients who underwent external traction fixation for high-energy tibial fractures. Overall incidence of complications was low (4.7%); vascular injury or compartmental syndrome was not noted. Complications of hammer insertions were significantly fewer than drill insertions.

Citation: Yang JZ, Zhu WB, Li LB, Dong QR. Early complications of preoperative external traction fixation in the staged treatment of tibial fractures: A series of 402 cases. *World J Clin Cases* 2020; 8(20): 4743-4752

URL: <https://www.wjgnet.com/2307-8960/full/v8/i20/4743.htm>

DOI: <https://dx.doi.org/10.12998/wjcc.v8.i20.4743>

INTRODUCTION

High-energy tibial fractures (including AO/OTA-41/42/43/44), also known as “soft tissue injuries combined with fractures,” are considered a challenge for orthopedic traumatologists^[1]. The soft tissue coverage and vascular distribution of the tibia are limited, leading to a high incidence of complications, such as wound dehiscence and infection^[2]. Therefore, the condition of the soft tissue often limits the choice for open surgery for high-energy tibial fractures. The selection of a simple and universal preoperative transitional staged therapeutic strategy is particularly important for patients with high-energy tibial fractures who are not suitable for immediate internal fixation surgery.

Various external skeletal fixation procedures and devices have been widely used for preoperative traction of tibial fractures. As with all invasive procedures, the risks and complications associated with inserting pins, such as neurovascular injuries, are occasionally reported in literature^[3-6]. However, systematic complication analyses are rarely reported as routine management in staged treatment for preoperative soft tissue amelioration of tibial fractures. In this study, we investigated the early complications associated with the application of preoperative external traction fixation in the staged treatment of high-energy tibial fractures, based on a series of 402 cases.

MATERIALS AND METHODS

This retrospective study was conducted at a Level 1 trauma center in a province with a population of more than 60 million in China. Patients who underwent staged treatment of closed tibial fractures and Gustilo I open fractures (AO/OTA-41 proximal tibial fractures, AO/OTA-42 middle tibial fractures, AO/OTA-43 distal tibial fractures or pilon fractures, and AO/OTA-44 ankle fractures) with preoperative external traction fixation between January 2015 to December 2018 were enrolled. The exclusion

criteria were: Incomplete medical records, presence of a Gustilo II or III open fracture, previous disability, severe concomitant injury impairing verbal communication, and adoption of definitive treatment with an external fixator. A total of 402 patients were enrolled.

Demographic information, Tscherne soft tissue classification, fracture site, entry point placement, and duration of traction were recorded. Complications were assessed by physical examinations, as follows: Assessment of the range of motion, which included decreased flexion and extension of the ankle and toes; sensory examination, which included hypoesthesia or loss of sensation; vascular examination, which included decreased or absent pulse in the dorsalis pedis or posterior tibial arteries; signs of infection, which included discharge, redness, and swelling of the pin tract; loosening of the pin; and iatrogenic fractures. These physical examinations were performed at three different time-points (before traction, after traction, and after removal). Patients who showed inconsistent results before and after the placement of an external traction fixator were monitored for complications. Two observers collected the aforementioned data and the imaging data of the patients from the medical records. The ethics review committee of the institution approved the study protocol.

Intervention

The patient was positioned in the supine position. The limbs on the affected side were propped up using pillows. Based on the fracture site and length of the tibia, the length of the connecting rod was selected preoperatively to avoid a secondary incision. Bone landmarks were marked at both ends of the fracture to indicate the insertion points. After disinfection with 0.5% iodophor and draping, the injured limb was maintained in a neutral position by an assistant. We used 1% lidocaine to infiltrate and locally anesthetize the periosteum at the insertion points on both sides. A scalpel penetrated the skin, and two 4.0-mm smooth Steinmann pins were inserted at the proximal and distal ends of the fracture, parallel to the ground and perpendicular to the bone axis, using a hammer or an electric high-speed power drill. If necessary, the direction was adjusted with an assistant's guidance before perforation of the first bone cortex. [Table 1](#) shows the specific placement method. Femoral supracondylar and lower tibial pins were selected for tibial plateau fractures, while calcaneal and upper tibial pins were selected for tibial shaft fractures ([Figure 1](#)). Using the length of the healthy limb as a reference, the assistant pulled and tightened the distal pin-to-rod clamp when the length of the limb was restored or the length exceeded by approximately 1 cm. If necessary, the fracture alignment was reassessed using radiography to determine the need for further adjustments in traction force and transverse connecting rod length to achieve better stability. Correction of fracture shortening and maintenance of soft tissue tension were prioritized; anatomical reduction was not mandatory.

The operative area was disinfected again immediately after installation of the external traction fixator. Medical alcohol was used to disinfect the pin insertion site and connecting rod twice per day. Patients were discharged home and re-admitted for definitive surgical treatment. Follow-up was conducted through social networking or telephone interviews to assess the condition of the soft tissue. The standard for re-admittance for definitive treatment depended on the recovery of the injured tissue was established at the discretion of the experienced surgeons.

Statistical analysis

SPSS Statistics 20 (IBM Corp, Armonk, NY, United States) was used for statistical analysis. For numerical variables, normality was tested using the Shapiro-Wilk test. As most variables displayed a skewed distribution, the Mann-Whitney *U* test was used for comparison. The chi-square test or Fisher's exact test was used for the categorical variables. The tests were two-sided, and $P < 0.05$ was considered statistically significant. The incidence rate of complications was further analyzed with respect to the related factors including sex, affected side, screw placement method, and fracture site.

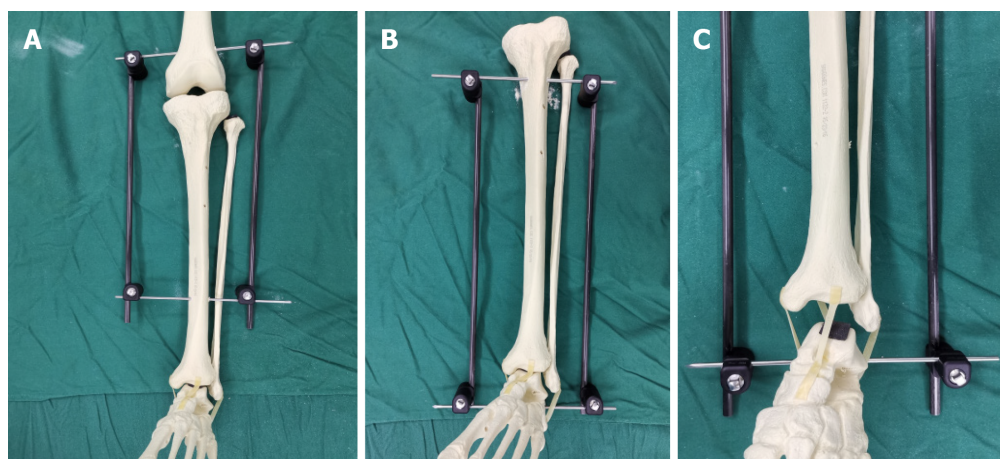
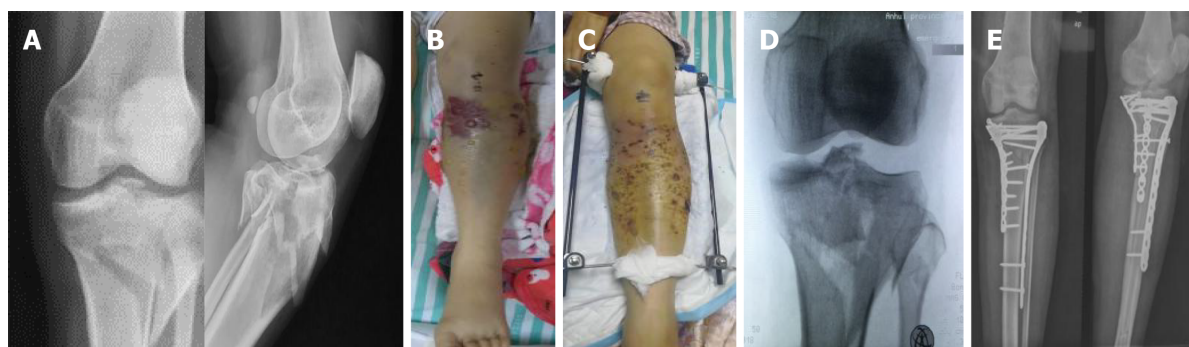RESULTS

Illustrative cases

Case 1: A 55-year-old female patient was injured in a road accident ([Figure 2](#)) and experienced a left tibial plateau fracture (AO/OTA 41-C3) combined with a pulmonary injury. The Tscherne soft tissue injury classification was C3, and blisters were observed 12 h after the injury. The external traction fixator was applied in the

Table 1 Position and direction of Steinmann pin entry point

Position	Entry point	Direction
Supracondylar femur	Intersection of horizontal line two digits upper patella and sagittal line three digits beside the midline	Medial to lateral
Proximal tibia	2 cm distal to the point 2 cm beside the highest point of the tibial tubercle	Lateral to medial
Distal tibia	More than 5 cm above the leading edge of the ankle	Lateral to medial
Calcaneus	The posterior 2/3 point of the line between the tip of the medial malleolus and the posterior lower margin of the heel	Medial to lateral

**Figure 1** Illustration for external traction fixator. A: AO/OTA-41 with the femoral supracondylar and lower tibia entry point; B: AO/OTA-42/43/44 with the upper tibia and calcaneus entry point; C: Traction after fracture, restoring alignment and length through ligament tension.**Figure 2** Illustrative case 1. A: Radiograph after injury (AO/OTA-41-C3); B: Soft tissue swelling and blisters before external traction fixator installing; C: Ten days after external traction fixator application; D: Preoperative radiograph showed increased joint space and improved plateau alignment; E: Postoperative radiograph.

ward. The radiographs revealed an increased joint space and partial reduction of the lateral plateau. The blisters subsided on the 10th d after the injury, and a lateral-medial combined incision approach was used for internal fixation.

Case 2: A 43-year-old male patient injured his left leg in a fall, resulting in a closed tibial shaft fracture (AO/OTA 42-A1, 4F1A) with skin contusion (Figure 3). The Tscherne soft tissue injury classification was C2. The external traction fixator was applied after debridement in the emergency room. The radiograph showed satisfactory fracture alignment, and plate fixation was performed 8 d after the injury.

Case 3: A 41-year-old male patient, who had fallen from a height of 3 m, was diagnosed with a right pilon fracture (AO/OTA 43-C3) with a minor traumatic brain injury (Figure 4). The medial ankle skin showed contusion and stasis. The Tscherne soft tissue injury classification was C2. The external traction fixator was applied after

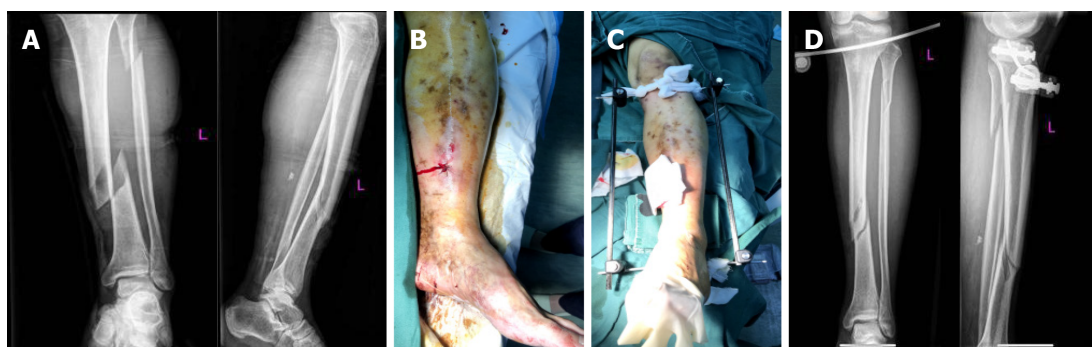


Figure 3 Illustrative case 2. A: Radiograph after injury (42-A1, 4F1A); B: Soft tissue swelling and skin contusion before external traction fixator installing; C: External traction fixator application. D: Preoperative radiograph showed a satisfactory fracture alignment.

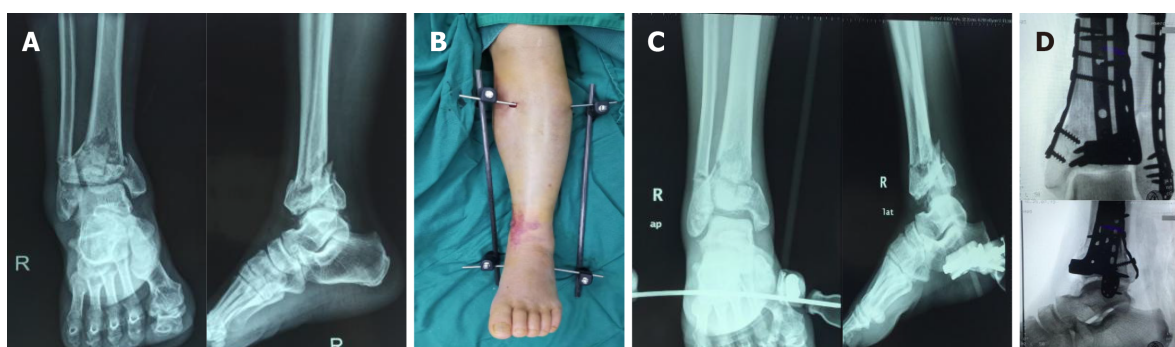


Figure 4 Illustrative case 3. A: Radiograph after injury (AO/OTA 43-C3); B: Soft tissue swelling and skin contusion after external traction fixator application; C: Preoperative radiograph showed an improved fracture alignment; D: Postoperative radiograph showed a plate combined fixation.

debridement in the emergency room. A radiograph showed satisfactory alignment of the fracture fragments, and plate fixation was performed using the anterior external-posterior internal combined incision approach 8 d after the injury.

Results

The demographic characteristics of the 402 patients are shown in Table 2. The mean age of the patients was 42.5 (18-71) years. Among these patients, 32.3% patients sustained injuries in car accidents; 10.7% patients, on falling from a height; 27.1% patients, in cycling accidents, 21.1% patients, during twisting motion, and 8.7% patients, in other accidents. Seventy-nine (19.7%) patients presented with concurrent comorbidities, as follows: 6.0% patients with brain trauma; 11.2% patients with chest injury; and 2.5% patients with abdominal injury. With the exception of two patients, external traction fixator was removed in all other patients 1 d before definitive surgery. The average duration of traction was 7.5 (3-26) d.

A total of 19 patients experienced related complications, including technique-associated complications in 6 patients and nursing-associated complications in 13 patients, leading to a total incidence of 4.7%. The details of complications of the cases are shown in Table 3. Differences were not observed with respect to sex, fracture side, soft tissue injury classification, and complications in different parts of the tibia. Complications associated with hammer insertion were significantly less frequently noted than those associated with drill insertion (2.9% *vs* 7.4%). In 6 patients, the complications were technique related, accounting for 31.6% (6/19) of all complications, and complete recovery was noted in 83.3% (5/6) of these patients. Case 13 experienced a significant decrease in sensation in the dorsum after drilling into the proximal tibia; hence, it was pulled out immediately. The patient had not completely recovered sensation at the final follow-up. A young male patient (Case 14) experienced a crack fracture around the pin trajectory after hammering into the proximal end of the tibia.

Discharge and loosening were the most common complications, accounting for 38.5% (5/13) and 30.8% (4/13) of all complications, respectively. A male patient (Case 7) developed a pin trajectory infection, which spread along the plantar fascia on the 8th d after traction, owing to diabetes mellitus. Plantar necrotizing fasciitis was

Table 2 Demographic data

	<i>n</i>	Complications	<i>P</i> value
Sex			0.403
Male	283	15	
Female	119	4	
Laterality			0.833
Left	160	8	
Right	242	11	
Pin placement			
Drill	163	12	0.040 ^a
Hammer	239	7	
Tscherne classification			0.722
C1	93	4	
C2	213	9	
C3	96	6	
Tibial fractures			0.775
AO41	115	5	
AO42	49	1	
AO43	127	7	
AO44	111	6	

^a*P* < 0.05.

considered. The patient underwent two procedures of debridement combined with placement of an antibiotic bone cement spacer and vacuum sealing drainage. He was finally cured on the 19th d. Vascular complications and compartment syndrome did not develop in this group.

DISCUSSION

In this study, we assessed the complications associated with preoperative external traction fixation in the staged treatment of tibial fractures and found that the associated complication rate was low and was not significantly associated with the severity of soft tissue injury and fracture site. We did not observe a difference in the incidence of complications with respect to sex, affected side, soft tissue injury classification, and fracture site. However, the incidence of complications associated with hammer insertion was significantly lower than that of those associated with drill insertion.

Tibial plateau, shaft, pilon, and ankle fractures are commonly encountered in trauma centers. Most of these fractures are caused by high-energy injuries, such as falls and traffic accidents, and result in limb shortening or instability, accompanied by severe soft tissue injuries. Soft tissue injury is an important reference when determining the optimal timing of internal fixation surgery, and swelling is a direct indicator. Definitive surgery can be scheduled when soft tissue swelling has reduced, as indicated by the appearance of skin wrinkles and epithelialization of the blisters. Therefore, two-staged management, consisting of initial fracture stabilization followed by internal fixation, was performed for these high-energy tibial fractures. In a study on the staged treatment of pilon fractures, Zelle *et al*^[7] reported that severe soft tissue injuries usually require a transitional stage of 1-4 wk. Canton *et al*^[8] reported that internal fixation can be attempted for tibial plateau fractures combined with soft tissue injuries 2-13 d after the injury^[8]. Axial traction at the fracture site aids in recovering the limb length and alignment while reducing pain and providing favorable conditions for the elimination of swelling^[9]. Accordingly, in our study, the mean time to reduce

Table 3 Complications details

Cases	Age	Sex	Injury mechanism	Fractures, AO/OTA	Pin placement	Complications	Comorbidity	Outcome	Traction duration in d
1	32	Male	Traffic trauma	43	Drilling	Discharge	-	Recovered	9
2	45	Male	Fall	44	Hammering	Cellulitis	-	Recovered	10
3	56	Male	Traffic trauma	43	Drilling	Loosening	-	Recovered	11
4	41	Male	Traffic trauma	41	Drilling	Dorsal foot hypoesthesia	Obesity	Recovered	10
5	32	Female	Traffic trauma	44	Hammering	Effusion	-	Recovered	11
6	56	Female	Traffic trauma	41	Drilling	Loosening	-	Recovered	9
7	67	Male	Traffic trauma	43	Drilling	Effusion& Loosening	Osteoporosis	Recovered	8
8	55	Male	Fall	41	Drilling	Infection &Loosening	Diabetes	Twice debridement	8
9	67	Male	Traffic trauma	43	Drilling	Erysipelas	Hypertension	Recovered	6
10	44	Male	Traffic trauma	41	Hammering	Reducing ankle extension	-	Recovered	4
11	24	Male	Traffic trauma	41	Drilling	Effusion	-	Recovered	6
12	37	Male	Traffic trauma	44	Hammering	Loosening	-	Recovered	6
13	19	Male	Traffic trauma	44	Drilling	Dorsal foot hypoesthesia	-	No	2
14	28	Male	Traffic trauma	44	Hammering	Iatrogenic fracture	-	Recovered	8
15	37	Female	Traffic trauma	42	Drilling	Reducing hallux extension	Obesity	Recovered	7
16	32	Male	Traffic trauma	43	Drilling	Effusion	-	Recovered	8
17	56	Male	Traffic trauma	43	Hammering	Reducing hallux extension	Coronary heart disease	Recovered	8
18	45	Male	Traffic trauma	43	Drilling	Loosening	-	Recovered	19
19	56	Female	Traffic trauma	44	Drilling	Effusion	Diabetes	Recovered	11

swelling before the surgery was 7.5 d.

The transfixion pin traction system was first used for stabilization before intramedullary nailing of the tibia, a procedure initially described as “traveling traction”^[10]. Later, it was improved and simplified by many researchers, and has been widely used as a minimally invasive auxiliary reduction technique in surgery^[11-13]. Inspired by the “traveling traction”^[14], the insertion point in this technique is the common bone traction point for lower limb fractures, such as that in femoral supracondylar, tibial tubercle, and calcaneal traction. Previous reports have described the selection of the entry points and safety zones in detail^[9,15-17]. We believe that palpation and accurate marking of the insertion points are important steps for reducing the incidence of complications. However, patient anatomy and surgical techniques vary. The irregular triangular structure of the proximal tibia, for example, may lead to the development of iatrogenic fractures owing to slippage of the traction pin and failure to pass through the two cortices (Case 14). In addition, obesity can directly affect the palpation of the bony marks at the point of entry. A Steinmann pin is required to access the bone through the soft tissue, which may cause damage to the nerves, blood vessels, and tendons (Cases 4 and 15).

Linn *et al*^[8] reported a popliteal artery pseudoaneurysm caused by proximal tibial traction. However, injury to the major vessels can be avoided as long as the insertion site is not located excessively posteriorly to the proximal tibia during the operation^[17]. Vascular injury was not noted in our study. Sobol *et al*^[9] reported that transfixion pin injuries are usually resolved after pin removal. This is in accordance with our study, where 83.3% (5/6) of the patients with transfixion pin injuries recovered completely. We believe that in the future, high-risk patients, such as those with obesity, may warrant B-mode ultrasound-guided pin placement to reduce the development of complications, similar to the method used by Yu *et al*^[18] for the reduction of femoral

neck fractures.

Denham pins are better anchored in the bone but cause more damage to the soft tissue than smooth pins during placement^[19]. In our study, soft tissue injury caused by high-speed power drilling was more frequently noted than hammer injury; resolution of the associated complication was difficult. The heat generated during drilling may have caused soft tissue and bone damage^[20]. However, pain may be experienced when the hammer method is used, despite the administration of local anesthesia. In our center, hammers were used for pin insertion during 2015 and 2016; therefore, this approach was abandoned and replaced by drilling. Although an association between the type of pin site dressing and development of deep infection was not reported in a recent study, nursing care was described as an important factor in pin site infection^[21]. In this regard, smooth Steinmann pins are advantageous in that they facilitate discharge. Common pin site infections or erysipelas and swelling can be controlled well with frequent dressing changes and antibiotic treatment. Moreover, an incision wound that is too small for pin insertion may lead to poor drainage, which should be considered when inserting the pin. Special caution must be exercised when the procedure is performed for patients with diabetes owing to the increased risk of adverse outcomes.

Regardless of the traction type, a certain force must be applied to the soft tissue and ligaments to achieve fracture alignment. Excessive traction can lead to vascular and nerve damage. In this regard, the most serious outcome in tibial fractures is the development of compartment syndrome. Shakespeare *et al*^[22] reported that every additional 1 kg of traction weight would result in a 5.7% increase in the posterior deep fascial pressure and a 1.6% increase in the anterior fascial pressure. To prevent excessive tension, in our study, the length of the healthy limb was used as a reference during traction, and the distal pin was pulled 1 cm beyond the healthy limb. This value can be marked on the connecting rod in advance, and can be adjusted depending on the radiographic assessment, if necessary.

Although some researchers reported a certain correlation between the Tscherne soft tissue injury classification and postoperative complications^[23], our results indicated that the severity of soft tissue injury was not associated with pin insertion complications. It is worth noting that, in all our patients, the pin was placed far from the site of injury. The stabilizing effect of external traction fixation may be more important than that of conventional bone traction for combined ligament injuries. This is different from bone traction alone, which is contraindicated in ligament injuries. The pin insertion and postoperative complications, especially postoperative infection, are important concerns among orthopedic surgeons. The first stage treatment was usually maintained for 14 or 28 d^[24]. Beyond this period, the risk of infection may need to be reassessed or an external fixator may be used as the final treatment. It is recommended that the time interval between stage 1 and stage 2 should not be more than 9 or 14 d^[25,26]. Evaluating the timing and interval of staged treatment requires a combination of individual patients and dynamically observed indicators of infection.

The limitations of this study included the lack of objective evaluation indicators, such as electromyography to evaluate the sensory and motor parameters. Furthermore, the clinical significance of some complications, such as injury of the medial superior knee artery branch caused by supracondylar traction, was not assessed. In addition, the analysis of the association between temporary fixation and definitive care complications was limited due to the lack of a control group. The results of this study must be validated in a prospective comparative study.

CONCLUSION

Staged treatment of tibial fractures is suitable for soft tissue injury and is not indicated for immediate internal fixation. External traction fixation for staged treatment is a simple procedure which involves fewer components that allow for quick installation. In this cases series, we found that the incidence of early complications was low, and that the technique could be safely performed by a junior resident. As a “travelling traction,” external traction fixation for staged treatment may also play an important role in the prevention of deep venous thrombosis of the lower extremities and chest complications. We believe that external traction fixation is a viable alternative for the staged treatment of tibial fractures.

ARTICLE HIGHLIGHTS

Research background

External traction fixation for staged treatment is a simple procedure which involves fewer components that allow for quick installation.

Research motivation

The safety of external traction fixation has not been well studied.

Research objectives

Analyze the early complications associated with preoperative external traction fixation in the staged treatment of tibial fractures.

Research methods

This study included 402 patients who underwent external traction fixation for high-energy tibial fractures.

Research results

Overall incidence of complications was low (4.7%); vascular injury or compartmental syndrome was not noted.

Research conclusions

Complications of hammer insertions were significantly fewer than drill insertions.

Research perspectives

We found a low incidence of early complications related to the fixation.

REFERENCES

- 1 **Jain D**, Selhi HS, Yamin M, Mahindra P. Soft tissue complications in distal tibial fractures managed with medial locking plates: A myth or reality? *J Clin Orthop Trauma* 2017; **8**: S90-S95 [PMID: 29158651 DOI: 10.1016/j.jcot.2017.07.001]
- 2 **Sohn HS**, Chung JY, Song HK. Analysis of complications and clinical outcomes in the treatment of segmental tibial fractures according to the method of internal fixation. *Asian J Surg* 2019; **42**: 740-745 [PMID: 30471888 DOI: 10.1016/j.asjsur.2018.11.001]
- 3 **Linn MS**, Indresano AA, Schwartz A. Popliteal artery pseudoaneurysm: an unusual complication of tibial traction. *Am J Orthop (Belle Mead NJ)* 2015; **44**: E156-E159 [PMID: 25950546]
- 4 **Liporace FA**, Yoon RS, Kesani AK. Transient common peroneal nerve palsy following skeletal tibial traction in a morbidly obese patient - case report of a preventable complication. *Patient Saf Surg* 2012; **6**: 4 [PMID: 22353163 DOI: 10.1186/1754-9493-6-4]
- 5 **Snyder RL**, Buhr BR. Bilateral peroneal nerve injuries in a patient with bilateral femur fractures: a case report. *J Orthop Trauma* 2000; **14**: 216-219 [PMID: 10791676 DOI: 10.1097/00005131-200003000-00014]
- 6 **Suri T**, Dabas V, Sural S, Dhal A. Pseudoaneurysm of the anterior tibial artery: A rare complication of proximal tibial steinman pin insertion. *Indian J Orthop* 2011; **45**: 178-180 [PMID: 21430875 DOI: 10.4103/0019-5413.77140]
- 7 **Zelle BA**, Dang KH, Ornell SS. High-energy tibial pilon fractures: an instructional review. *Int Orthop* 2019; **43**: 1939-1950 [PMID: 31093715 DOI: 10.1007/s00264-019-04344-8]
- 8 **Canton G**, Santolini F, Stella M, Moretti A, Surace MF, Murena L. Strategies to minimize soft tissues and septic complications in staged management of high-energy proximal tibia fractures. *Eur J Orthop Surg Traumatol* 2020; **30**: 671-680 [PMID: 31893294 DOI: 10.1007/s00590-019-02619-9]
- 9 **Sobol G**, Gibson P, Patel P, Koury K, Sirkin M, Reilly M, Adams M. Low Incidence of Neurovascular Complications After Placement of Proximal Tibial Traction Pins. *Orthopedics* 2017; **40**: e1004-e1008 [PMID: 29058756 DOI: 10.3928/01477447-20171012-04]
- 10 **Moed BR**, Watson JT. Intramedullary nailing of the tibia without a fracture table: the transfixion pin distractor technique. *J Orthop Trauma* 1994; **8**: 195-202 [PMID: 8027887]
- 11 **Beazley JC**, Hull P. Temporary intra-operative reduction techniques for tibial fracture fixation: A review of the literature. *Injury* 2010; **41**: 1228-1233 [PMID: 20691444 DOI: 10.1016/j.injury.2010.07.250]
- 12 **Jackson M**, Topliss CJ, Atkins RM. Fine wire frame-assisted intramedullary nailing of the tibia. *J Orthop Trauma* 2003; **17**: 222-224 [PMID: 12621265]
- 13 **Krause PC**, Whatley AN, Mautner JF. A technique for nailing severely shortened and displaced tibia fractures. *J Orthop Trauma* 2008; **22**: 138-141 [PMID: 18349784 DOI: 10.1097/BOT.0b013e31815a58c4]
- 14 **Lareau CR**, Daniels AH, Vopat BG, Kane PM. Emergency department external fixation for provisional treatment of pilon and unstable ankle fractures. *J Emerg Trauma Shock* 2015; **8**: 61-64 [PMID: 25709258 DOI: 10.4103/0974-2700.150400]
- 15 **DeFroda SF**, Gil JA, Born CT. Indications and anatomic landmarks for the application of lower extremity traction: a review. *Eur J Trauma Emerg Surg* 2016; **42**: 695-700 [PMID: 27448398 DOI: 10.1007/s00264-016-0344-8]

- 10.1007/s00068-016-0712-3]
- 16 **Kwon JY**, Ellington JK, Marsland D, Gupta S. Calcaneal traction pin placement simplified: a cadaveric study. *Foot Ankle Int* 2011; **32**: 651-655 [PMID: [21733432](#) DOI: [10.3113/FAI.2011.0651](#)]
- 17 **Kwon JY**, Johnson CE, Appleton P, Rodriguez EK. Lateral femoral traction pin entry: risk to the femoral artery and other medial neurovascular structures. *J Orthop Surg Res* 2010; **5**: 4 [PMID: [20205875](#) DOI: [10.1186/1749-799X-5-4](#)]
- 18 **Yu S**, Xu X, Pandey NR, Zhao Y, Jing J. A safe percutaneous technique for the reduction of irreducible femoral neck fractures using ultrasound localization of the femoral vascular and nervous structures at the hip. *Medicine (Baltimore)* 2019; **98**: e15163 [PMID: [30985696](#) DOI: [10.1097/MD.00000000000015163](#)]
- 19 **Althausen PL**, Hak DJ. Lower extremity traction pins: indications, technique, and complications. *Am J Orthop (Belle Mead NJ)* 2002; **31**: 43-47 [PMID: [11827229](#)]
- 20 **Matullo KS**, Gangavalli A, Nwachuku C. Review of Lower Extremity Traction in Current Orthopaedic Trauma. *J Am Acad Orthop Surg* 2016; **24**: 600-606 [PMID: [27454023](#) DOI: [10.5435/JAAOS-D-14-00458](#)]
- 21 **Potter JM**, van der Vliet QMJ, Esposito JG, McTague MF, Weaver M, Heng M. Is the proximity of external fixator pins to eventual definitive fixation implants related to the risk of deep infection in the staged management of tibial pilon fractures? *Injury* 2019; **50**: 2103-2107 [PMID: [31530380](#) DOI: [10.1016/j.injury.2019.09.016](#)]
- 22 **Shakespeare DT**, Henderson NJ. Compartmental pressure changes during calcaneal traction in tibial fractures. *J Bone Joint Surg Br* 1982; **64**: 498-499 [PMID: [7096431](#)]
- 23 **Valderrama-Molina CO**, Estrada-Castrillón M, Hincapié JA, Lugo-Agudelo LH. Intra- and interobserver agreement on the Oestern and Tscherne classification of soft tissue injury in periarticular lower-limb closed fractures. *Colomb Med (Cali)* 2014; **45**: 173-178 [PMID: [25767306](#)]
- 24 **Guerado E**, Cano JR, Fernandez-Sanchez F. Pin tract infection prophylaxis and treatment. *Injury* 2019; **50** Suppl 1: S45-S49 [PMID: [31003703](#) DOI: [10.1016/j.injury.2019.03.044](#)]
- 25 **Bhandari M**, Zlowodzki M, Tornetta P 3rd, Schmidt A, Templeman DC. Intramedullary nailing following external fixation in femoral and tibial shaft fractures. *J Orthop Trauma* 2005; **19**: 140-144 [PMID: [15677932](#) DOI: [10.1097/00005131-200502000-00012](#)]
- 26 **Nieto H**, Baroan C. Limits of internal fixation in long-bone fracture. *Orthop Traumatol Surg Res* 2017; **103**: S61-S66 [PMID: [28082050](#) DOI: [10.1016/j.otsr.2016.11.006](#)]



Published by **Baishideng Publishing Group Inc**
7041 Koll Center Parkway, Suite 160, Pleasanton, CA 94566, USA

Telephone: +1-925-3991568

E-mail: bpgoffice@wjgnet.com

Help Desk: <https://www.f6publishing.com/helpdesk>

<https://www.wjgnet.com>

