



3

Name of Journal: *World Journal of Clinical Cases***Manuscript NO:** 58205**Manuscript Type:** CASE REPORT**Pancreatic cancer with ovarian metastases: A case report and review of literature**Wang SD *et al.* Pancreatic cancer with ovarian metastases

Shun-Da Wang, Liang Zhu, Huan-Wen Wu, Meng-Hua Dai, Yu-Pei Zhao

Match Overview



1	Crossref 38 words Falchook, G.S.. "Clinicopathologic features and treatment strategies for patients with pancreatic adenocarcinoma and ova	2%
2	Internet 16 words crawled on 30-Jul-2020 worldwidescience.org	1%
3	Internet 14 words crawled on 27-Apr-2020 f6publishing.blob.core.windows.net	1%
4	Internet 13 words crawled on 21-Aug-2020 www.mdpi.com	1%
5	Crossref 12 words Liyang Han. "Combination of MUC5ac and WT-1 immunohistochemistry is useful in distinguishing pancreatic ductal carcinoma	1%



Pancreatic cancer with ovarian metastases: A case report and literature review



ALL

IMAGES

VIDEOS

619,000 Results

Any time ▾

Including results for **pancreatic cancer with ovarian metastasis** a case report and literature review.

Do you want results only for **Pancreatic cancer with ovarian metastases: A case report and literature review**?

Cutaneous metastasis from pancreatic cancer: A case report ...

<https://www.ncbi.nlm.nih.gov/pmc/articles/PMC4214468>

In the present report **63** cases of **cutaneous metastases** originating from pancreatic cancer were identified during a systematic literature review and are discussed in detail. The review revealed that cutaneous metastatic disease from pancreatic cancer occurs in all ages, ranging from 40 to 85 years, however, more commonly occurs in older patients, with a mean age of 62.9 years and ...

Cited by: 13

Author: Hai-Yan Zhou, Xian-Bao Wang, Fang Ga...

Publish Year: 2014

Utility of ovarian biopsy in pancreatic metastasis of high ...

<https://www.ncbi.nlm.nih.gov/pmc/articles/PMC4907032>

Utility of **ovarian** biopsy in **pancreatic metastasis** of high-grade serous **ovarian** carcinoma: **A case report**. ... Only a few cases of **ovarian cancer** metastasizing to the pancreas have been reported in the **literature** ... primary **pancreatic cancer** with a **metastatic ovarian** tumor, and double primary cancers of the ovary and pancreas. ...

Cited by: 1

Author: Kohei Nakamura, Kentaro Nakayama, M...

Publish Year: 2016

Case Report: Mammary and rectal metastases from an ovarian ...

<https://www.ncbi.nlm.nih.gov/pmc/articles/PMC4275024>

In the **case** of breast **metastases**, surgery should not to be the first option, since in **metastatic ovarian cancer** the chemotherapy is the main course of treatment. Unfortunately, breast **metastasis** of an **ovarian cancer** indicates an extensive disease. The prognosis is poor. Previous studies **report** survivals



ALL

IMAGES

VIDEOS

571,000 Results

Any time ▼

Cutaneous metastasis from pancreatic cancer: A case report ...

<https://www.ncbi.nlm.nih.gov/pmc/articles/PMC4214468>

In the present report 63 cases of **cutaneous** metastases originating from pancreatic cancer were identified during a systematic literature review and are discussed in detail. The review revealed that **cutaneous metastatic disease** from pancreatic cancer occurs in all ages, ranging from 40 to 85 years, however, more commonly occurs in older patients, with a mean age of 62.9 years and ...

Cited by: 14

Author: Hai-Yan Zhou, Xian-Bao Wang, Fang Ga...

Publish Year: 2014

Pancreatic acinar cell carcinoma with bilateral ovarian ...

<https://www.sciencedirect.com/science/article/pii/S1424390315000782>

Jul 01, 2015 · Introduction. About 337,872 new cases of **pancreatic** carcinoma are estimated to occur worldwide each year .Patients with **metastatic** disease have an estimated 5-year survival rate of 2%, with a median overall survival shorter than 12 months for treated patients in several published series , , .PACC is a rare exocrine **pancreatic** tumor accounting for 1% of all **pancreatic** ...

Cited by: 10

Author: Hector R. Callata-Carhuapoma, Espera...

Publish Year: 2015

Utility of ovarian biopsy in pancreatic metastasis of high ...

<https://www.ncbi.nlm.nih.gov/pmc/articles/PMC4907032>

May 04, 2016 · Only a few cases of **ovarian cancer** metastasizing to the pancreas have been reported in the **literature** (4,5). Differences exist in the treatment of patients with primary **ovarian cancer** and those with primary **pancreatic cancer**. Therefore, it is important to confirm the precise diagnosis when **ovarian** and **pancreatic** tumors are discovered ...

Cited by: 1

Author: Kohei Nakamura, Kentaro Nakayama, M...

Publish Year: 2016

Successful resection of pancreatic metastasis from ...

<https://www.ncbi.nlm.nih.gov/pubmed/30953505>



577,000 Results Any time ▾

Cutaneous metastasis from pancreatic cancer: A case report ...

<https://www.ncbi.nlm.nih.gov/pmc/articles/PMC4214468>

In the present report 63 cases of **cutaneous** metastases originating from pancreatic cancer were identified during a systematic literature review and are discussed in detail. The review revealed that **cutaneous metastatic disease** from pancreatic cancer occurs in all ages, ranging from 40 to 85 years, however, more commonly occurs in older patients, with a mean age of 62.9 years and 63.5% patients ...

Cited by: 14

Author: Hai-Yan Zhou, Xian-Bao Wang, Fang Ga...

Publish Year: 2014

Case Report: Mammary and rectal metastases from an ovarian ...

<https://www.ncbi.nlm.nih.gov/pmc/articles/PMC4275024>

In the **case** of breast **metastases**, surgery should not to be the first option, since in **metastatic ovarian cancer** the chemotherapy is the main course of treatment. Unfortunately, breast **metastasis** of an **ovarian cancer** indicates an extensive disease. The prognosis is poor. Previous studies **report** survivals ranging between 13 days and 3.5 years 10.

Cited by: 2

Author: Mounia Amzerin, Camilo Garcia, Claudia ...

Publish Year: 2014

ACTH-secreting pancreatic neuroendocrine carcinoma with ...

<https://www.ncbi.nlm.nih.gov/pmc/articles/PMC4713687>

Ovarian metastatic NENs from the pancreas are rare. Only 2 cases have been previously reported [9,21] and this study represents the third **case** of an ACTH-secreting **pancreatic NEN with ovarian metastases**. Our **case** developed peritoneal implants and bilateral **ovarian** involvement, suggesting that the tumor spread through direct peritoneal seeding.

Cited by: 1

Author: Wen-Qing Yao, Xia Wu, Gan-Di Li, Wei-L...

Publish Year: 2015

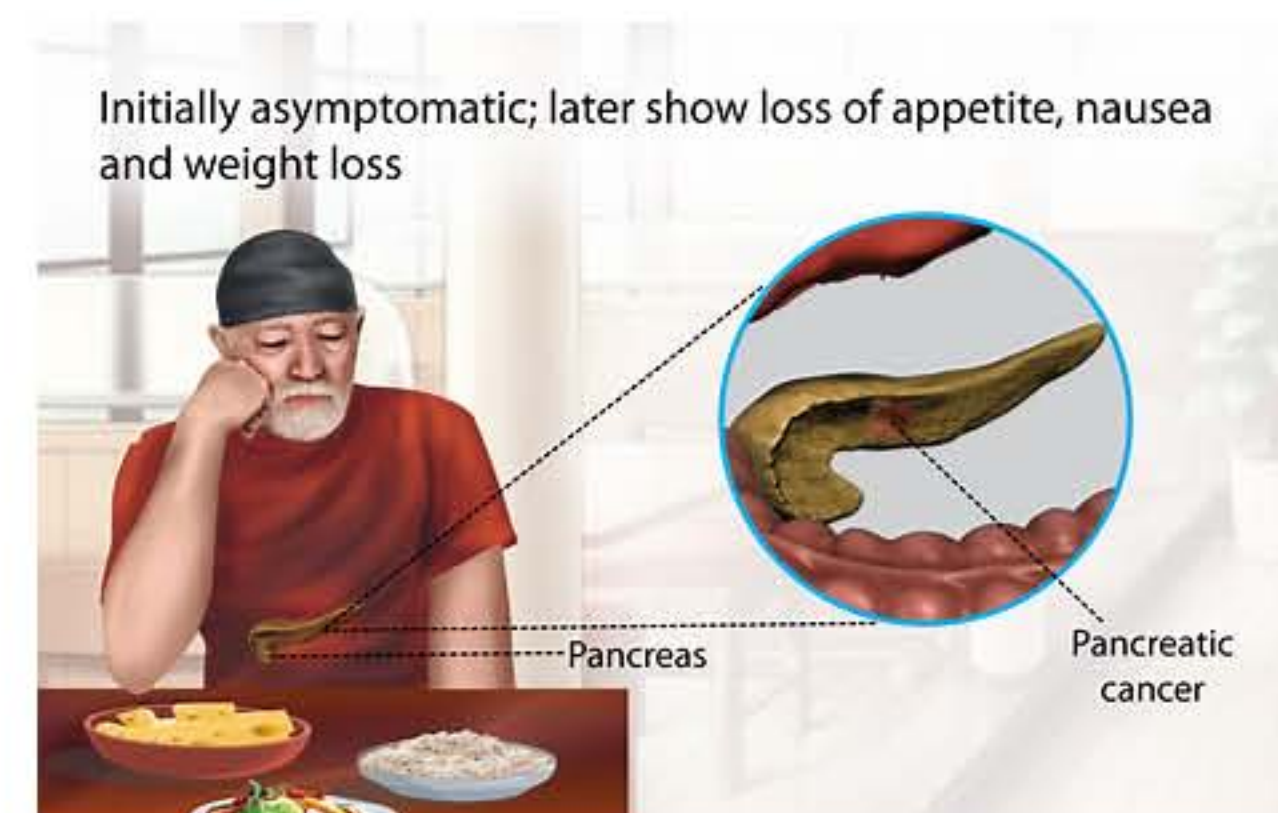
Pancreatic Metastasis of High-Grade Papillary Serous ...

<https://www.hindawi.com/journals/crim/2012/943280> ▾

Introduction Reports of epithelial **ovarian** carcinomas **metastatic** to the pancreas are very rare. We herein present a **metastasis** of high grade papillary serous **ovarian cancer** to mid portion of pancreas

Pancreatic Cancer

Medical Condition



Initially asymptomatic; later show loss of appetite, nausea and weight loss

Cancer of pancreas, an organ which is behind the lower part of the stomach.

- 📊 Rare (Fewer than 200,000 cases per year in US)
- 🧪 Often requires lab test or imaging
- 👨‍⚕️ Treatment from medical professional advised
- 🕒 Can last several months or years

The exact cause of pancreatic cancer is unknown. Risk factors include diabetes, chronic pancreatitis and stomach ulcer. In the early stage, it is asymptomatic. Common symptoms at later stages are weight loss and abdominal pain. Treatment includes surgeries and other therapies.

Symptoms

Early stage of pancreatic cancer may be asymptomatic. Symptoms will